



CASE REPORT

Case Report: Whole exome sequencing helps in accurate molecular diagnosis in siblings with a rare co-occurrence of paternally inherited 22q12 duplication and autosomal recessive non-syndromic ichthyosis. [version 1; referees: 2 approved]

Aayush Gupta¹, Yugal Sharma¹, Kirti Deo¹, Shamsudheen Vellarikkal^{2,4},
Rijith Jayarajan², Vishal Dixit², Ankit Verma², Vinod Scaria^{3,4}, Sridhar Sivasubbu^{2,4}

¹Department of Dermatology, Dr. D.Y. Patil Medical College, Pune, India

²Genomics and Molecular Medicine, CSIR Institute of Genomics and Integrative Biology, Delhi, India

³GN Ramachandran Knowledge Center for Genome Informatics, CSIR Institute of Genomics and Integrative Biology, Delhi, India

⁴Academy of Scientific and Innovative Research, Center for Genome Informatics, CSIR Institute of Genomics and Integrative Biology, Delhi, India

v1 First published: 31 Jul 2015, 4:446 (doi: [10.12688/f1000research.6779.1](https://doi.org/10.12688/f1000research.6779.1))
Latest published: 31 Jul 2015, 4:446 (doi: [10.12688/f1000research.6779.1](https://doi.org/10.12688/f1000research.6779.1))

Abstract

Lamellar ichthyosis (LI), considered an autosomal recessive monogenic genodermatosis, has an incidence of approximately 1 in 250,000. Usually associated with mutations in the transglutaminase gene (*TGM1*), mutations in six other genes have, less frequently, been shown to be causative. Two siblings, born in a collodion membrane, presented with fish like scales all over the body. Karyotyping revealed duplication of the chromosome arm on 22q12+ in the father and two siblings. Whole exome sequencing revealed a homozygous p.Gly218Ser variation in *TGM1*; a variation reported earlier in an isolated Finnish population in association with autosomal recessive non-syndromic ichthyosis. This concurrence of a potentially benign 22q12+ duplication and LI, both rare individually, is reported here likely for the first time.

Open Peer Review

Referee Status: 

Invited Referees

1 2

version 1

published
31 Jul 2015



report



report

- Mohamed Badawy Abdel-Naser**, Ain Shams University Egypt
- Regina Fölster-Holst**, University of Kiel Germany

Discuss this article

Comments (0)

Corresponding authors: Vinod Scaria (vinods@igib.in), Sridhar Sivasubbu (sridhar@igib.in)

How to cite this article: Gupta A, Sharma Y, Deo K *et al.* **Case Report: Whole exome sequencing helps in accurate molecular diagnosis in siblings with a rare co-occurrence of paternally inherited 22q12 duplication and autosomal recessive non-syndromic ichthyosis.** [version 1; referees: 2 approved] *F1000Research* 2015, 4:446 (doi: [10.12688/f1000research.6779.1](https://doi.org/10.12688/f1000research.6779.1))

Copyright: © 2015 Gupta A *et al.* This is an open access article distributed under the terms of the [Creative Commons Attribution Licence](#), which permits unrestricted use, distribution, and reproduction in any medium, provided the original work is properly cited.

Grant information: Authors acknowledge funding from the Council of Scientific and Industrial Research (CSIR), India through Grant No. BSC0122 (CARDIOMED).

The funders had no role in study design, data collection and analysis, decision to publish, or preparation of the manuscript.

Competing interests: The authors declare that they have no competing interests.

First published: 31 Jul 2015, 4:446 (doi: [10.12688/f1000research.6779.1](https://doi.org/10.12688/f1000research.6779.1))

Introduction

Autosomal recessive congenital ichthyosis (ARCI), a heterogeneous disorder of cornification of skin, encompasses three clinical subtypes: lamellar ichthyosis (LI; OMIM 242300); congenital ichthyosiform erythroderma (CIE; OMIM 242100); and harlequin ichthyosis (HI; OMIM 242500)¹. LI has an incidence of approximately 1 in 250,000. Over 115 mutations in *TGM1* and less frequent ones in six other genes (*NIPAL4z*, *ALOX12B*, *CGI-58*, *FLJ39501*, *ICHYN* and *ABCA12*) have been associated with the LI/CIE phenotypic spectrum worldwide^{2,3}. Overlapping phenotypes and the non-specificity of the conventional histopathology, makes clinical diagnosis challenging in many cases and inaccurate in some⁴. Whole exome sequencing has become a useful diagnostic aid for genetic disorders including multigene dermatoses such as epidermolysis bullosa^{5,6} and acrokeratosis verruciformis⁷.

Case report

Two, 8 and 6-year-old, siblings born out of a non-consanguineous marriage (Figure 1a) presented with hyperpigmented fish-like scales all over the body including face and flexures ectropion, loss of lateral half of eyebrows and alopecia along the scalp margins (Figure 1b–1e). Both siblings were heat intolerant, photosensitive and hypohidrotic. Born uneventfully vaginally they were encased in a collodion membrane which was shed within a week of birth. There was no family history of any dermatoses. Slit lamp examination revealed bilateral keratitis. Karyotyping of their parents and the siblings performed previously revealed duplication of the chromosome arm on 22q12+ in the father and two siblings. The patients were put on daily oral (5 mg) isotretinoin after analysing their lipid profile.

Considering the diagnosis of LI, whole exome sequencing was attempted. Genomic DNA (gDNA) was isolated from 5 ml of blood⁸ of each of the affected children after obtaining written

informed consent conforming to the institutional ethical committee approvals (Dr. D.Y. Patil Vidyapeeth, Pune. Approval number DYPV/EC/178/14). The whole exome capture and library preparation (Nextera expanded exome, Illumina Inc., USA) were carried out according to the manufacturer's instructions and followed by high throughput sequence generation on HiSeq 2500 with default 101 paired end single index sequence by synthesis chemistry (Illumina Inc., USA). The raw sequence reads were trimmed at a Phred score of 30 leaving over 44.9 and 33.45 million reads respectively for the two siblings. The variations were called against the hg19 version of the human genome using standard GATK-Picard pipeline with Burrows-Wheeler Alignment according to GATK best practice⁹. The variants from the genomes of both siblings were further analysed using ANNOVAR¹⁰ for coding region and also screened using the NCBI-Clinvar database (<http://www.ncbi.nlm.nih.gov/clinvar/>). Analysis revealed a homozygous p.Gly218Ser variation in *TGM1* previously reported to be associated with autosomal recessive non-syndromic ichthyosis in an isolated Finnish population¹¹. The variant mapped to the transglutaminase domain in the protein (Figure 1g) and was also predicted to be pathogenic by both SIFT (Sorts Intolerant From Tolerant)¹⁵ and PolyPhen2¹⁶ (Polymorphism Phenotyping v2). This variation was further validated in parents and both siblings by site-specific PCR using a forward primer CTTCTCCTGGGGTCAGGCA and reverse primer GAGAAGTCCCAGGCTCCATC (Sigma Aldrich). The PCR was done using *taq* polymerase (Invitrogen, USA, Cat. No. 10342053) according to the manufacturer supplied protocol with a Tm of 60.5°C. The PCR products were size selected and gel purified (2% agarose) using qiaquick gel extraction kit (QIAGEN, NL) and performed capillary sequencing (Applied Biosystems) performed using manufacturer instruction. Analysis revealed the variant was heterozygous in parents, while homozygous in both affected siblings (Figure 1f).

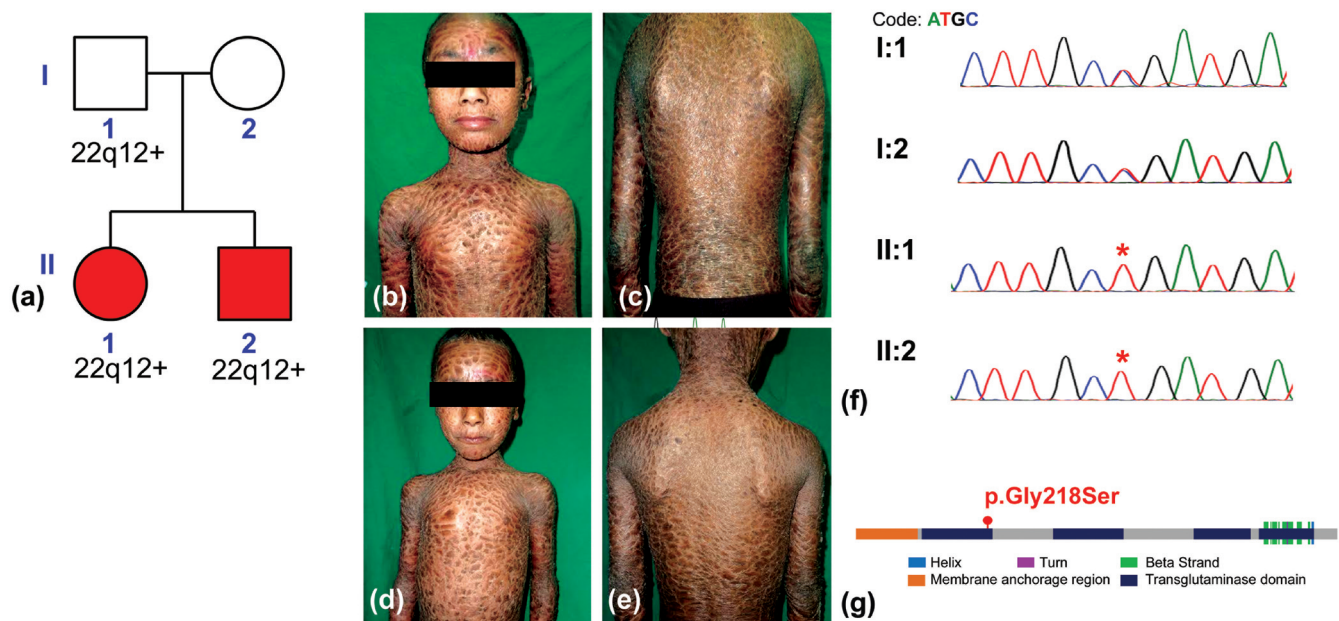


Figure 1. a) Pedigree of the family; (b), (c) and (d), (e) correspond to the ventral and dorsal views of siblings II:1, and II:2 respectively and shows hyperpigmented fish-like scales all over the body including face and flexures, ectropion, loss of lateral half of eyebrows and hair along scalp margins. Panel (f) shows the chromatogram from capillary sequencing for the parents and siblings, while panel (g) shows the domain organization of the protein and the location of the p.Gly218Ser variation with respect to the protein domains.

Follow up after two years of low dose isotretinoin, titrated intermittently, revealed complete subsidence of ectropion, eclabium and alopecia with residual fine scales.

Discussion

ARCI is a rare disorder with an estimated prevalence of 1 per 200,000 population in Europe and 1 per 200,000–300,000 population in the United States. Neonates with LI typically present with a collodion membrane which dries and peels away and is replaced by brown, plate-like scales over the entire body. Disease course ranges from very mild to severe, latter entailing ectropion, eclabium, scarring supraciliary and scalp alopecia, and palmoplantar hyperkeratosis¹¹.

DNA based molecular diagnosis is crucial in ichthyosis as it provides a firm basis for genetic counseling of affected individuals and families, and also permits prenatal diagnosis. In a cohort of 520 independent families with ARCI, mutations were identified by direct sequencing of the 6 ARCI genes identified to date in 78% of patients: 32% harbored mutations in *TGMI*, 16% in *NIPALA*, 12% in *ALOX12B*, 8% in *CYP4F22*, 5% in *ABCA12*, and 5% in *ALOXE3*. Whole exome sequencing may fill in the diagnostic lacuna of at least 22% of the patients who failed in this study to exhibit mutations in any of the known ARCI genes, indicating the existence of additional loci, such as 2 loci on chromosome 12p11.2-q13¹². The 22q12+ duplication is known to cause cat eye syndrome, which has a range of potential morbidities with the occurrence of characteristic triad of iris coloboma, aural tags and/or pits and anal atresia¹⁴, though none of these features were present in the father or the children.

To the best of our knowledge, this is the first reported concurrence of a potentially benign 22q12+ duplication and LI, both of which are extremely rare individually. The mother of the siblings is now pregnant and the present finding will be used to help screen the foetus prenatally.

Consent

Written informed consent for publication of their clinical details and clinical images was obtained from the parent of the patients.

Data availability

The raw exome sequencing data are available at the NCBI Sequence Read Archive (<http://www.ncbi.nlm.nih.gov/sra>), accession numbers SRX1096915 (II:1) and SRX1096920 (II:2).

Author contributions

AG, YKS and KD identified the patient, took the biopsies for histopathology and sent the blood for DNA analyses. They helped in writing the initial case report as well as editing and formatting the manuscript. SKV, RJ, VD and AV isolated the DNA, performed the quality checks, prepared the exome capture and sequencing library, performed the exome sequencing. SKV performed data quality checks on the reads, reference alignments, variant call and computational prioritisation of the variants, designed and performed the validation experiments. SS and VS conceptualised and oversaw the DNA isolation, quality checks, exome sequencing, exome sequence analysis and validation and contributed to writing the manuscript.

Competing interests

The authors declare that they have no competing interests.

Grant information

Authors acknowledge funding from the Council of Scientific and Industrial Research (CSIR), India through Grant No. BSC0122 (CARDIOMED).

I confirm that the funders had no role in study design, data collection and analysis, decision to publish, or preparation of the manuscript.

Acknowledgements

Authors acknowledge Dr. Vamsi Y Krishna for critical comments and members of VS, SS labs and the GUARDIAN Consortium for their help and support.

References

- Oji V, Tadini G, Akiyama M, *et al.*: **Revised nomenclature and classification of inherited ichthyoses: results of the First Ichthyosis Consensus Conference in Sorèze 2009.** *J Am Acad Dermatol.* 2010; **63**(4): 607–641.
[PubMed Abstract](#) | [Publisher Full Text](#)
- Herman ML, Farasat S, Steinbach PJ, *et al.*: **Transglutaminase-1 gene mutations in autosomal recessive congenital ichthyosis: summary of mutations (including 23 novel) and modeling of TGase-1.** *Hum Mutat.* 2009; **30**(4): 537–547.
[PubMed Abstract](#) | [Publisher Full Text](#) | [Free Full Text](#)
- Cao X, Lin Z, Yang H, *et al.*: **New mutations in the transglutaminase 1 gene in three families with lamellar ichthyosis.** *Clin Exp Dermatol.* 2009; **34**(8): 904–909.
[PubMed Abstract](#) | [Publisher Full Text](#)
- Akiyama M, Sawamura D, Shimizu H: **The clinical spectrum of nonbullous congenital ichthyosiform erythroderma and lamellar ichthyosis.** *Clin Exp Dermatol.* 2003; **28**(3): 235–240.
[PubMed Abstract](#) | [Publisher Full Text](#)
- Takeichi T, Liu L, Fong K, *et al.*: **Whole-exome sequencing improves mutation detection in a diagnostic epidermolysis bullosa laboratory.** *Br J Dermatol.* 2015; **172**(1): 94–100.
[PubMed Abstract](#) | [Publisher Full Text](#)
- Vellarikkal SK, Patowary A, Singh M, *et al.*: **Exome sequencing reveals a novel mutation, p.L325H, in the KRT5 gene associated with autosomal dominant Epidermolysis Bullosa Simplex Koebner type in a large family from Western India.** *Human Genome Variation.* 2014; **1**: 14007.
[Publisher Full Text](#)
- Gupta A, Sharma YK, Vellarikkal SK, *et al.*: **Whole-exome sequencing solves diagnostic dilemma in a rare case of sporadic acrokeratosis verruciformis.** *J Eur Acad Dermatol Venereol.* 2015.
[PubMed Abstract](#) | [Publisher Full Text](#)
- Miller SA, Dykes DD, Polesky HF: **A simple salting out procedure for extracting DNA from human nucleated cells.** *Nucleic Acids Res.* 1988; **16**(3): 1215.
[PubMed Abstract](#) | [Publisher Full Text](#) | [Free Full Text](#)
- DePristo MA, Banks E, Poplin R, *et al.*: **A framework for variation discovery and genotyping using next-generation DNA sequencing data.** *Nat Genet.* 2011; **43**(5): 491–8.
[PubMed Abstract](#) | [Publisher Full Text](#) | [Free Full Text](#)
- Wang K, Li M, Hakonarson H: **ANNOVAR: functional annotation of genetic variants from high-throughput sequencing data.** *Nucleic Acids Res.* 2010; **38**(16): e164.
[PubMed Abstract](#) | [Publisher Full Text](#) | [Free Full Text](#)

11. Laiho E, Ignatius J, Mikkola H, *et al.*: **Transglutaminase 1 mutations in autosomal recessive congenital ichthyosis: private and recurrent mutations in an isolated population.** *Am J Hum Genet.* 1997; **61**(3): 529–38.
[PubMed Abstract](#) | [Publisher Full Text](#) | [Free Full Text](#)
12. Oji V, Tadini G, Akiyama M, *et al.*: **Revised nomenclature and classification of inherited ichthyoses: results of the First Ichthyosis Consensus Conference in Sorèze 2009.** *J Am Acad Dermatol.* 2010; **63**(4): 607–41.
[PubMed Abstract](#) | [Publisher Full Text](#)
13. Fischer J: **Autosomal recessive congenital ichthyosis.** *J Invest Dermatol.* 2009; **129**(6): 1319–21.
[PubMed Abstract](#) | [Publisher Full Text](#)
14. Rosias PR, Sijstermans JM, Theunissen PM, *et al.*: **Phenotypic variability of the cat eye syndrome. Case report and review of the literature.** *Genet Couns.* 2001; **12**(3): 273–82.
[PubMed Abstract](#)
15. Sim NL, Kumar P, Hu J, *et al.*: **SIFT web server: predicting effects of amino acid substitutions on proteins.** *Nucleic Acids Res.* 2012; **40**(Web Server issue): W452–7.
[PubMed Abstract](#) | [Publisher Full Text](#) | [Free Full Text](#)
16. Adzhubei I, Jordan DM, Sunyaev SR: **Predicting functional effect of human missense mutations using PolyPhen-2.** *Curr Protoc Hum Genet.* 2013; Chapter 7: Unit7.20.
[PubMed Abstract](#) | [Publisher Full Text](#) | [Free Full Text](#)

Open Peer Review

Current Referee Status:



Version 1

Referee Report 24 August 2015

doi:10.5256/f1000research.7283.r10062



Regina Fölster-Holst

Department of Dermatology, Allergology and Venerology, University of Kiel, Kiel, Germany

Gupta *et al.* focused on two siblings with ARCI with confirmed TGM1 mutation. In addition they found 22q12 duplication in these siblings and in their father. The title and abstract are both appropriate for the article, and the abstract is a suitable summary. The diagnosis has been sufficiently described, however it is a little bit unclear whether the 22q12 duplication is associated with the ARCI. The authors mention the cat eye syndrome which is related to the duplication of the chromosome 22q12. What about the relevance of this finding? It should be worked out in more detail.

I have read this submission. I believe that I have an appropriate level of expertise to confirm that it is of an acceptable scientific standard.

Competing Interests: No competing interests were disclosed.

Referee Report 10 August 2015

doi:10.5256/f1000research.7283.r9750



Mohamed Badawy Abdel-Naser

Faculty of Medicine, Ain Shams University , Cairo, Egypt

- The authors reported 2 siblings with lamellar ichthyosis (LI) and the family pedigree shows the autosomal pattern of inheritance. In addition, duplicate 22q12+ has been shown in the father and the 2 affected siblings. **It seems, however, that this chromosomal abnormality is unrelated to the LI** as the father is phenotypically normal and the 2 siblings do not show any of the manifestations of this chromosomal abnormality. **The significance of this concurrence is not clear.**
- The authors may amend the manuscript by naming the site of the TGM1 mutation at the nucleotide level and the name of the gene transcript.
- It is not clear whether the authors examined the father and the affected siblings for manifestations of the duplicate 22q12+ (apart from the cat eye syndrome), such as learning difficulties, growth retardation, minor genital abnormalities of the boy etc.

- There are few typo errors. For instance, the "transglutaminase gene" is better given as "transglutaminase gene1" and "Ichyn" is "Ichthyin" etc.
- Ref.13 is not cited in the text and there seems to be a problem with enumeration of the references in the text.

I have read this submission. I believe that I have an appropriate level of expertise to confirm that it is of an acceptable scientific standard.

Competing Interests: No competing interests were disclosed.
