



Oncology

Capillary leak syndrome induced by neoadjuvant cisplatin and gemcitabine in a patient with bladder cancer

Marco Massafra^{*,1}, Maria Ilenia Passalacqua^{*}, Giuseppe Lupo, Giuseppe Altavilla, Mariacarmela Santaripa

Department of Human Pathology "G. Barresi", Medical Oncology Unit, University of Messina, 98122, Messina, Italy



ARTICLE INFO

Keywords:

Capillary leak syndrome
Bladder cancer
Gemcitabine

ABSTRACT

Capillary leak syndrome (CLS) is a rare disorder associated with an increased capillar permeability due to an endothelial damage, causing leakage of plasma and proteins into the interstitial compartment. CLS is characterized by rapidly developing edema, hypotension and hypoproteinemia. We observed CLS in a 54-year-old man affected by muscle-invasive bladder cancer who received neoadjuvant treatment with Cisplatin and Gemcitabine. Treatment with infusion of albumin and increasing corticosteroid doses and diuretics led to a complete regression of all signs and symptoms related to the disorder. Of note, the patient showed an objective complete response to chemotherapy and underwent radical surgery on schedule.

Introduction

Capillary leak syndrome (CLS) is a rare clinical condition characterized by rapid and reversible increase in endothelial permeability, with consequent leakage of plasma proteins into the interstitial space, with peripheral edema.¹ A similar phenomenon is observed during sepsis and less frequently in some manifestations of autoimmune diseases. This syndrome can be suspected in patients with hypotension, hypoalbuminemia without organ failure, partial or generalized edema, hemoconcentration and possible presence of paraproteins in the blood.

It can be idiopathic, called Clarkson's syndrome, or induced by other factors. In all cases, it can be a life-threatening condition. Among the causes that trigger this syndrome are counted some drugs, the engraftment syndrome, promyelocytic leukemia which undergoes induction treatment with either all-trans retinoic acid or arsenic trioxide, ovarian hyperstimulation syndrome, Hemophagocytic lymphohistiocytosis, hemorrhagic fever and snakebite. Acute renal failure, hypovolemic shock and coagulopathies are often found in the conditions mentioned above. Among the drugs that have been reported to lead to CLS in the literature, there is gemcitabine. This is a chemotherapeutic drug used in several types of malignancies, including bladder cancer. So far, few cases, less than ten, of CLS induced by gemcitabine are found in literature. Herein we report a case of CLS developed during last cycle of neoadjuvant treatment with cisplatin and gemcitabine in a patient with

muscle-invasive bladder cancer.

Case

A 54-year-old male, affected by locally advanced, muscle-invasive high grade papillary urothelial cancer of bladder, without any other significant comorbidities, was proposed for neoadjuvant chemotherapy with cisplatin 80 mg/mq and gemcitabine 1000 mg/mq 1,8 q21 for four cycles, as for guidelines.² During first three cycles, the patient did not receive the gemcitabine on day 8 for grade 3 neutropenia. The fourth cycle was completed. Five days after from receiving last dose of gemcitabine, the patient developed fever and petechiae on legs and trunk and he was hospitalized. The blood count showed anemia (hemoglobin 9,6 g/dL), leukopenia (1900 mm³) and thrombocytopenia (21,000 mm³). The renal function, hepatic function and coagulation parameters were within normal ranges. Albuminemia was decreased (3.07 g/dL). He was infused with platelets concentrate and started granulocyte colony-stimulating factor (G-CSF), 30 million units/die. He also started antibiotic therapy. On day 6th, the patient showed contraction of diuresis, hypotension and edema of the trunk and arms, bilaterally. Eco-color-doppler of the arms excluded venous thrombosis. Cardiac ecocolor-doppler and Angio-CT excluded thrombo-embolic events of arterial vessels. Edema progressively extended to lower limbs (Fig. 1) and the persistence of fever, neutropenia, hypotension posed the suspect

* Corresponding author. Department of Human Pathology "G. Barresi", Medical Oncology Unit, University of Messina, 98122 Messina, Italy.

E-mail address: marcomassafra@hotmail.it (M. Massafra).

¹ Equally contributed.

<https://doi.org/10.1016/j.eucr.2020.101461>

Received 15 September 2020; Received in revised form 18 October 2020; Accepted 20 October 2020

Available online 21 October 2020

2214-4420/© 2020 The Authors.

Published by Elsevier Inc.

This is an open access article under the CC BY-NC-ND license

(<http://creativecommons.org/licenses/by-nc-nd/4.0/>).

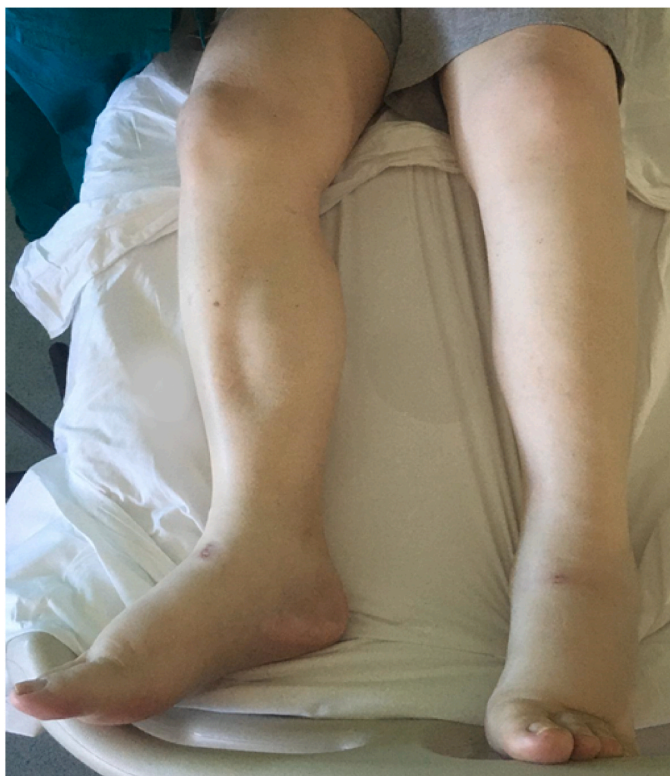

Fig. 1. Edema of lower limbs on the day of lower level of albuminemia (2,45 g/dL on day 8th).

of sepsis, excluded by serial hemocultures at feverish peak, urine cultures and by normal blood procalcitonin levels. On day 8th, total protein value and level of albuminemia further decreased (4,4 g/dL and 2,45 g/dL, respectively) (Fig. 2). There was no proteinuria in the urine test and we started treatment with albumin 20% 50 ml once daily. He also received intravenous furosemide (20 mg, once daily) and prednisone 25 mg, once daily and received transfusions of platelets and red blood cells concentrates. The clinical manifestations persisted, without

improvement, until day 12th, when we increased prednisone dose to 50 mg daily. On day 14th, we observed a reduction of edema of the trunk and arms, an increasing of blood cells count and normalization of diuresis and blood pressure. Renal function was within normal range. The complete normalization of clinical condition was observed on day 17th. No other cycles of chemotherapy were administered.

Interestingly, a Chest-Abdomen CT was performed and showed an objective complete response to neoadjuvant chemotherapy (Fig. 3).

The patient successfully underwent radical cystectomy and bilateral pelvic lymph node dissection, with construction of cutaneous ureteroileostomy ad modum Bricker. At histopathological examination, there was no evidence of infiltrating tumor on bladder wall, but the presence of carcinoma in situ, mild lymphocytes infiltration and focal granulomatous inflammatory reaction with macrophages and multinucleated giant cells. Nonspecific reactive lymphadenitis in 10 lymph nodes examined was detected.

Discussion

In this clinical experience, we have witnessed a rare adverse event of gemcitabine, for the first time reported in a patient with bladder cancer receiving neoadjuvant treatment.

We cannot exclude that cisplatin, associated with gemcitabine, might also have played a role in the pathogenesis of the disorder. Nevertheless, in view of the absence of the syndrome during the first cycles in which the patient had not sustained the eighth day of treatment with gemcitabine alone, a dose-dependent effect and a particular susceptibility of the patient in metabolizing the drug may be assumed.

Increasing in corticosteroid dosage led to a rapid improvement in symptoms, demonstrating an almost total ineffectiveness of prednisone at lower doses of 0.5 mg/kg, despite simultaneous diuretic therapy.

Combination of steroids and diuretics at an appropriate dosage has allowed the complete reversibility of symptoms 8–10 days after the start of treatment.

Similar experiences have already been published,³ underlying the need for prompt recognition of CLS and treatment, that need to be continued for some weeks before being able to see concrete clinical benefits.

The effectiveness of the therapy, with the complete clinical response to the chemotherapy treatment, has largely justified the risk of toxicity.

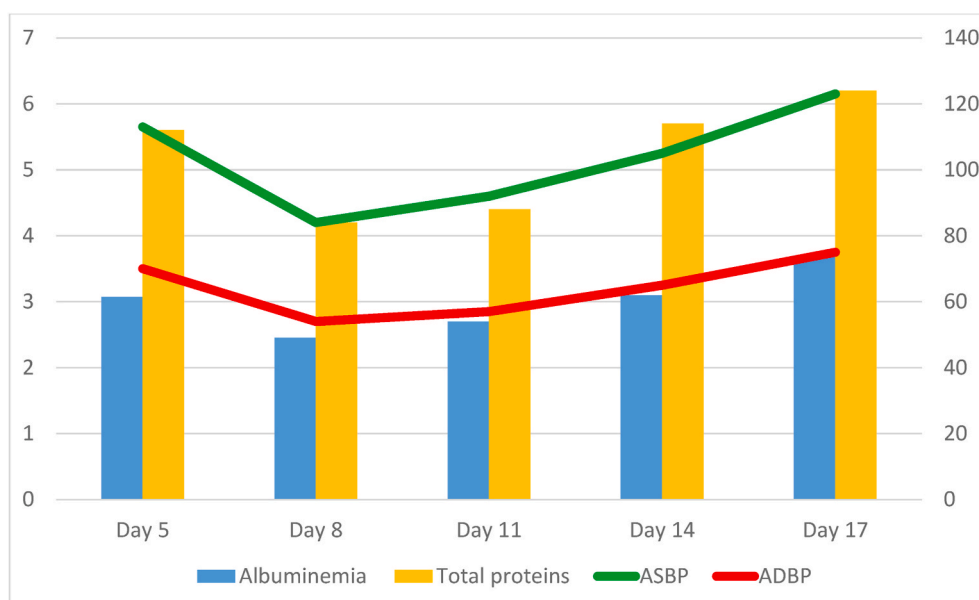


Fig. 2. The graphic shows decreasing of total proteins and albumin levels and blood pressure until day 8th from last administration of gemcitabine and subsequent gradual normalization of this values, more evident after improving therapy with prednisone on day 12th.

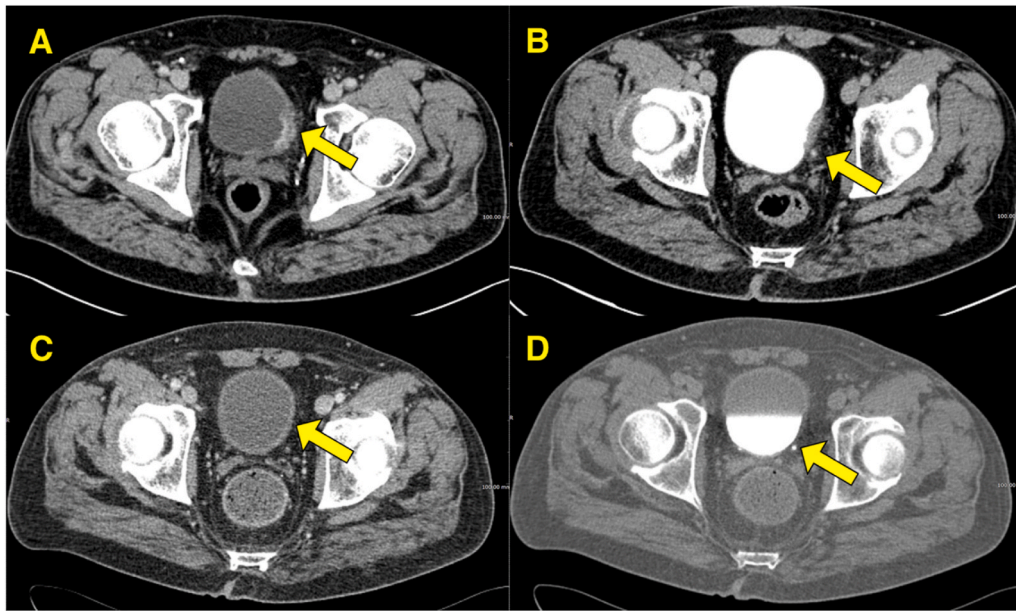


Fig. 3. Comparative CT with contrast images of the bladder neof ormation, before and after neoadjuvant chemotherapy treatment; A. Image before neoadjuvant treatment; C. Image after neoadjuvant treatment: we observed a total disappearance of the parietal lesion; B. Image before neoadjuvant treatment; D. Image after neoadjuvant treatment: the filling defect is no more detectable.

The patient was subsequently operated and he returned to his previous daily routine.

Cases of CLS have recently been reported to be associated with the administration of immune checkpoint inhibitors (ICIs), including Nivolumab⁴ and during infection with SARS-CoV-2.⁵ These experiences suggest a probable pathogenesis due to a dysregulation of the immune response with cytokine alterations, in the absence of a cellular inflammatory response, impacting on endothelial permeability.

Conclusion

CLS remains a clinical challenge, not just as a side effect of chemotherapy. The main goal is a prompt recognition of the symptoms, regardless of the underlying cause, because even if CLS is a rare syndrome, it needs to be treated properly to avoid serious and irreversible damages.

Focusing on the pathophysiological mechanism that underlies this syndrome, a predictive role of response to chemotherapy could be assumed, for example by inducing an increased activity of the inflammatory response. This hypothesis could be investigated by other clinical experiences.

Declaration of competing interest

The authors report no conflicts of interest in this work.

References

- Siddall E, Khatri M, Radhakrishnan J. Capillary leak syndrome: etiologies, pathophysiology, and management. *Kidney Int.* 2017;92(1):37–46. <https://doi.org/10.1016/j.kint.2016.11.029>.
- Flaig TW, Spiess PE, Agarwal N, et al. Bladder cancer, version 3.2020, NCCN clinical practice guidelines in oncology. *J Natl Compr Canc Netw.* 2020;18(3):329–354. <https://doi.org/10.6004/jnccn.2020.0011>.
- De Pas T, Curigliano G, Franceschelli L, Catania C, Spaggiari L, de Braud F. Gemcitabine-induced systemic capillary leak syndrome. *Ann Oncol.* 2001;12(11):1651–1652. <https://doi.org/10.1023/a:1013163831194>.
- Lescure C, Lescoat A, Salé A, et al. Systemic capillary leak syndrome (Clarkson's Disease) as a Complication of Anti-Programmed Death 1 Immunotherapy. *J Thorac Oncol.* 2019;14(6):e131–e132. <https://doi.org/10.1016/j.jtho.2019.02.003>.
- Pineton de Chambrun M, Cohen-Aubart F, Donker DW, et al. SARS-CoV-2 Induces Acute and Refractory Relapse of Systemic Capillary Leak Syndrome (Clarkson's Disease). *Am J Med.* 2020;S0002–9343(20):30373–30379. <https://doi.org/10.1016/j.amjmed.2020.03.057> [published online ahead of print, 2020 May 13].