

developed in association with silicone implants [4]. These lesions may develop after the implantation of either saline or silicone implants, but they develop more commonly when silicone implants are used. When a breast mass has developed after implant insertion, physicians must consider desmoid tumor and anaplastic large cell lymphoma in the diagnosis, although the incidence is low.

This article is the first report describing an implant-associated breast desmoid tumor in Korea. Although there is no evidence to suggest that breast augmentation with either saline or silicone implants is associated with an increased risk of developing desmoid tumors, appropriate vigilance and follow-up examinations are necessary to ensure a timely diagnosis, especially in women who develop capsular contraction following breast augmentation.

References

1. Shields CJ, Winter DC, Kirwan WO, et al. Desmoid tumours. *Eur J Surg Oncol* 2001;27:701-6.
2. Chummun S, McLean NR, Abraham S, et al. Desmoid tumour of the breast. *J Plast Reconstr Aesthet Surg* 2010; 63:339-45.
3. Sakorafas GH, Nissotakis C, Peros G. Abdominal desmoid tumors. *Surg Oncol* 2007;16:131-42.
4. Matrai Z, Toth L, Gulyas G, et al. A desmoid tumor associated with a ruptured silicone breast implant. *Plast Reconstr Surg* 2011;127:1e-4e.
5. Godwin Y, McCulloch TA, Sully L. Extra-abdominal desmoid tumour of the breast: review of the primary management and the implications for breast reconstruction. *Br J Plast Surg* 2001;54:268-71.

Mycosis Fungoides Misdiagnosed As Squamous Cell Carcinoma

Sang Wha Kim, Dong Jin Kim, Sung-No Jung

Department of Plastic and Reconstructive Surgery, Uijeongbu St. Mary's Hospital, The Catholic University of Korea College of Medicine, Uijeongbu, Korea

Correspondence: Sung-No Jung
Department of Plastic and Reconstructive Surgery, Uijeongbu St. Mary's Hospital, The Catholic University of Korea College of Medicine, 271 Cheonbo-ro, Uijeongbu 480-717, Korea
Tel: +82-31-820-3576, Fax: +82-31-847-0301
E-mail: jsn7190@catholic.ac.kr

No potential conflict of interest relevant to this article was reported.

Received: 19 Mar 2013 • Revised: 10 Apr 2013 • Accepted: 22 Apr 2013
pISSN: 2234-6163 • eISSN: 2234-6171
<http://dx.doi.org/10.5999/aps.2013.40.4.472> • Arch Plast Surg 2013;40:472-474

Copyright © 2013 The Korean Society of Plastic and Reconstructive Surgeons
This is an Open Access article distributed under the terms of the Creative Commons Attribution Non-Commercial License (<http://creativecommons.org/licenses/by-nc/3.0/>) which permits unrestricted non-commercial use, distribution, and reproduction in any medium, provided the original work is properly cited.

Mycosis fungoides (MF) is the most common type of cutaneous T-cell lymphoma (CTCL) [1]. It is progressive and is associated with poor prognoses in the later stages. The diagnosis of MF remains difficult due to the nonspecificity of the skin lesions and low prevalence. There are broad-based therapeutic options, but the choice of treatment strategy is difficult [2]. Currently, the treatment of MF is divided into two categories: topical therapy, such as corticosteroid, retinoid, and phototherapy, and systemic therapy, such as chemotherapy, electron beam therapy, and radiation therapy [3]. Surgical excision is not considered a first-line treatment option, especially in late-

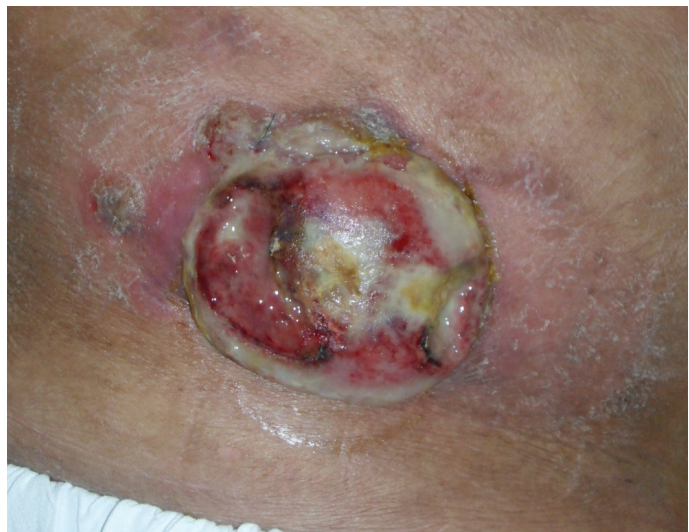

Fig. 1.

Preoperative findings of the mass. A 56-year-old man presented with a 2-year history of a solitary and protruding mass on his flank. The lesion was 7 cm x 6 cm and was erythematous, ulcerated, and bleeding.

stage disease.

In this article, we present the case of a patient with a huge ulcerated mass on his right flank that was initially diagnosed as squamous cell carcinoma (SCC) on punch biopsy. We performed wide excision of the tumor, but the final pathologic report revealed findings consistent with MF. Nevertheless, we obtained good results with surgical excision, despite the late stage of disease. We wish to emphasize the difficulty in diagnosing MF.

A 56-year-old male presented with a solitary protruding mass on his right flank that had been present for 2 years. At first, the size of the lesion was 1 cm × 1 cm, but it had suddenly grown during the three months prior to presentation. Upon physical examination, the 7 cm × 6 cm lesion was ulcerated with focal bleeding. A foul odor and purulent discharge were also detected (Fig. 1).

A punch biopsy was performed, and a diagnosis of poorly differentiated SCC was made. Computerized tomography (CT) revealed a lesion 5 cm in diameter and approximately 1.3 cm in elevation. There was no evidence of intra-abdominal extension of the malignant lesion or abnormal lymph node enlargement (Fig. 2). Positron emission tomography-computed tomography (PET-CT) showed no evidence of regional or distant metastasis.

Laboratory studies of red blood cell count, white blood cell count, and total serum protein were all within the normal range. There was no eosinophilia, and an human immunodeficiency virus test was

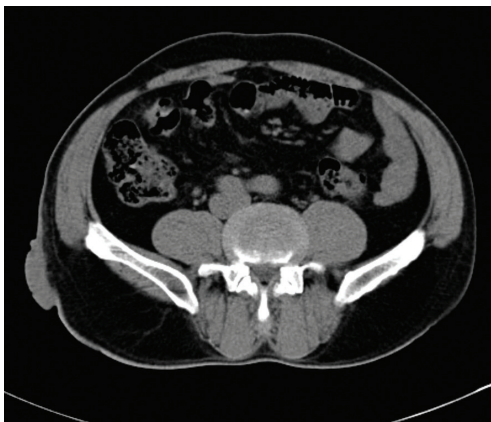


Fig. 2. Computerized tomography results showing the mass. The lesion extended 5 cm and was elevated 1.3 cm above the skin surface. There was no evidence of related intra-abdominal malignant extension or abnormal lymph node enlargement.

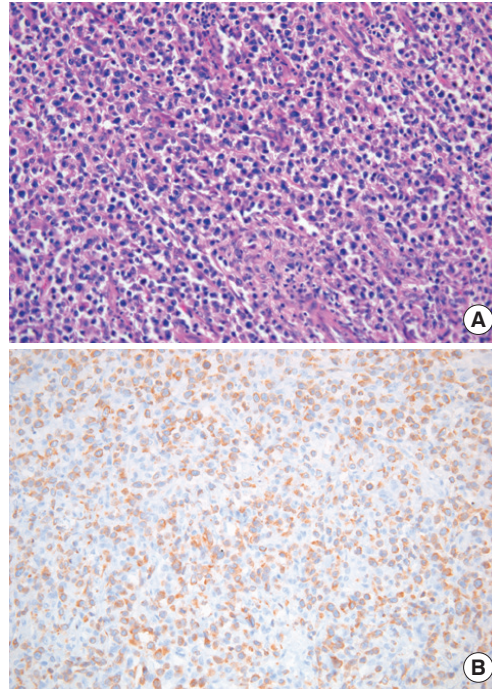


Fig. 3. Histopathologic examinations of mycosis fungoides. (A) The nuclei of the cells are hyperchromatic and highly irregular. There are uniform populations of mycosis cells and a conspicuous vasculature (H&E, ×200). (B) The lymphocytes have specific T cell monoclonality, expressing CD3 with dermal infiltration (CD 3 immunohistochemical staining, ×200).

negative [1].

We planned wide surgical excision and skin graft to cover the defect. The tumor was completely excised with a 3 cm safety margin. The tumor depth was limited to the subcutaneous layer. The wound healed without complications.

Pathologic examination revealed MF at the tumor stage. The nuclei of the cells were hyperchromatic and highly irregular. There was a uniform population of mycosis cells with a conspicuous vasculature. The dissection of collagen demonstrated the tumor stage of the MF (Fig. 3). Additionally, immunohistochemical examination confirmed that the lymphocytes had specific T-cell monoclonality, expressing CD3 (Fig. 3). A proliferation index (KI-67) was positive, suggesting an aggressive tumor. *In situ* hybridization for Epstein-Barr virus was negative.

A diagnosis of stage IIB MF (T3N0M0) was established. Two years after surgery, the patient has experienced no wound complications (Fig. 4), and follow-up PET-CT showed remission of the tumor.

CTCL is a type of T-cell malignancy that develops from the skin, which is the primary organ of its manifestation [3]. MF is the most common variant of CTCL. MF can develop at any age and usually involves sun-protected areas, especially the trunk. Typically, MF occurs at the patch stage or plaque stage as multiple erythematous scaling patches or plaques of varying size [4]. Once MF evolves to the

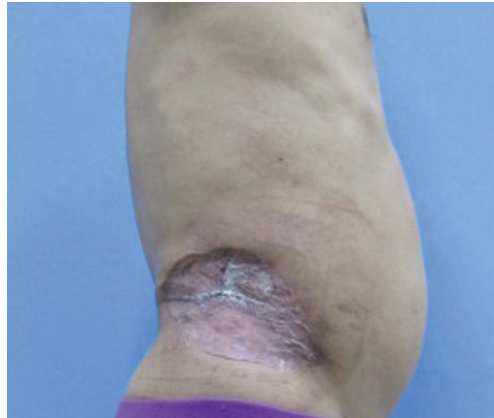


Fig. 4.
Two years after the surgery. The patient has experienced no wound complications, and follow-up positron emission tomography-computed tomography showed remission of the tumor.

tumor stage, tumor nodules are often palpable. The diagnosis of MF is difficult, and even once diagnosed, there is controversy over treatment modalities [3].

Currently, MF is a life-threatening malignancy, so non-surgical options are often the choice for treatment. In the early stages, targeted skin therapy, such as local corticosteroids, phototherapies, and nitrogen mustard ointment, are employed. In the later stages, a systemic agent is used, such as bexarotene therapy, interferon alfa, or vorinostat [3].

Hodak et al. [5] reported 7 cases of unilesional MF, which is characterized by solitary lesions and by benign histopathologic features indistinguishable from those of MF. Unilesional MF presents as a patch or plaque, consistent with stage IA MF, so most were cured with electron beam, topical steroid, or nitrogen therapy. In 2 cases, the lesion was small enough for primary closure after excision and so was surgically excised. The authors recommended superficial radiotherapy or excision as the treatment for unilesional MF. However, their unilesional MF differed from our case, which had progressed to the tumor stage with ulceration, classified as late stage (IIB) disease.

We performed wide excision, as if treating SCC, based on the physical exam, laboratory findings, and punch biopsy results. However, the final pathologic diagnosis confirmed MF. If the initial punch biopsy had diagnosed MF, non-surgical treatment strategies would have been considered in consultation with an oncologist. However, during the 2-year follow-up period, there was no local recurrence or distant metastasis. It appears that late stage MF can be cured by surgical excision.

There are no reports of successful primary surgical treatment of MF. Nor are there any reports of MF presenting as a huge tumor with ulceration [1-5]. Therefore, the long-term follow-up and prognosis of

MF after surgical treatment have not been previously described.

Clinicians should beware of punch biopsy results in the case of large and atypical skin lesions. Zic [3] insisted on at least two 6-mm punch biopsies from the oldest and thickest skin lesion. Although the role of the pathologist is pivotal in the diagnosis of non-melanoma skin cancer, the role of the clinician and pathologist is “equally” pivotal in the diagnosis of potential CTCL variant. Carbia et al. [1] explained that the skin lesions of MF do not always show a conclusive histology, especially in cases of lymphomatous ulcers because the malignant lymphoid cells are often mixed with a reactive inflammatory infiltrate, probably from superimposed infection. Thus, follow-up and repeated biopsies are often necessary.

We performed surgical excision of a late stage MF due to an initial misdiagnosis. Promising results were obtained at a 2-year follow-up visit. This case suggests that surgical treatment may be a viable treatment option for late stage MF without metastasis. In the case of an ulcerated lesion with bloody and purulent exudates, clinicians should be wary of punch biopsy results and consider repeat biopsy or incisional biopsy.

References

1. Carbia SG, Hochman A, Chain M, et al. Mycosis fungoides presenting with extensive pyoderma gangrenosum-like ulcers. *J Eur Acad Dermatol Venereol* 2002;16:401-4.
2. Galper SL, Smith BD, Wilson LD. Diagnosis and management of mycosis fungoides. *Oncology (Williston Park)* 2010;24:491-501.
3. Zic JA. Controversies in the management of the cutaneous T cell lymphomas. *Dermatol Ther* 2009;22:407-17.
4. Martorell-Calatayud A, Botella-Estrada R, Sanmartin-Jimenez O, et al. Papular mycosis fungoides: two new cases of a recently described clinicopathological variant of early mycosis fungoides. *J Cutan Pathol* 2010;37:330-5.
5. Hodak E, Phenig E, Amichai B, et al. Unilesional mycosis fungoides: a study of seven cases. *Dermatology* 2000;201:300-6.