



Extracapsular Invasion of Sentinel Lymph Nodes Is Not Associated With Disease Recurrence in Breast Cancer

Takaaki Fujii¹, Reina Yajima¹, Satoru Yamaguchi¹, Yasuhiro Yanagita^{1,2}, Tomomi Fujisawa^{1,2}, Tomoko Hirakata^{1,2}, Soichi Tsutsumi¹, Takayuki Asao¹, Misa Iijima³, Hiroyuki Kuwano¹

¹*Department of General Surgical Science, Graduate School of Medicine, Gunma University, Gunma, Japan*

²*Department of Breast Oncology, Gunma Cancer Center, Gunma, Japan*

³*Department of Pathology, Gunma Cancer Center, Gunma, Japan*

The purpose of this study was to evaluate the presence of extracapsular invasion (ECI) in positive sentinel lymph nodes (SLNs) as a predictor of disease recurrence in breast cancer. SLN biopsy was performed on 318 breasts of 316 breast cancer patients, of which 50 (15.7%) had positive SLNs. Six (12.0%) of these 50 cases had disease recurrence. The clinicopathologic features of these cases were reviewed. The ECI at SLNs was not significantly associated with disease recurrence. The recurrence-free interval by Kaplan-Meier curves did not differ significantly among patients with and without ECI at SLNs. On the other hand, metastasis at non-SLNs was observed in 12 cases (24.0%) among the 50 cases with positive SLNs, and in the non-SLN metastasis group there were 7 patients with ECI at non-SLNs. Three of 7 cases with ECI at non-SLNs had disease recurrence and none of those 5 without ECI at non-SLNs had disease recurrence. Our current study suggests that the presence of ECI at metastatic SLNs is not associated with recurrent disease in breast cancer. Our results also imply that patients with ECI at positive non-SLNs have a high risk of disease recurrence.

Key words: Sentinel lymph node – Breast cancer – Extracapsular invasion – Prognosis

Reprint requests: Takaaki Fujii, MD, PhD, Department of General Surgical Science, Graduate School of Medicine, Gunma University, 3-39-22 Showa-machi, Maebashi, Gunma 371-8511, Japan.
Tel.: +81-027-220-8224; Fax: +81-027-220-8230; E-mail: ftakaaki@med.gunma-u.ac.jp

The status of the axillary lymph node is one of the most important prognostic factors for breast cancer. Previous studies have demonstrated and confirmed that the presence of extracapsular invasion (ECI) at metastatic lymph nodes is significantly related to prognosis in various types of cancer including breast cancer.^{1–11} The ability of metastatic nodes to recruit degradation factors, such as matrix metalloproteinases, that permit cancer cells to break through the lymph node capsule is indicative of a very aggressive cancer.^{12–14} We have previously reported that the presence of an ECI at sentinel lymph nodes (SLNs) is a strong predictor of residual axillary disease, or nonsentinel lymph node (NSLN) metastasis in breast cancer.¹⁵ However, it remains to be determined whether ECI at SLNs, not axillary metastatic lymph nodes, is correlated with disease recurrence in breast cancer. The purpose of this study was to evaluate the presence of ECI in positive SLNs as a predictor of disease recurrence in breast cancer.

Methods

Three hundred sixteen consecutive patients and 318 breasts with breast cancer with clinically negative nodes were enrolled in this study biopsy at the Department of General Surgical Science, Graduate School of Medicine, Gunma University and Gunma Cancer Center from January 2005 to May 2008. Patients with previously diagnosed breast cancer, prior axillary surgery, or incomplete clinical information were excluded. None of the patients had received neo-adjuvant chemotherapy. Of these eligible cases, 50 (16.7%) had positive SLN and were analyzed in this study. Informed consent was obtained from all patients. Data were collected retrospectively.

The SLN biopsy was performed using both a radioisotope tracer and blue dye injection. Briefly, 12 hours prior to surgery, the radioisotope with ^{99m}Tc-phytate colloid was injected subcutaneously in the periareolar region. Intradermal injection of a blue dye, indigocarmine, in the periareolar region was also performed immediately prior to surgery. Any lymph nodes with blue dye and radioactivity were regarded as SLN. The SLN detection rate was 100%. Patients with positive SLN underwent complete axillary lymph node dissection. The SLN and other dissected NSLN were paraffin-embedded and stained with hematoxylin and eosin of single sections and were examined in permanent sections.

Micrometastases were defined as metastasis <2 mm in size.¹⁶

The primary tumor size, age, size of SLN foci, number of metastatic SLNs, histologic type, pathologic grade, lymphatic invasion at the primary tumor site, ECI at positive SLNs, estrogen receptor status, and HER2 status were tested as possible predictors of disease recurrence. Estrogen receptor (ER) status was assessed by Allred scores, and an Allred score of 3 or more was defined as ER positive.^{17,18} ECI was defined as extra capsular growth of tumor cells, invasion of perinodal fat or extranodal location of tumor cells.¹⁵ Fisher's exact test, the χ^2 test, and Student's *t* test were used to compare recurrent and nonrecurrent groups. Multivariate analysis was performed with logistic regression analysis to select covariates. Differences were considered to be significant when $P < 0.05$.

Results

The 50 cases with metastatic SLNs were divided into two groups based on the presence of disease recurrence. Table 1 shows the patients and tumor characteristics. Among 50 cases with positive SLN, 6 (12.0%) had disease recurrence. Table 1 also summarizes the results of the univariate analysis conducted to determine the relationship between the clinicopathologic variables and the presence of disease recurrence. Age, histologic type, histologic grade, the presence of metastasis in nonSLN, lymphovascular invasion, estrogen receptor status and HER2 status were not predictors of recurrent disease. The ECI at the SLNs also fell short of reaching statistical significance. As shown in Table 1, the positive predictive values of the ECI at the SLNs in the prediction of recurrent disease were only 25%. In the univariate analysis the primary tumor size and number of positive lymph nodes were factors significantly associated with disease recurrence. Time-to-tumor recurrence by Kaplan–Meier curves differ relatively among patients with the presence of ECI in SLNs, but no statistically significant differences were observed (Fig. 1).

Discussion

Lymph node metastasis is one of the most important prognostic factors in patients with breast cancer, and many studies have indicated that the number of metastatic nodes affect prognosis. Regarding ECI, previous studies have demonstrated and confirmed

Table 1 Patient and tumor characteristics

	Recurrence		P
	Present (n = 6)	Absent (n = 44)	
age (y.o.)	58.0 ± 5.2	57.7 ± 10.9	0.940
Disease:			
Papillotubular	1	7	0.842
Solid tubular	1		
Scirrhou	4	27	
others	0	5	
Tumor size (mm)	4.42 ± 1.99	2.35 ± 1.37	0.004
Histologic grade			
1	0	16	0.158
2	2	13	
3	4	15	
Size of largest SLN metastasis (mm)	8.40 ± 4.45	5.95 ± 3.91	0.210
Number of positive lymph nodes	3.17 ± 2.54	1.75 ± 1.26	0.036
ECI at SLNs	3	9	0.280
Lymphovascular invasion	6	42	0.564
Estrogen receptor status	4	39	0.408
HER2 status	1	10	0.850
Adjuvant therapy	5	43	0.564

Values are expressed as mean ±SD.

SLN, sentinel lymph node; ECI, extracapsular invasion.

that the presence of ECI at metastatic lymph nodes is significantly associated with prognoses in various types of cancer.¹⁻⁹ The importance of ECI as a risk factor for either local or distant recurrence and poorer survival in breast cancer patients also has been suggested and confirmed by several studies.^{11,12} Tumor cells invade the lymphatic vessels, which enable tumor cells to penetrate into the lymphatic system. Both experimental tumor models and human clinicopathologic data indicate that the growth of lymphatic vessels near solid tumors is often associated with lymph node metastasis.¹²⁻¹⁴ In our previous study, the presence of an ECI at SLNs was found to be a strong predictor of residual axillary disease, or NSLN metastasis.¹⁵ Thus, this study was undertaken to evaluate the presence of ECI in positive SLNs as a predictor of disease recurrence in breast cancer. The key observations made in this study can be summarized as follows: In our metastatic SLN cases, the number of positive lymph nodes and primary tumor size were significantly associated with the recurrence, but the presence of an ECI at SLNs was not a predictor of recurrent disease.

The ability of metastatic nodes to recruit degradation factors that permit cancer cells to break through the lymph node capsule is indicative of a

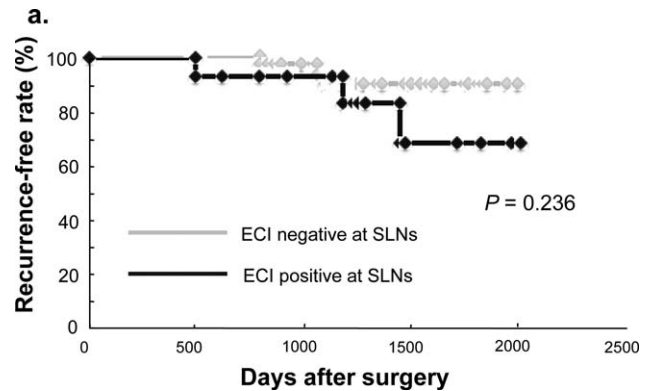


Fig. 1 Time-to-tumor recurrence by Kaplan–Meier curves differ relatively among patients with the presence of ECI in SLNs, but no statistically significant differences were observed.

very aggressive breast cancer. Thus, ECI is a biologic marker of aggressive nodal disease and reflects nodal spread. In our current study, ECI at metastatic SLNs was not a predictor of recurrent disease. In our series, metastasis at non-SLNs was observed in 12 cases (24.0%) among the 50 cases with positive SLNs (Table 1); in the NSLN metastasis group there were 7 patients with ECI at NSLNs. Three of 7 cases with ECI at NSLNs had disease recurrence and none of those 5 without ECI at NSLNs had disease recurrence and the positive predictive values of the ECI at the NSLNs in the prediction of recurrent disease was 42.9%; our findings essentially support those previous reports.¹⁻¹¹ On the other hand, 3 cases (50%) among the 6 cases with recurrence did not have NSLN metastasis. Our results indicate that the presence of ECI at positive lymph nodes is significantly related to the nodal spread of tumor cells in breast cancer patients. These findings suggest that there is a different mechanism or process to spread cancer cells and metastasis from ECI at positive nodes in breast cancer.

This study has several potential limitations. The major limitation is that it used retrospective methods of data collection. In addition, the number of cases in our study was relatively small and the follow-up periods were relatively short. However, the clinical implications of this data are very important, and these findings serve to emphasize that ECI at NSLNs, but not SLNs, may be an important prognostic factor for breast cancer. Additional research is needed to explore this putative association between the presence of ECI at NSLNs and the risk of recurrence.

In conclusion, our previous study and the present results suggest that the presence of ECI at metastatic SLNs is associated with the presence of positive NSLN but not associated with recurrent disease in breast cancer. Our results also imply that patients with ECI at positive NSLNs have a high risk of disease recurrence. Analyses from large randomized trials are warranted to evaluate this relationship between ECI at NSLN metastasis and disease recurrence.

Acknowledgments

The authors would like to thank Saitoh Y, Yano T, Ohno M, Matsui Y, and Muraoka S for their secretarial assistance. Supported by Grants-in-Aid from the Japanese Ministry of Education, Culture, Sports, Science and Technology. The authors declare that they have no competing financial interests.

References

- Fujii T, Tabe Y, Yajima R, Yamaguchi S, Tsutsumi S, Asao T *et al.* Extracapsular invasion as a risk factor for disease recurrence in colorectal cancer. *World J Gastroenterol* 2011;**17**(15):2003–2006
- Yano H, Saito Y, Kirihara Y, Takashima J. Tumor invasion of lymph node capsules in patients with Dukes C colorectal adenocarcinoma. *Dis Colon Rectum* 2006;**49**(12):1867–1877
- Komuta K, Okudaira S, Haraguchi M, Furui J, Kanematsu T. Identification of extracapsular invasion of the metastatic lymph nodes as a useful prognostic sign in patients with respectable colorectal cancer. *Dis Colon Rectum* 2001;**44**(12):1838–1844
- Heide J, Krull A, Berger J. Extracapsular spread of nodal metastasis as a prognostic factor in rectal cancer. *Int J Radiat Oncol Biol Phys* 2004;**58**(3):773–778
- D'Journo XB, Avaro JP, Michelet P, Trousse D, Tasei AM, Dahan L *et al.* Extracapsular lymph node involvement is a negative prognostic factor after neoadjuvant chemoradiotherapy in locally advanced esophageal cancer. *J Thorac Oncol* 2009;**4**(4):534–539
- Okamoto T, Tsuburaya A, Kameda Y, Yoshikawa T, Cho H, Tsuchida K *et al.* Prognostic value of extracapsular invasion and fibrotic focus in single lymph node metastasis of gastric cancer. *Gastric Cancer* 2008;**11**(3):160–167
- Lagarde SM, ten Kate FJ, de Boer DJ, Busch OR, Obertop H, van Lanschot JJ. Extracapsular lymph node involvement in node-positive patients with adenocarcinoma of the distal esophagus or gastroesophageal junction. *Am J Surg Pathol* 2006;**30**(2):171–176
- Yamashita H, Noguchi S, Murakami N, Toda M, Uchino S, Watanabe S *et al.* Extracapsular invasion of lymph node metastasis. A good indicator disease recurrence and poor prognosis in patients with thyroid microcarcinoma. *Cancer* 1999;**86**(5):842–849
- Stitzenberg KB, Meyer AA, Stem SL, Cance WG, Calvo BF, Klauber-DeMore N *et al.* Extracapsular extension of the sentinel lymph node metastasis: a predictor of nonsentinel node tumor burden. *Ann Surg* 2003;**237**(5):607–613
- Neri A, Marrelli D, Roviello F, De Stefano A, Guarnieri A, Pallucca E *et al.* Prognostic value of extracapsular extension of axillary lymph node metastases in T1 to T3 breast cancer. *Ann Surg Oncol* 2005;**12**(3):246–253
- Ilknur GB, Hilmi A, Tülay C, Oguz C, Selma S, Serdar S *et al.* The importance of extracapsular extension of axillary lymph node metastases in breast cancer. *Tumori* 2004;**90**(1):107–111
- Achen MG, Stacker SA. Molecular control of lymphatic metastasis. *Ann N Y Acad Sci* 2009;**1131**:225–234
- Royton D, Jackson DJ. Mechanisms of lymphatic metastasis in human colorectal adenocarcinoma. *J Pathol* 2009;**217**(5):608–619
- Fujii T, Tabe Y, Yajima R, Yamaguchi S, Tsutsumi S, Asao T *et al.* Process of distant lymph node metastasis in colorectal carcinoma of extracapsular invasion of lymph node metastasis. *BMC Cancer* 2011;**11**:216
- Fujii T, Yanagita Y, Fujisawa T, Hirakata T, Iijima M, Kuwano H. Implication of extracapsular invasion of sentinel lymph nodes in breast cancer: prediction of non-sentinel lymph node metastasis. *World J Surg* 2010;**34**(3):544–548
- Greene FL, Page DL, Fleming ID. *AJCC Cancer Staging Manual*. 6th ed. New York: Springer, 2002
- Allred DC, Harvey JM, Berardo M, Clark GM. Prognostic and predictive factors in breast cancer by immunohistochemical analysis. *Mod Pathol* 1998;**11**(2):155–168
- Shousha S. Oestrogen receptor status of breast carcinoma: Allred/H score conversion table. *Histopathology* 2008;**53**(3):346–347

© 2014 Fujii et al; licensee The International College of Surgeons. This is an Open Access article distributed under the terms of the Creative Commons Attribution Non-commercial License which permits use, distribution, and reproduction in any medium, provided the original work is properly cited, the use is non-commercial and is otherwise in compliance with the license. See: <http://creativecommons.org/licenses/by-nc/3.0>