



Original Article

## Dural sac shrinkage signs on spinal magnetic resonance imaging indicate overdrainage after lumboperitoneal shunt for idiopathic normal pressure hydrocephalus

Takashi Kawahara<sup>1</sup>, Masamichi Atsuchi<sup>1</sup>, Kazunori Arita<sup>2</sup>, Shingo Fujio<sup>2</sup>, Nayuta Higa<sup>2</sup>, FM Moinuddin<sup>3</sup>, Koji Yoshimoto<sup>4</sup>, Ryosuke Hanaya<sup>2</sup>

<sup>1</sup>Department of Neurosurgery, Atsuchi Neurosurgical Hospital, <sup>2</sup>Department of Neurosurgery, Kagoshima University, Kagoshima City, Japan, <sup>3</sup>Department of Neurologic Surgery, Mayo Clinic, Rochester, Minnesota, United States, <sup>4</sup>Department of Neurosurgery, Kyushu University, Higashi-ku, Hukuoka, Japan.

E-mail: Takashi Kawahara - takashi.kawahara@jifukai.jp; Masamichi Atsuchi - atsuchi0824@yahoo.co.jp; \*Kazunori Arita - karita@m2.kufm.kagoshima-u.ac.jp; Shingo Fujio - ofuji@m2.kufm.kagoshima-u.ac.jp; Nayuta Higa - nayuhiga@gmail.com; FM Moinuddin - moinuddin.f@mayo.edu; Koji Yoshimoto - kyoshimo@m.kufm.kagoshima-u.ac.jp; Ryosuke Hanaya - hanaya@m2.kufm.kagoshima-u.ac.jp



**\*Corresponding author:**

Kazunori Arita,  
Department of Neurosurgery,  
Kagoshima University,  
Kagoshima City, Japan.

karita@m2.kufm.kagoshima-u.ac.jp

Received : 28 March 2022

Accepted : 02 June 2022

Published : 23 June 2022

**DOI**

10.25259/SNI\_291\_2022

**Quick Response Code:**



### ABSTRACT

**Background:** We previously found the usefulness of dural sac shrinkage signs (DSSSs), which are the anterior shift of the spinal cord and dura mater behind the cord, detected by magnetic resonance imaging (MRI) at the thoracic level for the diagnosis of spontaneous intracranial hypotension (IH). This is a retrospective survey on the usefulness of DSSSs for the early detection of iatrogenic IH caused by overdrainage through a lumboperitoneal shunt (LPS) for patients with idiopathic normal pressure hydrocephalus (INPH).

**Methods:** Forty-five INPH patients had an LPS using a pressure programmable valve equipped with an anti-siphon device.

**Results:** Nine patients complained of orthostatic headache after the LPS, indicating IH due to overdrainage, which persisted for more than a week in three patients and 2–7 days in six patients. The headache was transient/nonorthostatic in ten patients and absent in 26 patients. The DSSSs and accompanying enlargement of the venous plexus were observed in all three patients with prolonged orthostatic headaches. Only the anterior shift of the dura mater was observed in 1 (4%) among 25 patients who had short-term orthostatic headache, transient/nonorthostatic headache, or absent headache, and underwent spinal MRI. A patient with prolonged severe orthostatic headache with both DSSSs eventually developed intracranial subdural effusion and underwent tandem valve surgery, which provided a quick improvement of symptoms. The DSSSs on thoracic MRI also disappeared promptly.

**Conclusion:** DSSSs may serve as objective signs for the diagnosis of IH due to overdrainage through an LPS for INPH.

**Keywords:** Dural sac shrinkage signs, Enlarged venous plexus, Lumboperitoneal shunt, Normal pressure hydrocephalus, Overdrainage

### INTRODUCTION

Lumboperitoneal shunt (LPS) is an effective treatment for idiopathic normal pressure hydrocephalus (INPH). Intracranial hypotension (IH) caused by overdrainage through LPS

This is an open-access article distributed under the terms of the Creative Commons Attribution-Non Commercial-Share Alike 4.0 License, which allows others to remix, transform, and build upon the work non-commercially, as long as the author is credited and the new creations are licensed under the identical terms.

©2022 Published by Scientific Scholar on behalf of Surgical Neurology International

presents with orthostatic headache, nuchal pain, vertigo, and nausea, which delay ambulation and prolongs hospital stay. A Japanese multicenter study found that approximately 30% of patients complained of symptoms of overdrainage after surgery.<sup>[7,11,13]</sup> Overdrainage often has severe sequelae including intracranial subdural effusion or hematoma.

To prevent overdrainage, the authors routinely use a pressure programmable valve initially set at the highest opening pressure and equipped with an anti-siphon device.<sup>[2,14]</sup> In addition, we provide sufficient hydration to the patients after surgery. However, a considerable proportion of the patients had symptoms of overdrainage even with these preventive measures. In general, magnetic resonance imaging (MRI) fails to show classic signs of IH during the early stage of overdrainage.<sup>[4,16,22]</sup>

The authors previously reported highly sensitive and specific signs of spontaneous IH called dural sac shrinkage signs (DSSSs), which are the anterior shift of the spinal cord and dura mater behind the cord and are often accompanied by a prominent epidural venous plexus.<sup>[9]</sup> These signs are easily detectable by sagittal T2-weighted MRI at the thoracic level.

We supposed the DSSSs may also provide good clues to diagnose secondary IH. Thus, we recently assessed the thoracic MRI scans of patients with post-LPS orthostatic headaches for DSSSs for the early detection of secondary IH due to overdrainage. This is a retrospective analysis of thoracic MRI scans of patients who underwent LPS in a single center for INPH.

## MATERIALS AND METHODS

### Patients

We retrospectively reviewed the charts and the neuroimaging database of 45 consecutive INPH patients who had an LPS during 10 months from July 2020 to April 2021 at the NPH Center in Atsuchi Neurosurgical Hospital, Kagoshima, Japan. The patient demographics are shown in Table 1. The diagnosis of NPH was based on clinical symptoms, brain MRI,<sup>[6]</sup> and tap test.

### Neuroradiological studies

Brain MRI was obtained before the tap test using 3-T or 1.5-T MR scanners in all patients. The basic imaging sequences for brain MRI were axial T1-weighted imaging, T2-weighted imaging, fluid-attenuated inversion recovery, and diffusion-weighted imaging. T2 and T2-fat saturated spinal images were obtained in all to screen the spinal lesions which may be a possible cause of present difficulty in ambulation and could be aggravated by LPS.<sup>[18,25]</sup> The preoperative spinal images were obtained before tap test in 25 patients and after tap test in the remaining 20 patients.

**Table 1:** Patients' demographics.

Characteristics	Variables
Total number	45
Mean age±SD	78.9±6.5
Median age	79
Sex (male/female)	23/22
Evans index (mean±SD)	
Baseline	0.342±0.035
After LPS*	0.330±0.034
Wilcoxon <i>P</i> value	<0.0001
Timed up and go test (seconds, mean±SD)	
Baseline	19.82±15.41
After LPS*	14.12±7.02
Wilcoxon <i>P</i> value	0.0069
Mini-mental state examination (mean±SD)	
Baseline	19.49±6.28
After LPS*	21.50±6.56
Wilcoxon <i>P</i> value	0.0012

SD: Standard deviation. \*Studied 3 to 6 months after surgery

After the LPS, 28 patients underwent spinal and brain MRI within 2 weeks of LPS.

### Definition of DSSS

The DSSSs were judged positive when the spinal cord and dura mater behind the spinal cord shifted anteriorly at the thoracic level. Based on the previous report, the anterior shift of the spinal cord was considered positive when the distance from the vertebral body to the anterior aspect of the spinal cord was <2 mm.<sup>[9]</sup> Similarly, the anterior shift of the dura mater was considered positive when the distance from the posterior aspect of the spinal cord to the dura mater was <2 mm.

### Surgical procedures

All 45 patients had an LPS under neuroleptanalgesia and local anesthesia with a minimally invasive technique as previously reported.<sup>[10,12]</sup> In this series, a pressure programmable valve equipped with an anti-siphon device (CERTAS Plus, Codman, NJ, USA) was used. The valve was initially set at the highest opening pressure: 40 cm H<sub>2</sub>O or more, higher than those set in the past randomized trial and large case series.<sup>[11,19]</sup> The patients were encouraged to ambulate from the day after surgery.

### Clinical evaluation of postoperative overdrainage

In this study, IH symptoms due to overdrainage after the LPS were surrogated by the most frequent and specific one, which was orthostatic headache. The degree of headache was determined as follows: absent: no headache at all; transient/nonorthostatic: transient and nonorthostatic headache that

subsided within 2 days without special treatment; short orthostatic: orthostatic headache that improved within a week with bed resting and hydration; and prolonged orthostatic: severe orthostatic headache persisting for more than a week even with strict bed resting and sufficient hydration.

### Statistical analysis

All the statistical analyses were conducted using StatFlex version 6.0 software (Artech Co., Ltd., Osaka, Japan). Depending on the characteristics of the data sets, the data were analyzed with Fisher's exact test or the Wilcoxon signed-rank test. Statistical significance was set at  $P < 0.05$ .

### Ethical consideration

This noninterventional study was approved by the Medical Ethics Committee of in Atsuchi Neurosurgical Hospital (R3-2, October 2021). This study was conducted according to the principles of the Declaration of Helsinki, as revised in 2000, and the Ethical Guidelines for Medical and Health Research Involving Human Subjects (effective on February 9, 2015) promulgated by the Ministry of Health, Labour and Welfare of Japan.

## RESULTS

### Efficacy of LPS

The mean baseline Evans index was  $0.342 \pm 0.035$  (SD); it significantly decreased to  $0.330 \pm 0.034$  (SD) 3–6 months after the LPS surgery (Wilcoxon's  $P < 0.0001$ ) [Table 1]. Ambulation ability was assessed using the timed up and go test (TUG); this assesses the time to stand up from a standard armchair, walk a distance of 3 m, turn, walk back to the chair, and sit down again.<sup>[21]</sup> The mean baseline TUG was  $19.82 \pm 15.41$  (SD) seconds. It significantly decreased to  $14.12 \pm 7.02$  (SD) 3–6 months after the surgery (Wilcoxon's  $P = 0.0069$ ). Cognitive function was examined with the mini-mental scale examination (MMSE). The mean baseline MMSE was  $19.49 \pm 6.28$  (SD). It significantly improved to  $21.50 \pm 6.56$  (SD) 3–6 months after the surgery (Wilcoxon's  $P = 0.0012$ ).

### Degree of headache after LPS

The number of patients with each category of headache was as follows; three had prolonged orthostatic, six had short orthostatic, ten had transient/nonorthostatic, and the remaining 26 patients had no headache [Table 2].

### Neuroradiological findings

Before LPS, spinal MRI showed only the anterior shift of the dura mater in 4 (8.9%) among 45 total patients. The incidence was 4% (1/25) before tap test and 15% (3/20) after tap test.

Spinal and brain MRI was obtained 2–14 days after the LPS for 28 patients: all three patients with prolonged orthostatic headache, all six patients with short orthostatic headache, eight of the ten patients with transient/nonorthostatic headache, and 11 of the 26 patients without headache [Table 2]. Both DSSSs accompanied by enlarged epidural venous plexus were observed in all three patients with prolonged orthostatic headaches. No DSSSs were observed in all six patients with short orthostatic headaches and in all 11 patients without headache. Only the anterior shift of the dura mater was observed in one of the eight patients with transient/nonorthostatic headache. The development of the DSSSs in patients with prolonged orthostatic headache was statistically significant compared with patients with transient/nonorthostatic, short orthostatic, or absent headache (3/3 vs. 1/25, Fisher's  $P = 0.0012$ ). All the cases with orthostatic headache except one (representative case) improved within 2 weeks with bed resting and sufficient hydration.

Post-LPS brain MRI for the 29 patients showed no classic signs of IH except the representative case.

### Representative case

A 71-year-old female visited our clinic with complaints of gradually aggravating gait disturbance, memory disturbance, and urinary incontinence for the past 3 years. The MMSE score was 25/30. She was diagnosed with probable INPH based on the symptom triad, disproportionately enlarged subarachnoid space hydrocephalus on MRI [Figures 1a and b],<sup>[6]</sup> and the result of tap test. There were no DSSSs on thoracic MRIs at the diagnosis of INPH [Figures 1c and d]. TUG decreased to 11.3 s after a spinal tap from the baseline of 14.9 s. She underwent LPS installment using CERTAS Plus valve, whose pressure was set at 40 cm at H<sub>2</sub>O or more.

Postoperatively, she complained of severe orthostatic headache, nausea, and nuchal pain. Although brain MRI obtained 3 days after the surgery did not show any abnormality except the slight reduction of the ventricular size [Figure 2a], spinal MRI at the thoracic level showed classic DSSSs and dilatation of the epidural venous plexus [Figure 2b] which had not been observed before LPS. In the following days, she was put on bed rest and given intravenous 1000 mL of extracellular fluid per day, which failed to improve the symptoms. On the 14<sup>th</sup> day after the surgery, brain MRI revealed a thin subdural effusion [Figure 2c]. Thoracic MRI showed the exacerbation of the DSSSs; the spinal cord appeared to be in contact with the vertebral body and dura mater behind the spinal cord at Th4–Th7 levels also appeared to be attaching to the spinal cord [Figure 2d].

She was judged to suffer severe overdrainage. On the 16<sup>th</sup> day after the LPS, tandem valve surgery involving the vertical insertion of an additional valve (SHUNTASSISTANT, Aesculap,

**Table 2:** Types and degrees of headache and radiological features after LPS ( $n=45$ ).

Variables	Headache			
	Absent	Transient and non-orthostatic	Short orthostatic	Prolonged orthostatic
Total number of patients	26	10	6	3
Number of patients who had thoracic MRI after LPS <sup>#</sup>	11	8	6	3
DSSSs on MRI at thoracic level				
Anterior shift of spinal cord	0	0	0	3 (100%)
Anterior shift of dura mater	0	1 (12.5%)	0	3 (100%)
Enlarged epidural venous plexus	0	0	0	3 (100%)
Number of patients who underwent cranial MRI after LPS <sup>#</sup>	11	8	6	3
Signs indicating intracranial hypotension	0	0	0	1 (33.3%)*

<sup>#</sup>Studied within 2 weeks after LPS. Short: persisted for less than a week. Prolonged: persisted for more than a week. \*Appeared 2 weeks after LPS.  
LPS: Lumboperitoneal shunt, DSSS: Dural sac shrinkage sign, MRI: magnetic resonance imaging

PA, USA) downstream to the previously installed valve was performed.<sup>[1,19]</sup>

After the surgery, the postural headache quickly disappeared. Brain and spinal MRIs 6 days after the tandem valve surgery revealed the disappearance of the overdrainage signs; subdural effusion, DSSSs, and dilatation of the epidural venous plexus [Figures 2e and f]. Her TUG decreased to 10.04 s 3 months after the LPS surgery, but the MMSE score did not change, 26/30, at the moment.

## DISCUSSION

The authors previously reported that the DSSSs on thoracic MRI are sensitive and specific markers of spontaneous IH.<sup>[9]</sup> This retrospective analysis showed that the DSSSs are common in patients with prolonged orthostatic headache after LPS but very rarely seen in patients without it. The results suggest that DSSSs may also be conducive to early detection of iatrogenic IH due to overdrainage through the LPS for INPH patients. The signs seemed to appear before the emergence of intracranial signs of overdrainage on MRI according to the representative case.

One-third of the patients who received LPS for the INPH were reported to suffer from the symptoms related to IH due to overdrainage including orthostatic headache.<sup>[7,11,13]</sup> Eventually, 3.5% of the patients had LPS and had received surgical intervention for the overdrainage such as replacement of the valve and ligation of shunt-tube.<sup>[20]</sup>

Several measures were proposed to prevent this complication, such as the use of a pressure controllable valve, anti-siphon device, tandem valve, and sufficient intravenous hydration for the patients after surgery. We currently use the pressure programmable valve equipped with an anti-siphon device initially set at the highest opening pressure of 40 cm H<sub>2</sub>O or more.<sup>[26]</sup> Commonly, the valve opening pressure is decreased gradually from one to 2 weeks after surgery unless

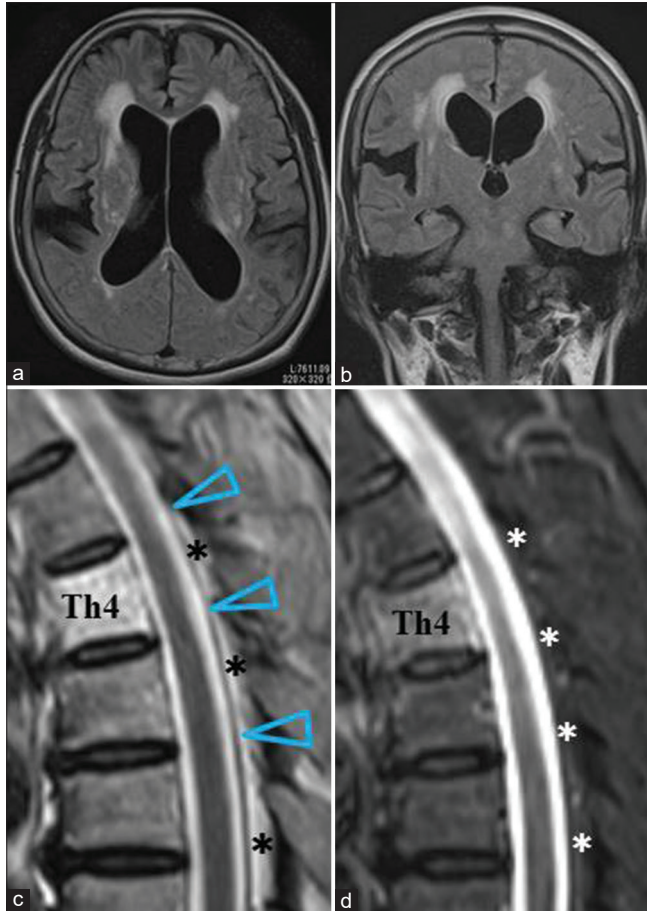
the overdrainage symptoms emerge. However, orthostatic headaches, including the transient cases, which are almost the pathognomonic symptoms of overdrainage, have been observed in 20–30% of patients who had LPS in our NPH center (data are not shown).

Brain MRI during the early stage usually fails to show the classic signs of IH, such as downward displacement of the brain, subdural fluid collection, and pituitary enlargement. We found no classic signs of IH on brain MRI in nine patients with orthostatic headache, while thoracic MRI showed DSSSs and a dilated epidural venous plexus in all three patients with prolonged headaches out of these nine patients.

Our proposed mechanism underlying DSSSs in patients who had an LPS is as follows [Figure 3]. Severe overdrainage, and a profound decrease of intrathecal cerebrospinal fluid, results in the shrinking of the spinal dural sac, leading to the anterior shift of dura mater posterior to the spinal cord on MRI, as the dura mater is not strongly attached to the spinal column posteriorly.<sup>[23]</sup> This decrease in cerebrospinal fluid leads to a straightening of the sac that otherwise follows the natural curvature of the spinal canal. The straightening of the spinal dural sac is most prominent at the thoracic level as this section of the spine has the longest physiological kyphotic curve; therefore, straightening of the sac in this region results in the anterior shift of the spinal cord. Furthermore, as observed in the representative case, thoracic MRI may show extreme forms of DSSSs; the spinal cord appeared to touch the vertebral body, and the dura mater behind the spinal cord also appeared to attach to the spinal cord.

The collapse of the dural sac is compensated for by the enlargement of the surrounding venous plexus, as explained by the extended idea of the Monro-Kellie doctrine to the spinal column.<sup>[17]</sup> This compensation mechanism in the spinal column may act as “a shock absorber” for intracranial pressure, which may prevent intracranial complications

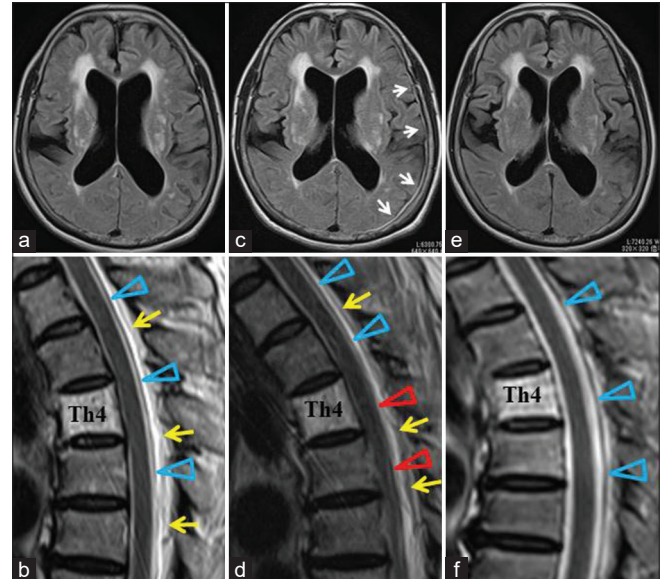




**Figure 1:** Preoperative magnetic resonance imaging (MRI) for a 71-year-old female with idiopathic normal pressure hydrocephalus. (a) Brain axial fluid-attenuated inversion recovery (FLAIR) image. (b) Brain coronal FLAIR image. (c) T2-weighted (T2-W) sagittal image at the thoracic level. (d) T2 fat-saturated sagittal image at the thoracic level. Brain MRIs showed enlarged lateral ventricles, unilateral dilatation of the right Sylvian fissure, and tight high-convexity sulci (a and b). T2-W sagittal imaging at the thoracic level showed normal positioning of the spinal cord and dura mater (arrowheads in [c]). Asterisks indicate epidural fat tissue (c and d). The Th4 vertebral body was involved by a hemangioma in this case.

during the early stage of overdrainage. Our representative case showed extreme DSSSs and further enlargement of the epidural venous plexus 2 weeks after the LPS. Subdural effusion began to appear at this moment. As we have already reported for cases with spontaneous IH treated with an epidural blood patch, the removal of the cause of the iatrogenic IH through tandem valve surgery in the representative case led to the rapid disappearance of these signs.<sup>[9]</sup>

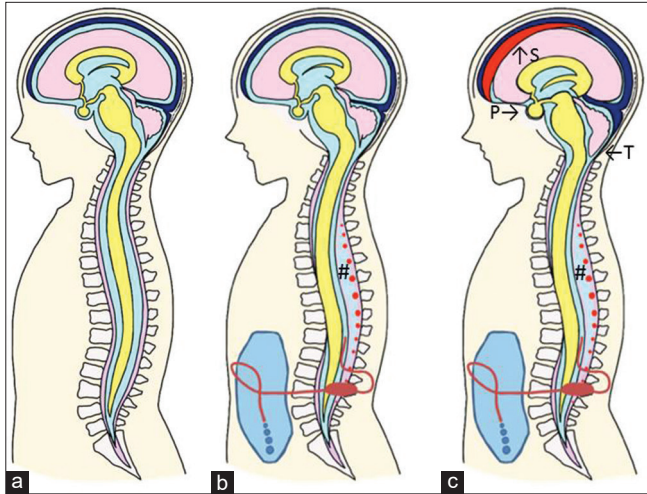
Finding the DSSSs and enlargement of the epidural venous plexus after LPS are particularly important in patients who have difficulty in speech communication due to aphasia or severe cognitive decline. The absence of complaints of



**Figure 2:** MRIs after lumboperitoneal shunt (LPS) in a 71-year-old female complaining of a severe orthostatic headache after surgery. Upper column (a, c, e): Brain axial fluid-attenuated inversion recovery images. Lower column (b, d, f): T2-W sagittal images at the thoracic level. 3 days after LPS, brain MRI (a) showed no signs of intracranial hypotension IH. Thoracic MRI (b) revealed DSSSs, which are the anterior shift of spinal cord and dura mater (arrowheads), and enlarged epidural venous plexus (arrows). Two weeks after LPS, thoracic MRI (d) showed aggravation of the DSSSs. The spinal cord appeared to touch the vertebral body, and the dura mater (arrowheads) became inseparable from the spinal cord at the Th4-Th7 levels (red arrowheads). The epidural venous plexus was now engorged (arrows). Brain MRI (c) revealed a thin subdural effusion in the left convexity (white arrows). Six days after the tandem valve surgery, brain MRI showed the disappearance of subdural effusion (e). Spinal MRI (f) showed a normally positioned spinal cord and dura mater (arrowheads).

orthostatic headache in these patients underscores the value of DSSSs as objective indicators for the early detection of overdrainage.

The enlargement of the epidural venous plexus has been reported to occur in patients with overdrainage after the ventriculoperitoneal (VP) shunt, not the LP shunt. In these reports, an enlarged epidural venous plexus mainly observed at the cervical level with compression of the spinal cord caused myelopathy and occasional radiculopathy. It was designated as overshunting-associated myelopathy (OSAM) syndrome.<sup>[15]</sup> The past cases of OSAM were generally accompanied by a slit ventricle and classic cranial signs of IH on brain MRI. The OSAM developed after long lapses following the VP shunt, with a mean of 12 years.<sup>[3,15,24,27]</sup> Thus, OSAM seems to be the ultimate stage of slowly progressing overdrainage. However, findings of dural sac shrinkage at the thoracic level were not mentioned in these reports. Meticulous observation of thoracic MRI scans in patients with OSAM may reveal



**Figure 3:** Illustrative mechanism underlying the DSSSs and classic intracranial signs of IH after LPS. (a) Preoperative condition. (b) For the cases with overdrainage, the DSSSs, which are the anterior shift of the spinal cord and dura mater due to severe reduction of cerebrospinal fluid in the dural sac, develop. And the epidural venous plexus (red dots) is enlarged in low-pressure epidural space (#). Intracranial signs of IH are not seen at this stage. (c) When the overdrainage is prolonged, the classic intracranial signs of IH appear. S: Subdural effusion, P: Enlargement of the pituitary gland, and T: Herniation of cerebellar tonsil.

DSSSs, which have been present in some figures of the past reports.<sup>[24,27]</sup> The assessment of the differences in DSSSs and enlargement of the epidural venous plexus between the LP and VP shunts may be a future research project.

#### Limitation of this study

This is the first study to investigate thoracic MRI in patients who had LPS for INPH, which showed that DSSSs were good indicators of overdrainage. However, the study had several limitations. First, 44.4% of the preoperative thoracic MRI scans were performed after tap rest. The transient in IH caused by the tapping could be a factor for the relatively high frequency (15%) of the anterior shift of dura mater in this group. Second, due to the retrospective nature of the study, we were able to analyze the postoperative spinal MRI of 62.2% (28/45) of the total participants. However, the DSSSs were observed only in 1 patient (4%) from the 25 patients with short orthostatic, transient/nonorthostatic, or absent headache. Compared with these groups, the DSSSs in patients with prolonged orthostatic headache were significantly frequent, 100% (3/3). The difference should be confirmed with a prospective study necessitating routine pretapping and postoperative thoracic MRIs for all study participants.

Third, only three patients complained of prolonged orthostatic headache in this series. The use of the pressure programmable valve set at the highest opening pressure,

40 cm H<sub>2</sub>O or more, which is equipped with an anti-siphon device in our center led to the scarcity of severe overdrainage symptoms. A multi-institutional study involving a larger sample of patients with prolonged overdrainage symptoms is needed to validate our discovery.

Fourth, we assumed entangled fascicular objects behind the dura mater, low intensity on T2-W thoracic MRI, and to be flow-void of enlarged epidural venous plexus in this and the previous study.<sup>[9]</sup> They are believed to be prominent for compensation of the shrinkage of the dural sac. The future studies should be performed to confirm our assumption using enhanced MR studies or susceptibility-weighted imaging.<sup>[5,8]</sup>

Fifth, investigating the possible cause of the difference in the emergence of IH after the same procedure for LPS seems beyond the aim of this study. However, finding the factor causing the difference may confer the better management of patients after LPS surgery. At present, we are investigating the body habitus and size of spinal canal and intervertebral foramen in patients who underwent the LPS. We hope that we can reveal the possible anatomical background which leads to IH in the near future.

#### CONCLUSION

Based on a previous report that DSSSs and the enlargement of the epidural venous plexus at the thoracic level were sensitive and specific signs of IH, we performed this retrospective survey on the significance of these signs among 45 patients who received an LPS in our NPH center. We found these signs as good indicators for the early detection of overdrainage or iatrogenic IH after receiving an LPS. A multicenter prospective study is required to validate our findings. A comparison of the signs associated with LP and VP shunts is also warranted.

#### Acknowledgment

The authors would like to thank Ms. Rina Kawahara for the comprehensive illustration [Figure 3], Haibunsha Kagoshima for performing a critical review of this manuscript, and Editage (www.editage.com) for English language editing.

#### Declaration of patient consent

The authors certify that they have obtained all appropriate patient consent.

#### Financial support and sponsorship

Nil.

#### Conflicts of interest

There are no conflicts of interest.



## REFERENCES

1. Aihara Y, Kawamata T, Mitsuyama T, Hori T, Okada Y. Novel method for controlling cerebrospinal fluid flow and intracranial pressure by use of a tandem shunt valve system. *Pediatr Neurosurg* 2010;46:12-8.
2. Aschoff A, Kremer P, Benesch C, Fruh K, Klank A, Kunze S. Overdrainage and shunt technology. A critical comparison of programmable, hydrostatic and variable-resistance valves and flow-reducing devices. *Childs Nerv Syst* 1995;11:193-202.
3. Caruso R, Wierzbicki V, Marrocco L, Pesce A, Piccione E. A poorly known cerebrospinal fluid shunt complication: Miyazaki syndrome. *World Neurosurg* 2015;84:834-8.
4. Dobrocky T, Grunder L, Breiding PS, Branca M, Limacher A, Mosimann PJ, *et al.* Assessing spinal cerebrospinal fluid leaks in spontaneous intracranial hypotension with a scoring system based on brain magnetic resonance imaging findings. *JAMA Neurol* 2019;76:580-7.
5. Haacke EM, Xu Y, Cheng YC, Reichenbach JR. Susceptibility weighted imaging (SWI). *Magn Reson Med* 2004;52:612-8.
6. Hashimoto M, Ishikawa M, Mori E, Kuwana N, Study of INPH on neurological improvement (SINPHONI). Diagnosis of idiopathic normal pressure hydrocephalus is supported by MRI-based scheme: A prospective cohort study. *Cerebrospinal Fluid Res* 2010;7:18.
7. Headache Classification Committee of the International Headache Society (IHS). The international classification of headache disorders. 3<sup>rd</sup> edition. *Cephalalgia* 2018;38:1-211.
8. Ishizaka K, Kudo K, Fujima N, Zaitu Y, Yazu R, Tha KK, *et al.* Detection of normal spinal veins by using susceptibility-weighted imaging. *J Magn Reson Imaging* 2010;31:32-8.
9. Kawahara T, Arita K, Fujio S, Hanaya R, Atsuchi M, Moinuddin FM, *et al.* Dural sac shrinkage signs on magnetic resonance imaging at the thoracic level in spontaneous intracranial hypotension its clinical significance. *Acta Neurochir* 2021;163:2685-94.
10. Kawahara T, Tokimura H, Higa N, Hirano H, Bohara M, Hanaya R, *et al.* Surgical technique for preventing subcutaneous migration of distal lumboperitoneal shunt catheters. *Innov Neurosurg* 2013;1:169-72.
11. Kazui H, Miyajima M, Mori E, Ishikawa M, SINPHONI-2 investigators. Lumboperitoneal shunt surgery for idiopathic normal pressure hydrocephalus (SINPHONI-2): An open-label randomised trial. *Lancet Neurol* 2015;14:585-94.
12. Kuwana N, Kuwabara T, Nakajima F, Hosoda H, Yamaguchi K. Simplified technique of lumbar subarachnoid-peritoneal shunt. *No Shinkei Geka* 1977;5:229-34.
13. Miyajima M, Kazui H, Mori E, Ishikawa M, On Behalf of the SINPHONI-2 Investigators. One-year outcome in patients with idiopathic normal-pressure hydrocephalus: Comparison of lumboperitoneal shunt to ventriculoperitoneal shunt. *J Neurosurg* 2016;125:1483-92.
14. Miyake H. Shunt devices for the treatment of adult hydrocephalus: Recent progress and characteristics. *Neurol Med Chir* 2016;56:274-83.
15. Miyazaki T, Chiba A, Nishina H, Uesaka Y, Nakase H, Kanazawa I. Upper cervical myelopathy associated with low CSF pressure: A complication of ventriculoperitoneal shunt. *Neurology* 1998;50:1864-6.
16. Mokri B. Spontaneous low pressure, low CSF volume headaches: Spontaneous CSF leaks. *Headache* 2013;53:1034-53.
17. Mokri B. The Monro-Kellie hypothesis: Applications in CSF volume depletion. *Neurology* 2001;56:1746-8.
18. Mori E, Ishikawa M, Kato T, Kazui H, Miyake H, Japanese society of normal pressure hydrocephalus, *et al.* Guidelines for management of idiopathic normal pressure hydrocephalus: Second edition. *Neurol Med Chir* 2012;52:775-809.
19. Nakajima M, Miyajima M, Akiba C, Ogino I, Kawamura K, Sugano H, *et al.* Lumboperitoneal shunts for the treatment of idiopathic normal pressure hydrocephalus: A comparison of small-lumen abdominal catheters to gravitational add-on valves in a single center. *Oper Neurosurg* 2018;15:634-42.
20. Nakajima M, Miyajima M, Ogino I, Akiba C, Kawamura K, Kurosawa M, *et al.* Shunt intervention for possible idiopathic normal pressure hydrocephalus improves patient outcomes: A nationwide hospital-based survey in Japan. *Front Neurol* 2018;9:421.
21. Podsiadlo D, Richardson S. The timed "Up and Go": A test of basic functional mobility for frail elderly persons. *J Am Geriatr Soc* 1991;39:142-8.
22. Schievink WI, Maya MM, Louy C, Moser FG, Tourje J. Diagnostic criteria for spontaneous spinal CSF leaks and intracranial hypotension. *AJNR Am J Neurorad* 2008;29:853-6.
23. Tardieu GG, Fisahn C, Loukas M, Moisi M, Chapman J, Oskouian RJ, *et al.* The epidural ligaments (of Hofmann): A comprehensive review of the literature. *Cureus* 2016;8:779.
24. Várallyay P, Nagy Z, Szűcs A, Czegléczki G, Markia B, Nagy G, *et al.* Miyazaki syndrome: cervical myelo/radiculopathy caused by overshunting: A systematic review. *Clin Neurol Neurosurg* 2019;186:105531.
25. Wang VY, Barbaro NM, Lawton MT, Pitts L, Kunwar S, Parsa AT, *et al.* Complications of lumboperitoneal shunts. *Neurosurgery* 2007;60:1045-8.
26. Watt S, Agerlin N, Romner B. Initial experience with the Codman Certas adjustable valve in the management of patients with hydrocephalus. *Fluids Barriers CNS* 2012;9:21.
27. Wnuk E, Maj E, Dziedzic T, Podlecka PA. Spinal epidural venous plexus enlargement as a cause of neurologic symptoms: Vascular anatomy and MRI findings. *Neurol India* 2020;68:1238-41.

**How to cite this article:** Kawahara T, Atsuchi M, Arita K, Fujio S, Higa N, Moinuddin FM, *et al.* Dural sac shrinkage signs on spinal magnetic resonance imaging indicate overdrainage after lumboperitoneal shunt for idiopathic normal pressure hydrocephalus. *Surg Neurol Int* 2022;13:269.