


ORIGINAL ARTICLE

Balloon-occluded retrograde transvenous obliteration as a procedure to improve liver function in patients with decompensated cirrhosis

Manabu Nakazawa, Yukinori Imai, Hiroshi Uchiya, Satsuki Ando, Kayoko Sugawara, Nobuaki Nakayama, Tomoaki Tomiya and Satoshi Mochida 

Department of Gastroenterology and Hepatology, Faculty of Medicine, Saitama Medical University, Saitama, Japan

Key words

balloon-occluded retrograde transvenous obliteration, cirrhosis, gastric fundal varices, hepatic encephalopathy, portosystemic shunt.

Accepted for publication 3 October 2017.

Correspondence

Satoshi Mochida, MD, PhD, Department of Gastroenterology and Hepatology, Faculty of Medicine, Saitama Medical University, 38 Morohongo, Moroyama-cho, Iruma-gun, Saitama 350-0495, Japan.
Email: smochida@saitama-med.ac.jp

Declaration of conflict of interest: None

Abstract

Aim: Portosystemic shunts aggravate liver function by decreasing portal blood flow. The usefulness of balloon-occluded retrograde transvenous obliteration (B-RTO), a standardized therapeutic procedure for gastric fundal varices (GFV), for the improvement of liver function was evaluated in cirrhotic patients with or without varices.

Methods: The subjects were 161 patients with portosystemic shunts. A balloon catheter was inserted into the shunts, followed by the injection of 5% ethanolamine oleate through the catheter under balloon inflation. The balloon was kept inflated for 6 to 48 h.

Results: B-RTO was performed as a therapy for GFV in 112 patients and for the improvement of liver function in 49 patients. The targets were splenorenal shunts in 104 patients (93.6%) in the former group and 33 patients (67.3%) in the latter group, and the procedures were successfully completed in 109 (97.3%) and 39 (79.6%) patients, respectively. In both groups, the serum albumin levels were increased and the serum ammonia levels were decreased at more than 1 month after the procedures, compared with the baseline levels, whereas significant improvements in the Child–Pugh scores and prothrombin times were only seen in the latter group. In these patients, the portal blood flows evaluated using Doppler ultrasound were increased at 1 week after the procedures, compared with the baseline levels.

Conclusions: B-RTO is a useful therapeutic procedure for improving liver function even in patients without GFV by increasing the portal venous flow with successfully targeted, uncommon portosystemic shunts.

Introduction

In patients with cirrhosis, collateral pathways draining into the systemic circulation can develop in any part of the portal venous system. Portosystemic shunts are responsible for the occurrence of hepatic encephalopathy, since toxic intestinal substances, such as ammonia, mainly produced by bacterium in the intestinal flora, may arrive at the brain after escaping detoxification by urea cycle in the hepatocytes.¹ Such shunts also aggravate liver function by decreasing blood flow in the portal vein even in patients without overt hepatic encephalopathy.² Thus, therapeutic procedures to increase the portal blood flow are needed for patients with decompensated cirrhosis.

As a therapeutic procedure for portal hypertension, transjugular intrahepatic portosystemic shunt (TIPS) has been done in Western countries, especially for esophageal and gastric varices and intractable ascites.³ In Japan, however, balloon-occluded retrograde transvenous obliteration (B-RTO) is a standardized therapeutic procedure for gastric fundal varices (GFV) with splenorenal shunts.^{4–7} This procedure is less invasive than TIPS procedure,

can be applied even for varices with portosystemic shunts other than splenorenal shunts⁶ and has been shown to eradicate varices completely with minimal invasion. Previously, we reported that GFV did not recur in any of the patients who had received successful B-RTO procedures in a long-term follow-up study of 154 patients.⁷ As a secondary benefit of treatment for GFV, B-RTO procedures have been shown to improve liver function; serum ammonia levels decreased after B-RTO because of the increase in the portal blood flow after the occlusion of splenorenal shunts,^{8–12} whereas TIPS procedures aggravate hepatic encephalopathy through decreasing the portal blood flow. Considering this secondary merit, B-RTO has been applied for the treatment of recurrent hepatic encephalopathy in patients with GFV.^{8,9,13–15} Yamagami *et al.* investigated the hemodynamic changes in the portal venous circulation using splenic arteriography and arterial portography on computer tomography (CT) before and after the B-RTO procedures targeting splenorenal shunts, and they showed that the occlusion of the shunts produced a switch in the portal blood flow from hepatofugal to hepatopetal.¹⁰ These observations

prompted us to postulate that B-RTO procedures may be useful for the improvement of liver function in patients with decompensated cirrhosis and those requiring treatment for GFV. In this report, however, B-RTO procedures were performed only in nine patients as treatments for GFV, among whom only one patient with overt hepatic encephalopathy was included.

The usefulness of B-RTO, however, as a procedure for improving liver function has yet to be elucidated, since the procedure can increase the portal venous pressure leading to the aggravation of esophageal varices, ascites, hydrothorax, and portal hypertensive gastroenteropathy.^{16,17} Also, the effects of B-RTO in patients without GFV have not been clarified because of the difficulty in occluding portosystemic shunts other than splenorenal shunts. Thus, in the present study, B-RTO was performed using a microballoon catheter and a standard catheter in patients with decompensated cirrhosis, in whom prophylactic procedures for GFV were not required, and the usefulness of B-RTO for improving liver function was evaluated by a comparison with patients undergoing B-RTO for the treatment of GFV.

Patients and methods

Patients and therapeutic designs. The subjects were patients with cirrhosis manifesting the portosystemic shunts on contrast-enhanced CT examinations between January 2007 and August 2016 at the Saitama Medical University Hospital. In patients with F3 or F2/red color sign (RC)-positive GFV according to the classification of the Japan Society for Portal Hypertension,¹⁸ B-RTO procedures were done as therapies for the varices. In contrast, in patients without GFV and those with F1 or F2, but RC-negative varices, the procedures were performed to improve liver function and/or attenuate refractory hepatic encephalopathy. Patients with refractory ascites and/or serum bilirubin concentrations of 5.0 mg/dL or more were excluded from candidates for B-RTO procedures. In patients with complicated esophageal varices of F3 and/or RC positive at baseline on endoscopic examinations, endoscopic variceal ligation (EVL) and/or endoscopic injection sclerotherapy (EIS) was done 1 day after the B-RTO procedure. In patients seen later than May 2013, partial splenic embolization (PSE) was performed simultaneously with the B-RTO procedure or 7 days before the procedures, when sizes of the portosystemic shunts and/or spleen were huge on contrast-enhanced CT examinations.

Written informed consent for the B-RTO procedures was obtained from all the patients. The study results were analyzed retrospectively based on the clinical data obtained for each patient, and the study itself was approved by the Institutional Review Board of the Saitama Medical University Hospital.

B-RTO procedures. A 5-Fr or a 6-Fr balloon catheter (Selecon MP; Terumo Clinical Supply, Gifu, Japan) or a 3-Fr microballoon catheter (Attendant; Terumo Clinical Supply, Gifu, Japan) was inserted into the portosystemic shunts via the femoral, internal jugular or epigastric vein. Retrograde venography was performed through the catheter under balloon inflation. When the shunts could not be visualized because of the presence of alternative drainage vessels, the vessels were occluded with metallic coils (Vortex; Boston Scientific, Natick, MA, USA) via a 2.1-Fr microcatheter (Tangent; Boston Scientific, MA, USA)

selectively inserted into the drainage vessels, or a dual B-RTO procedure was performed using an additional microballoon catheter. Then, 5% ethanolamine oleate (Oldamin; Asuka Pharmaceutical Co. Ltd., Tokyo, Japan) was injected into the shunts. The balloons were kept inflated, and the catheters were removed between 6 and 48 h after the balloon occlusion. Human haptoglobin (Haptoglobin; Japan Blood Products Organization, Tokyo, Japan) at a dose of 4000 units was intravenously injected in all the patients immediately after the injection of the sclerosant. In patients with two types of portosystemic shunts, B-RTO procedures were performed twice at an interval of 7 days.

Evaluation of therapeutic efficacy. Blood flow and thrombus formation in the portosystemic shunts were assessed by contrast-enhanced CT (SOMATOM Definition Flash and SOMATOM Emotion 16, Siemens, Forchheim, Germany) between 3 and 7 days after the B-RTO procedures. When a complete thrombosis formation was confirmed in the shunt, the therapeutic efficacy was judged as being successful. In patients who underwent successful B-RTO procedures, liver function tests were compared between baseline and later than 1 month after the procedure. In addition, the blood flow volumes in the portal vein were measured at baseline and 7 days after the procedure in patients seen in October 2012 and thereafter. The flow volumes were calculated using the diameter and blood flow velocity of the right branch of the portal vein using ultrasound pulsed Doppler flowmetry (ProSound F75, $\alpha 7$; Hitachi Aloka Medical Ltd., Tokyo, Japan) with 1.8–5.7 MHz convex probe. The extents of the esophageal varices were examined every 6 to 12 months after the B-RTO procedures, and the varices were diagnosed as aggravated when variceal bleeding occurred or when prophylactic endoscopic therapies were performed.

Statistical analysis. The paired *t*-test and Fisher's exact test were performed to compare the demographic and clinical features of patients, including liver function parameters, observed after the B-RTO procedures with those at baseline. The Wilcoxon's signed-rank test was performed to compare portal blood flows after the B-RTO procedures with those at baseline. *P*-values of less than 0.05 were considered statistically significant.

Results

Demographic and clinical features of patients undergoing B-RTO procedures. A total of 161 patients underwent B-RTO procedures. Among them, the procedures were performed as treatment for GFV in 112 patients (69.6%) and as improvement of liver function in 49 patients (30.4%). The demographic and clinical features of 161 patients are shown in Table 1. Patient age, sex, and the percentages of patients with hepatocellular carcinoma (HCC) were equivalent between patients undergoing B-RTO for the treatment of GFV and those undergoing B-RTO for the improvement of a liver function. In both groups, hepatitis C virus (HCV) infection was the most frequent etiology for liver diseases, followed by alcohol intake; however, non-alcoholic steatohepatitis (NASH) or an indeterminate etiology was more frequent in the former group than in the latter group, while hepatitis B virus (HBV) infection was more frequent in the latter group than in the former group. Differences in baseline liver function were observed between both groups;

Table 1 Demographic and clinical features of patients with the portosystemic shunts undergoing balloon-occluded retrograde transvenous obliteration (B-RTO)

Purpose of B-RTO procedures		Therapy for gastric fundal varices		Improvement of liver function		P-values
		112		49		
Number of patients						
Age: years	Medium (range)	66	(39–86)	63	(39–81)	0.133
Sex	Men	65	58.0%	27	55.1%	0.729
	Women	47	42.0%	22	44.9%	
Refractory encephalopathy	Absent	112	100%	11	22.4%	<0.001
	Present	0	0%	38	77.6%	
Portosystemic shunts	Splenorenal	104	92.3%	33	67.4%	<0.001
	Inferior phrenic	8	7.2%	0	0%	
	Mesocaval	0	0%	5	10.2%	
	Epigastric	0	0%	7	14.3%	
	Azygos	0	0%	2	4.1%	
	Splenorenal/azygos	0	0%	2	4.1%	
Etiology (%)	HBV	1	0.9%	5	10.2%	0.908
	HCV	51	45.5%	23	46.9%	
	Alcohol intake	28	25.0%	14	28.6%	
	NASH/indeterminate	26	23.2%	4	8.2%	
	AIH	2	1.8%	0	0%	
	PBC	4	3.6%	3	6.1%	
Child–Pugh scores (%)	A	64	57.1%	1	2.0%	<0.001
	B	47	42.0%	31	63.2%	
	C	1	0.9%	17	34.7%	
Hepatocellular carcinoma (%)	Absent	80	71.4%	34	69.4%	0.793
	Present	32	28.6%	15	30.6%	
Esophageal varices† (%)	None	29	26.0%	11	22.4%	0.096
	Mild	54	48.2%	37	75.5%	
	Severe	29	26.0%	1	2.0%	
Partial splenic embolization (%)	Not done	111	99.1%	34	69.4%	<0.001
	Done	1	0.9%	15	30.6%	

AIH, autoimmune hepatitis; HBV, hepatitis B virus; HCC, hepatocellular carcinoma; HCV, hepatitis C virus; NASH, non-alcoholic steatohepatitis; PBC, primary biliary cholangitis; PSE, partial splenic embolization.

†The extent of esophageal varices manifesting both F1/F2 and RC0 was diagnosed as “mild,” while that of the varices with F3 or RC1/RC2/RC3 as “severe.”

Child–Pugh grade A liver damage was more frequent among those undergoing B-RTO for the treatment of GFV than among those undergoing the procedures for the improvement of liver function (57.1% vs 2.0%, respectively), while grade C liver damage was more frequent in the latter patients than in the former patients (0.9% vs 34.7%, respectively). Also, refractory hepatic encephalopathy was exclusively present in the latter patients (0% vs 77.6%, respectively).

Moreover, the portosystemic shunts observed using contrast-enhanced CT differed between the two groups (Table 1 and Fig. 1). The percentage of patients with a splenorenal shunt was higher among those undergoing a B-RTO procedure for the treatment of GFV (92.3%) than among those undergoing the procedure for the improvement of liver function (71.4%, including two patients with both splenorenal and azygos shunts). In patients in the former group, inferior phrenic vein shunts were seen as alternatives to splenorenal shunts. In the latter group, however, both mesocaval and epigastric shunts and azygos shunts were observed. The percentages of patients with esophageal varix complications were similar between the two groups (74.3% vs 77.6%, respectively), but patients with severe esophageal varices, for whom endoscopic therapies were required simultaneously with

the B-RTO procedure, were more frequent in the former group than in the latter group (25.7% vs 2.0%, respectively).

Therapeutic efficacies of B-RTO procedures. B-RTO procedures were performed for 112 portosystemic shunts in 112 patients undergoing the procedures for the treatment of GFV and for 51 shunts in 49 patients undergoing the procedures to improve liver function. PSE was simultaneously performed in 15 patients (30.6%) in the latter group; the percentage was significantly higher than that in the former group (0.9%) (Table 1). As shown in Figure 1, B-RTO procedures were performed successfully for 109 shunts (97.3%) among the former patients and for 41 (80.4%) shunts among 39 patients (79.6%) in the latter group ($P < 0.001$). Among the latter patients, the success rates depending on the types of portosystemic shunts were 80.0% for splenorenal shunts, 75.0% for azygos shunts, 100% for mesocaval shunts, and 71.4% for epigastric shunts.

The liver function parameters were compared between those at baseline and those at 1 month or later after the B-RTO procedures in 109 and 39 patients undergoing successful B-RTO procedures for the treatment of GFV and for the improvement of liver function, respectively. As shown in Figure 2a, in patients

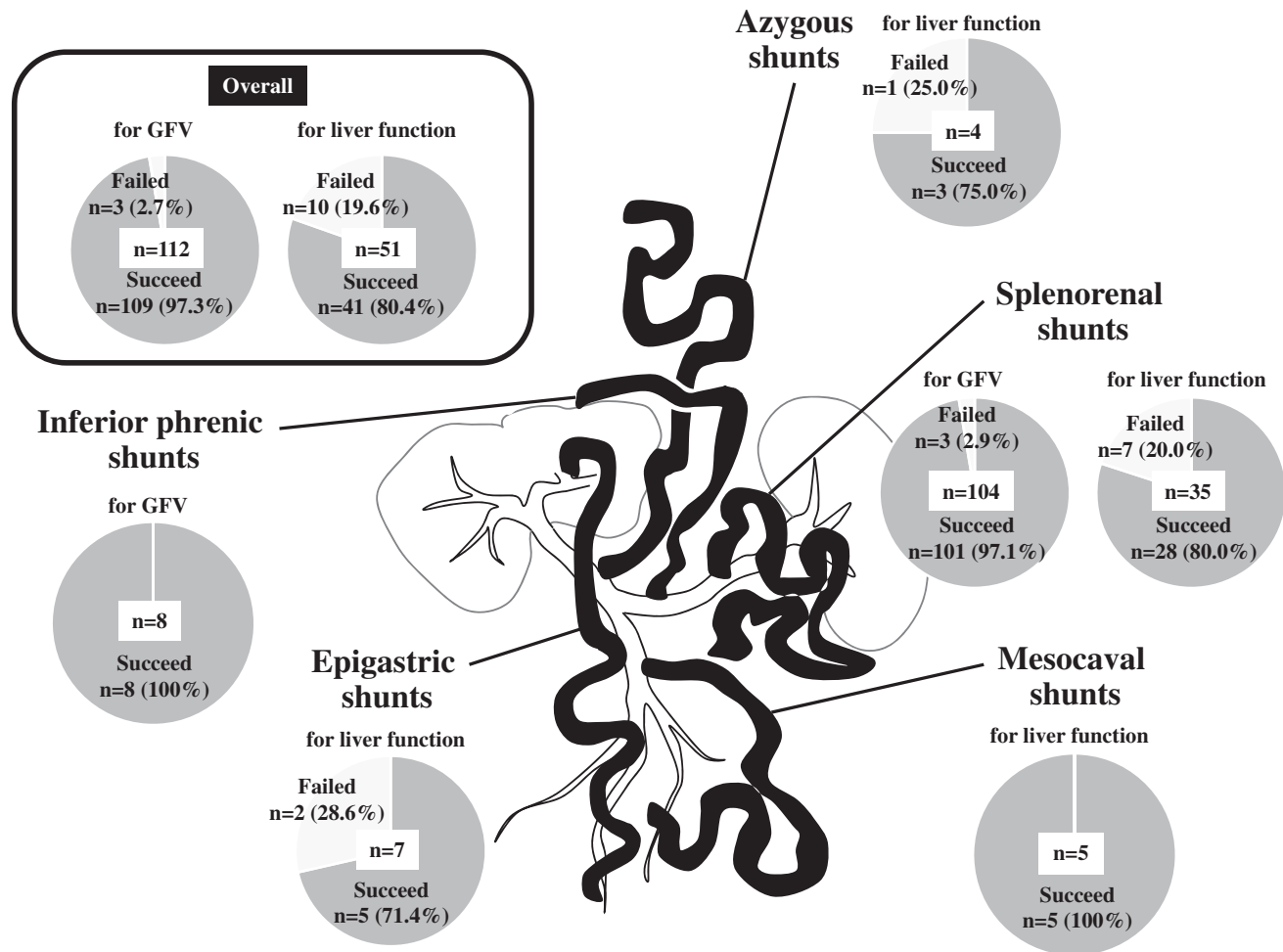


Figure 1 Success Rates of Balloon-Occluded Retrograde Transvenous Obliteration (B-RTO) Depending on the Types of Portosystemic Shunts. B-RTO procedures were performed for 112 shunts in 112 patients receiving the procedures as therapy for gastric fundal varices (GFV) and for 51 shunts in 49 patients receiving the procedures to improve liver function.

undergoing the procedures for the treatment of GFV, the serum ammonia levels were decreased ($\mu\text{g/dL}$; mean \pm SD, from 69.9 ± 38.8 to 57.8 ± 33.7 ; $P < 0.05$), while the serum albumin levels were increased (g/dL ; from 3.3 ± 0.5 to 3.5 ± 0.5 ; $P < 0.001$) after the B-RTO procedures compared to the baseline levels, while significant changes were not seen in the prothrombin time (%; from 73.2 ± 11.1 to 75.0 ± 13.5) and the serum total bilirubin levels (mg/dL : from 1.1 ± 0.7 to 1.2 ± 0.8). In contrast, in patients undergoing the procedures to improve liver function (Fig. 2b), the serum ammonia levels were decreased (from 158.2 ± 63.0 to 59.9 ± 30.9 ; $P < 0.001$), while both the serum albumin levels and the prothrombin times were increased (from 2.9 ± 0.4 to 3.4 ± 0.4 ; $P < 0.001$ and from 67.0 ± 13.5 to 74.1 ± 15.0 ; $P < 0.005$, respectively) after the procedures, compared with those at baseline, but the serum total bilirubin levels did not change (from 1.5 ± 0.8 to 1.4 ± 1.1). Consequently, the Child–Pugh scores were decreased from 8.6 ± 1.3 to 6.6 ± 1.3 ($P < 0.001$) after the B-RTO procedures in the latter patients, while they remained unchanged in the former patients (from 6.4 ± 1.1 to 6.2 ± 1.5).

Blood flow in the portal vein was examined in 14 patients undergoing successful B-RTO procedures for the improvement of liver function (Fig. 3). The flows had increased significantly at 1 week after the procedures, compared with those at baseline (cm^3/s ; from 5.3 ± 10.2 to 19.9 ± 10.0 ; $P < 0.005$) (Fig. 4).

In patients undergoing B-RTO for the improvement of liver function, esophageal varices became aggravated in three patients (6.1%) within 6 months of the procedures, but these varices were successfully treated endoscopically. Thrombosis of the portal vein developed in seven patients (17.9%) after the procedures. Intractable ascites did not occur in any of the patients within 6 months of the procedures.

Discussion

In the present study, B-RTO procedures were performed in cirrhotic patients with portosystemic shunts, and the efficacies were compared between those with and those without GFV requiring therapy, with the procedures being done to improve liver function in the latter patients. The clinical features of the two patient

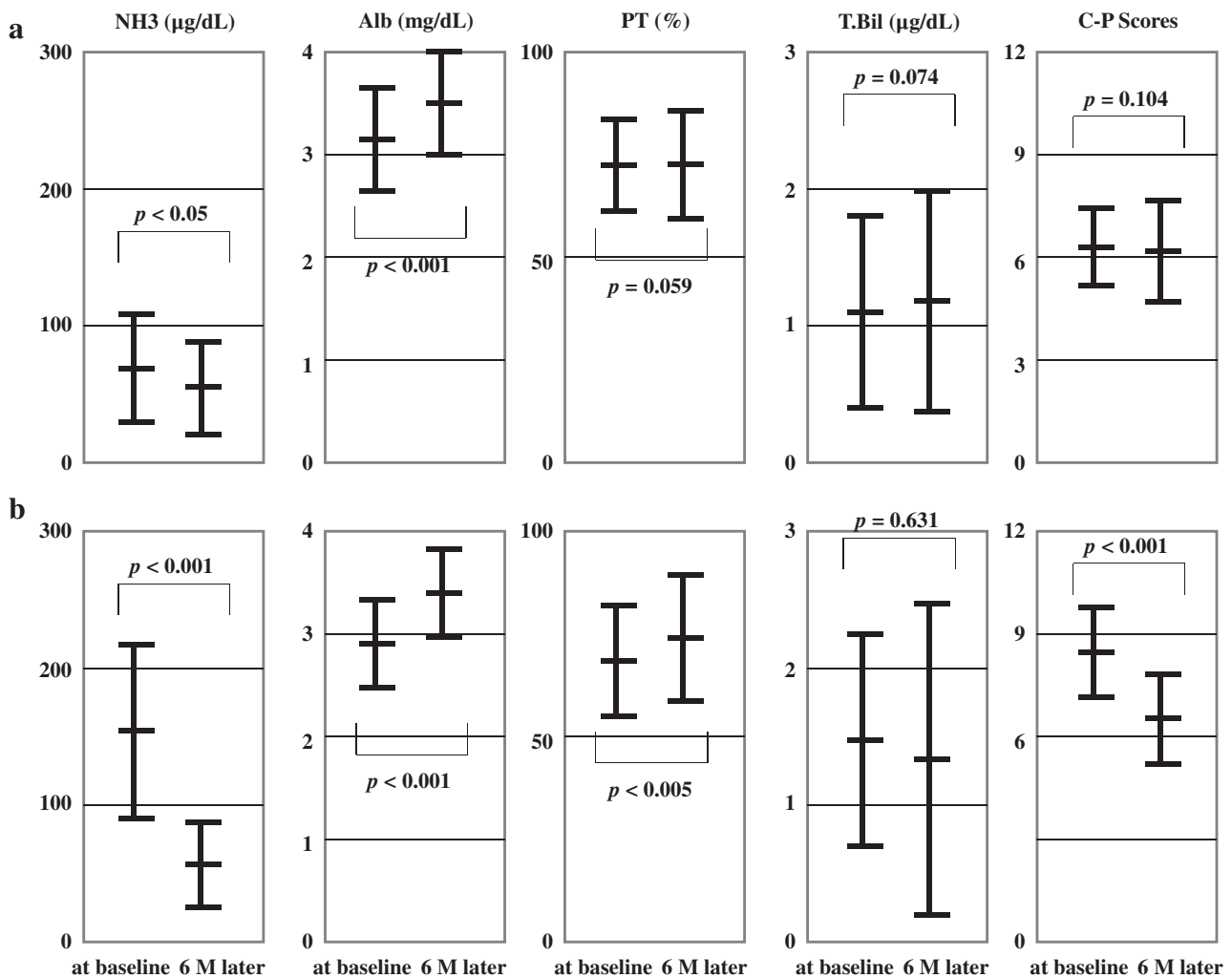


Figure 2 Liver Functions at Baseline of Balloon-Occluded Retrograde Obliteration (B-RTO) and Those at 1 Month or Later After the Procedures. a) Liver functions in 109 patients receiving successful B-RTO procedures for the treatment of gastric fundal varices. The serum levels of ammonia (NH₃; mg/dL; $n = 68$) were decreased ($P < 0.05$), while those of albumin (Alb; g/dL; $n = 100$) were increased ($P < 0.001$), but a significant improvement was not seen in the prothrombin time (PT; %; $n = 93$), the serum levels of total bilirubin (T.Bil; mg/dL; $n = 100$) or the Child-Pugh scores (C-P; total score; $n = 93$). b) Liver functions in 39 patients receiving successful B-RTO procedures to improve liver function. The serum NH₃ levels ($n = 33$) and the C-P scores ($n = 33$) were decreased ($p < 0.001$), while the serum Alb levels ($n = 35$) and PT ($n = 33$) were increased ($p < 0.001$ and $p < 0.005$, respectively); the serum T.Bil levels ($n = 35$) remained unchanged.

groups differed, with patients whose conditions were caused by NASH or an indeterminate etiology being more frequent in the former group than in the latter group, whereas the percentages of patients with decompensated cirrhosis with or without refractory hepatic encephalopathy were higher in the latter group than in the former group. Moreover, of note, the types of portosystemic shunts differed between both patient groups: shunts other than splenorenal shunts, such as azygos, mesocaval, and epigastric shunts, were more frequent in patients undergoing B-RTO procedures to improve liver function than in those undergoing the procedures for the treatment of GFV, while the opposite trend was observed for patients with severe-grade esophageal varices. Differences in the hemodynamics of the portosystemic shunts contributed to the gap in the success rates for the B-RTO procedures between both patient groups, with a success rate of 97.3%

observed for patients undergoing B-RTO procedures for the treatment of GFV and 79.6% for those undergoing the procedures to improve liver function. Also, PSE was performed more frequently in the latter patients than in the former patients.

Miyamoto *et al.* evaluated hepatic blood flow and liver function in patients with GFV using the continuous indocyanine green (ICG) infusion method and showed that B-RTO procedures increased the blood flow volume, leading to an improvement in hepatic metabolic activities, such as serum albumin and ammonia levels, prothrombin times, ICG extraction ratio at 15 min, and the Child-Pugh scores evaluated 4 weeks after the procedures.⁹ Also, Kumamoto *et al.* compared liver function and the long-term prognosis among three groups: cirrhotic patients with and without splenorenal shunts and those undergoing B-RTO procedures for the treatment of splenorenal shunts.¹² They concluded

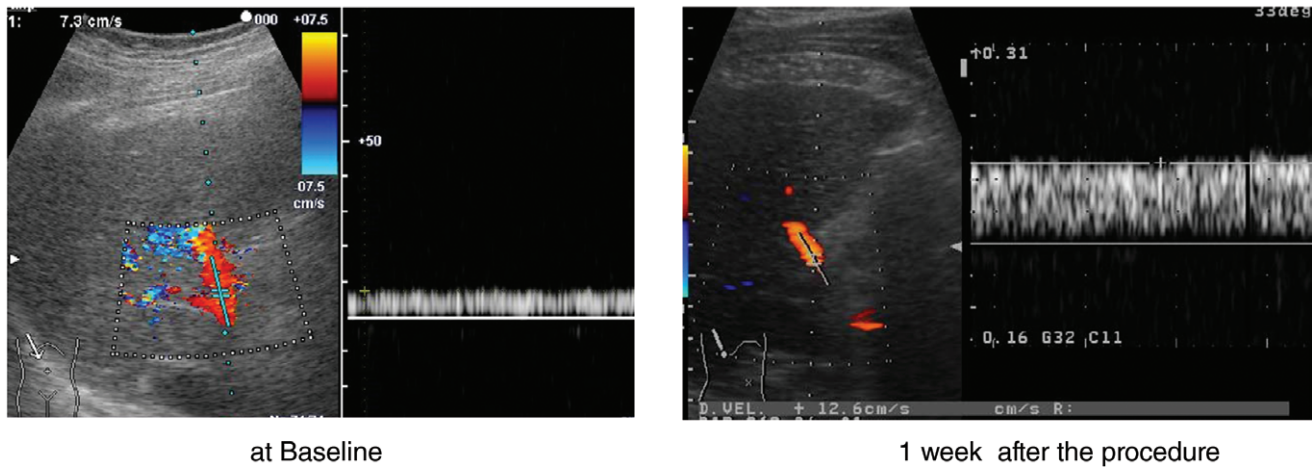


Figure 3 *Ultrasound Pulsed Doppler Findings at Baseline and 1 Week after Balloon-Occluded Retrograde Transvenous Obliteration (B-RTO).* a) The velocity of portal venous flow at baseline was 7.3 cm/s, and the flow volume was calculated as 9.7 cm³/s (b) The velocity at 1 Week after B-RTO increased from 7.3 cm/s to 12.6 cm/s, and the flow volume was calculated as 16.7 cm³/s.

that the shunts were responsible for the derangement of liver function and vital outcome and that B-RTO procedures may improve the outcomes of patients with shunts.¹² Moreover, several reports supported the usefulness of B-RTO procedures in patients with refractory hepatic encephalopathy.^{8–10}

In previous studies, however, the usefulness of B-RTO as a treatment for GFV was only evaluated among small numbers of patients with splenorenal shunts exclusively. The present study is the

first large-scale report to clarify the therapeutic efficacies of B-RTO procedures and to include patients with decompensated cirrhosis without GFV. B-RTO procedures were shown to increase the portal blood flow at 1 week after the procedure, leading to an improvement in liver function at 1 month or later after the procedure. The extents of the attenuations in the deranged serum levels of ammonia and albumin were smaller in patients undergoing B-RTO procedures for the treatment of GFV than in those undergoing the procedures for the improvement of liver function. Moreover, improvements in the prothrombin times and the Child–Pugh scores were found exclusively in the latter patients. These results suggest that the use of B-RTO in cirrhotic patients without GFV for the improvement of liver function when portosystemic shunts are observed on contrast-enhanced CT examinations merits consideration.

The limitations of the present study were as follows. First, the study was performed retrospectively, and B-RTO procedures were performed only in patients manifesting the portosystemic shunt hemodynamics suitable for the procedures. We tried to enlarge the indications for the procedures using a micro-balloon catheter and a standard balloon catheter to target shunts other than splenorenal shunts. In general, hemodynamic states are complicated especially in patients with azygos and epigastric shunts, in whom multiple drainage vessels with tortuous structures through which a balloon catheter cannot be advanced may exist. The percentages of patients among those with decompensated cirrhosis, in whom effective B-RTO procedures can be done, should be determined to clarify the position of these procedures as a therapeutic strategy. Second, the long-term outcome of patients with decompensated cirrhosis undergoing B-RTO procedures to improve liver function must be elucidated in comparison with patients undergoing the procedures for the treatment of GFV.

In conclusion, B-RTO procedures were useful for the improvement of liver function even in cirrhotic patients without GFV by increasing the portal venous flows, though technical difficulties may exist in procedures targeting portosystemic shunts other than the splenorenal shunt.

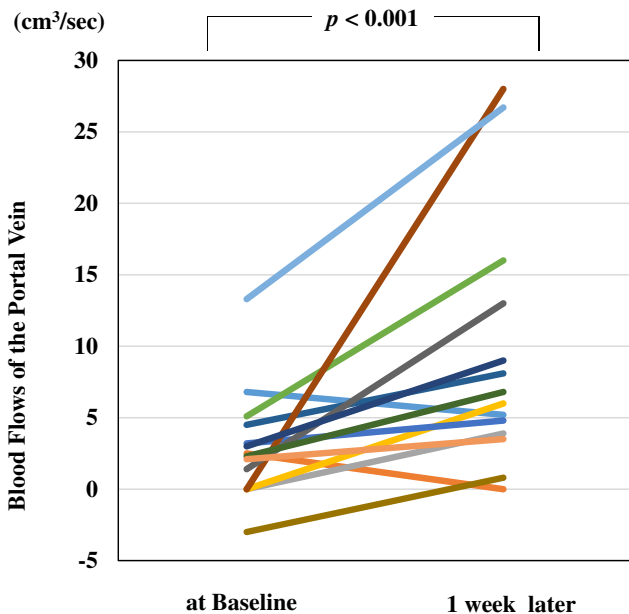


Figure 4 *Blood Flows in the Portal Vein at Baseline and Those at 1 Week after Balloon-Occluded Retrograde Transvenous Obliteration (B-RTO).* The portal venous flows were examined in 14 patients, and a significant increase after the procedures, compared with the baseline flows (cm³/sec; from 5.3 ± 10.2 to 19.9 ± 10.0, *P* < 0.001), was observed.

References

- 1 Sherlock S, Summerskill WHJ, White LP, Phear EA. Portal-systemic encephalopathy, neurological complications of liver disease. *Lancet*. 1954; **4**: 453–7.
- 2 Nakano R, Iwao T, Oho K, Toyonaga A, Tanikawa K. Splanchnic hemodynamic pattern and liver function in patients with cirrhosis and esophageal or gastric varices. *Am. J. Gastroenterol.* 1997; **92**: 2085–9.
- 3 Saad WEA, Darcy MD. Transjuglar intrahepatic portosystemic shunt (TIPS) versus balloon-occluded retrograde transvenous obliteration (BRTO) for the management of gastric varices. *Semin. Intervent. Radiol.* 2011; **28**: 339–49.
- 4 Kanagawa H, Mima S, Kouyama H, Gotoh K, Uchida T, Okuda K. Treatment of gastric fundal varices by balloon-occluded retrograde transvenous obliteration. *J. Gastroenterol. Hepatol.* 1996; **11**: 51–8.
- 5 Hirota S, Matsumoto S, Tomita M, Sako M, Kono M. Retrograde transvenous obliteration of gastric varices. *Radiology*. 1999; **211**: 349–56.
- 6 Imai Y, Nakazawa M, Ando S *et al.* Balloon-occluded retrograde transvenous obliteration using a microballoon catheter for intractable gastric fundal varices. *J. Gastroenterol. Hepatol.* 2014; **29**: 365–71.
- 7 Imai Y, Nakazawa M, Ando S, Sugawara K, Mochida S. Long-term outcome of 154 patients receiving balloon-occluded retrograde transvenous obliteration for gastric fundal varices. *J. Gastroenterol. Hepatol.* 2016; **31**: 1844–50.
- 8 Fukuda T, Hirota S, Sugimura K. Long-term results of balloon-occluded retrograde transvenous obliteration for the treatment of gastric varices and hepatic encephalopathy. *J. Vasc. Interv. Radiol.* 2001; **12**: 327–36.
- 9 Miyamoto Y, Oho K, Kumamoto M, Toyonaga A, Sata M. Balloon-occluded retrograde transvenous obliteration improves liver function in patients with cirrhosis and portal hypertension. *J. Gastroenterol. Hepatol.* 2003; **18**: 934–42.
- 10 Yamagami T, Kato T, Iida S, Tanaka O, Nishimura T. Change in the hemodynamics of the portal venous system after retrograde transvenous balloon occlusion of a gastrosplenic shunt. *Am. J. Roentgenol.* 2003; **181**: 1011–5.
- 11 Akahane T, Iwasaki T, Kobayashi N *et al.* Changes in liver function parameters after occlusion of gastrosplenic shunts with balloon-occluded retrograde transvenous obliteration. *Am. J. Gastroenterol.* 1997; **92**: 1026–30.
- 12 Kumamoto M, Toyonaga A, Inoue H *et al.* Long-term results of balloon-occluded retrograde transvenous obliteration for gastric fundal varices: Hepatic deterioration links to portosystemic shunt syndrome. *J. Gastroenterol. Hepatol.* 2010; **25**: 1129–35.
- 13 Sakurabayashi S, Sezai S, Yamamoto Y, Hirano M, Oka H. Embolization of portal-systemic shunts in cirrhotic patients with chronic recurrent hepatic encephalopathy. *Cardiovasc. Intervent. Radiol.* 1997; **20**: 120–4.
- 14 Kato T, Uematsu T, Nishigaki Y, Sugihara J, Tomita E, Moriwaki H. Therapeutic effect of balloon-occluded retrograde transvenous obliteration on portal-systemic encephalopathy in patients with liver cirrhosis. *Intern. Med.* 2001; **40**: 677–8.
- 15 Uehara H, Akahoshi T, Tomikawa M *et al.* Prediction of improved liver function after balloon-occluded retrograde transvenous obliteration: relation to hepatic vein pressure gradient. *J. Gastroenterol. Hepatol.* 2012; **27**: 137–41.
- 16 Cho SK, Shin SW, Yoo EY *et al.* The short-term effects of balloon-occluded retrograde transvenous obliteration, for treating gastric variceal bleeding, on portal hypertensive changes: a CT evaluation. *Korean J. Radiol.* 2007; **8**: 520–30.
- 17 Tanihata H, Minamiguchi H, Sato M *et al.* Changes in portal systemic pressure gradient after balloon-occluded retrograde transvenous obliteration of gastric varices and aggravation of esophageal varices. *Cardiovasc. Intervent. Radiol.* 2009; **32**: 1209–16.
- 18 Tajiri T, Yoshida H, Obara K *et al.* General rules for recording endoscopic findings of esophagogastric varices (2nd edition). *Dig. Endosc.* 2010; **22**: 1–9.