



# Acute management of complete bilateral ureteral transections aligned via stent through antegrade and retrograde approach

Abrar Mian<sup>a,\*</sup>, Kirk Redger<sup>b</sup>, Brian Flynn<sup>b</sup>

<sup>a</sup> Medical Student at Midwestern University, 555 31st St, Downers Grove, IL 60515, USA

<sup>b</sup> Urologist at University of Colorado Anschutz Medical Campus, 1635 Aurora Ct, Aurora, CO, 80045, USA

## ARTICLE INFO

### Keywords:

Ureteral transection  
Antegrade and retrograde approach  
Stent placement  
Endoscopic realignment

## ABSTRACT

To manage bilateral complete distal ureteral transections (CDUT) via stent placement achieved through a combination of antegrade and retrograde approaches. An antegrade wire was advanced through the nephrostomy tube. Flexible ureteroscopy was utilized via retrograde approach to identify the guidewire in the pelvis. The guidewire was grasped and withdrawn out the urethra, and bilateral stents were placed over guidewire. Patient continues to remain asymptomatic one year later, with symmetrical renal function and no evidence of obstruction. We demonstrate that a CDUT can be successfully realigned with a combined endourological approach, thereby avoiding open/laparoscopic ureteral repair.

## 1. Introduction

Ureteral injury is rare, most commonly occurring as a result of iatrogenic injury.<sup>1</sup> Iatrogenic injury occurs in the operating room during endoscopic, laparoscopic, open and vaginal surgery. Abdominal hysterectomy is the most common cause of severe ureteral injury, accounting for more than 50% of the injuries.<sup>2</sup> Most intra-operative ureteral transections go unrecognized and are discovered when the patient develops fever, nausea, abdominal and flank pain, azotemia, sepsis or fistula. Partial ureteral transection can usually be managed definitively with ureteral stenting or percutaneous nephrostomy. However, complete ureteral transection almost always requires percutaneous nephrostomy followed by delayed ureteral repair. We present a case of complete ureteral transections that were able to be successfully realigned via concomitant antegrade and retrograde stenting that healed without the need for further surgery.

## 2. Case presentation

A 41-year-old female underwent a hysterectomy with bilateral salpingectomy, complicated by complete bilateral ureteral transection. Postoperatively, the patient was anuric, and a CT abdomen/pelvis demonstrated extravasation of contrast into the pelvic cavity with no associated hydronephrosis, and no contrast in the bladder. Complete ureteral transection was confirmed both radiographically and

endoscopically. The proximal ureter's patency was confirmed via an antegrade nephrostogram demonstrating contrast extravasation directly into the pelvic space. Retrograde evaluation demonstrated patency of the distal ureters with contrast entry into the pelvic space, and no visualization of the proximal ureter. A flexible ureteroscope was also advanced retrograde over a guidewire into the pelvic space without any resistance. These findings were seen bilaterally, indicating bilateral complete ureteral transections with patent lumens.

Acute management consisted of bilateral percutaneous nephrostomy tube placement by interventional radiology. Three days later, the patient developed abdominal pain and fever; labs revealed a leukocytosis.

Repeat CT abdomen/pelvis demonstrated that the left nephrostomy tube was going through the descending colon; it was subsequently replaced. The patient decompensated that day, prompting an exploratory laparotomy, repair of colonic perforation, debridement, and drainage of pelvic abscess. Due to pelvic abscess, significant tissue edema, and sepsis, no attempt at ureteral repair occurred. Retrograde stent placement was attempted but was unsuccessful. On post-operative day #8, the patient's JP drain fluid creatinine was 10.04 mg/dL and serum creatinine was 0.56 mg/dL. The patient was discharged home with bilateral nephrostomy tubes and JP drain with plans for delayed ureteral repair. Despite having nephrostomy tubes in place, the patient had persistent urine leakage per vagina.

On post-operative day #14 the patient underwent ureteral realignment via a combined antegrade and retrograde approach (formal repair

\* Corresponding author.

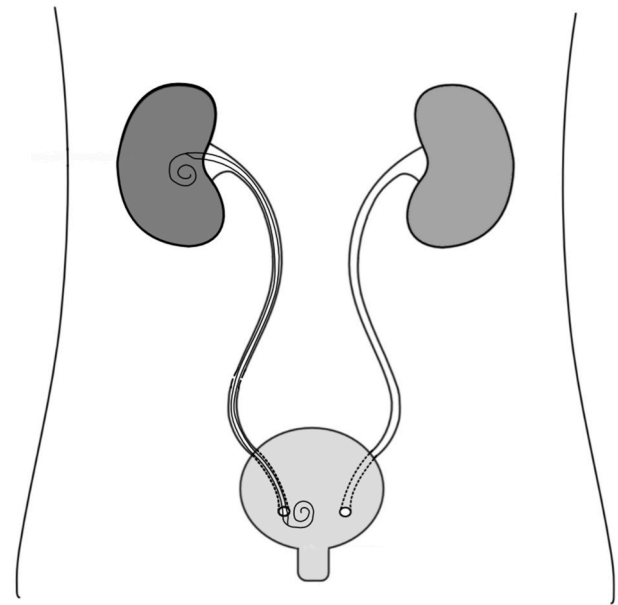
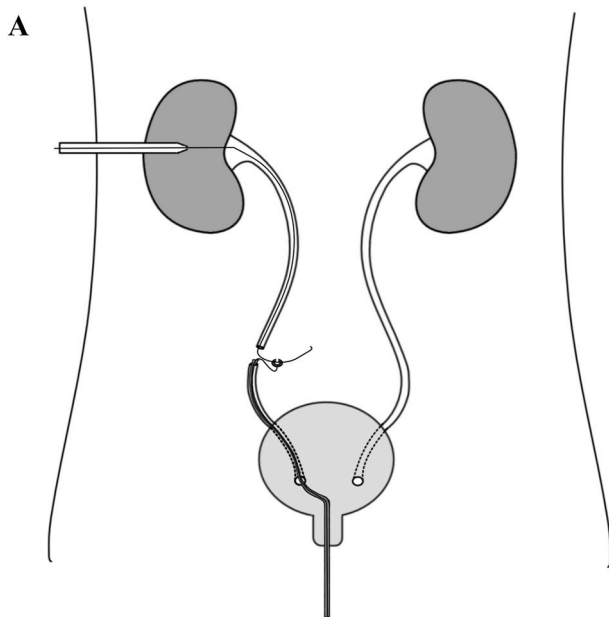
E-mail addresses: [abrar.mian@midwestern.edu](mailto:abrar.mian@midwestern.edu) (A. Mian), [KIRK.REDGER@cuanschutz.edu](mailto:KIRK.REDGER@cuanschutz.edu) (K. Redger), [BRIAN.FLYNN@cuanschutz.edu](mailto:BRIAN.FLYNN@cuanschutz.edu) (B. Flynn).

<https://doi.org/10.1016/j.eucr.2021.101816>

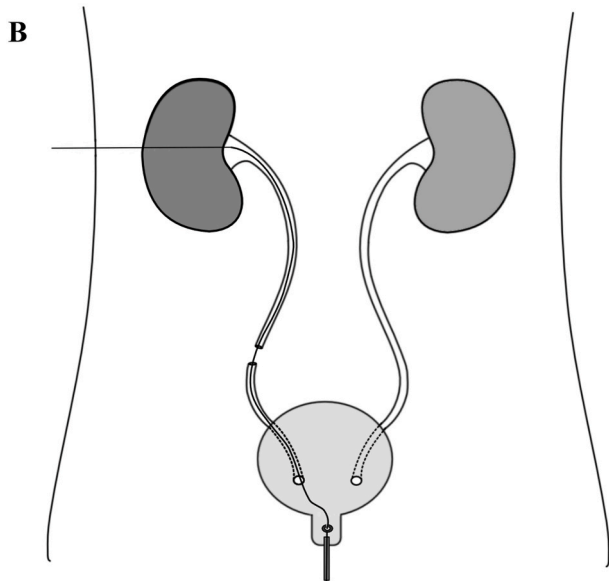
Received 5 August 2021; Received in revised form 18 August 2021; Accepted 20 August 2021

Available online 21 August 2021

2214-4420/© 2021 Published by Elsevier Inc. This is an open access article under the CC BY-NC-ND license (<http://creativecommons.org/licenses/by-nc-nd/4.0/>).



**Fig. 2.** A double J stent is placed to allow for ureteral healing.



**Fig. 1.** The antegrade guidewire is grasped with a flexible ureteroscope under fluoroscopic and direct visualization. The ureteroscope and guidewire are then pulled out from the urethra.

could not be conducted due to patient being septic). The patient was placed in supine position with the flank elevated about 20° to expose the nephrostomy tube. The nephrostomy tube and genitalia were prepped into the operative field, and an antegrade guide wire was placed via the nephrostomy tube into the pelvic space under fluoroscopic guidance. The nephrostomy tube was removed and the guidewire left in place. An access sheath was advanced over the antegrade guidewire into the renal pelvis. A second safety guidewire was placed via the access sheath into the renal pelvis. The access sheath was removed and safety guidewire was secured to the drapes. Next, a flexible cystoscope was advanced into the bladder and a retrograde guidewire was placed through the scope into the ureteral orifice and advanced into the pelvis under fluoroscopic visualization. The cystoscope was removed, with the guidewire remaining. A flexible ureteroscope was advanced over guidewire into the distal ureter. Utilizing direct and fluoroscopic visualization, the antegrade guidewire was located in the pelvic space. Once visualized,

the antegrade guidewire was retracted from the antegrade side until its end could be visualized in the pelvic space. The end of the wire was grasped with a grasper and the ureteroscope and guidewire were withdrawn from the urethra (Fig. 1). A double J stent was advanced over the guidewire via a retrograde approach into to the renal pelvis (Fig. 2) and deployed. A nephrostomy tube was placed in an antegrade fashion over the remaining safety guidewire into the renal pelvis. This procedure was performed bilaterally. Unfortunately, the intra-operative images could not be preserved due to equipment malfunction, so illustrations were used to demonstrate the pertinent steps.

Bilateral nephrostograms were performed 10 days later to address concerns for poor drainage from the left nephrostomy tube. The nephrostogram demonstrated appropriate tube position and contrast was visualized in the bladder, although bilateral extravasation into the vaginal cuff was present. At 6 weeks from the ureteral realignment, bilateral nephrostograms were repeated and demonstrated no further extravasation; per patient's request, the stents were left in place. The nephrostomy tubes were capped and the patient continued to remain asymptomatic. The stents were removed 4 months after the realignment and the nephrostomy tubes removed 1-week later after a normal antegrade study. Final outcome was successful as evident by a normal renal ultrasound and renal function (GFR 85 ml/min; Creatine 0.82 mg/dL). A nuclear renal scan was performed one year after realignment, demonstrating symmetrical renal function and no evidence of obstruction. The patient continues to be asymptomatic with no pain, fistula, or stricture.

### 3. Conclusion

Alignment of transected ureters over stents through an antegrade and retrograde approach is not a common treatment for complete ureteral transections in the acute setting, and there is scarce literature on this subject discussing its efficacy in this space. However, acute primary endoscopic/fluoroscopic urethral realignment following pelvic fracture urethral injury in men is widely accepted.<sup>3</sup> The "rendezvous procedure" has been well described for the delayed management of complete ureteral transections that develop ureteral stricture.<sup>4,5</sup> A study by Tsai et al. demonstrated successful treatment 7/10 strictures after ureteral transection 4 months post-alignment. Our case demonstrates using a similar technique to manage complete ureteral transections (with patent lumens) in the acute setting – prior to stricture formation.<sup>4</sup> Utilizing an

endourological approach to treat acute ureteral transections may spare patients from undergoing a delayed endourologic or open/laparoscopic ureteral repair for subsequent stricture formation. To prove the effectiveness of this treatment, more cases are required with longer follow up.

#### Declaration of competing interest

None.

#### References

1. Elliott SP, McAninch JW. Ureteral injuries: external and iatrogenic. *Urol Clin North Am.* 2006;33(1):55–66. vi.
2. Rock JA, Jones HW, Te Linde RW. *Telinde's Operative Gynecology*. Lippincott Williams & Wilkins; 2011 [Philadelphia?].
3. Elliott DS, Barrett DM. Long-term followup and evaluation of primary realignment of posterior urethral disruptions. *J Urol.* 1997;157(3):814–816.
4. Tsai CK, Taylor FC, Beagher MA. Endoscopic ureteroureterostomy: long-term followup using a new technique. *J Urol.* 2000;164(2):332–335.
5. Pastore AL, Palleschi G, Silvestri L, et al. Endoscopic rendezvous procedure for ureteral iatrogenic detachment: report of a case series with long-term outcomes. *J Endourol.* 2015;29(4):415–420.