

## A Case of Hemolytic Uremic Syndrome Associated with Epstein-Barr Virus Infection

Myong Ho Lee, M.D., Kyoon Seok Cho, M.D., Kyoung Won Kahng, M.D.,  
Chong Myung Kang, M.D.

*Department of Internal Medicine, College of Medicine,  
Hanyang University, Seoul, Korea*

*The precise etiology of hemolytic uremic syndrome (HUS) is unknown. However, it has been associated with bacterial (Shigella, Salmonella, E. coli, S. pneumoniae), Bartonella, and viral (coxsackie, ECHO, influenza, varicella, Epstein-Barr) infections and with endotoxemia. Recently, we experienced a case of HUS in a 16-year-old boy who was in the acute phase of an Epstein-Barr virus (EBV) infection. He had typical manifestations of HUS and EBV infection. He also transiently presented disseminated intravascular coagulation. His renal dysfunction recovered by supportive care, including hemodialysis, plasmapheresis, antihypertensive medication and aspirin. We present this case with a review of the literature as the second report of HUS associated with EBV infection.*

**Key Words :** Hemolytic Uremic Syndrome, Epstein-Barr Virus, Disseminated Intravascular Coagulation, Plasmapheresis

### INTRODUCTION

Hemolytic uremic syndrome (HUS) is a clinical state characterized by microangiopathic hemolytic anemia, thrombocytopenia and acute renal failure. The precise etiology of the disease is unknown. However, it has been associated with bacterial (*Shigella*, *Salmonella*, *E. coli*, *S. pneumoniae*), *Bartonella*, and viral (coxsackie, ECHO, influenza, varicella, Epstein-Barr) infections and with endotoxemia<sup>1)</sup>.

Recently we experienced a case of hemolytic uremic syndrome in a 16-year-old boy who was in the acute phase of Epstein-Barr virus (EBV) infection. He had typical manifestations of HUS, including pallor, malaise, edema, epistaxis, anuria, hematuria, azotemia and hypertension, as well as its prodrome such as bloody diarrhea, vomiting and mild fever. He also had manifestations of EBV infection including fever, skin rash, cervical

lymphadenopathy, splenomegaly and positive immunoglobulin M (IgM)-EBV antibody and EBV nuclear antigen (EBNA). He also presented disseminated intravascular coagulation (DIC) transiently. He recovered by supportive care, including hemodialysis, plasmapheresis, antihypertensive medication and aspirin. We present this case with a review of the literature.

### CASE REPORT

A 16-year-old boy had been in good health until June 21, 1996, when he finished a trip. On the next day, June 22, he developed bloody diarrhea with diffuse abdominal pain and was treated conservatively at a local clinic. A few days later, he developed oliguria, hematuria and acute renal failure with anemia and thrombocytopenia. He had a transfusion and underwent hemodialysis twice, and then was referred to our hospital on July 4, 1996.

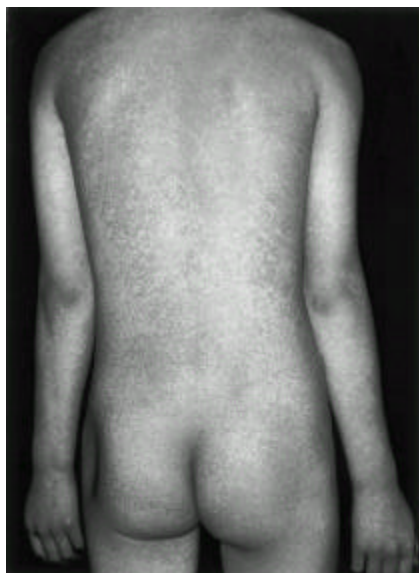The patient had no history of childhood illness and his family history revealed no specific illnesses.

On admission day, he had a mild fever, malaise, diffuse abdominal pain, chest discomfort, anuria, gross hematuria and epistaxis. On examination, the patient was

---

Address reprint requests to : Myong Ho Lee, Department of Internal Medicine, College of Medicine, Hanyang University, 17 Haengdang-dong, Seongdong-gu P.O. Box 93 Seoul 133-600, Korea

moderately developed and nourished. His vital signs were as follows: blood pressure, 180/110 mmHg; pulse rate, 80 beats per minute and regular; respirations, 20 per minute; temperature 37.2 °C. Jaundice was not present. He had a skin rash over his entire body (scarlatiniform and petechial) (Fig. 1, 2), periorbital edema, cervical lymphadenopathy and severe tenderness in the right costovertebral area.



**Fig. 1.** The scarlatiniform skin rash in the 16-year-old boy with hemolytic uremic syndrome associated with Epstein-Barr virus infection. This rash appeared a few days before admission and subsided on the 3rd day after admission.



**Fig. 2.** In the close-up of back, the petechial lesions were also observed. They also seem to be due to the Epstein-Barr virus infection.

The hemoglobin level was 81 g/L, the white blood cell count (WBC) was  $7.9 \times 10^9$  cells/L (polymorphoneutrophil 0.88, lymphocyte 0.06, monocyte 0.03) and the platelet count was  $40 \times 10^9$ /L. Other values were as follows: blood urea nitrogen (BUN), 21.1 mmol/L; serum creatinine, 1.001  $\mu$ mol/L; serum aspartate aminotransferase (AST), 1.01  $\mu$ kat/L; and serum alanine aminotransferase (ALT), 0.33  $\mu$ kat/L. The stool occult blood was positive. Urinalysis showed albumin 3+, 1 to 4 WBC and many RBC per high power field, and bile 2+. The reticulocyte was 0.051. The blood chemistry showed the following results: lactate dehydrogenase (LDH), 22.3  $\mu$ kat/L; serum total protein, 52 g/L; serum albumin, 33 g/L, calcium, 2.00 mmol/L, phosphorus, 2.19 mmol/L, total bilirubin, 11.9  $\mu$ mol/L; peripheral blood smear showed anisocytosis, polychromatosis and schizocytosis which suggested hemolytic anemia. At a local clinic, prothrombin time (PT) was 26.1 sec, activated partial thromboplastin time (aPTT) was 150 sec, fibrinogen was 2.3 g/L and fibrin degradation products (FDP) were positive. Upon admission to our hospital, PT was 13.7 sec (79%), aPTT was 29 sec, fibrinogen was 3.5 g/L, FDP was 80 mg/L and D-dimer test was positive. These findings suggested disseminated intravascular coagulation. An antistreptolysin titer was 54.2 Todd units. Antinuclear antibody was negative. C3 was 0.85 g/L. C4 was 0.27 g/L. Direct and indirect Coombs' tests were negative. Anti-platelet antibody was negative. Immunoglobulin G, A, and M were 6.11 g/L, 1.14 g/L, and 1.51 g/L, respectively. The blood culture and stool culture were negative. The cytomegalovirus (CMV) antibody, rubella antibody, HIV antibody, Hantaan virus antibody, leptospira antibody, and chikettsia antibody were all negative. The EBV-IgM antibody was positive. Eighteen days after this result, early antigen (EA)-IgG antibody was negative and Heterophil antibody had a low titer of 1:14, but the Epstein-Barr nuclear antigen (EBNA) and EBV-IgG antibody were positive.

On his chest X-ray, there was pleural effusion in the left side. On abdominal ultrasonography, the size of both kidneys was about 12 cm, the cortical echogenicity of the kidney was increased and there were splenomegaly and ascites. The electrocardiogram showed myocardial ischemia and there was a moderate degree of pericardial effusion on cardiac echocardiography.

On the second day in hospital, therapy with hemodialysis and antihypertensives had been commenced. On the 3rd day, his fever and skin rash subsided. On the 4th day, the hemoglobin level was 68

A CASE OF HEMOLYTIC UREMIC SYNDROME ASSOCIATED WITH  
EPSSTEIN-BARR VIRUS INFECTION

g/L, BUN was 24.2 mmol/L, serum creatinine was 1,238  $\mu$  mol/L, platelet count was  $50 \times 10^9$  /L, urine output was below 50 ml/day and aspirin (100 mg/day) therapy was started. From the 7th day, plasma exchange using 10 units of fresh frozen plasma was done five times on alternate days. On the 11th day, urine output was increased to more than 1,000 ml per day. On the 15th day, BUN, serum creatinine and LDH were decreased to 11.0 mmol/L, 406  $\mu$  mol/L, and 2.55  $\mu$  kat/L, respectively, and gross hematuria disappeared. On the 17th day, BUN was 6.8 mmol/L and serum creatinine was 226  $\mu$  mol/L. Plasma exchange and hemodialysis were stopped. Prior to the patient's discharge, on the 29th day, renal function had markedly improved; BUN was 6.0 mmol/L; serum creatinine was 122  $\mu$  mol/L; creatinine clearance, 0.86 mL/s; urine protein, 1.0 g/d; on urinalysis albumin (-), WBC 0 to 1, and RBC 5 to 9 per high power field. Other values had also improved; the hemoglobin level, 101 g/L; reticulocyte, 0.001; platelet count,  $190 \times 10^9$  /L; total bilirubin, 5.1  $\mu$  mol/L; AST, 0.31  $\mu$  kat/L; ALT, 0.17  $\mu$  kat/L; blood pressure was 140/90 mmHg (Fig. 3).

This patient recovered by hemodialysis, plasma-

pheresis, antihypertensive medication and aspirin, and was treated with an antiplatelet agent after discharge.

DISCUSSION

HUS associated EBV was first reported in 1974<sup>3</sup>. Since then, it has been known that EBV can develop into thrombocytopenia with HUS during the convalescent phase as an unusual manifestation<sup>3</sup>.

In this case, the patient had typical manifestations of hemolytic uremic syndrome, including pallor, malaise, edema, epistaxis, anuria, gross hematuria, proteinuria, azotemia and hypertension, as well as its prodrome such as bloody diarrhea, vomiting and mild fever. He showed the following signs: (1) microangiopathic hemolytic anemia (anemia, schizocyte in peripheral blood smear, and increased reticulocyte count and LDH), (2) renal involvement (increased BUN and creatinine, hematuria, proteinuria, waxy cast in follow-up urinalysis, anuria for 12 days) and (3) thrombocytopenia.

Autoimmune hemolytic anemia in infectious mononucleosis occurs rarely and it usually shows a positive

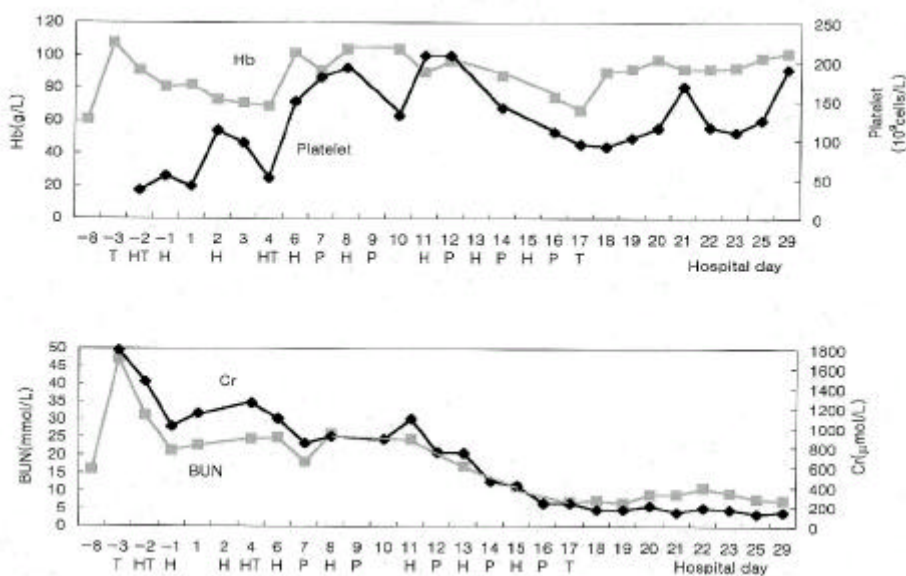


Fig. 3. The serum hemoglobin level, platelet count, blood urea nitrogen and creatinine before and after admission. Transfusion was done as follows: 4 units of packed RBCs 3 days before admission, 10 units of platelet concentrates and 2 units of fresh frozen plasma 2 days before admission and 2 units of packed RBCs on the 4th and on the 17th day after admission. H: hemodialysis; P: plasmapheresis using 10 units of fresh frozen plasma; T: transfusion; Hb: hemoglobin; BUN: blood urea nitrogen; Cr: creatinine.

Coombs' test<sup>3</sup>). In this case, the Coombs' test was negative, so it was concluded that hemolytic anemia in this case was not due to infectious mononucleosis but a manifestation of HUS.

In infectious mononucleosis, mild thrombocytopenia is frequently found, but more marked thrombocytopenia with peripheral destruction occurs occasionally, and antiplatelet antibodies have been found in some of the cases<sup>3</sup>). In this case, antiplatelet antibody was negative and thrombocytopenia was moderate, so it was also considered that thrombocytopenia was not due to infectious mononucleosis itself but due to HUS associated with EBV. The decreased IgG levels and elevated IgA and IgM levels have been shown during the acute phase of HUS<sup>4</sup>) and, in this case, a decreased IgG level was present.

Disseminated intravascular coagulation (DIC) occurs often in HUS. In one report, DIC was observed in 3 out of 22 cases of HUS with acute renal failure<sup>5</sup>). In another report, out of 14 children with HUS that followed acute dysentery, DIC was found in 12 cases. Therefore, it was suggested that DIC may have a role in the pathogenesis of HUS associated with acute dysentery<sup>6</sup>). However, Bukowski reported that less than 10 percent of cases reviewed retrospectively had fibrinogen levels depressed under 1.5g/L<sup>7</sup>). In our case, the patient had DIC transiently, but the fibrinogen level was 2.3 g/L.

Infectious mononucleosis is an acute viral infection usually characterized by fever, sore throat, lymphadenopathy, splenic enlargement and abnormal lymphocytes in the peripheral blood<sup>3</sup>). In our case, there was no lymphocytosis and the test of heterophil antibody was negative. However, fever, cervical lymphadenopathy, splenomegaly, periorbital edema, skin rash, mild elevated transaminase, IgM-EBV antibody and EBNA were present, representing the acute phase of infectious mononucleosis in this case. There was a difference in the time of the development of HUS, as compared with the case reported in 1974 in which HUS had developed in the convalescent phase of infectious mononucleosis<sup>2</sup>). In 5 percent of patients, a macular, petechial, scarlatiniform, urticarial or erythema multiforme-like rash may appear<sup>3</sup>). In this case, a petechial and scarlatiniform skin rash appeared. The elevation of transaminase appears in 20 to 40 percent of patients, and clinical jaundice is present in 5 percent of patients with infectious mononucleosis<sup>3</sup>). In this case, jaundice did not appear. The transient abnormalities of electrocardiography and cardiac echocardi-

graphy in this patient (myocardial ischemia and a moderate degree of pericardial effusion) were considered as complications of infectious mononucleosis<sup>8</sup>). The renal involvement of infectious mononucleosis may appear as hematuria, proteinuria, nephritis, hemoglobinuria or nephrotic syndrome<sup>2</sup>). But renal failure is very rare in infectious mononucleosis. In one report, renal failure appeared in 1.6 percent of infectious mononucleosis and generally occurred as interstitial nephritis, histologically<sup>9</sup>). The mechanism of renal involvement is probably multifactorial and includes both a direct viral cytopathic effect and other factors including hemolysis, hyperuricemia, and nephrotoxic drugs<sup>9</sup>). In some reports, infectious mononucleosis associated with renal failure and rhabdomyolysis was reported<sup>10, 11</sup>). However, to our knowledge, infectious mononucleosis associated with renal failure and HUS has not been reported since 1974.

Although we do not know the pathogenesis of HUS in EBV infection, it is not possible to exclude a coexisting viral infection as the cause for the HUS because the stool culture for *E. coli*, *Shigella* etc. was negative. Thus, we present this case with a review of the literature as the second report of HUS associated with EBV infection and suggest that EBV can be associated with HUS in the acute phase.

## REFERENCES

1. Behrman RE, Kliegman RM, Nelson WE, Vaughan III VC. *Hemolytic-uremic syndrome*. In: *Nelson Textbook of Pediatrics*. 4th ed. Philadelphia : WB Saunders, 1992; 1335-1336.
2. Shashaty GS, Atamer MA. *Hemolytic uremic syndrome associated with infectious mononucleosis*. *Am J Dis Child* 1974; 127:720-722.
3. Shurin SB. *Symposium on Unusual Infections: Infectious Mononucleosis*. *Pediatr Clin North Am* 1979; 26:315-326.
4. Bymes JJ, Moake JL. *Thrombotic thrombocytopenic purpura and the hemolytic uremic syndrome: Evolving concepts of pathogenesis and therapy*. *Clin Hematol* 1986; 15:413-442.
5. Dayal R, Agarwal S, Prasad R, Mathur PP, Agarwal A, Anand A. *A clinico-hematological profile of hemolytic uremic syndrome*. *Southeast Asian J Trop Med Public Health* 24 Suppl 1993; 1280-283.
6. Badami KG, Srivastava RN, Kumar R, Saraya AK. *Disseminated intravascular coagulation in post-dysenteric hemolytic uremic syndrome*. *Acta Paediatr Scand* 1987; 76:919-922.
7. Bukowski R. *Thrombotic thrombocytopenic purpura: A review*. *Prog Hemost Thromb* 1982; 62:87-337.

A CASE OF HEMOLYTIC UREMIC SYNDROME ASSOCIATED WITH  
EPSTEIN-BARR VIRUS INFECTION

8. Iselbacher KJ, Braunwald E, Wilson JD, Martin JB, Fauci AS, Kasper DL. *Epstein-Barr virus infections, including infectious mononucleosis. In: Harrison's principles of internal medicine. 13th ed. Singapore : McGraw-Hill, 1994; 790-793.*
  9. Lee S, Kjellstrand CM. *Renal disease in infectious mononucleosis. Clin Nephrol 1978; 9: 236-240.*
  10. Kanto RJ, Norden CW, Wein TP. *Infectious mononucleosis associated with rhabdomyolysis and renal failure. South Med J 1978; 71:346-348.*
  11. McCabe JL, Duckett S, Kaplan P. *Epstein Barr virus infection complicated by acute rhabdomyolysis. Am J Emerg Med 1988; 6:453-455.*
-