

A Completely Unique Branching Pattern of the Facial Artery

Kanae Nakamura, MD*

Hiroki Umezawa, MD, PhD*

Kazuhiko Yokoshima, MD, PhD†

Munenaga Nakamizo, MD, PhD†

Rei Ogawa, MD, PhD, FACS*

Summary: This case report describes a recent case where a patient with hypopharyngeal cancer underwent resection and reconstruction with a free jejunum flap and the surgeons found a rare variation in the branching pattern of the common carotid artery. Specifically, the left facial artery arose directly from the common carotid artery, whereas the left superior thyroid artery arose from the facial artery. This branching pattern has not been reported previously. Although this is a hitherto unique case, head and neck and reconstructive surgeons should be aware of the possibility that this branching pattern may be present because it could complicate the outcomes of both neck dissection and reconstruction by free tissue transfer. (*Plast Reconstr Surg Glob Open* 2019;7:e2305; doi: 10.1097/GOX.0000000000002305; Published online 25 July 2019.)

In general, the superior thyroid, lingual, and facial arteries branch off from the external carotid artery in a sequential manner. The anatomy of the external carotid artery and its branches is important in head and neck cancer surgery because it is a key landmark when dissecting the neck. Moreover, the branches of the external carotid artery often serve as recipient arteries in free flap transfer: our recent report showed that during reconstructive surgery after resection of head and neck cancers, the superior thyroid artery and the lingual or facial arteries serve as the recipient arteries in 44% and 20% of cases, respectively.¹

Thus, it is essential that head and neck and reconstructive surgeons fully understand the branching pattern of the external and common carotid arteries. However, several anatomical studies have reported variations in the branching of the superior thyroid, lingual, and facial arteries from the carotid arteries.²⁻⁹ Here we report a rare variation in the branching pattern of the common carotid artery that we encountered recently during head and neck surgery.

From the *Department of Plastic, Reconstructive and Aesthetic Surgery, Nippon Medical School, Tokyo, Japan; and †Department of Otolaryngology, Head and Neck Surgery, Nippon Medical School, Tokyo, Japan

Received for publication January 5, 2019; accepted April 26, 2019.

Copyright © 2019 The Authors. Published by Wolters Kluwer Health, Inc. on behalf of The American Society of Plastic Surgeons. This is an open-access article distributed under the terms of the Creative Commons Attribution-Non Commercial-No Derivatives License 4.0 (CCBY-NC-ND), where it is permissible to download and share the work provided it is properly cited. The work cannot be changed in any way or used commercially without permission from the journal. DOI: 10.1097/GOX.0000000000002305

CASE REPORT

An 80-year-old male patient who was diagnosed with hypopharyngeal cancer underwent total hypopharyngeal resection with bilateral neck dissection and total thyroidectomy followed by reconstruction with free jejunum transfer. When preparing the recipient vessels for microvascular anastomosis of the free jejunum flap, we observed that 2 of the arteries in the left neck of the patient had unique branching patterns. Specifically, instead of both the superior thyroid and facial arteries branching sequentially from the external carotid artery, the facial artery arose from the common carotid artery and the superior thyroid branched from the facial artery. The facial artery exhibited marked thickening of its wall. The superior thyroid artery was also slightly thicker than usual. By contrast, the external carotid artery was thinner than usual. The left lingual artery arose as usual from the external carotid (Figs. 1, 2).

We used the facial artery for vascular anastomosis because the superior thyroid artery was dissected by a surgeon during the dissection. After vascular anastomosis, the blood flow of the facial artery was successfully restored. The free flap survived without congestion and any other postsurgical complications (Fig. 3).

DISCUSSION

Several variations in the common and external carotid arteries have been reported. First, several studies reported cases where the superior thyroid and lingual arteries arose via a thyrolingual trunk from either the external carotid artery,² the common carotid artery,³⁻⁶ or the carotid bifurcation.^{2,7} The incidence of a thyrolingual trunk aris-

Disclosure: The authors have no financial interest to declare in relation to the content of this article.




Fig. 1. Schematic depiction of the usual bifurcation pattern of the common carotid artery. A, ascending pharyngeal artery; C, common carotid artery; E, external artery; F, facial artery; I, internal carotid artery; J, internal jugular vein; L, lingual artery; O, occipital artery; S, superior thyroid artery; SCM, sternocleidomastoid muscle.

ing from the common carotid artery has been reported to be less than 0.1%.²

However, the thyrolingual trunk arising from the external carotid artery appears to be more common (0.7%–3%).^{4–6} Second, Latha and Sugavasi⁸ reported cases with a linguofacial trunk that arose from the common carotid artery (4% of 50 cadavers). In addition, Devadas, Pillay, and Sukumaran recently detected a linguofacial trunk arising from the external carotid artery in 16% of their cadavers.⁹

Third, Rao³ reported a case where the lingual and facial arteries arose from a linguofacial trunk that branched off the external carotid artery at the same point as the superior thyroid artery. Fourth, Kishve et al¹⁰ described a case where the superior thyroid artery branched from the common carotid artery and then the common carotid artery branched simultaneously into a linguofacial trunk, the occipital artery, the ascending pharyngeal artery, the external carotid artery, and the internal carotid artery.

Our case report describes a completely novel carotid artery variation. Specifically, the facial artery bifurcated directly from the common carotid artery rather than from the external carotid. Indeed, it had developed as a branch that supported the external carotid artery: consequently, it was thicker than usual and the external carotid artery was narrower than usual. The superior thyroid artery bifurcated from this thick facial artery instead of from the external carotid artery. The internal carotid artery was

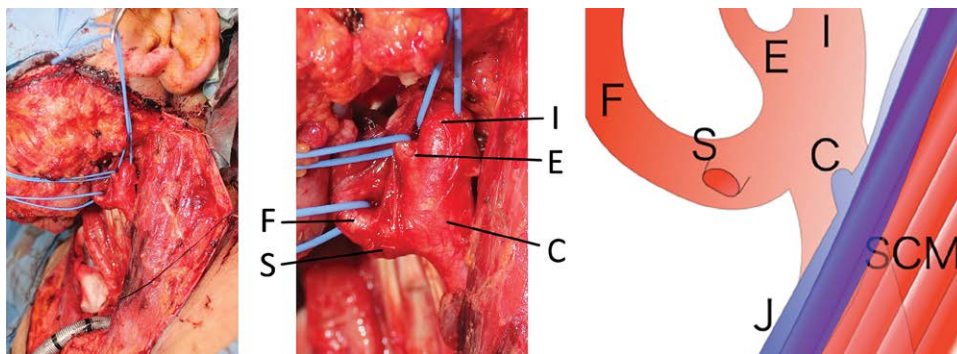


Fig. 2. Perioperative photographs showing the facial artery arising from the common carotid artery in our case and a schematic depiction of the anatomic variation. The superior thyroid artery was tied off and ligated during neck dissection. C, common carotid artery; E, external artery; F, facial artery; I, internal carotid artery; J, internal jugular vein; S, superior thyroid artery; SCM, sternocleidomastoid muscle.

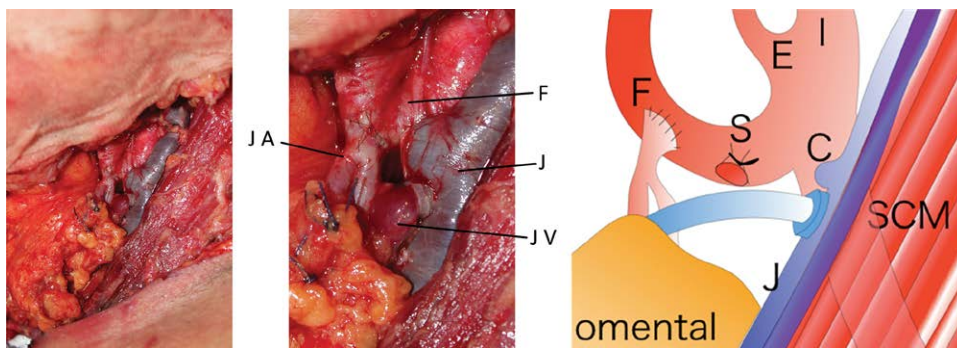


Fig. 3. The facial artery was anastomosed end-to-side with the free jejunum flap. C, common carotid artery; E, external artery; F, facial artery; I, internal carotid artery; J, internal jugular vein; JA, jejunal artery; JV, jejunal vein; S, superior thyroid artery; SCM, sternocleidomastoid muscle.

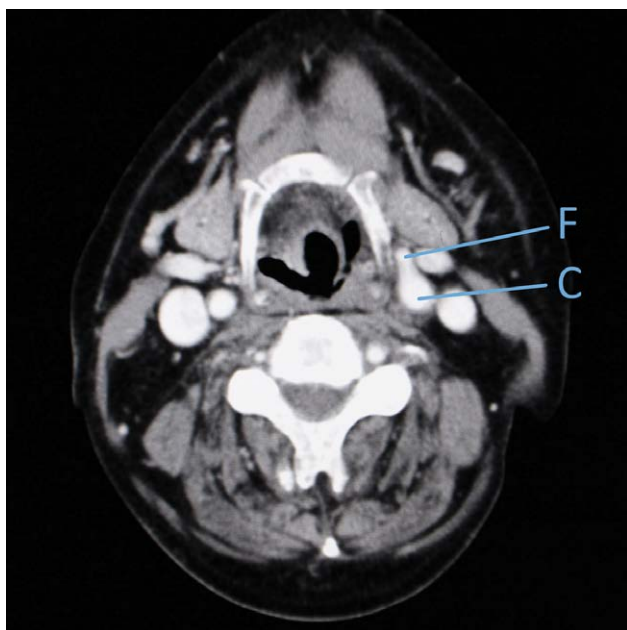


Fig. 4. The common carotid anatomical variation observed during surgery was difficult to see on preoperative contrast-enhanced CT images. C, common carotid artery; CT, computed tomography; F, facial artery.

normal. Despite its different branching origin, the facial artery still passed under the digastric muscle and then ran toward the submandibular gland.

In this case, we did not detect the unusual branching pattern of the vessels in the preoperative contrast-enhanced computed tomography scan of the head and neck. However, when we examined the computed tomography images carefully after the operation, we were eventually able to see the bifurcation of the facial artery from the common carotid artery, although it was very difficult to spot (Fig. 4). This reflects the limitations of preoperative magnetic resonance imaging and computed tomography imaging of the head and neck: although these imaging techniques are sufficient for evaluating the location, size, and local invasion of head and neck tumors and their metastasis to lymph nodes, they are not as effective in terms of delineating details such as thin vessels. We believe that 3-dimensional reconstructive computed tomography scans may be more useful for guiding surgeons, especially young surgeons. In particular, this technology will help surgeons to avoid errors in recipient vessel selection.

CONCLUSIONS

To our knowledge, this is the first report of (1) a facial artery that arises from the common carotid artery and (2) a superior thyroid artery that arises from the facial artery. It is also an example of the rare cases in which a variation in the common carotid artery anatomy is discovered during surgery: most other cases of common carotid artery variations were discovered when cadavers were dissected for anatomical analyses of the bifurcation of the branches of the common carotid artery. It is very important that surgeons, especially those performing head and neck surgery, are fully aware of the possible variations of the external and common carotid arteries.

Kanae Nakamura, MD

Department of Plastic, Reconstructive
and Aesthetic Surgery
Nippon Medical School
1-1-5 Sendagi

Bunkyo-ku, 113-8603 Tokyo, Japan
E-mail: nakamurakanaejapan@gmail.com

REFERENCES

1. Umezawa H, Ogawa R, Nakamizo M, et al. A comparison of microsurgical venous anastomosis techniques. *J Nippon Med Sch.* 2015;82:17.
2. Kapre M, Mangalgi AS, Mahore D. Study of thyro-lingual trunk and its clinical relevance. *Indian J Otolaryngol Head Neck Surg.* 2013;65:102–104.
3. Rao TR. Unusual branching pattern of the external carotid artery in a cadaver. *Chang Gung Med J.* 2011;34(6 Suppl):24–27.
4. Ergur IK, Icke C. A case with thyrolingual trunk originating from common carotid artery. *ARAJ IK.* 2004;18:256–259.
5. Babu BP. Anomalous origin of thyrolingual trunk from right common carotid artery: a case report. *J Anat Soc India.* 2001;50:47–48.
6. Budhiraja V, Rastogi R. Variant origin of thyrolingual trunk from left common carotid artery. *Int J Anat Variation.* 2010;3:44–45.
7. Jadhav SD, Ambali MP, Patil RJ, et al. Thyrolingual trunk arising from the common carotid bifurcation. *Singapore Med J.* 2011;52:e265–e266.
8. Latha KA, Sugavasi R. Study of the common origin of lingual and facial artery from external carotid artery. *J Dental Med Sci.* 2016;15:58–59.
9. Deepa D, Minnie P, Tomtu TS. A cadaveric study on Variations in branching pattern of external carotid artery. *Anat Cell Biol.* Available at <https://www.ncbi.nlm.nih.gov/pmc/articles/PMC6318462/>. Accessed Dec 2018.
10. Kishve PS, Kishve SP, Joshi M, et al. An unusual branching pattern of common and external carotid artery in a human cadaver: a case report. *Australas Med J.* 2011;4:180–182.