

[ CASE REPORT ]

## Diagnosing Corticobasal Syndrome Based on the Presence of Visual Hallucinations and Imaging with Amyloid Positron Emission Tomography

Hiroshi Nishida<sup>1</sup>, Yuichi Hayashi<sup>2</sup>, Naoko Harada<sup>1</sup>, Takeo Sakurai<sup>1</sup> and Kenji Wakida<sup>1</sup>

### Abstract:

A 61-year-old woman was admitted to our hospital due to memory difficulties, visual hallucinations, and slowly progressing motor difficulties in the limbs. A clinical examination revealed bradykinesia, gait disturbance, left-side-dominant rigidity, ideomotor apraxia, dressing apraxia, left-sided spatial agnosia, impaired visuospatial ability, and executive dysfunction. Her symptoms were unresponsive to levodopa, and corticobasal syndrome (CBS) was diagnosed. One year later, amyloid positron emission tomography revealed amyloid beta accumulation in the bilateral cerebral cortices; at this point, CBS with underlying Alzheimer's disease pathology (CBS-AD) was diagnosed. Visual hallucinations may help differentiate CBS with corticobasal degeneration (CBS-CBD) from other pathologies, including CBS-AD.

**Key words:** corticobasal syndrome, visual hallucinations, amyloid positron emission tomography

(Intern Med 57: 605-611, 2018)

(DOI: 10.2169/internalmedicine.8534-16)

### Introduction

Corticobasal degeneration (CBD) is characterized by the clinical presentation of cortical symptoms, including apraxia, cortical sensory loss, and alien limb sign. The asymmetrical presentation of extrapyramidal symptoms, including rigidity that is unresponsive to levodopa, akinesia, dystonia, and myoclonus, are also observed in CBD. Pathologically, CBD is characterized by neuronal loss in the cerebral cortices, striatum, and substantia nigra, cortical ballooned neurons, and the abnormal accumulation of tau protein in neurons, astrocytes, and oligodendroglia (1).

Rebeiz et al. first reported CBD (2), and subsequent reports of other cases indicated substantial variation in its underlying pathology. Boeve et al. postulated that neuropathologic criteria were necessary for the diagnosis of CBD because cases that were clinically diagnosed with CBD had other pathologies, including Alzheimer's disease (AD), progressive supranuclear palsy, Pick's disease, and Creutzfeldt-Jakob disease (3). In 2003, Boeve et al. proposed clinical

criteria for use in the diagnosis of corticobasal syndrome (CBS) and pathological criteria to be used for diagnosing CBD (4). Several diagnostic criteria for CBS have been proposed (4-7). A review of the existing reports on CBS suggested that 37% of the underlying pathology was CBD, while AD-like dementia accounted for 8% of cases (7).

It is notable that AD pathology accounts for a significant percentage of CBS cases. AD is characterized by dementia. Amyloid positron emission tomography (PET) allows for the *in vivo* visualization of amyloid beta (A $\beta$ ) peptide accumulation, which is an important biomarker and a useful tool for the diagnosis of AD (8-10). Pittsburgh compound B (PiB)-PET is widely used to detect A $\beta$  accumulation due to its superior sensitivity and specificity.

We herein report the clinical characteristics of a patient who was initially diagnosed with CBS but was subsequently diagnosed with CBS with underlying AD pathology (CBS-AD) following amyloid PET imaging.

<sup>1</sup>Department of Neurology, Gifu Prefectural General Medical Center, Japan and <sup>2</sup>Departments of Neurology and Geriatrics, Gifu University Graduate School of Medicine, Japan

Received: November 10, 2016; Accepted: August 17, 2017; Advance Publication by J-STAGE: December 21, 2017

Correspondence to Dr. Hiroshi Nishida, 41151@gifu-hp.jp

## Case Report

A 61-year-old, right-handed woman was admitted to our hospital due to memory difficulty and slowly progressive motor dysfunction in the left upper limb. She had a surgical history of uterine fibroids and cervical spondylosis. An interview with her husband revealed that the patient's difficulties with memory and left upper limb movement had begun approximately two years prior to admission, which made it difficult for the patient to perform household chores. Approximately one year before admission, the patient had started experiencing visual hallucinations, reporting that "someone is standing at the front door" and that "there are many children in the house." Despite these symptoms, the patient's insight into her illness was poor.

The patient was alert, with a body temperature of 37.4°C, blood pressure of 117/71 mmHg, and a pulse of 72 beats per min. Examinations of the heart, lungs, and abdomen were unremarkable. A neurological examination revealed bradykinesia, gait disturbance, rigidity in the left upper and lower limbs, and impaired fine motor skills in the left upper limb. In addition, ideomotor apraxia, dressing apraxia, constructive apraxia, limb-kinetic apraxia, left-sided spatial agnosia, topographical agnosia, impaired visuospatial ability, and executive dysfunction were noted. Blood test results were unremarkable. On a cognitive examination, the patient's Mini-Mental State Examination (MMSE) score was 18 points (orientation, 6 points; registration, 3 points; attention and calculation, 2 points; recall, 0 points; and language, 7 points); Hasegawa Dementia Scale-Revised (HDSR) score was 21 points (age, 1 point; orientation, 4 points; immediate recall of 3 words, 3 points; delayed recall of 3 words, 3 points; calculation, 1 point; backward digit span, 1 point; visual encoding and recall, 3 points; and semantic verbal fluency, 5 points). The patient's score of 15 points on the Montreal Cognitive Assessment, Japanese version (MoCA-J) indicated the presence of cognitive dysfunction [short-term memory, 0 points; visuospatial abilities (clock-drawing task), 2 points; three-dimensional cube copying, 0 points; executive function (alternating Trail Making Test B), 0 points; phonemic verbal fluency task, 0 points; a two-item verbal abstraction task to explain what each pair of words had in common, 1 point; attention, concentration, and working memory, 5 points (a vigilance or sustained-attention task, 1 point; a serial-subtraction task, 3 points; and forward and backward digits, 1 points); time and place orientation, 4 points; a further 1 point was added, as she had completed 10 years of education].

Magnetic resonance imaging (MRI) of the brain did not reveal clear evidence of ischemic changes, basal ganglia degeneration, or amyloid angiopathy. An analysis utilizing the voxel-based specific regional analysis system for AD (VSRAD<sup>®</sup>11) resulted in a Z-score of 2.2. There was evidence of atrophy in the AD areas of interest in the medial temporal lobe, including the entorhinal cortex, amygdala,

and hippocampus. T1-weighted images indicated atrophy in the regions around the right motor sensory area and bilateral superior frontal gyri (Fig. 1). Single photon emission computed tomography (SPECT) using <sup>99m</sup>Tc-ethyl-cysteinatedime (<sup>99m</sup>Tc-ECD) was also performed. An evaluation with an easy Z-score imaging system indicated decreased perfusion in the right frontal, parietal, and occipital lobes, right precuneus, and left parietal lobe (Fig. 2).

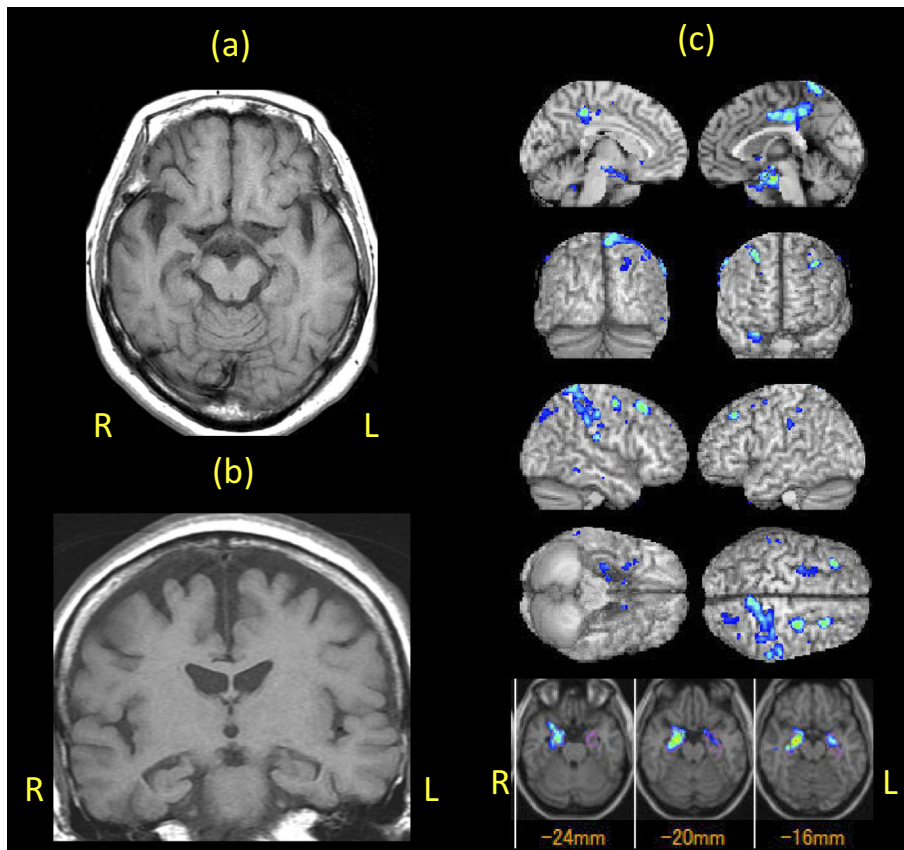
The patient was prescribed levodopa/carbidopa to treat her Parkinsonian symptoms following admission; however, her motor symptoms did not improve. These findings together satisfied the revised Cambridge criteria (6), and she was diagnosed with CBS. However, her response to treatment continued to be poor, and her symptoms worsened.

One year later, fluorodeoxyglucose (FDG)-PET and amyloid PET imaging were performed. Amyloid PET imaging revealed the accumulation of A $\beta$  in the bilateral cerebral cortices (Fig. 3a). Furthermore, FDG-PET imaging showed regions of low metabolism in the right frontal, temporal, parietal, and occipital lobes; in the left frontal, temporal, and parietal lobes; and in the bilateral precuneus (Fig. 3b). We therefore concluded that this patient had CBS-AD and started her on a cholinesterase inhibitor as treatment for AD.

In addition, a visual inspection of a [<sup>123</sup>I]-2 $\beta$ -carbomethoxy-3 $\beta$ -(4-iodophenyl)-N-(3-fluoropropyl) nortropane (FP-CIT) SPECT scan, which had been obtained to differentiate AD from Parkinson's disease (PD) and Lewy body disease such as dementia with Lewy bodies (DLB), revealed that the uptake of FP-CIT in the right dorsal striatum (the side contralateral to the dominant side of Parkinsonism) was decreased compared with the left dorsal striatum in all slices. However, the normal striatal uptake ratio (SUR) determined using DaTQUANT<sup>™</sup> (GE Healthcare, Little Chalfont, UK) (Fig. 4a) and meta-iodobenzylguanidine (MIBG) myocardial scintigraphy did not show any evidence of a reduced cardiac uptake, as the patient's heart-to-mediastinum (H/M) uptake ratio was 2.87 in the early phase and 2.32 in the late phase (Fig. 4b).

## Discussion

This case was diagnosed clinically with CBS-AD due to the presence of A $\beta$  accumulation on PiB-PET imaging. There has been a recent increase in the number of reported cases with CBS-AD based on pathological diagnoses, and studies comparing CBS-AD and CBS resulting from underlying CBD pathology (CBS-CBD) have been performed (12, 13). Hassan et al. reported that, compared with CBS-CBD cases, CBS-AD cases had a younger age of onset, hemisensory neglect, memory impairment, visuospatial difficulties, dressing apraxia, and myoclonus; however, there were no marked differences in aphasia, limb apraxia, alien limb phenomenon, fist hand, Parkinsonism, pyramidal motor signs, dystonia, or Gerstman syndrome between the two groups (13). The typical CBS-AD features of hemisensory neglect, memory impairment, visuospatial difficulties, and



**Figure 1.** T1-weighted magnetic resonance (MR) images of the brain [(a) axial section (cerebral peduncle level), (b) coronal section (interpeduncular fossa level)] showing asymmetric atrophy in the right temporal lobes. (c) The voxel-based specific regional analysis system for Alzheimer's disease (VSRAD<sup>®</sup>) revealed a significant decrease in the gray matter volume of the bilateral medial temporal area (the medial temporal lobe, including the entorhinal cortex, amygdala, and hippocampus), right motor area, and bilateral superior frontal gyri. Colored areas with Z-scores >2 are overlaid as significantly atrophied regions on tomographic sections and the cortical surface of the standardized MRI template.

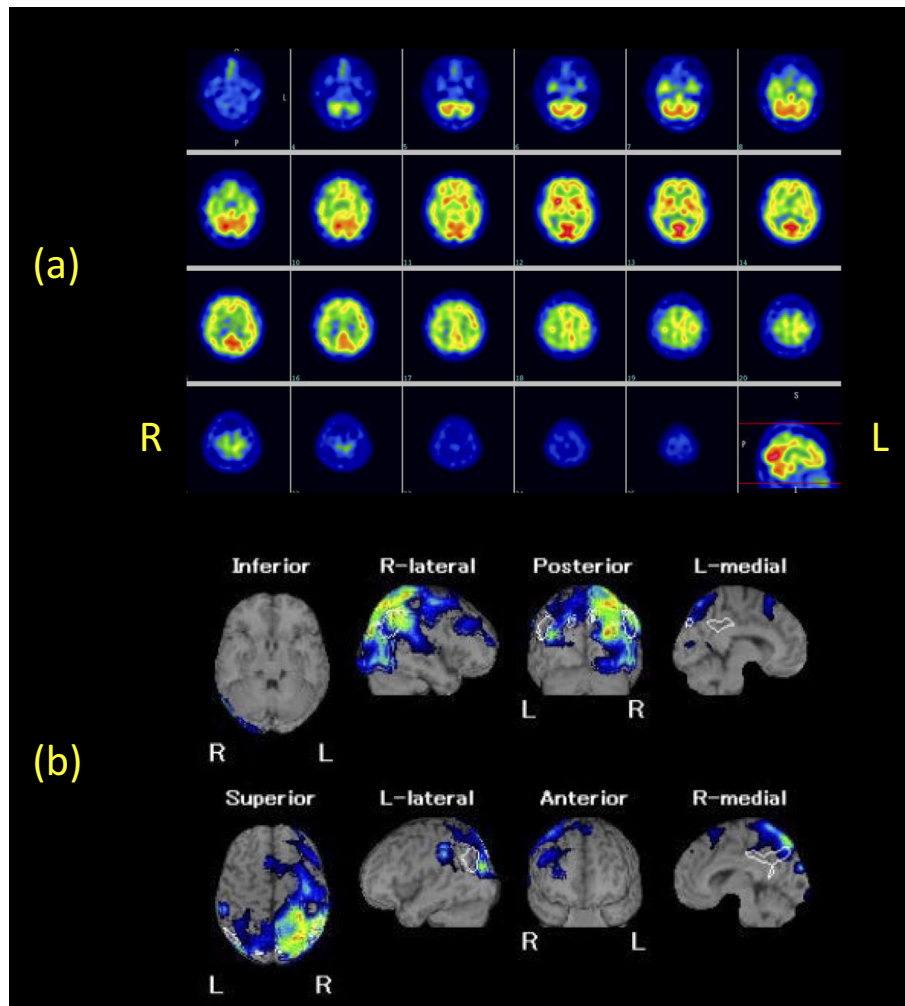
dressing apraxia were observed in our case, and visual hallucination was also present.

There have been an increasing number of reports on the use of amyloid PET imaging for the diagnosis of CBS-AD (14, 15). However, some cognitively normal individuals test positive for A $\beta$  on amyloid PET imaging. Indeed, it was reported that >40% of cognitively normal individuals over 71 years of age were positive for A $\beta$  (16). In addition, many DLB cases are known to have both AD and DLB pathologies (17). In particular, significantly more individuals with DLB have positive amyloid PET findings than those with PD, PD with dementia, or normal controls (18), suggesting that amyloid PET may not necessarily be a useful examination for differentiating AD from DLB. It should be noted that the clinical diagnosis of AD cannot be performed solely based on an A $\beta$ -positive finding, given that the accumulation of A $\beta$  can be seen even in cognitively normal individuals and in individuals with non-AD neurodegenerative diseases, including DLB.

In the present case, several instruments were used to measure the cognitive function. The patient's performance on all tests indicated an impaired short-term memory; her

MoCA-J score indicated an impaired visuospatial ability and executive function. Cognitive dysfunction in DLB is characterized by marked impairment in attention, visuospatial ability, and executive function, with milder memory impairment. Visuospatial abilities are reportedly more impaired in patients with DLB than in those with AD (19), and deficits in visuospatial abilities are a typical feature of CBS (20). While our patient had a relatively high attention score on the MoCA-J, her low scores on the MMSE and HDSR suggested that her performance fluctuated. These findings may be consistent with DLB, as cognitive fluctuations are a typical feature of this disease (17). Impaired attention is also a commonly observed symptom in DLB, frontotemporal lobar degeneration, and progressive supranuclear palsy. A cognitive examination of the current patient further suggested functional impairment in the parietal, temporal, occipital, and frontal lobes, in addition to pathological features of non-AD diseases, such as DLB. These findings are consistent with our results from SPECT and FDG-PET. We therefore considered that her cognitive dysfunction might be more of a consequence of DLB than AD.

As stated earlier, a remarkable feature of the current case



**Figure 2.** (a) Single photon emission tomography (SPECT) images showing a decrease in the cerebral blood flow in the right fronto-temporo-parietal-occipital lobes. (b) SPECT images analyzed with the easy Z-score imaging system (eZIS) showing a decrease in the cerebral blood flow in the right fronto-temporo-parietal-occipital lobes and precuneus, and in the left parietal lobe. This image is right-dominant.

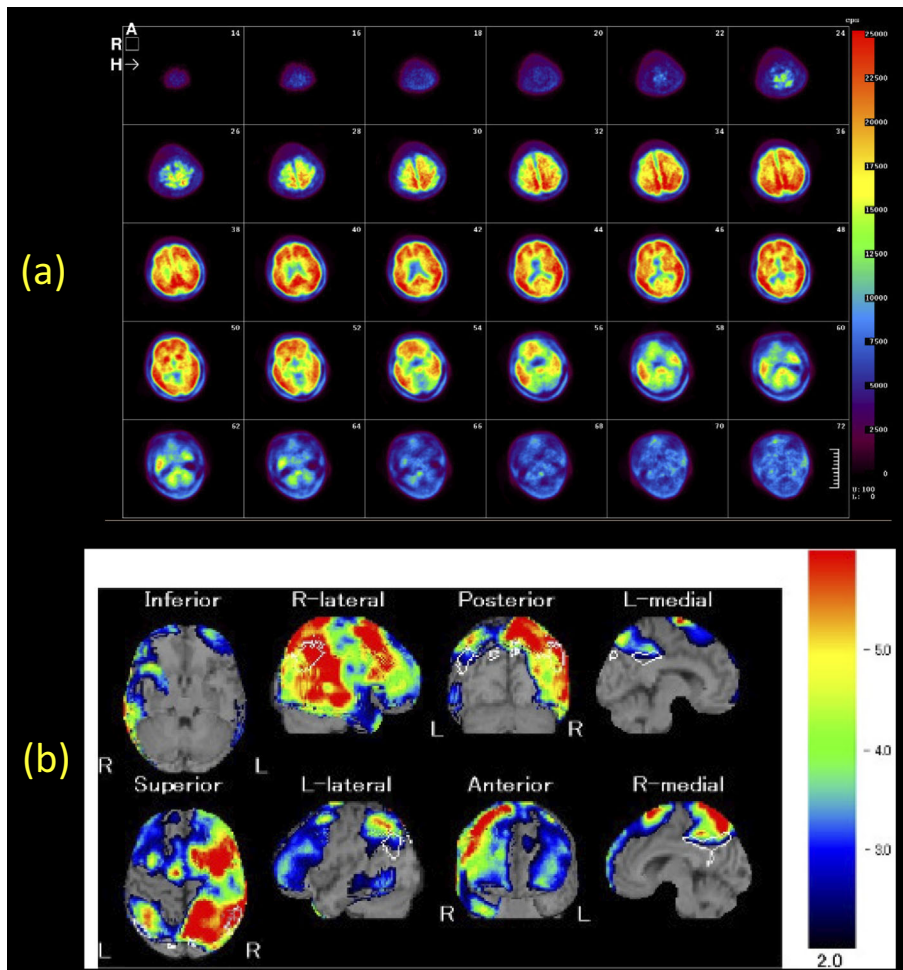
was the presence of visual hallucinations in addition to the symptoms frequently reported in CBS-AD, including memory impairment, visuospatial difficulties, and dressing apraxia. Visual hallucinations are reported frequently in PD and DLB and AD, but are rare in CBS (21, 22). Geda et al. suggested that the presence of visual hallucinations may be useful for differentiating CBD and other Parkinson's syndromes, as none of the patients pathologically diagnosed with CBD in their study experienced visual hallucinations (21). Bassiony et al. reported that 4-59% (median 19%) of patients with AD experienced visual hallucinations (23); however, the mechanisms underlying the development of visual hallucinations in AD are unclear.

CBD is extremely unlikely to cause visual hallucinations, so visual hallucinations can be a useful symptom for the differential diagnosis of CBS-CBD. Had visual hallucinations been included as a symptom of CBS, we would have needed to consider the possibility of CBS resulting from underlying DLB, PD or AD pathologies.

Although no clear atrophy was observed within the parie-

tal and occipital lobes in the current case, the  $^{99m}\text{Tc}$ -ECD SPECT and FDG-PET examinations demonstrated extensive areas of reduced perfusion and metabolic abnormalities in the parietal and occipital lobes. A decrease in perfusion in the occipital lobe, including the primary visual cortex, is a characteristic finding of cerebral blood flow scintigraphy in DLB. However, the sensitivity of decreased perfusion in DLB is not high, at approximately 65% (24). In contrast, in AD, decreased perfusion starts in the posterior cingulate cortex and precuneus and then spreads to the parietal, temporal, and frontal lobes during disease progression. The lack of decreased perfusion in the primary sensory and motor cortices, visual cortex in the occipital lobe, thalamus, basal ganglia, and cerebellum is useful for the diagnosis. In the current patient, we did not observe decreased perfusion in the medial occipital lobe, including the visual cortex, which is inconsistent with the typical features of AD. The patient instead showed decreased perfusion in the right lateral occipital lobe, which can be considered consistent with DLB according to cerebral blood flow scintigraphy. In addition, in pos-





**Figure 3.** (a) Amyloid positron emission tomography (PET) images using Pittsburgh compound B (PiB) showing significant diffuse deposition of fibrillary amyloid plaques throughout the cortex. (b) Fluorodeoxyglucose-PET images analyzed with eZIS showing glucose hypometabolism in the right fronto-temporo-parietal-occipital lobes and precuneus, and in the left fronto-temporo-parietal lobes. This image is right-dominant.

terior cortical atrophy (PCA), which presents with progressive functional impairment in the parietal and occipital lobes, parietal and occipital lobe atrophy is observed, with perfusion and metabolism abnormalities in those regions as shown by cerebral blood flow scintigraphy and FDG-PET (25). The most common underlying pathology is AD; however, visual hallucinations are rarely reported in such patients.

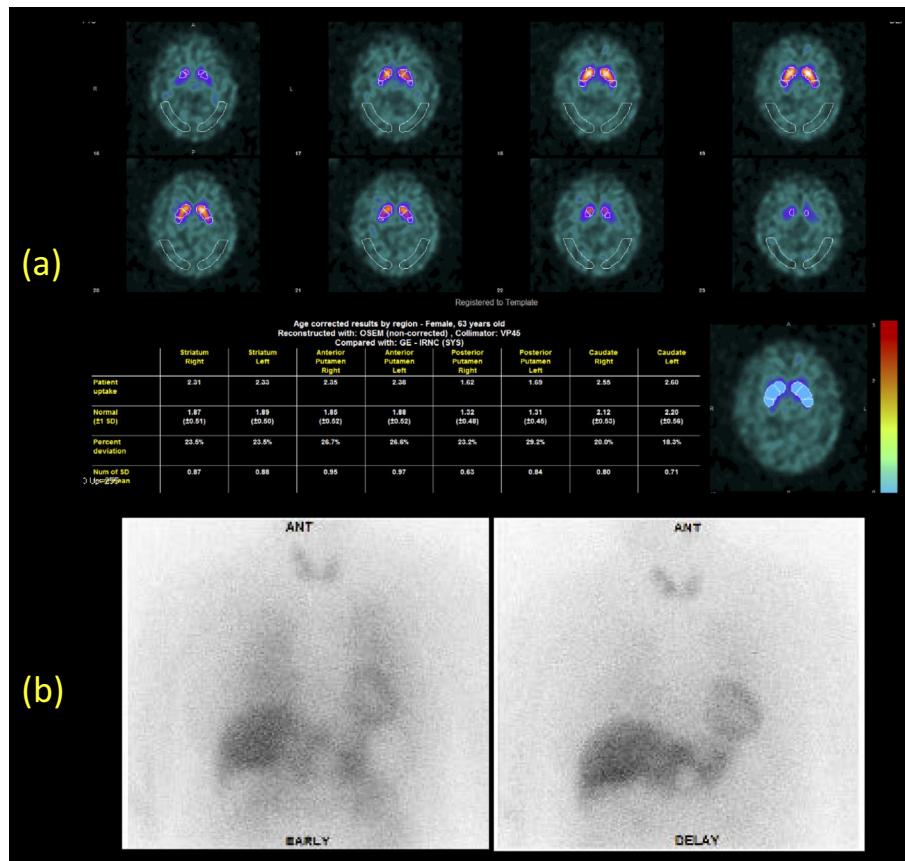
The current case and patients with PCA share an underlying AD pathology with functional abnormalities in the parietal and occipital lobes; however, these two conditions differ in terms of the presence of visual hallucinations. While the cause of this difference is unclear, the current case may have had DLB pathology as well, based on the clinical symptoms.

We used two neuroimaging techniques in the present study because of their ability to differentiate between DLB and PD. Our patient presented with asymmetric Parkinsonism. Although she had a normal SUR, a visual inspection of the SPECT scan revealed a decrease in the uptake of FP-CIT in the right dorsal striatum, which was the side contra-

lateral to the dominant side of her Parkinsonism. These results suggest that a mild degree of dopaminergic neuron degeneration may have existed in the substantia nigra.

In addition, although approximately one-third of patients with AD present with Parkinsonism over the course of their disease, not all cases have Lewy body pathology at autopsy. In a recent study of patients with a diagnosis of pure AD confirmed by pathology who presented with Parkinsonism, Parkinsonism associated with AD was related to a significant loss of neurons in both the substantia nigra pars compacta and the putamen (26). These changes might also have occurred in our case, since a visual inspection of the SPECT scan revealed a decrease in the FP-CIT uptake in the right dorsal striatum.

Cilia et al. reported that the majority of patients with CBS showed decreased FP-CIT binding on FP-CIT SPECT scans, while approximately 10% of patients showed normal binding (27). The current patient showed mild alterations on the SPECT scan, but the progression of her symptoms and changes in the FP-CIT SPECT scan over time should be monitored.



**Figure 4.** (a) [ $^{123}\text{I}$ ]-2 $\beta$ -Carbomethoxy-3 $\beta$ -(4-iodophenyl)-N-(3-fluoropropyl) nortropine (FP-CIT) SPECT images showed that the striatal uptake ratio (SUR) in the right striatum was 2.21 (normal range  $1.87\pm 0.51$ ) and in the left striatum was 2.33 (normal range  $1.89\pm 0.50$ ) using DaTQUANT<sup>TM</sup>. This result was normal. (b) Meta-iodobenzylguanidine (MIBG) myocardial scintigraphy showed that the heart/mediastinum (H/M) uptake ratio was 2.87 in the early phase and 2.32 in the late phase (normal H/M uptake ratio  $\geq 2.2$ ). This result was indicative of a normal cardiac uptake.

In the current case, the MIBG myocardial scintigraphy findings were within normal limits. A Japanese multi-center study in which the H/M ratio in the late phase of MIBG myocardial scintigraphy was used to differentiate probable AD from probable DLB had 68.9% sensitivity and 89.1% specificity (28). Furthermore, a multi-center study in which  $^{123}\text{I}$ -FP-CIT SPECT was used to differentiate DLB from non-DLB had 77.7% sensitivity and 90.4% specificity (29). Although typical neuroimaging methods were not indicated in the current case, it should be noted that differential diagnoses cannot be based solely on imaging results, as there are DLB cases with normal myocardial scintigraphy and  $^{123}\text{I}$ -FP-CIT SPECT findings.

Although the current case satisfied the diagnostic criteria for CBS, a diagnosis of probable DLB is also possible due to fluctuating cognition, visual hallucinations, and Parkinsonism, which satisfy the central and core features of the diagnostic criteria for the Consortium on DLB (17). In contrast, a diagnosis of AD based on the Diagnostic and Statistical Manual of Mental Disorders, Fifth Edition criteria, for instance, is not possible, because other neurodegenerative diseases cannot be ruled out due to their sharing similar clinical symptoms. Therefore, we were unable to diagnose

the current case with AD, and a diagnosis of CBS with underlying AD pathology seemed more appropriate. However, previous studies have shown co-existing AD pathology, commonly observed with DLB, as well as pathological findings consistent with CBS-progressive supranuclear palsy in cases of diffuse Lewy body disease (30).

It is important that a diagnosis of CBS-AD be made by amyloid PET imaging as it leads to the early initiation of treatment for AD. Furthermore, Armstrong et al. proposed new diagnostic criteria for CBD (7), which included the exclusion of AD. Therefore, ruling out AD is essential, and amyloid PET imaging will likely become increasingly important to this end in the future (31). However, a careful diagnosis is required for AD, as amyloid PET must be positive in non-AD neurodegenerative diseases, including DLB common form as well as AD. The current case suggests that visual hallucinations may be an important symptom that indicates pathologies other than CBS-CBD, such as CBS-AD. It is therefore necessary to consider visual hallucinations as an important clinical symptom for differential diagnosis.

A recent study, in which the cognitive function of patients diagnosed pathologically with CBD and AD was examined, reported that there was no clear difference between CBD

and AD in the early disease stage; however, CBD cases presented with some distinct clinical features, including asymmetric motor and sensory signs, and a reduced episodic memory, executive function, and letter fluency during disease progression. Therefore, interval screening to discriminate clinical features may improve the antemortem diagnosis (32).

Since CBS is a heterogeneous syndrome, a comparison of the clinical features and pathology at autopsy may help improve the accuracy of the antemortem diagnosis of CBS.

**The authors state that they have no Conflict of Interest (COI).**

#### Financial Support

This work was supported by grants-in-aid from the Gifu University Graduate School of Medicine.

#### Acknowledgement

We thank Prof. Jun Shinoda, Department of Neurosurgery, Chubu Medical Center for Prolonged Traumatic Brain Dysfunction, Kizawa Memorial Hospital, for the PET imaging studies.

#### References

- Dickson DW, Bergeron C, Chin SS, et al. Office of rare diseases neuropathologic criteria for corticobasal degeneration. *J Neuropathol Exp Neurol* **61**: 935-946, 2002.
- Rebeiz JJ, Kolodny EH, Richardson EP Jr. Corticodentatonigral degeneration with neuronal achromasia. *Arch Neurol* **18**: 20-33, 1968.
- Boeve BF, Maraganore DM, Parisi JE, et al. Pathologic heterogeneity in clinically diagnosed corticobasal degeneration. *Neurology* **53**: 795-800, 1999.
- Boeve BF, Lang AE, Litvan I. Corticobasal degeneration and its relationship to progressive supranuclear palsy and frontotemporal dementia. *Ann Neurol* **54** (Suppl 5): S15-S19, 2003.
- Lang AE, Riley DE, Bergeron C. Corticobasal ganglionic degeneration. In: *Neurodegenerative Diseases*. Calne DB, Ed. WB Saunders, Philadelphia, 1994: 877-894.
- Mathew R, Bak TH, Hodges JR. Diagnostic criteria for corticobasal syndrome: a comparative study. *J Neurol Neurosurg Psychiatry* **83**: 405-410, 2012.
- Armstrong MJ, Litvan I, Lang AE, et al. Criteria for the diagnosis of corticobasal degeneration. *Neurology* **80**: 496-503, 2013.
- Klunk WE, Engler H, Nordberg A, et al. Imaging brain amyloid in Alzheimer's disease with Pittsburgh Compound-B. *Ann Neurol* **55**: 306-319, 2004.
- Bacsikai BJ, Frosch MP, Freeman SH, et al. Molecular imaging with Pittsburgh Compound B confirmed at autopsy: a case report. *Arch Neurol* **64**: 431-434, 2007.
- Ikonomovic MD, Klunk WE, Abrahamson EE, et al. Post-mortem correlates of *in vivo* PiB-PET amyloid imaging in a typical case of Alzheimer's disease. *Brain* **131**: 1630-1645, 2008.
- Matsuda H, Mizumura S, Nemoto K, et al. Automatic voxel-based morphometry of structural MRI with SPM8 plus diffeomorphic anatomic registration through exponentiated lie algebra improves the diagnosis of probable Alzheimer disease. *AJNR Am J Neuroradiol* **33**: 1109-1114, 2012.
- Josephs KA, Whitwell JL, Boeve BF, et al. Anatomical differences between CBS-corticobasal degeneration and CBS-Alzheimer's disease. *Mov Disord* **25**: 1246-1252, 2010.
- Hassan A, Whitwell JL, Josephs KA. The corticobasal syndrome-Alzheimer's disease conundrum. *Expert Rev Neurother* **11**: 1569-1578, 2011.
- Bensaïdane MR, M-P F, Damasse G, et al. Clinical utility of amyloid imaging in a complex case of corticobasal syndrome presenting with psychiatric symptoms. *J Neurol Disord* **26**: 1-4, 2014.
- Burrell JR, Hornberger M, Villemagne VL, Rowe CC, Hodges JR. Clinical profile of PiB-positive corticobasal syndrome. *PLoS One* **8**: e61025, 2013.
- Fleisher AS, Chen K, Liu X, et al. Apolipoprotein E ε4 and age effects on florbetapir positron emission tomography in healthy aging and Alzheimer disease. *Neurobiol Aging* **34**: 1-12, 2013.
- McKeith IG, Dickson DW, Lowe J, et al. Diagnosis and management of dementia with Lewy bodies: third report of the DLB Consortium. *Neurology* **65**: 1863-1872, 2005.
- Gomperts SN, Locascio JJ, Marquie M, et al. Brain amyloid and cognition in Lewy body diseases. *Mov Disord* **27**: 965-973, 2012.
- Shimomura T, Mori E, Yamashita H, et al. Cognitive loss in dementia with Lewy bodies and Alzheimer disease. *Arch Neurol* **55**: 1547-1552, 1998.
- Burrell JR, Hodges JR, Rowe JB. Cognition in corticobasal syndrome and progressive supranuclear palsy: a review. *Mov Disord* **29**: 684-693, 2014.
- Geda YE, Boeve BF, Negash S, et al. Neuropsychiatric features in 36 pathologically confirmed cases of corticobasal degeneration. *J Neuropsychiatry Clin Neurosci* **19**: 77-80, 2007.
- Bertram K, Williams DR. Visual hallucinations in the differential diagnosis of parkinsonism. *J Neurol Neurosurg Psychiatry* **83**: 448-452, 2012.
- Bassiony MM, Lyketsos CG. Delusion and hallucination in Alzheimer's disease. Review of the brain decade. *Psychosomatics* **44**: 388-401, 2003.
- Lobotesis K, Fenwick JD, Phipps A, et al. Occipital hypoperfusion on SPECT in dementia with Lewy bodies but not AD. *Neurology* **56**: 643-649, 2001.
- Crutch SJ, Lehmann M, Schott JM, Rabinovici GD, Rossor MN, Fox NC. Posterior cortical atrophy. *Lancet Neurol* **11**: 170-178, 2012.
- Horvath J, Burkhard PR, Herrmann FR, Bouras C, Kövari E. Neuropathology of parkinsonism in patients with pure Alzheimer's disease. *J Alzheimers Dis* **39**: 115-120, 2014.
- Cilia R, Rossi C, Frosini D, et al. Dopamine transporter SPECT imaging in corticobasal syndrome. *PLoS One* **6**: e18301, 2011.
- Yoshita M, Arai H, Arai H, et al. Diagnostic accuracy of 123I-meta-iodobenzylguanidine myocardial scintigraphy in dementia with Lewy bodies: a multicenter study. *PLoS One* **10**: e0120540, 2015.
- McKeith I, O'Brien J, Walker Z, et al. Sensitivity and specificity of dopamine transporter imaging with <sup>123</sup>I-FP-CIT SPECT in dementia with Lewy bodies: a phase III, multicentre study. *Lancet Neurol* **6**: 305-313, 2007.
- Haug A, Boyer P, Kluger B. Diffuse Lewy body disease presenting as corticobasal syndrome and progressive supranuclear palsy syndrome. *Mov Disord* **28**: 1153-1155, 2013.
- Shimohata T, Aiba I, Nishizawa M. Criteria for the diagnosis of corticobasal degeneration. *Brain Nerve* **67**: 513-523, 2015 (in Japanese).
- Day GS, Lim TS, Hassenstab J, et al. Differentiating cognitive impairment due to corticobasal degeneration and Alzheimer disease. *Neurology* **88**: 1273-1281, 2017.

The Internal Medicine is an Open Access article distributed under the Creative Commons Attribution-NonCommercial-NoDerivatives 4.0 International License. To view the details of this license, please visit (<https://creativecommons.org/licenses/by-nc-nd/4.0/>).