

Utilization of a Simple Surgical Guide for Multidirectional Cranial Distraction Osteogenesis in Craniosynostosis

Chihiro Matsui, MD*
 Eijiro Tokuyama, MD, PhD*
 Takaya Senoo, MD*
 Kiyoshi Yamada, MD, PhD*
 Masahiro Kameda, MD, PhD†
 Tetsuo Takeuchi, CDT‡
 Yoshihiro Kimata, MD, PhD*

Background: Multidirectional cranial distraction osteogenesis (MCDO) can achieve a desired shape for deformities of the cranium. In the past, visual estimation was used to reflect on the actual skull, but it was time-consuming and inaccurate. Here we demonstrate an effective osteotomy navigation method using surgical guides made from a dental impression silicone.

Methods: Seven patients who underwent MCDO between August 2013 and September 2016 were included in the study. Five cases involved utilization of the surgical guide for osteotomy. Three-dimensional (3D) printed cranium models were made using 3D computed tomography (3DCT) imaging data and dental impression silicone sheets were molded using the printed cranium models. These surgical guides were sterilized and used for intraoperative osteotomy design. Vertical distance between nasion/porion and osteotomy lines were calculated using 3D printed cranial models and postoperative 3DCT images to assess reproducibility.

Results: The average surgical time/design time was 535/37.0 minutes for the non-surgical guide group and 486.8/11.8 minutes for the surgical guide group (SG). Treatment using the surgical guide was significantly shorter in terms of operative time and time required for design. For the vertical distance comparison, the average distance was 5.7mm (SD = 0.3) in the non-SG and 2.5mm (SD = 0.44) in the SG, and SG was more accurate.

Conclusions: Shorter operative times and higher reproducibility rates could be achieved by using the proposed surgical guide, which is accurate, low-cost, and easily accessible. (*Plast Reconstr Surg Glob Open* 2020;8:e2797; doi: [10.1097/GOX.0000000000002797](https://doi.org/10.1097/GOX.0000000000002797); Published online 29 April 2020.)

INTRODUCTION

Various surgical procedures have been defined for the treatment of children with craniosynostosis. Distraction osteogenesis is one of the most widely used and effective cranial vault remodeling techniques for treating craniosynostosis.¹⁻⁹ However, the action of moving a large piece of bone in a single direction limits this method to acquire adequate morphologic improvement. Multidirectional

calvarial distraction osteogenesis (MCDO)^{10,11} enables alteration of both the extension axis and morphology of the cranium (Fig. 1), and this method was first defined by Sugawara et al to address the limitations of distraction osteogenesis.

The preparation of a surgical guide to accurately reproduce the preoperative simulation design would theoretically enable the surgeon to easily carry out such cranio-plasty procedures. MCDO leads to favorable outcomes in terms of cranial morphology; however, the design is complicated for inexperienced surgeons.

Most institutions usually rely on visual estimation during surgery, but this takes a lot of time and frequently results in inaccurate osteotomy lines.

To achieve the accuracy of a surgical simulation on the patient, it is mandatory to reflect the predetermined osteotomy line on the surgical site during the surgery.

From the *Department of Plastic and Reconstructive Surgery, Okayama University Hospital, Okayama, Japan; †Department of Neurological Surgery, Okayama University Hospital, Okayama, Japan; and ‡Department of Occlusal and Oral Functional Rehabilitation, Okayama University Hospital, Okayama, Japan.

Received for publication October 15, 2019; accepted March 2, 2020.

Copyright © 2020 The Authors. Published by Wolters Kluwer Health, Inc. on behalf of The American Society of Plastic Surgeons. This is an open-access article distributed under the terms of the [Creative Commons Attribution-Non Commercial-No Derivatives License 4.0 \(CCBY-NC-ND\)](https://creativecommons.org/licenses/by-nc-nd/4.0/), where it is permissible to download and share the work provided it is properly cited. The work cannot be changed in any way or used commercially without permission from the journal.

DOI: [10.1097/GOX.0000000000002797](https://doi.org/10.1097/GOX.0000000000002797)

Disclosure: The authors have no financial interest to declare in relation to the content of this article.

Related Digital Media are available in the full-text version of the article on www.PRSGlobalOpen.com.

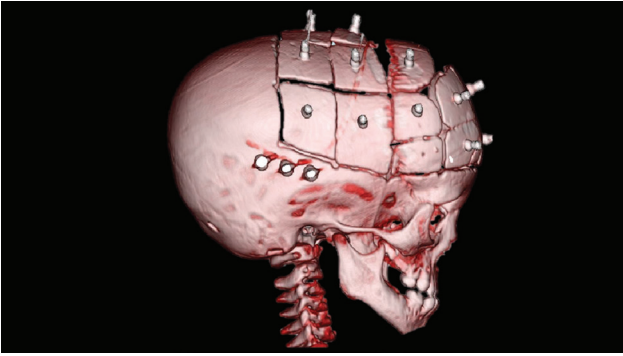


Fig. 1. High-resolution 3DCT images of a 2-year-old boy with sagittal synostosis taken right after cranioplasty with MCDO.

The osteotomy line for cranioplasty has been conventionally applied with a distance from landmark on 3-dimensional (3D) modeling of the cranium. However, the exposed part of the cranium is restricted by the scalp flap, making it difficult to precisely replicate the preoperative design due to the inability to visualize the entirety of the cranium.

In recent years, advances in digital technology and manufacturing processes have led to a paradigm shift in the simulation surgery field. Computer-aided design/computer-aided manufacturing (CAD/CAM) technology is widespread and commonly used for simulation surgery, and an increasing number of reports have been published.^{12–14} However, the planning software for simulation surgery and the virtual tools associated with CAD/CAM are still very costly.^{15,16}

Herein, we demonstrate a fast and effective method of operative navigation for cranial osteotomy by using an inexpensive and easy-to-use silicon dental impression material.

MATERIALS AND METHODS

A total of 7 patients who underwent MCDO for the treatment of craniosynostosis between August 2013 and September 2016 were included in the study. Five patients were men, and the remaining 2 were women. Average age at the time of surgery was 25.2 months (8–58 months). The surgical indications were (1) synostosis of >1 cranial suture on high-resolution computed tomographic (CT) images and (2) findings of digital impression on CT images or symptomatic cranial hypertension. Five patients were diagnosed with sagittal synostosis and the other 2 with multiple suture synostosis. The first 2 cases did not involve the utilization of a surgical guide, whereas surgical guides were used for osteotomy design for the remaining 5 cases.

The protocol for this study was conducted in accordance with the Declaration of Helsinki. All surgical treatment was done by the cooperative work of plastic surgeons and neurosurgeons.

Guide Creation and Design

Full-scale models of the cranium were prepared by a 3D printer (3D Systems ProJet460 plus; RICOH Co. Ltd.,

Tokyo, Japan), and the osteotomy lines were determined based on the cranial morphology and digital impression findings on CT images. An industrial drill (Mini Router NO.26800; Kiso Power Tool Mfg. Co. Ltd., Osaka, Japan) was used to drill a line of holes of 2-mm depth on the model surface. Protesil Labor (Vannini Dental Industry, Grassina [FI], Italy), a condensation silicone material of high viscosity and consistency which was widely used in dental medicine, was used to prepare the surgical guides. A silicone base and the catalyst were mixed homogeneously and then stretched onto the model to acquire 3-mm thickness. After 6 minutes required for the hardening of the material, the line of holes on the 3D-printed cranial models which were based on the osteotomy line were reproduced on the silicone model for viable intraoperative utilization (Fig. 2) (Videos 1–2). (See Video 1 [online], which displays a cranium model was created with a 3D printer based on high-resolution 3DCT imaging data and then the designed osteotomy lines were marked with 2-mm depth grooves created by a drill, Protesil Labor sheets to be used intraoperatively were molded into desired shapes by pushing against the printed cranium models. Designed osteotomy lines were copied onto the inner surface of the material.) (See Video 2 [online], which displays after molded and shaped Protesil Labor sheets, cut unnecessary part and marked osteotomy lines on the surface of surgical guide.)

The silicone models were autoclaved at 121°C for 20 minutes. After the exposure of the cranium by using a bicoronal incision, osteotomy by an ultrasonic bone scalpel (Sonopet, Mutoh Co. Ltd., Tokyo, Japan) was carried out with the guidance of the preprepared silicone models (Fig. 3). MCDO cranioplasty was carried out according to the surgical plan.

Analysis on Reproducibility

Porion and Nasion were selected as the points to accurately measure the osteotomy line in both simulation surgery and postoperative CT images. We measured the vertical distance (by millimeters) between nasion/porion and osteotomy lines, which were designed on the 3D models and osteotomy lines on postoperative high-resolution 3DCT images (Fig. 4).

RESULTS

The average patient age was 44 months (SD = 19.8) in the surgical guide group and 34.8 (SD = 5.8) in the nonsurgical guide group. Average operative time required for the design was 37 minutes in the nonsurgical guide group (SD = 1.4) and 11.8 minutes in the surgical guide group (SD = 0.83). The average total operative time was 535 minutes in the nonsurgical guide group and 486.8 minutes in the surgical guide group, and the average surgical design time was 37.0 minutes in the nonsurgical guide group and 11.8 minutes in the surgical guide group (Table 2). The surgical guides showed no major deformity through the autoclavization process and fit properly to the cranium intraoperatively in all cases. Comparison of the accuracy of the osteotomy line, the

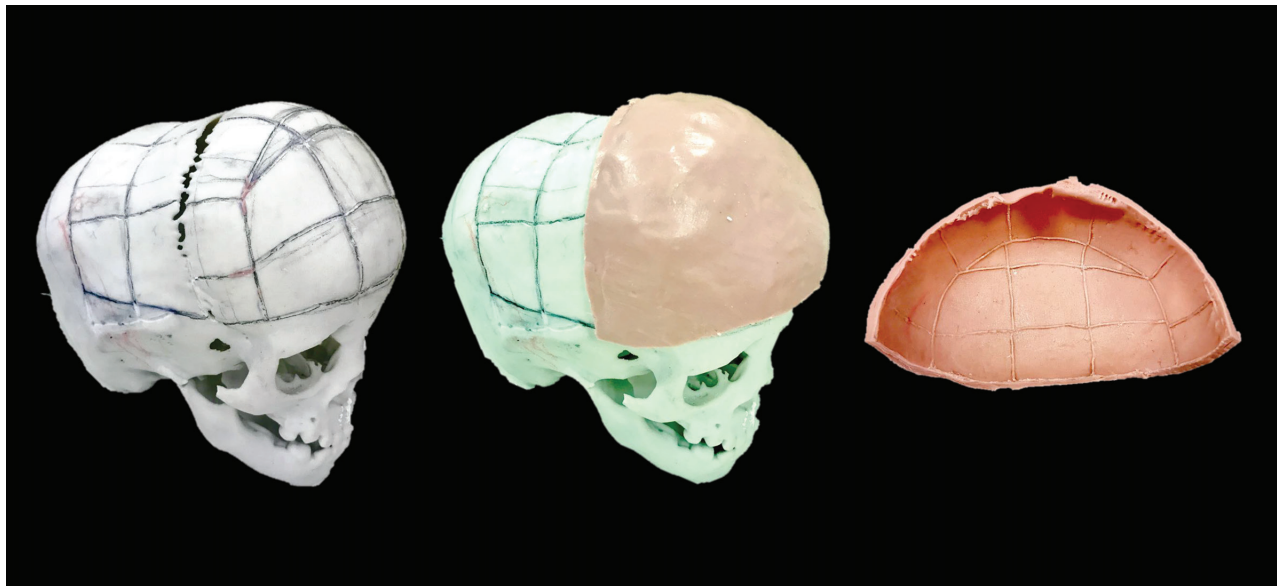


Fig. 2. A cranium model was created with a 3D printer based on high-resolution 3DCT imaging data and then the designed osteotomy lines were marked with 2-mm depth grooves created by a drill (left). Protasil Labor sheets to be used intraoperatively were molded into desired shapes by pushing against the printed cranium models (middle). Designed osteotomy lines were copied onto the inner surface of the material (right).

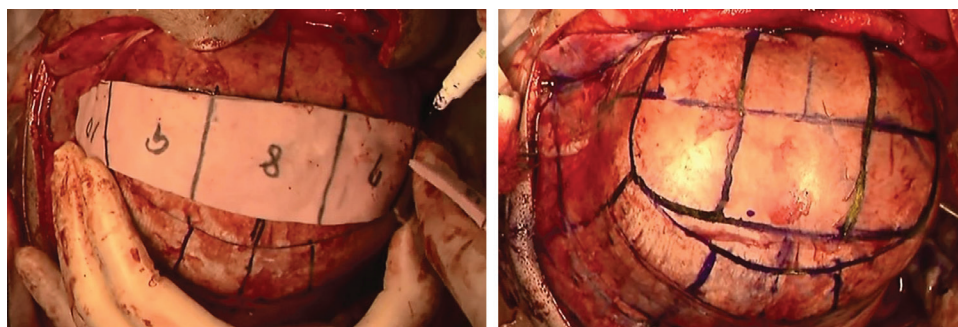


Fig. 3. Customized surgical guides were sterilized by autoclavization and used intraoperatively to design the actual osteotomy lines.

measured distance was 5.7 mm (SD = 0.3) in the nonsurgical guide group and 2.5 mm (SD = 0.44) in the surgical guide group.

DISCUSSION

MCDO allows 3-dimensional movement of bone fragments due to the multiple vector adjusters. Compared with the conventional unidirectional distraction technique, cranial morphologic improvement and intracranial volume expansion can be addressed effectively.^{10,11} We aimed to solve the problem of the difficulty in designing the osteotomy lines by using a dental silicone surgical guide. The surgical guide can be easily tailored for every individual patient.

The surgical guides are ideally required to be easily molded into 3-dimensional structures and resist high temperatures during autoclave sterilization. We have chosen the dental impression material Protasil Labor as the material for the process. This product is widely used for making

dental impressions in laboratories, and there are no other reports on the usage of Protasil Labor in live surgery. Protasil Labor could be easily cut and molded into complex structures and also resistant to temperatures up to 130°C.¹⁷ We noted a slight marginal distortion of the material during the 130°, 20-minute autoclavization process, but this problem is solved by changing the protocol to 121°, 20 minutes. To avoid any allergic reactions, confirmation of patients' medical history is necessary.¹⁷ The cost for the preparation of one surgical guide is approximately 5 US dollars. On the other hand, the cost for one 3D-printed cranial model is approximately 100 US dollars using the printer in our institution. However, 3D printing is becoming more and more available,^{18–21} and hospitals without a 3D printer could inquire with external companies for 3D printing services. Simultaneously, the computer software that can perform the simulation surgery and the output adjustment to the 3D printer is very expensive; thus, it is not always possible for every hospital to purchase this high-priced and high-performance computer software.

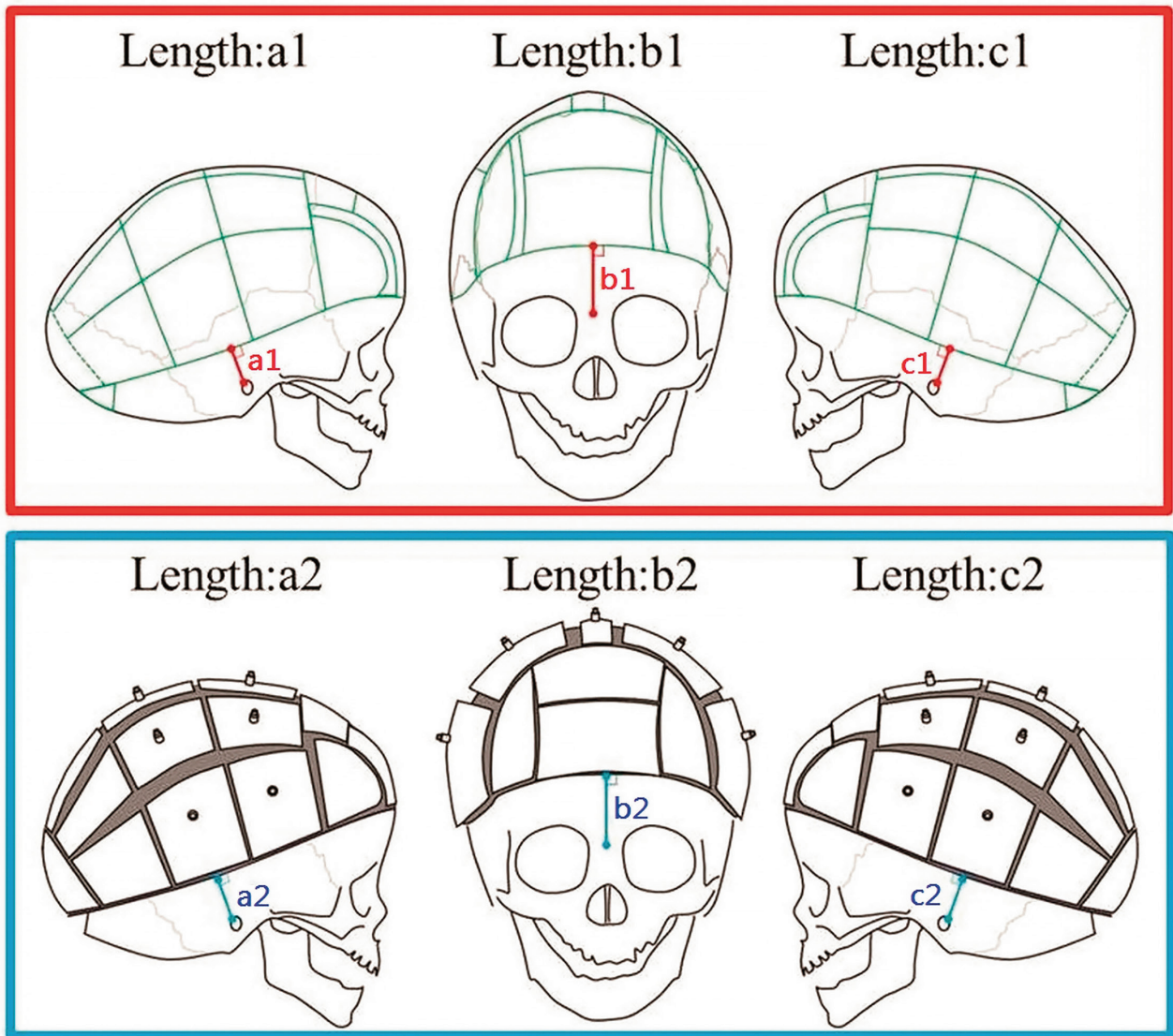


Fig. 4. After the preoperative decision on the osteotomy lines, calculations were made with references to the following: distance from right temporal osteotomy line to right porion: a1; distance from frontal inferior osteotomy line to nasion: b1; and distance from left temporal osteotomy line to left porion: c1. Similarly, postoperative calculations were made using 3DCT images with references to the following: distance from right temporal osteotomy line to right porion: a2, distance from frontal inferior osteotomy line to nasion: b2; and distance from left temporal osteotomy line to left porion: c2. Differences between pre- and postoperative calculations were used to determine the reproducibility of the model surgery.

Table 1. Details of the Studies about Usage of the Surgical Guides Group and Nonsurgical Guides Group

Patient	Sex	Age (mo)	Diagnosis	Total Operative Time (min)	Design Time (min)	Surgical Guide	No. Bone Pieces	Length: a1–a2 (mm)	Length: b1–b2 (mm)	Length: c1–c2 (mm)
1	F	30	Multiple suture synostosis	600	36	–	12	6.0	6.0	6.0
2	M	58	Multiple suture synostosis	470	38	–	16	5.2	5.5	5.6
3	M	17	Sagittal synostosis	508	11	+	26	2.8	3.2	3.1
4	M	8	Sagittal synostosis	441	12	+	11	2.1	2.0	2.3
5	F	20	Sagittal synostosis	495	12	+	22	2.6	2.0	2.2
6	M	22	Sagittal Synostosis	540	11	+	19	2.0	2.8	2.7
7	M	22	Sagittal synostosis	450	13	+	20	1.5	2.9	2.6

F, female; M, male.

This cost barrier to the software and devices is still a big problem. To improve this problem, we chose the dental impression silicone to make surgical guide because this material is inexpensive and easy to mold, and can stand autoclave sterilization. Also, the surgical guide can be created within 30 minutes if a skull model has already been created from a CT using a 3D printer. This is a significant advantage compared with the fact that it takes a few hours to one night to create a surgical guide on a 3D printer.^{22,23}

In this study, we have managed to achieve shorter operative times (48.2 minutes average) in the surgical guide group (Tables 1, 2). Considering that the decreased total operative time would result in a significant reduction in

the duration of hospitalization and patient morbidity,²⁴ we think that shorter designing time using this method can reduce complications. When we compared the accuracy of nonsurgical guide group and surgical guide group by measuring the vertical distance (by millimeters) between nasion/porion and osteotomy lines which were designed on the 3D models and osteotomy lines on postoperative high-resolution 3DCT images, the average difference in the distance was 3.23 mm.

In addition, even when comparing each porion–osteotomy lines and nasion–osteotomy lines (Fig. 4), surgical guide group was less deviation and superior in terms of accuracy.

Thus, surgical guide group was more accurate as the osteotomy system and has demonstrated improved accuracy over a free-hand operation.

Compared with the conventional approach, bone cutting design using the surgical guide has many advantages:

1. The surgical guide group is more accurate with respect to the reproduction accuracy of simulation surgery.
2. The same line can be drawn no matter which surgeon draws the osteotomy line on the skull.
3. The ability to standardize surgical design techniques and the ability to make more predictable and technology-independent designs, regardless of the clinician’s experience.
4. This can be used for educational purposes.

The guides are very accurate; it is possible that every surgeon can obtain accurate reconstruction results rather than using a free-hand approach where results are rather

Table 2. Patient Characteristics and Outcomes of the Vertical Distance between Nasion/Porion and Osteotomy Lines of 3D-printed Cranial Models and Postoperative 3DCT Images

Patient Characteristics	No Surgical Guide	Usage of Surgical Guide
	2	5
	Mean (SD)	Mean (SD)
Age (mo)	44.0 (19.8)	17.8 (5.8)
Bone pieces	14.0 (2.8)	19.6 (5.5)
Design time (min)	37.0 (1.4)	11.8 (0.8)
Total operation time (min)	535.0 (91.9)	486.8 (41.2)
Length a1 (mm)	39.0 (1.4)	31.8 (4.3)
Length a2 (mm)	33.4 (2.0)	29.6 (4.0)
Length a1–length a1 (mm)	5.6 (0.6)	2.2 (0.5)
Length b1 (mm)	39.0 (1.4)	39.2 (3.7)
Length b2 (mm)	33.3 (1.1)	36.5 (3.4)
Length b1–length b2 (mm)	5.8 (0.4)	2.7 (0.5)
Length c1 (mm)	38.5 (0.7)	31.8 (3.5)
Length c2 (mm)	32.7 (0.4)	29.2 (3.2)
Length c1–length c2 (mm)	5.8 (0.3)	2.6 (0.4)

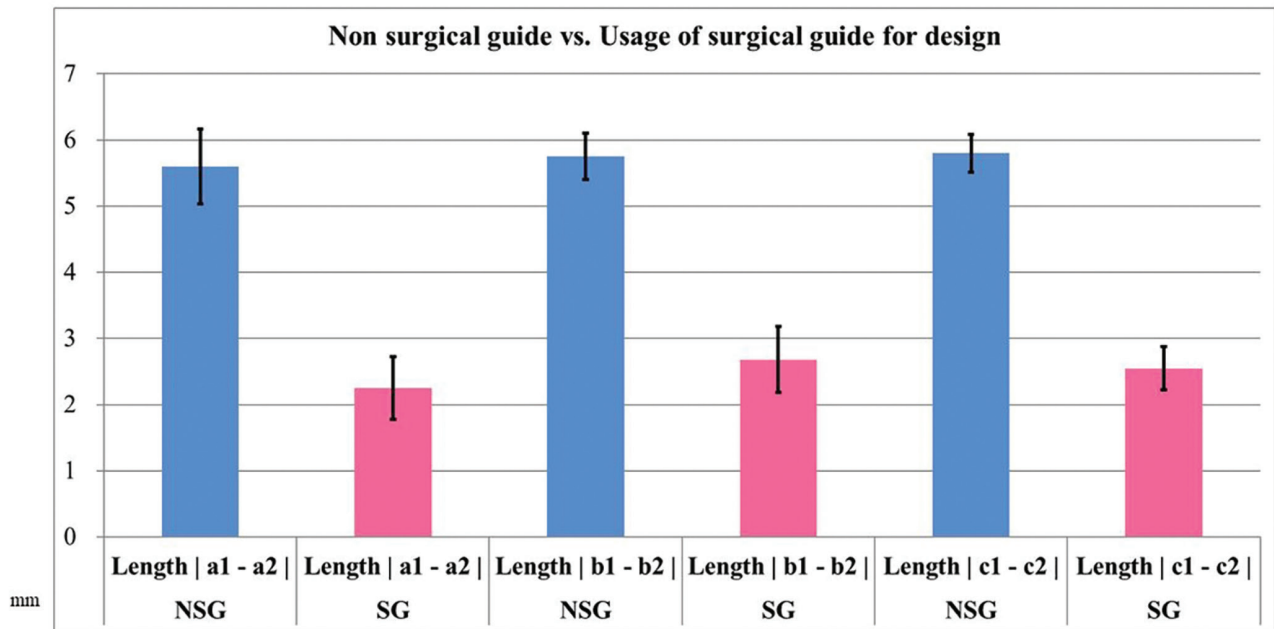


Fig. 5. Graph designed to demonstrate model surgery reproducibility by using the corrected values of the difference between aforementioned pre- and postoperative calculations. The surgical guide group was superior to non-model surgery group in terms of reproducibility. Blue: NSG, and red: SG. NSG indicates nonsurgical guide.

dependent on expertise (Fig. 5). However, our study only included 7 patients and we believe that further investigation with larger patient numbers is necessary.

CONCLUSIONS

The findings of this study show that shorter operative times and higher reproducibility rates for MCDO method could be achieved by using the surgical guide prepared according to our instructions. The mentioned guide is easy to prepare, low cost compared with other similar models, and easily accessible even in smaller clinical settings.

Chihiro Matsui, MD

Department of Plastic and Reconstructive Surgery
Okayama University Hospital
2-5-1, Shikata-cho
Kita-ku, Okayama-shi, Okayama-ken
Okayama, 700-0914 Japan
E-mail: onering2007@yahoo.co.jp

ACKNOWLEDGMENTS

The authors are very grateful to Yasushi Sugawara, MD, PhD, for his assistance. Without his guidance, valuable comments, and persistent help, this article would not have been possible. Our deepest appreciation also goes to Kazuaki Yamaguchi, MD, whose enormous support and insightful comments were invaluable during the course of the study.

REFERENCES

- Sugawara Y, Hirabayashi S, Sakurai A, et al. Gradual cranial vault expansion for the treatment of craniofacial synostosis: a preliminary report. *Ann Plast Surg.* 1998;40:554–565.
- Akai T, Iizuka H, Kawakami S. Treatment of craniosynostosis by distraction osteogenesis. *Pediatr Neurosurg.* 2006;42:288–292.
- Hirabayashi S, Sugawara Y, Sakurai A, et al. Frontoorbital advancement by gradual distraction. Technical note. *J Neurosurg.* 1998;89:1058–1061.
- Cho BC, Hwang SK, Uhm KI. Distraction osteogenesis of the cranial vault for the treatment of craniofacial synostosis. *J Craniofac Surg.* 2004;15:135–144.
- Imai K, Komune H, Toda C, et al. Cranial remodeling to treat craniosynostosis by gradual distraction using a new device. *J Neurosurg.* 2002;96:654–659.
- Kim SW, Shim KW, Plesnila N, et al. Distraction vs remodeling surgery for craniosynostosis. *Childs Nerv Syst.* 2007;23:201–206.
- Nishimoto S, Oyama T, Nagashima T, et al. Gradual distraction fronto-orbital advancement with ‘floating forehead’ for patients with syndromic craniosynostosis. *J Craniofac Surg.* 2006;17:497–505.
- Nonaka Y, Oi S, Miyawaki T, et al. Indication for and surgical outcomes of the distraction method in various types of craniosynostosis. Advantages, disadvantages, and current concepts for surgical strategy in the treatment of craniosynostosis. *Childs Nerv Syst.* 2004;20:702–709.
- Winston KR, Ketch LL, Dowlati D. Cranial vault expansion by distraction osteogenesis. *J Neurosurg Pediatr.* 2011;7:351–361.
- Sugawara Y, Uda H, Sarukawa S, et al. Multidirectional cranial distraction osteogenesis for the treatment of craniosynostosis. *Plast Reconstr Surg.* 2010;126:1691–1698.
- Gomi A, Sunaga A, Kamochi H, et al. Distraction osteogenesis update: introduction of multidirectional cranial distraction osteogenesis. *J Korean Neurosurg Soc.* 2016;59:233–241.
- Wauters LD, Miguel-Moragas JS, Mommaerts MY. Classification of computer-aided design-computer-aided manufacturing applications for the reconstruction of cranio-maxillo-facial defects. *J Craniofac Surg.* 2015;26:2329–2333.
- Hatamleh MM, Yeung E, Osher J, et al. Novel treatment planning of hemimandibular hyperplasia by the use of three-dimensional computer-aided-design and computer-aided-manufacturing technologies. *J Craniofac Surg.* 2017;28:764–767.
- Li B, Zhang L, Sun H, et al. A novel method of computer aided orthognathic surgery using individual CAD/CAM templates: a combination of osteotomy and repositioning guides. *Br J Oral Maxillofac Surg.* 2013;51:e239–e244.
- Sasaki R, Rasse M. Mandibular reconstruction using ProPlan CMF: a review. *Craniofacial Trauma Reconstruction Open.* 2017;1:e35–e42.
- Tahiri Y, Taylor JA. In support of using computer-aided design and modeling for periorbital osteotomies. *J Craniofac Surg.* 2015;26:100–103.
- Vannini Dental Industry Protesil labor condensation silicones. Available at http://www.vanninidental.com/products/protesil_labor.html. Accessed March 3, 2017.
- Lim SH, Kim MK, Kang SH. Precision of fibula positioning guide in mandibular reconstruction with a fibula graft. *Head Face Med.* 2016;12:7.
- Ohyama T, Toyoma H, Nagai E, et al. Effectiveness of surgical template for dental implants placed in bone graft. *J Prosthodont Res.* 2009;53:146–149.
- Suchyta MA, Gibreel W, Hunt CH, et al. Using black bone magnetic resonance imaging in craniofacial virtual surgical planning: a comparative cadaver study. *Plast Reconstr Surg.* 2018;141:1459–1470.
- Weijjs WL, Coppens C, Schreurs R, et al. Accuracy of virtually 3D planned resection templates in mandibular reconstruction. *J Craniofacial Surg.* 2016;44:1828–1832.
- Elegbede A, Diaconu SC, McNichols CHL, et al. Office-based three-dimensional printing workflow for craniomaxillofacial fracture repair. *J Craniofac Surg.* 2018;29:e440–e444.
- McAllister P, Watson M, Burke E. A cost-effective, in-house, positioning and cutting guide system for orthognathic surgery. *J Maxillofac Oral Surg.* 2018;17:112–114.
- Jeong JH, Song JY, Kwon GY, et al. The results and complications of cranial bone reconstruction in patients with craniosynostosis. *J Craniofac Surg.* 2013;24:1162–1167.