

COVID-19 is Associated with an Unusual Pattern of Brain Microbleeds in Critically Ill Patients

Aikaterini Fitsiori, Deborah Pugin, Camille Thieffry, Patrice Lalive, and Maria Isabel Vargas

From the Division of Neuroradiology, Diagnostic Department, University Hospitals of Geneva and Faculty of Medicine of Geneva, Geneva, Switzerland (AF, MIV); Division of Intensive Care, Acute Medical Department, University Hospitals of Geneva and Faculty of Medicine of Geneva, Geneva, Switzerland (DP, CT); and Division of Neurology, Department of Clinical Neurosciences, University Hospitals of Geneva and Faculty of Medicine of Geneva, Geneva, Switzerland (PL)

ABSTRACT

BACKGROUND AND PURPOSE: Covid-19, initially described as a respiratory system's infection, is currently more and more recognized as a multiorgan disease, including neurological manifestations. There is growing evidence about a potential neuroinvasive role of SARS-CoV-2. The purpose of this study is to describe new findings, in the form of cerebral microbleeds affecting different brain structures, observed in MRIs of critically ill patients.

METHODS: For this purpose, the MR images of 9 patients with a common pattern of abnormal findings (2 women/7 men; 55-79 years of age; mean age: 67.7 years) were depicted. All patients were tested positive for SARS-CoV-2 and presented with delayed recovery of consciousness or important agitation, requiring brain MRI.

RESULTS: All patients had suffered from severe (5/9) or moderate (4/9) acute respiratory distress syndrome, requiring prolonged stay in the intensive care unit. Their common MRI finding was the presence of microbleeds in unusual distribution with a specific predilection for the corpus callosum. Other uncommon locations of microbleeds were the internal capsule (5/9), as well as middle cerebellar peduncles (5/9). Subcortical regions were also affected in the majority of patients.

CONCLUSIONS: Brain MRI raised evidence that Covid-19 or its related treatment may involve the brain with an unusual pattern of microbleeds, predominantly affecting the corpus callosum. The mechanism of this finding is still unclear but the differential diagnosis should include thrombotic microangiopathy related to direct or indirect—through the cytokine cascade—damage by the SARS-CoV-2 on the endothelium of brain's vessels, as well as mechanisms similar to the hypoxemia brain-blood-barrier injury.

Keywords: Brain, Covid-19, infection, microbleeds, corpus callosum, MRI.

Acceptance: Received May 19, 2020, and in revised form June 23, 2020. Accepted for publication June 24, 2020.

Correspondence: Address correspondence to Maria-Isabel Vargas, Division of Neuroradiology, Diagnostic Department, University Hospitals of Geneva and Faculty of Medicine of Geneva, 4, rue Gabrielle-Perret-Gentil, 1205 Geneva, Switzerland. E-mail: maria.i.vargas@hcuge.ch.

Acknowledgments and Disclosure: The authors declare no conflict of interest regarding the publication of this article. There were no external funding sources for this work.

[Correction statement added on 17 September 2020 after first online publication: the article title was changed to [COVID-19 Is Associated with an Unusual Pattern of Brain Microbleeds in Critically Ill Patients]

J Neuroimaging 2020;30:593-597.

DOI: 10.1111/jon.12755

Introduction

There is currently a severe global public health concern due to a rapidly growing worldwide pandemic of a novel Coronavirus (SARSCoV-2), which has been first isolated in China after a local outbreak of severe respiratory system viral infection.¹ As more and more people are getting infected worldwide, a variety of extrapulmonary manifestations is being described, including gastrointestinal involvement,² cutaneous manifestations,³ as well as atypical manifestations from the sensorial system, specifically anosmia and ageusia.⁴ Symptoms, such as confusion, dizziness, and ataxia, have also been described, but were initially considered as the result of the inflammatory status and the hypoxemia resulting from the Covid-19 pneumonia. After the description of a case of acute hemorrhagic necrotizing encephalopathy in a Covid-19 positive patient,⁵ as well as cases of meningitis,⁶ there is currently increasing research interest about the potential neuroinvasive role of SARS-CoV-2.

Our institution, being the regional reference center for the disease, treats a significant number of Covid-19 patients, some of them presenting with neurological symptoms requiring brain

imaging, especially during weaning from ventilator support. We report nine cases of patients suffering from SARS-CoV-2 infection who underwent brain MRI, which was significant for microbleeds with atypical distribution.

Methods

In this brief report, the MR images of 9 patients (2 women/7 men; 55-79 years of age; mean age: 67.7 years) were depicted. Informed and written consent was obtained for all patients, as well as approval from the regional ethical standards committee. All patients had positive polymerase-chain-reaction assay for SARS-CoV-2 of nasopharyngeal swab and presented with various neurological symptoms requiring brain MRI. Images were obtained either in 1.5T Ingenia MRI (Philips) or 3T Skyra MRI (Siemens) machine, with a protocol, including diffusion weighted imaging, T2WI, T1WI before and after contrast media, fluid-attenuation-inversion-recovery (FLAIR), and susceptibility weighted imaging (SWI). All images were analyzed in consensus by two neuroradiologists.

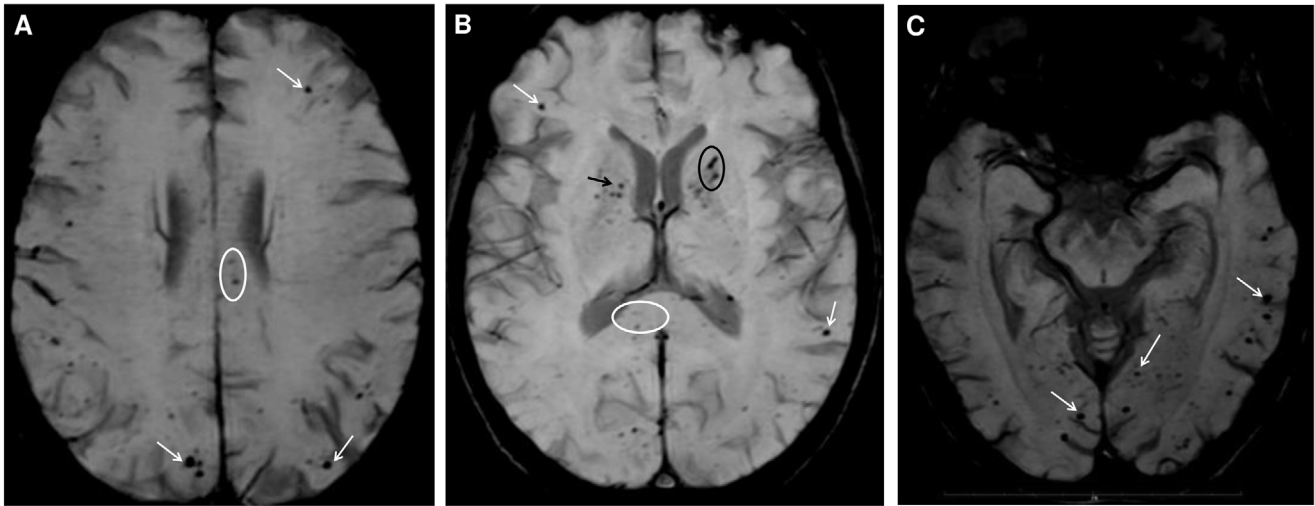


Fig 1. Multiple hypoattenuating foci involving the subcortical white matter (white arrows in A-C), as well as the corpus callosum (white ellipse in A and B), the anterior limb of the internal capsule (black arrow in B) and both middle cerebellar peduncles (not shown here), observed in susceptibility weighted imaging of the brain MRI of a 56-year-old woman. Interestingly, some of the lesions present a more linear shape, opening a differential diagnosis of microthrombi within vessels (black ellipse in B).

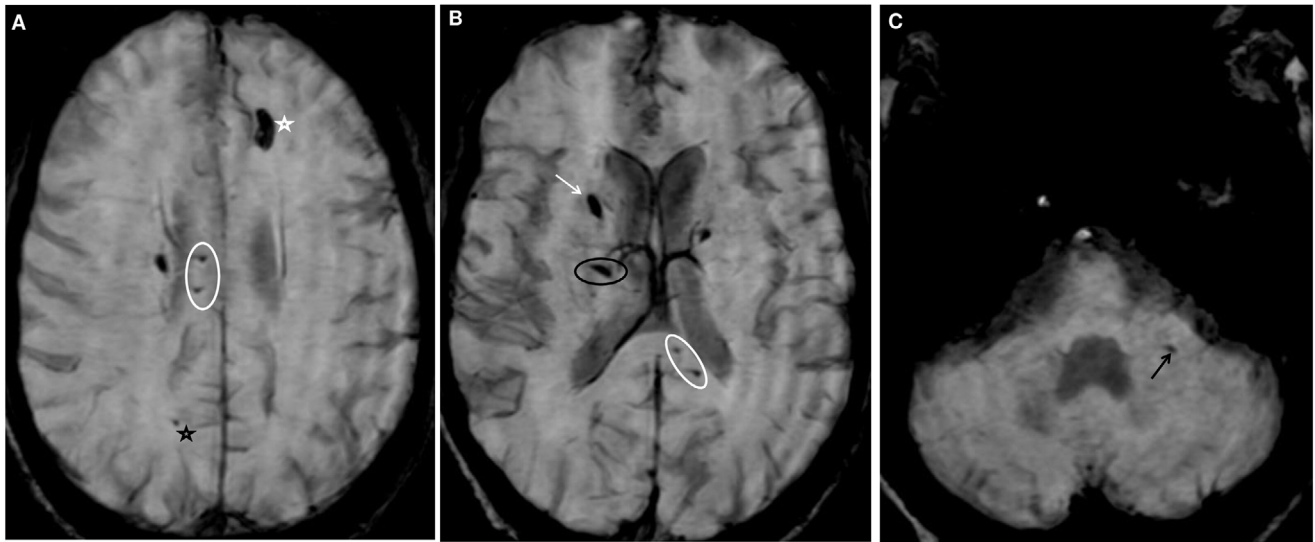


Fig 2. Brain MRI findings of a 66-year-old man include multiple microbleeds, involving the corpus callosum (white ellipse in A and B), the anterior limb of the right internal capsule (white arrow in B), the left middle cerebellar peduncle (black arrow in C), the basal ganglia (black ellipse in B), subcortical white matter (black star in A), as well as one left frontal macrobleed (white star in A). Similarly to the previous patient, some of the lesions appear linear (black ellipse in B).

Results

All patients had suffered from severe (5/9) or moderate (4/9) acute respiratory distress syndrome (ARDS), requiring neuromuscular blockade, deep sedation, and mechanical ventilation with an average stay in the intensive care unit (ICU) of 15.8 days (range: 8-27 days). They received a combination of supportive care and antibiotic/antiviral agents. The most common symptoms at presentation were fever, cough, and dyspnea. The indication for MRI performance was either a delayed recovery of consciousness after cessation of deep sedation, without specific explanation (3/9 patients), either an important psychomotor agitation (resembling a frontal syndrome), unexplained by metabolic disturbance or a withdrawal syndrome from sedation and benzodiazepines (6/9 patients). Their common MRI

finding was the presence of microbleeds in unusual distribution, with a specific predilection for the corpus callosum (CC). Other uncommon locations of microbleeds were the anterior or posterior limbs of internal capsule (five patients), as well as middle cerebellar peduncles (5/9 patients). Subcortical regions were also affected in the majority of patients (7/9). These lesions could only be depicted in SWI sequence as hypoattenuating foci with or without “blooming artifact” (Figs 1 and 2), while T2WI, FLAIR, and T1WI after Gadolinium injection sequences were unrevealing, apart from two patients who also had MRI findings consistent with acute ischemic lesions in the deep or subcortical white matter. Demographical, clinical characteristics, as well as type and duration of treatment and MRI findings of those patients are summarized in Table 1.

Table 1. Demographical and Clinical Characteristics, Type, and Duration of Treatment and MRI Findings of Our Patients

	Patient A	Patient B	Patient C	Patient D	Patient E	Patient F	Patient G	Patient I	Patient J
Age (years)	66	56	76	78	55	79	65	72	62
Gender	M	F	F	M	M	M	M	M	M
Comorbidities	COPD, HIV	Pulmonary emphysema, Hypothyroidism	Waldenström macroglobulinemia	CAD Cardiac valvulopathy, Hypertension, Hypercholesterolemia, Prostate cancer	Hypertension, Obesity, Hiatal hernia, Alcohol Use Disorder	Hypertension	Hypertension, Diabetes, Dyslipidemia, COPD, Sleep Apnea Syndrome	None	Mild Cognitive Impairment, Vitiligo, Obesity
Symptoms at presentation	Fever, productive cough, SOB, myalgias, headache	Fever, productive cough, headache, nausea	Fever, dry cough, SOB	Fever, dry cough, fatigue	Fever, dry cough	Fever, dry cough, SOB, fatigue	SOB	Fever, SOB, abdominal pain, vomiting, fatigue	Fever, dry cough, myalgias, SOB
Duration of mechanical ventilation (days)	14	13	13	17	16	21	8	27	13
Medical treatment type (days)	Co-Amoxicillin(10), Hydroxychloroquin(4), Azithromycin(4), Piperacillin+Tazobactam(2), Azithromycin(4), Lopinavir+Ritonavir(5), Levofloxacin(2), Piperacillin+Tazobactam(7)	Hydroxychloroquin(3), Azithromycin(4), Co-Amoxicillin(2), Levofloxacin(2), Piperacillin+Tazobactam(7)	Hydroxychloroquin(2), Azithromycin(4), Co-Amoxicillin(5), Piperacillin+Tazobactam(5)	Hydroxychloroquin(1), Azithromycin(4), Lopinavir+Ritonavir(5), Co-Amoxicillin(6), Piperacillin+Tazobactam(5), Vancomycin(14), Imipenem(7)	Hydroxychloroquin(3), Azithromycin(4), Lopinavir+Ritonavir(5), Co-Amoxicillin(5), Piperacillin+Tazobactam(4), Vancomycin(14)	Hydroxychloroquin(3), Azithromycin(4), Co-Amoxicillin(4), Piperacillin+Tazobactam(7)	Hydroxychloroquin(1), Azithromycin(4), Co-Amoxicillin(4), Cefotaxim(2), Amikacin(1), Piperacillin+Tazobactam(10), Remdesivir(8)	Co-Amoxicillin(6), Hydroxychloroquin(1), Piperacillin+Tazobactam(5), Azithromycin(3), Lopinavir+Ritonavir(2), Daptomycin(5), Imipenem+Clasatin(6), Aciclovir(7)	Co-Amoxicillin(2), Hydroxychloroquin(1), Piperacillin+Tazobactam(8), Azithromycin(5), Cefepim
Indication for MRI	Confusion, agitation	Confusion, agitation	Delayed recovery of consciousness	Confusion, agitation	Confusion, agitation	Delayed recovery of consciousness	Confusion	Delayed recovery of consciousness	Increasing confusion
Time interval from onset of Covid-19 to MRI (number of days)	29	28	24	23	21	27	40	41	26
Timing of MRI (day after intubation)	16 th	18 th	14 th	13 th	19 th	16 th	31 st	30 th	32 nd
MRI findings	Microbleeds in SWM, CC, Basal Ganglia, right ALIC, left MCP	Microbleeds in SWM, CC, SP, Basal Ganglia, both ALIC, both MCP	Microbleeds in the CC, SWM, a left parietal hemorrhagic sequella	Microbleeds in SWM CC, left MCP, sequella of a lacunar infarct in the external capsule	Microbleeds in the CC	Microbleeds in SWM, CC	Two acute lacunar infarcts in SWM, microbleeds in CC, MCP, PLIC, SWM, sequella of central pontine myelinolysis	Acute infarct in the centrum semi-ovale, microbleeds in the CC, SWM, PLIC, left MCP, cerebellum	Microbleeds in the CC, PLIC, Atrophy

Abbreviations: #, number; M, male; F, female; COPD, chronic obstructive pulmonary disease; HIV, human immunodeficiency virus; CAD, coronary artery disease; SOB, shortness of breath; SWM, subcortical white matter; CC, corpus callosum; ALIC, anterior limb of internal capsule; MCP, middle cerebellar peduncle; SP, septum pellucidum; PLIC, posterior limb of internal capsule.

Discussion

With this report, we want to draw attention to a potential new radiological manifestation of the Covid-19 or its related treatment, observed in the brain of critically ill patients. This observation was made in brain MRIs of Covid-19 patients, performed in our institution for two different neurological patterns: agitation or delayed recovery of consciousness, when patients were withheld from sedation after severe or moderate ARDS. In all nine patients, microbleeds were present in atypical locations, including the CC, internal capsule, middle cerebellar peduncles, as well as in more typical locations, such as the subcortical white matter.

These findings are a distinct entity from the most common causes of brain microbleeds, hypertension, and amyloid angiopathy, because of the atypical involvement of CC in these two entities, as well as because of nonconsistent demographical and clinical data. Furthermore, during the ICU stay monitoring, only short episodes of acute hypertension (up to 180 mmHg) were registered in 2/9 patients, rapidly and successfully treated with antihypertensives. Although our knowledge about the physiopathology of the Covid-19 is still limited, a hypothetic mechanism to explain our findings could be a direct damage of the SARS-CoV-2 to the endothelium of the brain vessels, as already suggested by Li et al⁷ and Baig et al.⁸ According to the latter, an interaction of the viral particles with the angiotensin-converting enzyme 2 receptors on the capillary endothelium of the brain could lead to blood-brain-barrier damage and bleeding within the brain tissue. Furthermore, there are some recent papers suggesting a potential propensity of the SARS-CoV-2 for the central nervous system (CNS), based on its structural similarity with the SARS-CoV, which has already been described as neurotropic,⁹ as well as description of other viruses causing brain hemorrhage.¹⁰ Some of the lesions had a linear shape, resembling to a vessel, which could alternatively represent microthrombi within small vessels. This is consistent with the hypercoagulable status of all our patients, as well as recent findings of microthrombi within pulmonary vessels in autopsy of Covid-19 patients.¹¹

On the other hand, this distribution of microbleeds has been described as the result of diffuse axonal injury or fat embolism,¹² as well as in patients who have been treated with extracorporeal membrane oxygenation (ECMO),¹³ but none of our patients had a history of brain trauma, bone injury, or ECMO treatment. The common clue of all our patients was the severe hypoxemia, secondary to ARDS, which required a prolonged mechanical ventilation and administration of various antiviral and antibiotic agents. These findings closely resemble to the findings of Fanou et al,¹² who described a series of critically ill patients, who were treated with mechanical ventilation and in whom the same characteristic microbleed phenomenon was observed, as well as the CC involvement in patients with ARDS described by Riech et al.¹⁴ Fanou et al¹² suggested a possible pathogenetic mechanism related to the hypoxemia blood-brain-barrier damage, similarly to the damage related to high-altitude exposure or alternatively a damage related to diffuse intravascular coagulation (DIC). However, none of our patients suffered from DIC or compensated DIC. On the contrary, our patients presented a hyperfibrinemic state as well as septic/inflammatory coagulopathy, as already reported in Covid-19 patients.¹⁵ Of note, all of the patients have received anticoagulation treatment in prophylactic

(7/9 patients) or therapeutic (2/9 patients) doses. Finally, we have found no data about brain hemorrhage due to hydroxychloroquine or azithromycin administration, received by all of our patients.

Our study has certain limitations, being a retrospective study in a limited number of patients. Brain MRI was performed only in severely ill patients presenting with atypical neurological symptoms and not as a systematic imaging surveillance of Covid-19 patients, due to the workload of our hospital during the pandemic, as well as difficulties in performing MRI in ventilated Covid-19 patients, related to their fragile health status and the risk of contamination. Furthermore, our study only included patients presenting with severe neurological manifestations and not patients with milder encephalopathies or other neurological alterations, such as dysexecutive syndrome, frontal syndrome, or delirium per se, which could also be related to lesions of the CC, the anterior limb of the internal capsule, or the subcortical regions, as those seen in our study. Finally, considering the pandemic situation, neuropsychological evaluation was not available for these patients to assess their mental status before their intubation, which can also be a caveat for our study.

Although microbleeds and/or microthrombi's etiology remains unclear, this observation could highlight a potential brain involvement during the course of the Covid-19 infection or relative to its treatment and explain some of the neurological manifestations observed in these patients. In particular, the alterations of consciousness have been reported in callosal injuries,¹⁶ while the anterior limb of the internal capsule involvement could explain the frontal signs, also observed in some of the patients. Indisputably, our knowledge about the disease is still limited and further research is required, as well as pathologic studies to confirm and better understand those findings in the brain and other organs of Covid-19 patients. A timely understanding of the relationship between the SARS-CoV-2 and the CNS is of great importance for an optimal approach of the disease.

References

1. Wu F, Zhao S, Yu B, et al. A new coronavirus associated with human respiratory disease in China. *Nature* 2020;579:265-9.
2. Li LY, Wu W, Chen S, et al. Digestive system involvement of novel coronavirus infection: prevention and control infection from a gastroenterology perspective. *J Dig Dis* 2020;31:199-204.
3. Recalcati S. Cutaneous manifestations in COVID-19: a first perspective. *J Eur Acad Dermatol Venereol* 2020;34:e213-4.
4. Vaira LA, Salzano G, Deiana G, et al. Anosmia and ageusia: common findings in COVID-19 patients. *Laryngoscope* 2020. 130:1787.
5. Poyiadji N, Shahin G, Noujaim D, et al. Covid-19 acute hemorrhagic necrotizing encephalopathy: CT and MRI features. *Radiology* 2020. <https://doi.org/10.1148/radiol.2020201187>.
6. Moriguchi T, Harii N, Goto J, et al. A first case of meningitis/encephalitis associated with SARS-Coronavirus-2. *Int J Infect Dis* 2020;94:55-8.
7. Li Z, Huang Y, Guo X. The brain, another potential target organ, needs early protection from SARS-CoV-2 neuroinvasion. *Sci China Life Sci* 2020;2:2-4.
8. Baig AM, Khaleeq A, Ali U, et al. Evidence of the COVID-19 virus targeting the CNS: tissue distribution, host-virus interaction, and proposed neurotropic mechanisms. *ACS Chem Neurosci* 2020;11:995-8.

9. Li Y-C, Bai W-Z, Hashikawa T. The neuroinvasive potential of SARS-CoV2 may play a role in the respiratory failure of COVID-19 patients. *J Med Virol* 2020. <http://doi:10.1002/jmv.25728>.
10. Shinya A, Makino A, Hatta M, et al. Subclinical brain injury caused by H5N1 influenza virus infection. *J Virol* 2011;85:5202-7
11. Dolhnikoff M, Duarte-Neto AN, de Almeida Monteiro RA, et al. Pathological evidence of pulmonary thrombotic phenomena in severe COVID-19. *J Thromb Haemost* 2020;18:1517-19.
12. Fanou EM, Coutinho JM, Shannon P, et al. Critical illness-associated cerebral microbleeds. *Stroke* 2017;48:1085-7.
13. Le Guennec L, Bertand A, Laurent C, et al. Diffuse cerebral microbleeds after extracorporeal membrane oxygenation support. *Am J Respir Crit Care Med* 2015;191:594-6.
14. Riech S, Kallenberg K, Moerer O, et al. The pattern of brain microhemorrhages after severe failure resembles the one seen in high-altitude cerebral edema. *Crit Care Med* 2015;43:e386-9.
15. Connors JM, Levy JH. Covid-19 and its implications for thrombosis and anticoagulation. *Blood* 2020;135:2033-240.
16. Huang LC, Wu MN, Chen CH, et al. Susceptibility weighted imaging in patient with consciousness disturbance after traffic accident. *Am J Emerg Med* 2013;31:261.