



Sperm Vitality and Necrozoospermia: Diagnosis, Management, and Results of a Global Survey of Clinical Practice

Ashok Agarwal¹, Rakesh K. Sharma¹, Sajal Gupta¹, Florence Boitrelle^{2,3}, Renata Finelli¹, Neel Parekh⁴, Damayanthi Durairajanayagam⁵, Ramadan Saleh⁶, Mohamed Arafa^{1,7,8}, Chak Lam Cho⁹, Ala'a Farkouh¹, Amarnath Rambhatla¹⁰, Ralf Henkel^{11,11,12,13}, Paraskevi Vogiatzi¹⁴, Nicholas Tadros¹⁵, Parviz Kavoussi¹⁶, Edmund Ko¹⁷, Kristian Leisegang¹⁸, Hussein Kandil¹⁹, Ayad Palani²⁰, Gianmaria Salvio²¹, Taymour Mostafa²², Osvaldo Rajmil²³, Saleem Ali Banihani²⁴, Samantha Schon²⁵, Tan V. Le^{26,27}, Ponco Birowo²⁸, Gökhan Çeker²⁹, Juan Alvarez³⁰, Juan Manuel Corral Molina³¹, Christopher C.K. Ho³², Aldo E. Calogero³³, Kareim Khalafalla⁷, Mesut Berkan Duran³⁴, Shinnosuke Kuroda¹, Giovanni M. Colpi³⁵, Armand Zini³⁶, Christina Anagnostopoulou³⁷, Edoardo Pescatori³⁸, Eric Chung^{39,40}, Ettore Caroppo⁴¹, Fotios Dimitriadis⁴², Germar-Michael Pinggera⁴³, Gian Maria Busetto⁴⁴, Giancarlo Balercia²¹, Haitham Elbardisi^{7,8}, Hisanori Taniguchi⁴⁵, Hyun Jun Park^{46,47}, Israel Maldonado Rosas⁴⁸, Jean de la Rosette⁴⁹, Jonathan Ramsay⁵⁰, Kasonde Bowa⁵¹, Mara Simopoulou⁵², Marcelo Gabriel Rodriguez⁵³, Marjan Sabbaghian⁵⁴, Marlon Martinez⁵⁵, Mohamed Ali Sadighi Gilani⁵⁴, Mohamed S. Al-Marhoon⁵⁶, Raghavender Kosgi⁵⁷, Rossella Cannarella³³, Sava Micic⁵⁸, Shinichiro Fukuhara⁵⁹, Sijo Parekattil⁶⁰, Sunil Jindal⁶¹, Taha Abo-Elmagd Abdel-Meguid^{62,63}, Yoshiharu Morimoto⁶⁴, Rupin Shah⁶⁵

¹American Center for Reproductive Medicine, Cleveland Clinic, Cleveland, OH, USA, ²Reproductive Biology, Fertility Preservation, Andrology, CECOS, Poissy Hospital, Poissy, France, ³Paris Saclay University, UVSQ, INRAE, BREED, Jouy-en-Josas, France, ⁴Department of Urology, Cleveland Clinic, Cleveland, OH, USA, ⁵Department of Physiology, Faculty of Medicine, Universiti Teknologi MARA, Sungai Buloh Campus, Selangor, Malaysia, ⁶Department of Dermatology, Venereology and Andrology, Faculty of Medicine, Sohag University, Sohag, Egypt, ⁷Department of Urology, Hamad Medical Corporation, Doha, Qatar, ⁸Department of Urology, Weill Cornell Medical-Qatar, Doha, Qatar, ⁹SH Ho Urology Center, Department of Surgery, Chinese University of Hong Kong, Hong Kong, ¹⁰Department of Urology, Vattikuti Urology Institute, Henry Ford Health System, Detroit, MI, USA, ¹¹Department of Metabolism, Digestion and Reproduction, Imperial College London, London, UK, ¹²Department of Medical Bioscience, University of the Western Cape, Bellville, South Africa, ¹³LogixX Pharma, Theale, Berkshire, UK, ¹⁴Andromed Health & Reproduction, Fertility Diagnostics Laboratory, Maroussi, Greece, ¹⁵Division of Urology, Southern Illinois University School of Medicine, Springfield, IL, USA, ¹⁶Austin Fertility and Reproductive Medicine/Westlake IVF, Department of Urology, University of Texas Health Science Center at San Antonio, San Antonio, TX, USA, ¹⁷Department of Urology, Loma Linda University Health, Loma Linda, CA, USA, ¹⁸Department of Physiology, School of Natural Medicine, Faculty of Community and Health Sciences, University of the Western Cape, Bellville, South Africa, ¹⁹Fakih IVF Fertility Center, Abu Dhabi, UAE, ²⁰Department of Biochemistry, College of Medicine, University of Garmian, Kalar, Iraq, ²¹Department of Endocrinology and Metabolic Diseases, Polytechnic University of Marche, Ancona, Italy, ²²Department of Andrology, Sexology and STIs, Faculty of Medicina, Cairo University, Cairo, Egypt, ²³Department of Andrology, Fundacio Puigvert, Barcelona, Spain, ²⁴Department of Medical Laboratory Sciences, Faculty of Applied Medical Sciences, Jordan University of Science and Technology, Irbid, Jordan, ²⁵Division of Reproductive Endocrinology and Infertility, Department of Obstetrics and Gynecology, University of Michigan, Ann Arbor, MI, USA, ²⁶Department of Andrology and Urology, Pham Ngoc Thach University of Medicine, Ho Chi Minh City, Viet Nam, ²⁷Department of Andrology, Binh Dan Hospital, Ho Chi Minh City, Viet Nam, ²⁸Department of Urology, Cipto Mangunkusumo General Hospital, Faculty of Medicine, Universitas Indonesia, Jakarta, Indonesia, ²⁹Department of Urology,

Received: Jul 5, 2021 Revised: Aug 2, 2021 Accepted: Aug 5, 2021 Published online Oct 13, 2021

Correspondence to: Ashok Agarwal  <https://orcid.org/0000-0003-0585-1026>

Andrology Center and American Center for Reproductive Medicine, Cleveland Clinic, Mail Code X-11, 10681 Carnegie Avenue, Cleveland, OH 44195, USA.

Tel: +1-216-444-9485, Fax: +1-216-445-6049, E-mail: agarwaa@ccf.org, Website: www.clevelandclinic.org/ReproductiveResearchCenter

Samsun Vezirköprü State Hospital, Samsun, Turkey, ³⁰Centro ANDROGEN, La Coruña, Spain, ³¹Servicio de Urología, Hospital Clínico de Barcelona. Barcelona, Spain, ³²Department of Surgery, School of Medicine, Faculty of Health and Medical Sciences, Taylor's University, Subang Jaya, Malaysia, ³³Department of Clinical and Experimental Medicine, University of Catania, Catania, Italy, ³⁴Department of Urology, Samsun Training and Research Hospital, Samsun, Turkey, ³⁵Andrology and IVF Unit, Procrea Institute, Lugano, Switzerland, ³⁶Department of Surgery, McGill University, Montreal, QC, Canada, ³⁷IVF Clinic "Akeso-Embryo ART", Athens, Greece, ³⁸Andrology and Reproductive Medicine Unit, Gynepro Medical, Bologna, Italy, ³⁹Department of Urology, Princess Alexandra Hospital, University of Queensland, Brisbane, QLD, Australia, ⁴⁰AndroUrology Centre, Brisbane, QLD, Australia, ⁴¹Reproductive and IVF Unit, Andrology Outpatients Clinic, ASL Bari, Conversano (Ba), Italy, ⁴²1st Urology Department, School of Medicine, Aristotle University, Thessaloniki, Greece, ⁴³Department of Urology, Innsbruck Medical University, Innsbruck, Austria, ⁴⁴Department of Urology and Renal Transplantation, University of Foggia, Ospedali Riuniti of Foggia, Foggia, Italy, ⁴⁵Department of Urology and Andrology, Kansai Medical University, Hirakata, Osaka, Japan, ⁴⁶Department of Urology, Pusan National University School of Medicine, Busan, Korea, ⁴⁷Medical Research Institute of Pusan National University Hospital, Busan, Korea, ⁴⁸Citmer Reproductive Medicine, IVF LAB, Mexico City, Mexico, ⁴⁹Department of Urology, Medipol Mega University Hospital, Istanbul, Turkey, ⁵⁰Department of Andrology, Hammersmith Hospital, London, UK, ⁵¹Department of Urology, Michael Chilufya Sata Copperbelt University School of Medicine, Ndola, Zambia, ⁵²Department of Experimental Physiology, School of Health Sciences, Faculty of Medicine, National and Kapodistrian University of Athens, Athens, Greece, ⁵³Departamento Docencia e Investigación, Hospital Militar Campo de Mayo, Universidad Barcelo, Buenos Aires, Argentina, ⁵⁴Department of Andrology, Reproductive Biomedicine Research Center, Royan Institute for Reproductive Biomedicine, ACECR, Tehran, Iran, ⁵⁵Section of Urology, University of Santo Tomas Hospital, Manila, Philippines, ⁵⁶Department of Surgery, Urology Division, Sultan Qaboos University, Muscat, Oman, ⁵⁷Department of Urology and Andrology, AIG Hospitals, Gachibowli, Hyderabad, India, ⁵⁸Department of Andrology, Uromedica Polyclinic, Belgrade, Serbia, ⁵⁹Department of Urology, Graduate School of Medicine, Osaka University, Osaka, Japan, ⁶⁰Avant Concierge Urology & University of Central Florida, Winter Garden, FL, USA, ⁶¹Department of Andrology and Reproductive Medicine, Jindal Hospital, Meerut, India, ⁶²Department of Urology, Faculty of Medicine, Minia University, Minia, Egypt, ⁶³Department of Urology, Faculty of Medicine, King Abdulaziz University, Jeddah, Saudi Arabia, ⁶⁴HORAC Grand Front Osaka Clinic, Osaka, Japan, ⁶⁵Division of Andrology, Department of Urology, Lilavati Hospital and Research Centre, Mumbai, India

Sperm vitality testing is a basic semen examination that has been described in the World Health Organization (WHO) Laboratory Manual for the Examination and Processing of Human Semen from its primary edition, 40 years ago. Several methods can be used to test sperm vitality, such as the eosin-nigrosin (E-N) stain or the hypoosmotic swelling (HOS) test. In the 6th (2021) edition of the WHO Laboratory Manual, sperm vitality assessment is mainly recommended if the total motility is less than 40%. Hence, a motile spermatozoon is considered alive, however, in certain conditions an immotile spermatozoon can also be alive. Therefore, the differentiation between asthenozoospermia (pathological decrease in sperm motility) and necrozoospermia (pathological decrease in sperm vitality) is important in directing further investigation and management of infertile patients. The causes leading to necrozoospermia are diverse and can either be local or general, testicular or extra-testicular. The andrological management of necrozoospermia depends on its etiology. However, there is no standardized treatment available presently and practice varies among clinicians. In this study, we report the results of a global survey to understand current practices regarding the physician order of sperm vitality tests as well as the management practices for necrozoospermia. Laboratory and clinical scenarios are presented to guide the reader in the management of necrozoospermia with the overall objective of establishing a benchmark ranging from the diagnosis of necrozoospermia by sperm vitality testing to its clinical management.

Keywords: Asthenozoospermia; Eosine Yellowish-(YS); Infertility; Nigrosin; Spermatozoa; Vitality

This is an Open Access article distributed under the terms of the Creative Commons Attribution Non-Commercial License (<http://creativecommons.org/licenses/by-nc/4.0>) which permits unrestricted non-commercial use, distribution, and reproduction in any medium, provided the original work is properly cited.

INTRODUCTION

Sperm vitality, assessed by eosin-nigrosin (E-N) stain, refers to the integrity and permeability of the cell membrane, while sperm viability, assessed by hypoosmotic swelling (HOS) test, refers to the percentage of live spermatozoa in the semen. In laboratory practice,

however, the terms "vitality" and "viability" are commonly used interchangeably [1] as they both refer to sperm membrane function and thereby whether or not the male germ cell is dead or alive. The assessment of human sperm vitality is an important parameter of basic semen analysis [2-4]. This test is commonly conducted in andrology laboratories and assisted reproduc-

tive technology (ART) clinics and the methodology is described in the 5th (2010) edition of the World Health Organization (WHO) Laboratory Manual for the Examination and Processing of Human Semen [5]. In this 5th edition, it is stated that sperm vitality testing is possible on all semen samples but is mainly recommended if the progressive motility is lower than 40%. The choice of a progressive motility threshold is surprising and confusing. Indeed, a spermatozoon, even a non-progressive motile one, can be alive. Moreover, the threshold of 40% corresponds to the reference threshold of total motility [3,5,6]. Both these arguments have been addressed in the latest (6th) edition of the WHO manual, available since July 2021. According to the 6th edition, it is not necessary to assess vitality when at least 40% of spermatozoa are motile [7]. Thus, in this article, we will describe the sperm vitality test as necessary if total motility is below 40%.

Regarding the definition of necrozoospermia, the WHO 5th edition states that the lower reference threshold of sperm vitality is set at 58%. Normal sperm vitality is applied to samples with $\geq 58\%$ (5th centile; 95% confidence interval [CI], 55%–63%) alive spermatozoa [5]. Thus, necrozoospermia was defined as the

presence of less than 58% of alive spermatozoa in semen. The 6th edition of the WHO manual has removed the standards and reference values, arguing that the boundaries between sperm from infertile and fertile men were not as clear [7].

Vitality should be examined in conjunction with motility in the same sample. The purpose of assessing both sperm vitality and motility is to clarify whether immotile spermatozoa seen in ejaculates with low sperm motility are dead or alive (Table 1). Vitality testing can also provide a counter-check on the motility evaluation, since the percentage of dead cells should not exceed (within sampling error) the percentage of immotile spermatozoa [5]. The importance of a proper diagnosis must be emphasized here as the management of asthenozoospermia is different from that of necrozoospermia in many instances, which is why a clear discrimination should be pursued.

The most commonly used method to assess sperm vitality is the combined E-N stain [7]. The prevalence of its use at the College of American Pathologists (CAP) certified clinics and laboratories across the United States is 62.8% (359/572) (CAP Proficiency report, May 2021; Supplement File 1). The E-N test is automati-

Table 1. Summary of the clinical and laboratory aspects pertaining to necrozoospermia

Testing for necrozoospermia
<p>Indication: if total sperm motility is less than 40%</p> <p>Importance: in order to distinguish whether the immotile spermatozoa are dead (necrozoospermia) or are alive but with abnormal motility (asthenozoospermia), as this will have clinical implications in terms of approach and management</p> <p>Methods:</p> <ul style="list-style-type: none"> • Eosin-nigrosin staining: dead sperm heads are stained dark pink or red – all tested sperm are damaged and can no longer be used for ART • HOS test: live sperm tails become swollen – sperm is not damaged and can be used for ART
Causes and risk factors of necrozoospermia
<ul style="list-style-type: none"> • Genital tract infections – the most common cause • Testicular hyperthermia – local or systemic (such as fever) • Varicocele • Hyperthyroidism • Spinal cord injury • Polycystic kidney disease • Antisperm antibodies • Advanced male age • Toxic substances – such as: tobacco, cannabis, pesticides • Idiopathic <p>Note: Should always rule out false results due to lubricant use or contamination of semen sample with antiseptic solution, soap, or water</p>
Management of necrozoospermia
<ul style="list-style-type: none"> • Avoiding and treating underlying risks and conditions • Frequent ejaculation • Absolute asthenozoospermia: consider the diagnosis of flagellar dyskinesia - perform HOS test or use enhancers of sperm motility and select viable sperm for ICSI • Absolute necrozoospermia: consider SDF testing if ejaculated live sperm are to be used in ICSI, testicular sperm extraction followed by ICSI

ART: assisted reproductive technology, HOS: hypoosmotic swelling, ICSI: intracytoplasmic sperm injection, SDF: sperm DNA fragmentation.

cally conducted by the laboratory technologist within the requirements of a basic semen analysis in cases of asthenozoospermia (<40% total motility). For this test, eosin is used as a vitality dye in the evaluation of the integrity of the sperm membrane. An intact membrane will not be penetrated by eosin, unlike compromised membranes of dead sperm. One of the drawbacks of the E-N test is that stained spermatozoa cannot be used in subsequent procedures, namely in ART. Therefore, in such cases sperm viability should be tested in a manner which is not detrimental to the spermatozoa to be used in ART. The HOS test, for example, is compatible with fertilization procedures [1,8-11].

In the current review article, we describe the technical characteristics of sperm vitality tests and discuss the etiology and management of necrozoospermia. We also present laboratory and clinical scenarios on the relevance, utilization, and significance of sperm vitality testing. Additionally, we provide the results of a short global survey on the current practice patterns of sperm vitality testing among infertility specialists.

SPERM VITALITY ASSESSMENT

Sperm vitality assessment should be performed with an abstinence period of 2 to 7 days [7]. The patient collects the specimen into a sterile container. The semen

sample should be stored at 37°C and the sperm vitality test must be performed after liquefaction within 30 minutes to one hour after collection. This prevents the deleterious effects of dehydration and temperature on sperm vitality [7].

1. Eosin-nigrosin staining

The most commonly used method to assess sperm vitality is the combined E-N stain. In this method, eosin is a supravital stain and nigrosin is a purple dye that serves as a counterstain [7]. Here we describe the step-by-step protocol for performing the vitality test (Fig. 1) along with the reagents, consumables, and equipment required (Fig. 2).

The E-N stain is prepared by dissolving 0.67 g of eosin Y and 0.9 g of sodium chloride (NaCl) in 100 mL of distilled water and this mixture is then placed on a hot plate to undergo gentle heating. Then 10 g of nigrosin is added to 100 mL of eosin Y solution. The suspension is boiled, then allowed to cool to room temperature. It is next filtered through a filter paper to remove coarse and gelatinous precipitates. The E-N stain is stored in a sealed dark-glass bottle.

To perform the vitality test, two frosted slides are labeled with patient's name, medical record number, and date. Fifty microliters of well-mixed semen are placed into a Boerner slide well (or a test-tube) and equal

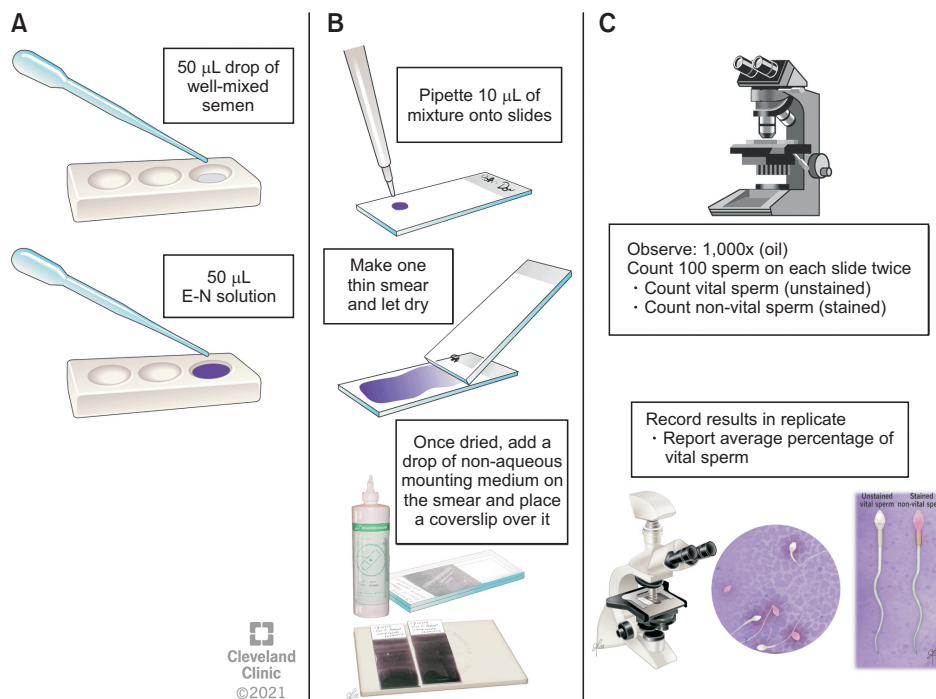


Fig. 1. Schematics of the steps involved in conducting the vitality test. (A) Fifty microliters of well-mixed semen is placed into a Boerner slide well. Equal volume of E-N stain is added. The sample is mixed well with a wooden stirrer, and left to sit for 30 seconds. (B) Immediately after that, ten microliters of the mixture is placed on the labeled frosted slide and a thin smear is made. Perform this step in duplicate. Once the smear is air-dried, a coverslip is placed on the mounting media. (C) A drop of immersion oil is placed on each of the mounted slides. One hundred spermatozoa are observed under bright-field microscopy with 1,000x magnification. This step is performed twice on each slide. The vital (unstained) and non-vital (stained) sperm are counted. Results are recorded in replicate and the average percentage of vital sperm is reported.

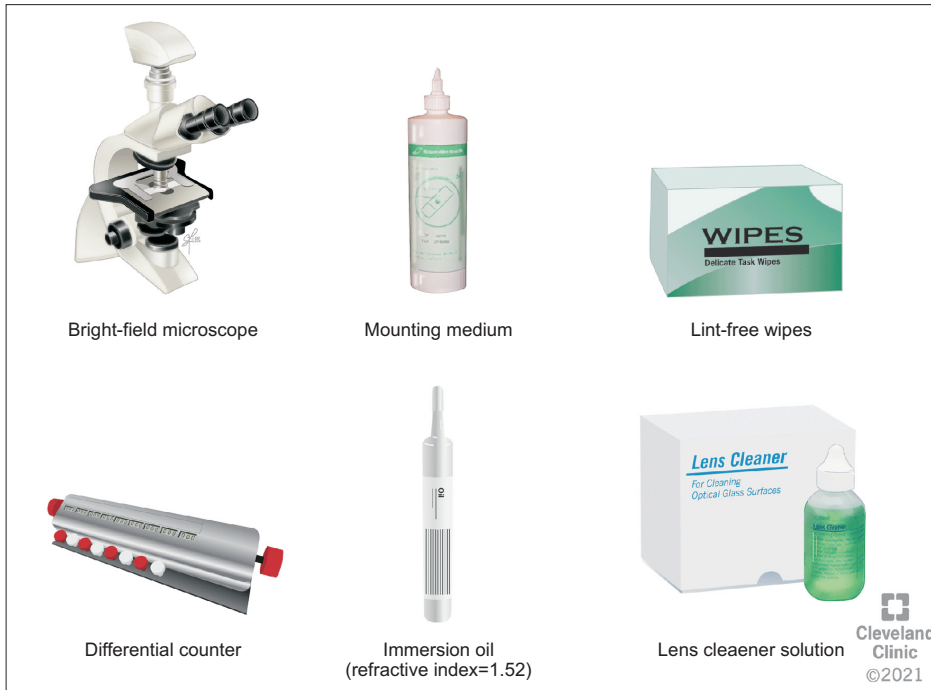

Fig. 2. Equipment, reagents, and consumables, required for components of the eosin-nigrosin test.

volume of E-N stain is added, and the sample is mixed well with a wooden stirrer, then it is let to settle for 30 seconds (Fig. 1A).

The nigrosin stain provides a dark background that makes it easier to distinguish faintly stained spermatozoa. Immediately two thin smears are made by pipetting 10 μ L of the mixture and placing on each of the labeled slide. After air-drying the smear, a coverslip is placed on the non-aqueous mounting media (Fig. 1B). A drop of immersion oil (refractive index=1.52) is placed on the mounted slide, and spermatozoa are observed with 100 \times objective and a 10 \times eye-piece at a total magnification of 1,000 \times under a bright-field microscopy (Fig. 1C). White or faint pink sperm heads indicate vital spermatozoa (Fig. 3A, 3B), while red or dark pink heads indicate non-vital spermatozoa (Fig. 3C). If the stain is limited only to a part of the neck region, and the rest of the head area is unstained (Fig. 3B), this is considered a “leaky neck membrane”, and it is not a sign of cell death and total membrane disintegration. These cells should be assessed as alive. Routine method of counting at least 200 spermatozoa gives sufficiently accurate results for the intended clinical purpose of establishing whether the immotile spermatozoa seen in the ejaculate with low sperm motility are alive or not [12]. The percentage of vital sperm is reported.

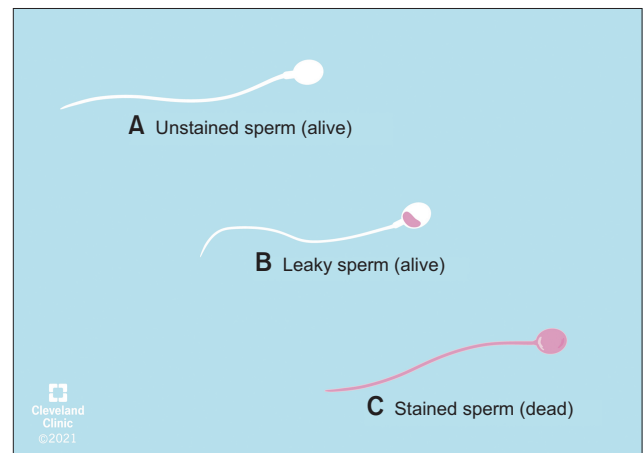


Fig. 3. Schematic representation of alive (A, B) and dead sperm (C) after eosin-nigrosin staining.

2. Hypoosmotic swelling test

This test evaluates the functional integrity of the sperm plasma membrane and also serves as a useful indicator of fertility potential [8]. Functional integrity can be demonstrated by allowing sperm to react in a hypoosmotic medium. The membrane is semi-permeable in live cells, therefore cells with intact membranes (live cells) will swell in hypotonic solutions. The HOS test has high reproducibility and accuracy and is closely correlated to the *in vitro* fertilizing ability of spermato-

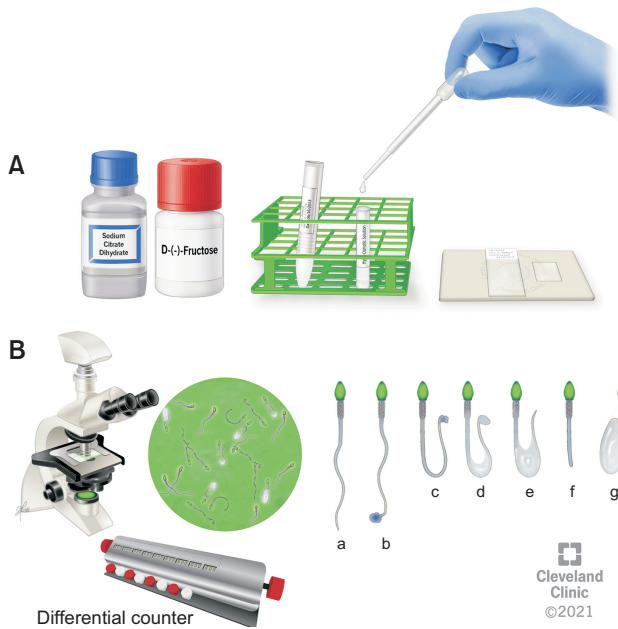


Fig. 4. (A) Components of the hypoosmotic swelling test. (B) Semen sample observation under a phase contrast microscope 40× objective and 10× eye piece, and sperm differentiation according to tail swelling. (a) Non-swollen tail of a dead spermatozoon. (b–g) Different patterns of swollen tails of alive spermatozoa.

zoa [13,14].

For HOS testing, a hypoosmotic solution is prepared by adding 0.735 g sodium citrate dehydrate and 1.351 g D-fructose in 100 mL of distilled water. A well-mixed 0.1 mL aliquot of semen is mixed with 1 mL HOS solution (Fig. 4). The sample is mixed gently by continuous pipette suction and release and incubated at 37°C for 30 minutes. Following incubation, 1 drop of the semen mixture is placed on a glass slide with a coverslip. This test is performed as a duplicate. The percentage of spermatozoa demonstrating tail swelling (Fig. 4A) are counted under 40× phase contrast lens. A total assessment of 200 spermatozoa for tail swelling/coiling is performed using a 2-channel differential cell counter. The average percentage of live sperm showing tail swelling is calculated. The normal threshold is $\geq 58\%$ (95% CI, 55%–63%) of spermatozoa with tail swelling (Fig. 4B) according to the guidelines in the WHO 5th edition manual [5].

3. Quality control and quality assurance

1) Quality control of the eosin-nigrosin stain and hypoosmotic swelling reagents

For E-N staining, a monthly patient quality control

(QC) is required to check the quality of the stain. A QC step is performed each time new reagents are prepared. This must be performed before a new stain is used to test further patient specimens [15]. The total motility of the specimen should be assessed prior to the QC protocol. The specimen should be stained with both the old lot of stain as well as the new lot. Both sets of slides should be scored for sperm vitality. The percentage of viable sperm should be greater than or equal to the total motility of the specimen used. The comparison of the 2 lots of reagents should be within 10% of each other. If results are not within the acceptable range, the staining must be repeated using another specimen [15]. Similarly, when a new HOS reagent is prepared, QC must be performed before they can be used to test further semen samples. A positive control is prepared using a normal semen sample and run monthly or when a fresh reagent is prepared with a result of $\geq 58\%$ to verify that the HOS reagents meet the criteria and can be used for patient testing. All results need to be verified and recorded when the control is run.

2) Internal quality control

Both vitality and viability slides are scored by two observers (RKS and SG) and the results are compared. A Bland–Altman plot can be used to check the correlation of inter-technician sperm vitality results.

3) External quality control

Two control vitality slides are prepared by accreditation laboratories and are assessed every six months for external QC. The designated technologist scores at least 200 spermatozoa and records results on the data sheet as percent viable. Results should be within ± 2 standard deviation of mean for all laboratories as reported by the accreditation agency. Corrective action must be undertaken if the results are not within the specified range. The technologist will have to be retrained in the test and then instructed to re-score the proficiency slides [15].

LABORATORY SCENARIOS

Some laboratory issues may be encountered during the preparation and scoring of the smears for vitality. Recommendations for troubleshooting are illustrated in the following scenarios.

1. Case A

1) Scenario

A 28-year-old patient provides a semen sample for laboratory evaluation. Upon examination, the sperm parameters are (1) volume, 3.3 mL; (2) concentration, $37 \times 10^6/\text{mL}$; (3) total motility, 15%. How will you proceed?

2) Solution

Total motility is below 40%. Prepare the slides by following the steps for E-N staining. The percentage of vital and non-vital spermatozoa must be counted and compared with motility. The vitality results must be equal to or greater than the sperm total motility.

2. Case B

1) Scenario

A 30-year-old patient provides a semen sample for laboratory evaluation. Upon examination, the parameters are (1) volume, 0.5 mL; (2) concentration, $5 \times 10^6/\text{mL}$; (3) total motility, 10%. How will you proceed?

2) Solution

All three parameters are below the WHO reference values [5]. Since the concentration is below $10 \times 10^6/\text{mL}$, first centrifuge the sample at 3,000 g for 7 minutes. Gently remove approximately 300 μL of the supernatant. After mixing the pellet thoroughly, perform the E-N test as previously described. Note on the frosted label "spun" indicating that it is a spun smear. The percentage of vital and non-vital sperm must be counted, and vitality compared with motility. The vitality results must be equal to or greater than the sperm total motility. Vitality test can indeed provide a check on the motility evaluation, since the percentage of dead cells should not exceed (within sampling error) the percentage of immotile spermatozoa [5]. If the evaluation of sperm vitality and motility are discordant (presence of less live sperm than motile sperm), the evaluation of these two parameters should be redone.

3. Case C

1) Scenario

A 35-year-old patient provides a semen sample for laboratory evaluation. Upon examination, the param-

eters are (1) volume, 2.5 mL; (2) concentration, $20 \times 10^6/\text{mL}$; (3) progressive motility, 30%. The sample is examined for vitality and a majority of the spermatozoa show sperm heads that are neither completely white nor completely stained pink. How will you proceed?

2) Solution

This is an example of "leaky" sperm. The neck region is very fragile and is the first to show signs of damage. The membrane breakdown may be very minimal at the initial stages and so there is a minute portion of stain that can enter the base of the head and neck region. Therefore, only a limited amount of pink stain is observed, and the rest of the sperm head is white (Fig. 3B). Spermatozoa with an appearance as described above following staining should be scored as vital. Gradually the damage may spread to the rest of the sperm head. This allows the stain to penetrate the sperm head and the extent of the pink stain may be more than at the base but still some portion of the head may be unstained and appear white. Spermatozoa that are stained pink should be reported as non-vital (Fig. 3C).

ETIOLOGIES OF NECROZOOSPERMIA

Proper patient history is essential to eliminate false results of necrozoospermia. For example, the addition of lubricants during masturbation or inadvertent spillage of antiseptic solution, soap or water into the semen collection sample may be responsible for false results. In such cases, another specimen should be collected following detailed instructions and submitted for vitality assessment. Necrozoospermia is reported to have a prevalence of 0.2% to 0.4% in infertile males [16-18]. Causes of necrozoospermia could either be local or general, testicular or extra-testicular, and some of them can be associated in the same patient (Table 1) [16,19-28].

Infections may account for nearly half of the causes of necrozoospermia [16]. The alteration of sperm vitality can be explained by several mechanisms: direct damage to spermatozoa by infectious organisms, effects of inflammatory mediators and/or possible long-term alteration of the genital tract environment [23]. With regard to the epididymal environment, the first to describe epididymal necrozoospermia was Wilton in 1988 [29]. The epididymis could indeed be dysfunctional and

lead to sperm abnormalities such as asthenozoospermia and necrozoospermia. The mechanisms of action involved could be multiple, including exposure of epididymal spermatozoa to oxidative stress. This is why some necrozoospermic cases, previously considered as due to “epididymal” causes [29], are now better explained by the possible action of seminal oxidative stress [30].

Some necrozoospermia can also be linked to an impairment of spermatogenesis. Testicular heat stress is a well-known mechanism for altering spermatogenesis [31], as heat is indeed the basis of thermal male infertility [32,33]. Hence, local or general hyperthermia (prolonged heat exposure, fever, hyperthyroidism, obesity, varicocele, *etc.*) can lead to necrozoospermia. For instance, Abalovich et al [24] described a large cohort of patients with hyperthyroidism presenting with necrozoospermia. These abnormalities were corrected in most of the cases, with the establishment of normal thyroid function. The mechanisms of action could be hormonal with a decrease in testosterone, or thermoregulation as related to the increase in body heat [24]. For patients with varicocele, the pathophysiological mechanisms of necrozoospermia involve an increase in local temperature as well as the simultaneous formation of reactive oxygen species (ROS) [34]. More recently, with the appearance of the Coronavirus Disease-2019 (COVID-19) pandemic, it was described that fever, even without the presence of the severe acute respiratory syndrome coronavirus 2 (SARS-CoV-2) in the semen, could induce an alteration in spermatogenesis and a decrease in sperm vitality [35]. It is therefore important to consider medical and reproductive history throughout the assessment, along with a thorough physical examination in patients with necrozoospermia in view of the wide spectrum of possible etiologies.

Necrozoospermia can also be observed following long-term exposure to toxic substances such as tobacco, cannabis and pesticides, amongst others [20-22,25,36-39]. A direct toxic effect of cannabis can be noted *via* the presence of cannabinoid receptors in testicular tissue (Sertoli and Leydig cells) and this would lead to the inhibition of mitochondrial respiration and the loss of energy in sperm, followed by death [25,38]. Necrozoospermia is also commonly reported in patients with spinal cord injury [27,40]. For these patients, other causes of necrozoospermia could include the thermal dysregulation induced by a prolonged sitting stance that promotes temperature increase in the male genital

area. These patients are also more at risk of urogenital infections.

Certain cytotoxic antibodies can also cause necrozoospermia. In a case report of a patient who underwent vasectomy reversal, the presence of necrozoospermia was associated with a positive test for antisperm antibodies [28]. Antisperm antibodies, produced locally in the seminal tract following the disruption of the epithelial tight-junction barrier, affect the overall motility of the samples involved and could be responsible for necrozoospermia. Furthermore, necrozoospermia has been found to be associated with polycystic kidney disease [19]. In these patients, cystic obstructions/dilatations of the seminal vesicles and ejaculatory duct (due to seminal vesicle atony) have been described as responsible for sperm stasis in the genital tract, followed by sperm death [41]. Advanced male age may also be accompanied by necrozoospermia. The mechanisms remain unknown at this time but may involve an alteration in accessory gland secretions [42-44]. However, after a complete andrological evaluation, some patients with necrozoospermia remain idiopathic.

MANAGEMENT OF NECROZOOSPERMIA

The first line of management in necrozoospermia is avoiding any etiological contributory factors mentioned previously (exposure to heat, modification of lifestyle, treatment of urogenital infections, correction of hyperthyroidism, *etc.*). In addition, if vitality is affected by infrequent ejaculations and prolonged epididymal storage, the parameters of sperm vitality could be improved by repeated ejaculations (60 minutes, 12 hours or 24 hours after the first ejaculate) [29,45,46].

Here we describe two conditions when (1) necrozoospermia is not absolute but asthenozoospermia is, and (2) when necrozoospermia is absolute.

1. Management of necrozoospermia with absolute asthenozoospermia

When no motile spermatozoa are observed, sperm vitality should be tested to differentiate asthenozoospermia from necrozoospermia. The presence of a large proportion of live but immotile spermatozoa may indeed be indicative of structural defects in the flagellum [7,47,48]. There is no definition in the latest edition of the WHO manual of this “large proportion of im-

motile living spermatozoa”, but it is considered that “if more than 25%–30% of all spermatozoa are alive and immotile, a genetic ciliary problem may be the cause” [7]. If flagellar dyskinesia is suspected, other clinical or sperm elements may help the diagnosis (Table 1). For example, the observation of short, bent or coiled flagella may be suggestive of such flagellar/ciliary problems [49].

In practice, if the spermatozoon is immotile and ART is being considered for the couple, it is necessary to test sperm vitality. In order to select a viable spermatozoon for intracytoplasmic sperm injection (ICSI), the HOS test is very useful in cases where no motile spermatozoa are present through microscopic examination [11]. At this instance, a modification of the main approach in HOS testing should be adapted for subsequent use for fertilization through ICSI, where the embryologist should aspirate the selected spermatozoon head first with the injecting needle and immerse the flagellum in a hypoosmotic solution for less than 5 minutes [7]. As soon as the tail swelling is visualized, the spermatozoon is considered as viable and is removed from the hypo-osmotic solution and rinsed in culture medium allowing osmotic equilibrium. Immotile testicular spermatozoa when selected with HOS and used for ICSI result in higher fertilization and pregnancy rates than immotile sperm selected without being subjected to HOS test [13,14]. HOS test could also be useful in cases of previous ICSI failure due to oocyte fertilization failure [50]. The only situation where the HOS test is not as useful would be in cases of cryopreserved semen samples [51,52]. This might be related to the loss of integrity of the sperm membrane after cryopreservation, which can lead to spontaneous swelling of the flagella [53].

Several other approaches for selection of viable spermatozoa for ICSI have been presented [54]. The mechanical technique of “touching” the flagellum, known as the sperm tail flexibility test (STFT), consists of evaluating the flexibility or rigidity of the flagellum by touching it with the ICSI pipette [55]. A dead spermatozoon would have a rigid flagellum. This technique is subjective and difficult to control [53,54]. The laser technique, known as the laser assisted immotile sperm selection (LAISS), consists of performing a laser shot of 129 microjoule for approximately 1.2 milliseconds very close to the flagellum, using a non-contact diode laser system [56]. The living spermatozoon then coils its

flagellum. Like the HOS test, STFT and LAISS could give false positives for frozen sperm as the flagellum could spontaneously curl after freezing-thawing [53,54]. These two techniques, STFT and LAISS, have not been described in recent years, probably because their costs in terms of learning time (STFT) or in terms of equipment (LAISS) might limit their routine use in ART laboratories [53,54,57].

Therefore, there are several techniques to test the vitality of immobile spermatozoa. Most studies have focused on activating substances such as pentoxifylline (PTX) or theophylline describing their role in activating flagellar movement of immotile spermatozoa (for a review see [53,54,57]). PTX is a 3' 5' nucleotidase phosphodiesterase inhibitor that improves sperm motility by increasing intracellular cyclic adenosine monophosphate [58]. It has been studied in infertile patients since the late 1980s [59]. Theophylline, which belongs to the same family, has been studied less frequently since its first clinical trial in 2011 [60]. Since then, several studies have shown the effectiveness of these substances in inducing sperm motility in immotile but alive spermatozoa (for a review see [54,57]). Their safety has been demonstrated in several studies (for a review see [53,54,57]). However, given their potential toxicity, it is necessary to rinse the spermatozoon before injecting it into the oocyte [53,54,57].

2. Management of absolute necrozoospermia

If absolute necrozoospermia in the ejaculate is confirmed, then testicular sperm extraction should be considered (Table 1), since it allows the extraction of live spermatozoa [61,62].

Necrozoospermia has been shown to be correlated with sperm DNA fragmentation (SDF). Samplaski et al [63] reported a strong direct correlation between sperm vitality and normal DNA integrity ($r=0.83$, $p<0.001$). Moreover, authors observed that SDF measured by spermatozoa chromatin structure assay (SCSA) was $\leq 30\%$ (normal) when sperm vitality was $\geq 75\%$ in 95% of samples. Similarly, SDF was $\geq 30\%$ (high) when vitality was $\leq 50\%$. Two other studies showed the same correlations between necrozoospermia and DNA fragmentation tested by the terminal deoxynucleotidyl transferase-mediated deoxyuridine triphosphate nick-end labeling (TUNEL) assay. SDF was significantly higher in sperm with necrozoospermia [64,65]. Derbel et al [66] found the same results using the sperm chro-

matin dispersion test in leukocytospermia. Some of the authors report a continuum between DNA damage and sperm death. The loss of viability would be part of a progressive oxidative process that starts with the excessive generation of ROS, leads to the peroxidation of membrane lipids and DNA damage, and ends in DNA fragmentation and ultimately death [67]. Thus, the question that must now be asked is the following: even if some immobile spermatozoa are alive, can we be confident of their nuclear integrity? The answer to this question is probably a no. Testing for SDF could then be useful in deciding whether to use live ejaculated sperm in ICSI or to use testicular sperm extraction. Nevertheless, interest in using antioxidants to reduce potential SDF in these patients with almost total necrozoospermia is open for discussion. Antioxidants may indeed have a beneficial effect on reducing SDF [18,68,69].

CLINICAL SCENARIOS

There are several clinical and diagnostic conditions or findings which indicate the need to perform the E-N or HOS test to rule out necrozoospermia or asthenozoospermia.

1. Case A

1) Scenario

A couple is undergoing ICSI procedure. On the day of the procedure, a fresh sperm sample is examined, and the embryologist identifies 6 spermatozoa, but none of them display any motility. How should they proceed?

2) Solution

Since the spermatozoa are going to be used for ICSI, assessing sperm viability is very important and hence, E-N stain cannot be used. The solution is to use HOS test, STFT, LAISS, PTX, or theophylline. If the sperm is assessed as viable, it can be rinsed in sperm wash medium and subsequently be used for oocyte injection. If the spermatozoon is not considered as viable, the procedure is repeated until a viable sperm can be retrieved. If absolute necrozoospermia is found (0% vitality), testicular sperm should be retrieved by surgical sperm extraction.

2. Case B

1) Scenario

A patient presents for semen analysis and has the following results: (1) semen volume, 3.5 mL; (2) sperm concentration, $35 \times 10^6/\text{mL}$; (3) sperm motility, 0%; (4) vitality, 0%. How will you manage this patient?

2) Solution

First, rule out spermicidal lubricant use or improper collection (with spillage of antiseptic solution, soap or water into the semen collection container). Repeat semen analysis. If there is no pathological cause, ICSI using testicular sperm improves the chance of conception, otherwise other alternatives should also be considered (e.g., use of donor sperm).

3. Case C

1) Scenario

A patient presents for semen analysis. Upon analysis the following parameters are reported: (1) semen volume, 4.5 mL; (2) concentration, $70 \times 10^6/\text{mL}$; (3) total sperm motility, 0%. His spouse had an early spontaneous miscarriage a few months ago. No cause for necrozoospermia was found on questioning or clinical examination. How will you manage this patient?

2) Management

Since the patient has a history of confirmed natural fertility and no motility, performing a viability test is recommended. Testing for SDF will help in the decision between using testicular and ejaculated sperm. Antioxidants can be proposed as supplements to reduce SDF if it is present.

ONLINE SURVEY

We have thus far described the principles of the sperm vitality test, the causes of necrozoospermia and discussed appropriate patient management. We now present the results of a worldwide survey of andrologists/urologists that was conducted to evaluate practice patterns in the management of necrozoospermia.

1. Methodology

The American Center for Reproductive Medicine (ACRM) designed and conducted an online survey to

investigate the importance, use and clinical implication of sperm vitality testing in male infertile patients. No ethical approval was required for this study. Researchers and clinicians from ACRM drafted the questions (AA, RKS, RF, SG, NP), which were subsequently revised by a pool of experienced andrologists, urologists, and attending physicians with expertise in male infertility selected from all over the world. English was the primary language of the survey and questions were carefully revised to make them understandable for non-native English speakers.

The survey consisted of 15 questions, in 2 different

sections: the first section (6 questions) aimed to collect the demographic data of the participants, while the questions in the second section targeted the clinical practice pattern of sperm vitality testing (Supplement File 2). We used SelectSurvey (https://www.classapps.com/product_ssv5.aspx; ClassApps Inc., Kansas City, MO, USA), a tool approved by the Information Technology Department, Cleveland Clinic, to securely populate the survey. A total of 106 international experts in male infertility received the survey link by email on June 19, 2021, and they were asked to complete the survey by June 28, 2021. SelectSurvey automatically

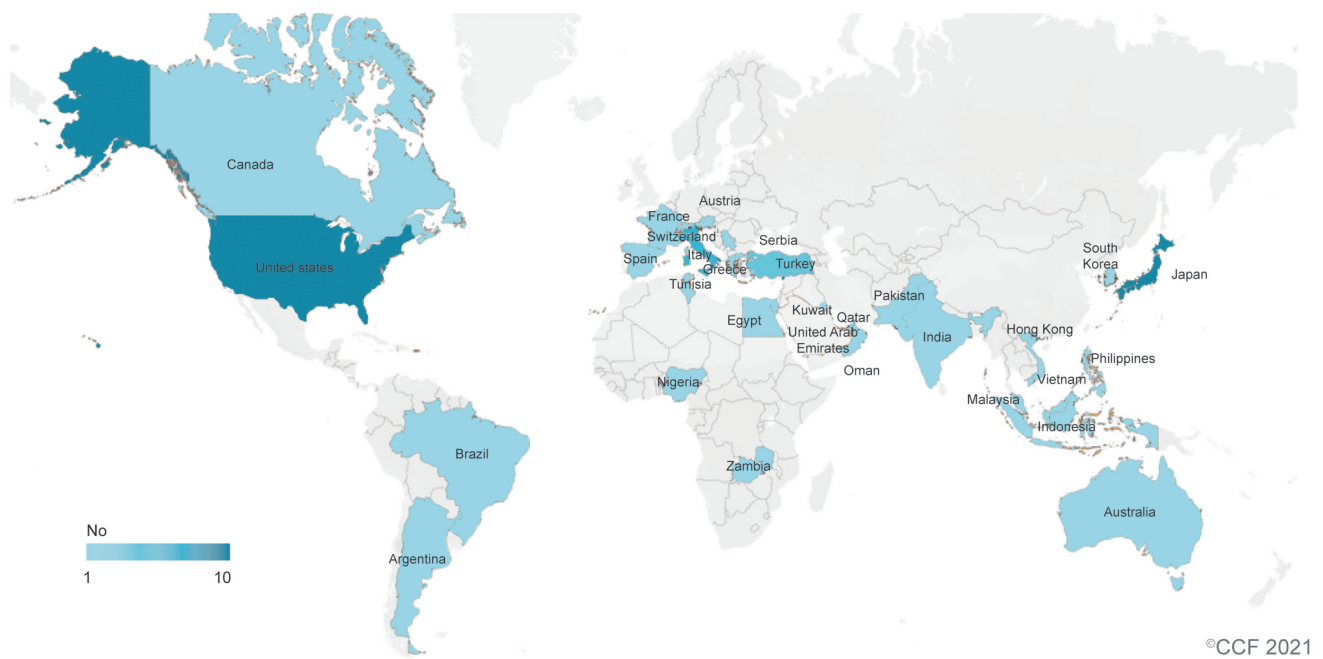


Fig. 5. Geographic map illustrating the distribution of participants.

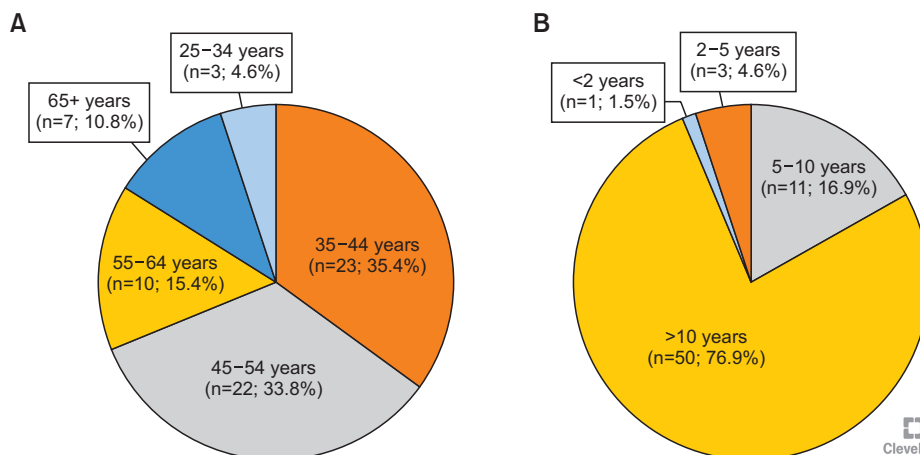


Fig. 6. Pie charts reporting (A) the age of participants and (B) their years of clinical practice.

generated a comma-separated values (CSV) file with the results, which were analyzed using the MedCalc Software (version 20.009; MedCalc Software, Ostend, Belgium). Incomplete responses were excluded. Results are reported as number of participants and percentage calculated for each category. When more than one option was available, results were expressed in percentage based on the total number of participants.

2. Survey results

The survey was completed by 65 out of 106 experts (response rate: 61.3%). The participants originated from 31 countries (Fig. 5, Supplement File 3). Most participants' ages were between 35 and 54 years old (n=45, 69.2%) (Fig. 6A), with >10 years of experience in clinical practice (n=50, 76.9%) (Fig. 6B). Their primary practice

setting was mostly identified as academic hospital/clinic (n=46, 70.8%) or private practice/clinic (n=22, 33.8%).

The majority of participants recommended sperm vitality testing in their clinical practice (n=45, 69.2%). The test is reported to be conducted on a weekly frequency (n=21, 46.7%), but the majority of practitioners prescribe it less than 10 times a month (n=28, 62.2%). More than half of them prescribe the test if the sperm total motility is <25% (n=26, 57.8%), while only one third of the participants conduct sperm vitality testing automatically when sperm motility is <40% (n=15, 33.3%) (Fig. 7).

The E-N test is reportedly the most commonly used stain to test sperm vitality (n=35, 77.8%) and 73.0% of the participants responded to order a test for SDF in case of abnormal vitality (n=33, 73.3%) (Fig. 8A). Few andrologists look for signs of infection or markers of oxidative stress (n=21, 46.7% respectively) (Fig. 8A).

Concerning management, patients with necrozoospermia (0% sperm vitality) are mainly offered surgical sperm retrieval followed by ICSI (n=41, 91.1%) (Fig. 8B). Few andrologists recommended frequent ejaculation (n=22, 48.9%) (Fig. 8B).

This survey highlighted that the WHO guidelines (test vitality if total motility is <40%) are not necessarily applied in clinical practice. Few andrologists look for signs of infection in the presence of necrozoospermia, even though this is a frequent cause of reduced sperm vitality. Regarding management, repetitive ejaculation is a non-invasive option in comparison with surgical sperm extraction. However, it seems to be given much less consideration by the andrologists.

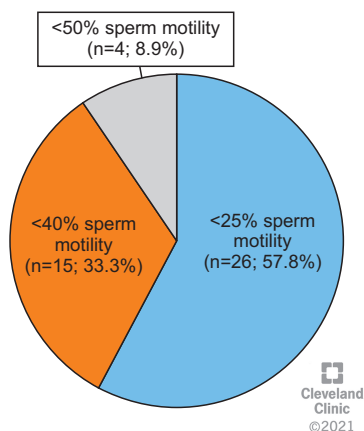


Fig. 7. Pie chart reporting the use of sperm vitality in the andrology laboratory.

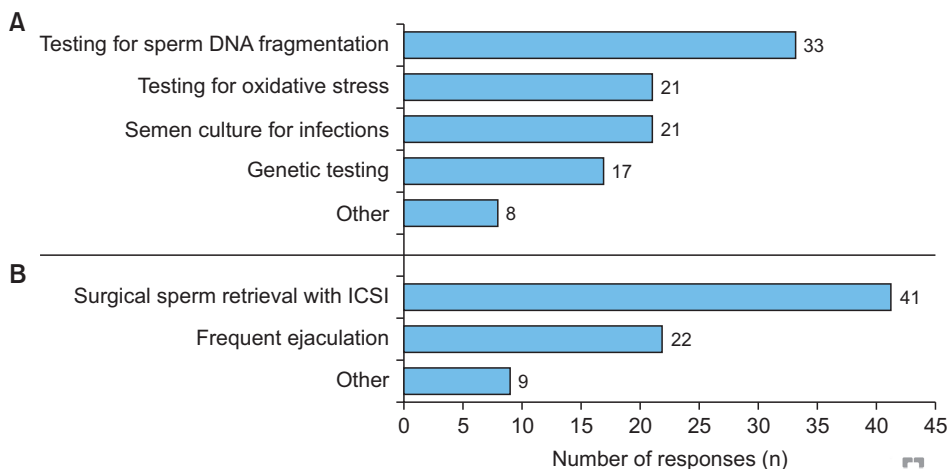


Fig. 8. (A) Testing options for the evaluation of patients with abnormal sperm vitality. (B) Clinical options for management of necrozoospermic patients. ICSI: intracytoplasmic sperm injection.

CONCLUSIONS

Sperm vitality staining is a useful test that should be performed when a semen sample shows reduced motility. It helps identify samples with necrozoospermia, and thus points to a number of potentially correctable clinical conditions that may contribute to impaired fertility. When all spermatozoa are immotile, then testing to distinguish between “live-immotile” *versus* “dead-immotile” spermatozoa is critical in determining whether ejaculated or testicular spermatozoa should be used for the ICSI procedure. Furthermore, necrozoospermia positively correlates with increased sperm DNA damage. Hence, SDF testing could be useful in patients with low numbers of alive spermatozoa. Our global survey reveals considerable diversity in approaches to vitality testing, and a relatively limited approach to the management of necrozoospermia, thus highlighting the need for guidelines on this relevant topic.

ACKNOWLEDGEMENTS

Authors are thankful to the artists Bernastine Buchanan and Ken Kula from the Cleveland Clinic's Center for Medical Art & Photography for their help with the illustrations. The study was supported by the American Center for Reproductive Medicine.

Conflict of Interest

The authors have nothing to disclose.

Author Contribution

Conceptualization: AA. Data curation: RF, SK. Methodology: AA, RKS, SG, RF. Project administration: AA, RKS, SG, RF, SK. Writing – original draft: AA, RKS, SG, FB, RF, Rupin Shah. Writing – review & editing: all authors.

Supplementary Materials

Supplementary materials can be found *via* <https://doi.org/10.5534/wjmh.210149>.

REFERENCES

1. Agarwal A, Gupta S, Sharma R. Eosin-nigrosin staining procedure. In: Agarwal A, Gupta S, Sharma R, editors. *Androlog-*

- ical evaluation of male infertility. Cham: Springer; 2016;73-7.
2. Björndahl L, Söderlund I, Johansson S, Mohammadi M, Pourian MR, Kvist U. Why the WHO recommendations for eosin-nigrosin staining techniques for human sperm vitality assessment must change. *J Androl* 2004;25:671-8.
3. Björndahl L, Mortimer D, Barratt CLR, Castilla JA, Menkveld R, Kvist U, et al. A practical guide to basic laboratory andrology. Cambridge: Cambridge University Press; 2010.
4. Mortimer D. Practical laboratory andrology. New York: Oxford University Press; 1994.
5. World Health Organization (WHO). WHO laboratory manual for the examination and processing of human semen. 5th ed. Geneva: WHO; 2010.
6. Barratt CL, Björndahl L, Menkveld R, Mortimer D. ESHRE special interest group for andrology basic semen analysis course: a continued focus on accuracy, quality, efficiency and clinical relevance. *Hum Reprod* 2011;26:3207-12.
7. World Health Organization (WHO). WHO laboratory manual for the examination and processing of human semen. 6th ed. Geneva: WHO; 2021.
8. Jeyendran RS, Van der Ven HH, Perez-Pelaez M, Crabo BG, Zaneveld LJ. Development of an assay to assess the functional integrity of the human sperm membrane and its relationship to other semen characteristics. *J Reprod Fertil* 1984;70:219-28.
9. Esteves SC, Sharma RK, Thomas AJ Jr, Agarwal A. Sperm viability assays--a matter of life and death! *Fertil Steril* 1999;72:184-5.
10. Smikle CB, Turek PJ. Hypo-osmotic swelling can accurately assess the viability of nonmotile sperm. *Mol Reprod Dev* 1997;47:200-3.
11. Simopoulou M, Gkoles L, Bakas P, Giannelou P, Kalampokas T, Pantos K, et al. Improving ICSI: a review from the spermatozoon perspective. *Syst Biol Reprod Med* 2016;62:359-371.
12. Mortimer D. A technical note on the assessment of human sperm vitality using eosin-nigrosin staining. *Reprod Biomed Online* 2020;40:851-5.
13. Sallam HN, Farrag A, Agameya AF, El-Garem Y, Ezzeldin F. The use of the modified hypo-osmotic swelling test for the selection of immotile testicular spermatozoa in patients treated with ICSI: a randomized controlled study. *Hum Reprod* 2005;20:3435-40.
14. Charehjooy N, Najafi MH, Tavalaee M, Deemeh MR, Azadi L, Shiravi AH, et al. Selection of sperm based on hypo-osmotic swelling may improve ICSI outcome: a preliminary prospective clinical trial. *Int J Fertil Steril* 2014;8:21-8.
15. Agarwal A, Gupta S, Sharma R. *Andrological evaluation of male infertility*. Cham: Springer; 2016.

16. Nduwayo L, Barthélémy C, Lansac J, Tharanne MJ, Lecomte P. [Management of necrozoospermia]. *Contracept Fertil Sex* 1995;23:682-5. French.
17. Correa-Pérez JR, Fernández-Pelegrina R, Aslanis P, Zavos PM. Clinical management of men producing ejaculates characterized by high levels of dead sperm and altered seminal plasma factors consistent with epididymal necrozoospermia. *Fertil Steril* 2004;81:1148-50.
18. Dumont A, Barbotin AL, Lefebvre-Khalil V, Mitchell V, Rigot JM, Boitrelle F, et al. [Necrozoospermia: from etiologic diagnosis to therapeutic management]. *Gynecol Obstet Fertil Senol* 2017;45:238-48. French.
19. Fang S, Baker HW. Male infertility and adult polycystic kidney disease are associated with necrozoospermia. *Fertil Steril* 2003;79:643-4.
20. Lerda D, Rizzi R. Study of reproductive function in persons occupationally exposed to 2,4-dichlorophenoxyacetic acid (2,4-D). *Mutat Res* 1991;262:47-50.
21. El-Gothamy Z, El-Samahy M. Ultrastructure sperm defects in addicts. *Fertil Steril* 1992;57:699-702.
22. Coutinho EM, Melo JF, Barbosa I, Segal SJ. Antispermato-genic action of gossypol in men. *Fertil Steril* 1984;42:424-30.
23. Boitrelle F, Robin G, Lefebvre C, Bailly M, Selva J, Courcol R, et al. [Bacteriospermia in assisted reproductive techniques: effects of bacteria on spermatozoa and seminal plasma, diagnosis and treatment]. *Gynecol Obstet Fertil* 2012;40:226-34. French.
24. Abalovich M, Levalle O, Hermes R, Scaglia H, Aranda C, Zylbersztein C, et al. Hypothalamic-pituitary-testicular axis and seminal parameters in hyperthyroid males. *Thyroid* 1999;9:857-63.
25. Bari M, Battista N, Pirazzi V, Maccarrone M. The manifold actions of endocannabinoids on female and male reproductive events. *Front Biosci (Landmark Ed)* 2011;16:498-516.
26. Jewett MA, Greenspan MB, Shier RM, Howatson AF. Necrozoospermia or immotile cilia syndrome as a cause of male infertility. *J Urol* 1980;124:292-3.
27. Brackett NL, Bloch WE, Lynne CM. Predictors of necrozoospermia in men with spinal cord injury. *J Urol* 1998;159:844-7.
28. Chavez-Badiola A, Drakeley AJ, Finney V, Sajjad Y, Lewis-Jones DI. Necrozoospermia, antisperm antibodies, and vasectomy. *Fertil Steril* 2008;89:723.e5-7.
29. Wilton LJ, Temple-Smith PD, Baker HW, de Kretser DM. Human male infertility caused by degeneration and death of sperm in the epididymis. *Fertil Steril* 1988;49:1052-8.
30. Mahfouz RZ, du Plessis SS, Aziz N, Sharma R, Sabanegh E, Agarwal A. Sperm viability, apoptosis, and intracellular reactive oxygen species levels in human spermatozoa before and after induction of oxidative stress. *Fertil Steril* 2010;93:814-21.
31. Ji ZL, Duan YG, Mou LS, Allam JP, Haidl G, Cai ZM. Association of heat shock proteins, heat shock factors and male infertility. *Asian Pac J Reprod* 2012;1:76-84.
32. Bujan L, Mieusset R. [Temperature and male fertility]. *Contracept Fertil Sex* 1996;24:429-38. French.
33. Mieusset R, Bujan L, Mansat A, Pontonnier F. [Scrotal hyperthermia and male infertility]. *Prog Urol* 1992;2:31-5; discussion 35-6. French.
34. Cho CL, Esteves SC, Agarwal A. Novel insights into the pathophysiology of varicocele and its association with reactive oxygen species and sperm DNA fragmentation. *Asian J Androl* 2016;18:186-93.
35. Hamdi S, Bendayan M, Huyghe E, Soufir JC, Amar E, El Osta R, et al. COVID-19 and andrology: recommendations of the French-speaking society of andrology (Société d'Andrologie de langue Française SALF). *Basic Clin Androl* 2020;30:10.
36. Harlev A, Agarwal A, Gunes SO, Shetty A, du Plessis SS. Smoking and male infertility: an evidence-based review. *World J Mens Health* 2015;33:143-60.
37. Zhang JP, Meng QY, Wang Q, Zhang LJ, Mao YL, Sun ZX. Effect of smoking on semen quality of infertile men in Shandong, China. *Asian J Androl* 2000;2:143-6.
38. du Plessis SS, Agarwal A, Syriac A. Marijuana, phytocannabinoids, the endocannabinoid system, and male fertility. *J Assist Reprod Genet* 2015;32:1575-88.
39. Daoud S, Sellami A, Bouassida M, Kebaili S, Ammar Keskes L, Rebai T, et al. Routine assessment of occupational exposure and its relation to semen quality in infertile men: a cross-sectional study. *Turk J Med Sci* 2017;47:902-7.
40. Mallidis C, Lim TC, Hill ST, Skinner DJ, Brown DJ, Johnston WI, et al. Necrozoospermia and chronic spinal cord injury. *Fertil Steril* 2000;74:221-7.
41. Hendry WF, Rickards D, Pryor JP, Baker LR. Seminal megavesicles with adult polycystic kidney disease. *Hum Reprod* 1998;13:1567-9.
42. Siddighi S, Chan CA, Patton WC, Jacobson JD, Chan PJ. Male age and sperm necrosis in assisted reproductive technologies. *Urol Int* 2007;79:231-4.
43. Demirkol MK, Barut O, Dogan NT, Hamarat MB, Resim S. At what age threshold does the decline in semen parameters begin? *J Coll Physicians Surg Pak* 2021;31:4-7.
44. Condorelli RA, La Vignera S, Barbagallo F, Alamo A, Mongioi LM, Cannarella R, et al. Bio-functional sperm parameters: does age matter? *Front Endocrinol (Lausanne)* 2020;11:558374.
45. Ron-El R, Strassburger D, Friedler S, Komarovsky D, Bern

- O, Raziell A. Repetitive ejaculation before intracytoplasmic sperm injection in patients with absolute immotile spermatozoa. *Hum Reprod* 1998;13:630-3.
46. Hanson BM, Aston KI, Jenkins TG, Carrell DT, Hotaling JM. The impact of ejaculatory abstinence on semen analysis parameters: a systematic review. *J Assist Reprod Genet* 2018;35:213-20.
47. Chemes EH, Rawe YV. Sperm pathology: a step beyond descriptive morphology. Origin, characterization and fertility potential of abnormal sperm phenotypes in infertile men. *Hum Reprod Update* 2003;9:405-28.
48. Afzelius BA, Eliasson R, Johnsen O, Lindholmer C. Lack of dynein arms in immotile human spermatozoa. *J Cell Biol* 1975;66:225-32.
49. Agarwal A, Sharma R, Gupta S, Finelli R, Parekh N, Panner Selvam MK, et al. Sperm morphology assessment in the era of intracytoplasmic sperm injection: reliable results require focus on standardization, quality control, and training. *World J Mens Health* 2021. doi: 10.5534/wjmh.210054 [Epub].
50. Goksan Pabuccu E, Sinem Caglar G, Dogus Demirkiran O, Pabuccu R. Uncommon but devastating event: total fertilisation failure following intracytoplasmic sperm injection. *Andrologia* 2016;48:164-70.
51. Hauser R, Yavetz H, Paz GF, Homonnai ZT, Amit A, Lessing JB, et al. The predictive fertilization value of the hypoosmotic swelling test (HOST) for fresh and cryopreserved sperm. *J Assist Reprod Genet* 1992;9:265-70.
52. Esteves SC, Sharma RK, Thomas AJ Jr, Agarwal A. Suitability of the hypo-osmotic swelling test for assessing the viability of cryopreserved sperm. *Fertil Steril* 1996;66:798-804.
53. Nordhoff V. How to select immotile but viable spermatozoa on the day of intracytoplasmic sperm injection? An embryologist's view. *Andrology* 2015;3:156-62.
54. Ortega C, Verheyen G, Raick D, Camus M, Devroey P, Tournaye H. Absolute asthenozoospermia and ICSI: what are the options? *Hum Reprod Update* 2011;17:684-92.
55. Soares JB, Glina S, Antunes N Jr, Wonchockier R, Galuppo AG, Mizrahi FE. Sperm tail flexibility test: a simple test for selecting viable spermatozoa for intracytoplasmic sperm injection from semen samples without motile spermatozoa. *Rev Hosp Clin Fac Med Sao Paulo* 2003;58:250-3.
56. Aktan TM, Montag M, Duman S, Gorkemli H, Rink K, Yurdakul T. Use of a laser to detect viable but immotile spermatozoa. *Andrologia* 2004;36:366-9.
57. Aydos K, Aydos OS. Sperm selection procedures for optimizing the outcome of ICSI in patients with NOA. *J Clin Med* 2021;10:2687.
58. Calogero AE, Fishel S, Hall J, Ferrara E, Vicari E, Green S, et al. Correlation between intracellular cAMP content, kinematic parameters and hyperactivation of human spermatozoa after incubation with pentoxifylline. *Hum Reprod* 1998;13:911-5.
59. Yovich JM, Edirisinghe WR, Cummins JM, Yovich JL. Preliminary results using pentoxifylline in a pronuclear stage tubal transfer (PROST) program for severe male factor infertility. *Fertil Steril* 1988;50:179-81.
60. Ebner T, Tews G, Mayer RB, Ziehr S, Arzt W, Costamoling W, et al. Pharmacological stimulation of sperm motility in frozen and thawed testicular sperm using the dimethylxanthine theophylline. *Fertil Steril* 2011;96:1331-6.
61. Negri L, Patrizio P, Albani E, Morengi E, Benaglia R, Desgro M, et al. ICSI outcome is significantly better with testicular spermatozoa in patients with necrozoospermia: a retrospective study. *Gynecol Endocrinol* 2014;30:48-52.
62. Tournaye H, Liu J, Nagy Z, Verheyen G, Van Steirteghem A, Devroey P. The use of testicular sperm for intracytoplasmic sperm injection in patients with necrozoospermia. *Fertil Steril* 1996;66z:331-4.
63. Samplaski MK, Dimitromanolakis A, Lo KC, Grober ED, Mullen B, Garbens A, et al. The relationship between sperm viability and DNA fragmentation rates. *Reprod Biol Endocrinol* 2015;13:42.
64. Aitken RJ, De Iuliis GN, Finnie JM, Hedges A, McLachlan RI. Analysis of the relationships between oxidative stress, DNA damage and sperm vitality in a patient population: development of diagnostic criteria. *Hum Reprod* 2010;25:2415-26.
65. Brahem S, Jellad S, Ibala S, Saad A, Mehdi M. DNA fragmentation status in patients with necrozoospermia. *Syst Biol Reprod Med* 2012;58:319-23.
66. Derbel R, Sellami H, Sakka R, Ben Slima A, Mkaddem I, Gdoura R, et al. Relationship between nuclear DNA fragmentation, mitochondrial DNA damage and standard sperm parameters in spermatozoa of infertile patients with leukocytospermia. *J Gynecol Obstet Hum Reprod* 2021;50:102101.
67. Aitken RJ, De Iuliis GN. On the possible origins of DNA damage in human spermatozoa. *Mol Hum Reprod* 2010;16:3-13.
68. Agarwal A, Leisegang K, Majzoub A, Henkel R, Finelli R, Panner Selvam MK, et al. Utility of antioxidants in the treatment of male infertility: clinical guidelines based on a systematic review and analysis of evidence. *World J Mens Health* 2021;39:233-90.
69. Agarwal A, Farkouh A, Parekh N, Zini A, Arafa M, Kandil H, et al. Sperm DNA fragmentation: a critical assessment of clinical practice guidelines. *World J Mens Health* 2021. doi: 10.5534/wjmh.210056 [Epub].