



Endoscopic removal of a spoon from the stomach using a 2-channel endoscope

Kazuki Yamamoto, MD, Takeshi Okamoto, MD, Katsuyuki Fukuda, MD, PhD

Foreign body ingestion occurs most commonly in children, but it can also occur in young adults with psychiatric disorders or alcohol intoxication.¹⁻³ First reported in 1972,⁴ various tools have been used for endoscopic removal, including grasping forceps, nets, baskets, and snares.¹ Endoscopic removal is indicated in 10% to 20% of cases, particularly for long or sharp objects with perforation risk.¹⁻³ Spoons account for about 1% of all ingested foreign bodies.² We report successful removal of a long spoon using alligator forceps and an endoscopic snare inserted simultaneously into a 2-channel endoscope.

A 21-year-old woman with binge-eating/purging-type anorexia nervosa presented after accidentally swallowing a spoon the night before. She had used the spoon habitually to induce vomiting after binge eating. Upon presentation, she was in no apparent distress, and physical examination was noncontributory. Abdominal roentgenogram revealed a radiopaque object measuring 19 cm (Fig. 1).

Urgent esophagogastroduodenoscopy was performed with a 2-channel endoscope (GIF-2TQ260M, Olympus Medical Systems, Tokyo, Japan) (Video 1, available online at www.giejournal.org). An overtube could not be used because the spoon was too large to fit through it. Conscious sedation with midazolam was used without intubation.

The spoon was buried in food residue in the upper body of the stomach (Fig. 2A and B). Rat tooth alligator jaw forceps (model FG-42L-1, Olympus) were inserted through the left channel, and a reusable endoscopic snare (SD-5U-1, Olympus) was inserted through the right channel. The forceps were advanced through the loop of the snare (Fig. 2C). After grasping the spoon with the forceps, followed by the snare, forceps and snare were alternately opened and closed to move toward the edge of the spoon (Fig. 2D). With the snare grasping the edge, the forceps were extended in an open position to push the side of the spoon, rotating it around the edge to become parallel to the esophagus (Fig. 2E). The endoscope was twisted clockwise so that the spoon and snare could pass the esophagogastric junction in the 12 o'clock position. As the endoscope slid along the 6 o'clock position within the esophageal lumen and the snare was passed through the left channel in the 7

o'clock position, this twisting created space for the edge of the spoon handle to pass without touching the mucosa. The endoscope was retracted slowly through the esophagus, ensuring that the rounded end of the spoon did not injure the esophagogastric junction (Fig. 2F). A diagram illustrating the spoon handle passing the esophagogastric junction is presented in Figure 3.

When the spoon reached the mouth, it could not be retracted through the mouthpiece. The endoscope was therefore drawn out of the mouth while advancing the snare, which still grasped the spoon, to prevent reingestion. The mouthpiece was then removed, the patient's head was tilted back, and the spoon was removed by hand (Fig. 4). The procedure was completed with no adverse effects. The patient reported no pain or tarry stools at her clinic visit 1 week later.

Guidelines recommend use of overtubes or protective hoods to prevent mucosal injury and intubation for patients with high aspiration risk during endoscopic foreign body removal.¹ Latex rubber hoods are not available in Japan. Although large plastic hoods are used for sharp

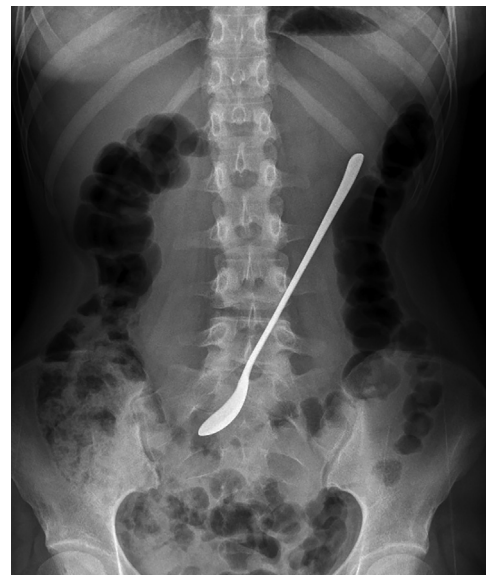

Figure 1. Abdominal roentgenogram revealed a long radiopaque object in the stomach.

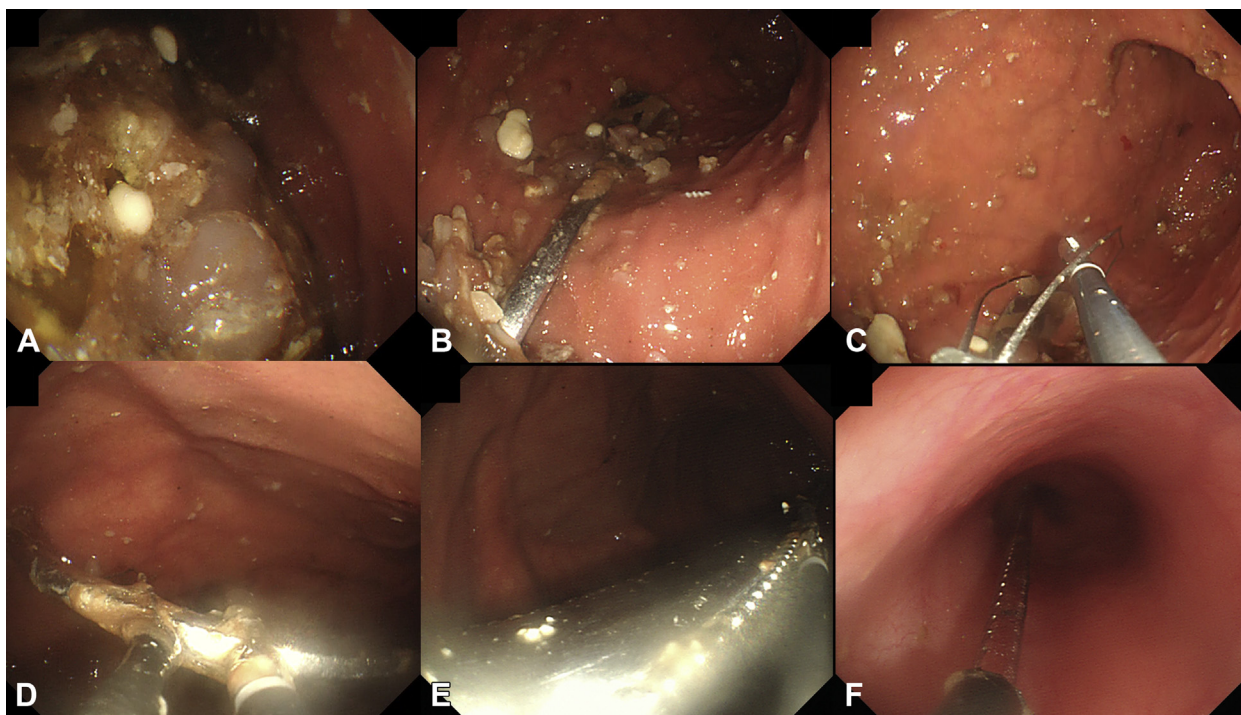


Figure 2. **A**, Significant food residue was observed in the stomach. **B**, A spoon was found in the upper body of the stomach. **C**, A snare and alligator forceps were inserted through the 2-channel endoscope, and forceps was advanced through the snare. **D**, The spoon was held with the forceps and snare side by side, gradually moving toward the edge of the spoon by alternating the opening and closing of each device. **E**, The forceps were extended to push the side of the spoon, making it parallel to the esophagus. **F**, The endoscope was retracted slowly through the esophagus.

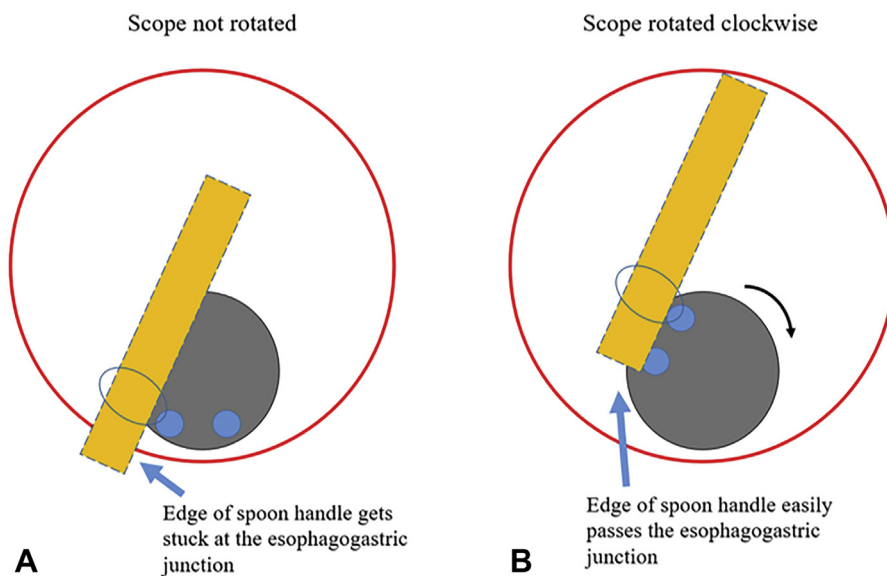


Figure 3. Diagram of the spoon handle passing the esophagogastric junction. **A**, The endoscope (gray circle) slides along the 6 o'clock position within the esophageal lumen (red circle). The snare (blue oval) in the left channel (blue circle) grasps the spoon (orange) in the 7 o'clock position. The short distance between the edge of the spoon handle and the snare causes the spoon to become stuck at the esophagogastric junction. **B**, When the endoscope is twisted clockwise to bring the left channel to the 12 o'clock position, the edge of the spoon handle can pass the esophagogastric junction without touching the mucosa.

objects, we did not use them because the hoods themselves can injure the throat and may hinder endoscopic manipulation or view, and the spoon was

not sharp. Intubation was not performed because the gag reflex of patients with binge-eating/purging-type anorexia is significantly weakened owing to repeated




Figure 4. The 19-cm silver spoon was removed without adverse events.

induction of vomiting. Our patient tolerated the procedure extremely well, without any gag reflex, coughing, or burping.

It is often difficult to grasp long objects at the very edge, which is required to pass them through the esophagogastric junction. Successful spoon removal with a 2-channel endoscope and 2 endoscopic snares has been previously reported.^{5,6} Simultaneous use of alligator forceps and snare can be another useful method for removing long foreign objects.

DISCLOSURE

All authors disclosed no financial relationships.

REFERENCES

1. Birk M, Bauerfeind P, Deprez PH, et al. Removal of foreign bodies in the upper gastrointestinal tract in adults: European Society of Gastrointestinal Endoscopy (ESGE) Clinical Guideline. *Endoscopy* 2016;48:489-96.
2. Limpas Kamiya KJ, Hosoe N, Takabayashi K, et al. Endoscopic removal of foreign bodies: a retrospective study in Japan. *World J Gastrointest Endosc* 2020;12:33-41.
3. Nassar E, Yacoub R, Raad D, et al. Foreign body endoscopy experience of a university based hospital. *Gastroenterology Res* 2013;6:4-9.
4. McKechnie JC. Gastroscopic removal of a phytobezoar. *Gastroenterology* 1972;62:1047-51.
5. Aoyagi K, Maeda K, Morita I, et al. Endoscopic removal of a spoon from the stomach with a double-snare and balloon. *Gastrointest Endosc* 2003;57:990-1.
6. Watanabe T, Aoyagi K, Tomioka Y, et al. Endoscopic removal of a tablespoon lodged within the duodenum. *World J Gastroenterol* 2015;21:5096-8.

Department of Gastroenterology, St. Luke's International Hospital, Tokyo, Japan.

If you would like to chat with an author of this article, you may contact Dr Okamoto at okamotot@luke.ac.jp.

Copyright © 2021 American Society for Gastrointestinal Endoscopy. Published by Elsevier Inc. This is an open access article under the CC BY-NC-ND license (<http://creativecommons.org/licenses/by-nc-nd/4.0/>).

<https://doi.org/10.1016/j.vgje.2021.05.005>

Twitter

Become a follower of *VideoGIE* on Twitter. Learn when new articles are posted and receive up-to-the-minute news as well as links to our latest videos. Search @VideoGIE on Twitter.