

# Corrective Tendon Repair with Local Anesthesia following Wrist-level Replantation

Yi Lu, MD\*

Chi-Ying Hsieh, MD†

Che-Ning Chang, MD‡

Ke-Chung Chang, MD†

Dun-Hao Chang, MD†§¶

**Summary:** Wide-awake local anesthesia with no tourniquet has become a popular method to ensure correct tendon condition intraoperatively. We report the case of a 17-year-old man who underwent nearly total left wrist amputation and successful replantation. The misconnection of flexor tendons between the thumb, index, and middle finger was found postoperatively. At 1.5 months postreplantation, simultaneous tenolysis and corrective tendon repair were performed under local anesthesia. The proximal tendon origins were confirmed intraoperatively with the patient awake. Six months after replantation, the patient underwent extensor pollicis longus tendon shortening and pulley reconstruction under wide-awake local anesthesia with no tourniquet for thumb extension lag. After adequate rehabilitation, the functional outcome was satisfactory. This case report demonstrates that local anesthesia is a judicious method to intraoperatively facilitate correct tendon repair, tension adjustment, and direct conversation between the surgeon and the patient. (*Plast Reconstr Surg Glob Open* 2022;10:e4218; doi: [10.1097/GOX.0000000000004218](https://doi.org/10.1097/GOX.0000000000004218); Published online 17 March 2022.)

Tenolysis and tendon transfer are the most common secondary procedures following distal forearm and wrist replantation. Recently, wide-awake local anesthesia with no tourniquet (WALANT) has become popular in hand tendon surgery because it ensures smooth active tendon gliding and adequate tensile strength during surgery.<sup>1</sup> Here, we present a post-wrist-level replantation case wherein the patient underwent a revision procedure for previous wrongly performed tendon repair, with local anesthesia, which yielded satisfactory results.

## CASE REPORT

A 17-year-old man had undergone successful replantation following nearly total amputation at the left

radiocarpal joint (Fig. 1). However, postoperatively, misconnection of the flexor pollicis longus (FPL) and flexor digitorum superficialis (FDS) tendons of the index and middle fingers, along with severe tendon adhesion, was found. The patient underwent tenolysis and corrective tendon repair 1.5 months after replantation. To obtain better intraoperative assessment and ensure optimal tendon repair, we performed the surgery under local anesthesia with sedation.

During the surgery, the patient was first sedated with propofol, and 80-mL 0.5% lidocaine with 1:200,000 epinephrine was instilled subcutaneously using a 27-gauge needle and 18-gauge blunt tip fat grafting cannula for deeper tissue. After 20 minutes, the skin was incised along the previous scar and dissection proceeded; the patient gradually awakened. Tenolysis was performed at the wrist flexor tendons, FPL tendon, all FDS tendons, and median nerve. The wrongly connected tendons were divided. The proximal tendon origins were identified by pulling the cut ends of the tendon and asking the patient to feel which finger was pulled. Correct tendon repair was further confirmed by the patient's active motion after completion of tenorrhaphy. The surgery took approximately 2 hours, bleeding was minimal, and the analgesic effect remained well without hindering the procedure. Throughout the procedure, no tourniquet was used. Postoperatively, hand and finger circulation remained steady. (See video

From the \*Chang Gung Memorial Hospital, Linkou Branch, Taoyuan, Taiwan; †Division of Plastic and Aesthetic Surgery, Department of Surgery, Far Eastern Memorial Hospital, New Taipei City, Taiwan; ‡Department of General Medicine, Mackay Memorial Hospital, Taipei City, Taiwan; §Department of Information Management, Yuan Ze University, Taoyuan, Taiwan; and ¶School of Medicine, National Yang Ming Chiao Tung University, Taipei, Taiwan.

Received for publication August 27, 2021; accepted February 2, 2022.

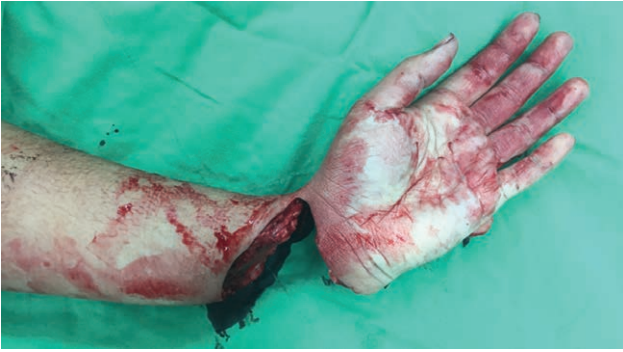Dr. Lu and Dr. Hsieh contributed equally to this work.

Copyright © 2022 The Authors. Published by Wolters Kluwer Health, Inc. on behalf of The American Society of Plastic Surgeons. This is an open-access article distributed under the terms of the [Creative Commons Attribution-Non Commercial-No Derivatives License 4.0 \(CCBY-NC-ND\)](https://creativecommons.org/licenses/by-nc-nd/4.0/), where it is permissible to download and share the work provided it is properly cited. The work cannot be changed in any way or used commercially without permission from the journal.

DOI: [10.1097/GOX.0000000000004218](https://doi.org/10.1097/GOX.0000000000004218)

**Disclosure:** The authors have no interest to declare in relation to the content of this article.

Related Digital Media are available in the full-text version of the article on [www.PRSGlobalOpen.com](http://www.PRSGlobalOpen.com).



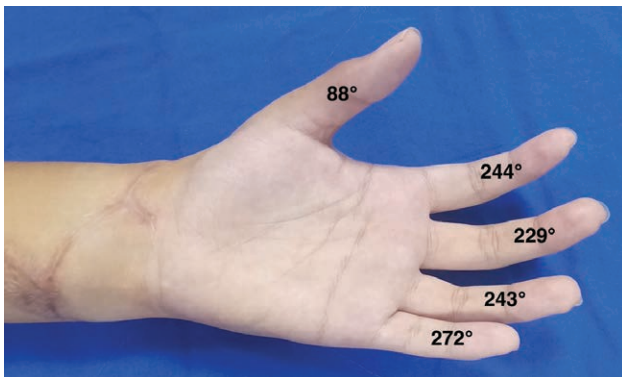
**Fig. 1.** Preoperative picture showing nearly total amputation at left radiocarpal joint.

[online], which provides a summary of the patient's preoperative condition, surgical process, and postoperative outcomes.)

Six months after replantation, the patient underwent tendon shortening and pulley reconstruction under WALANT for the bowstringing and subsequent extension lag of the extensor pollicis longus tendon. The tension on the extensor pollicis longus tendon after shortening was adjusted by intraoperative active extension. After diligent rehabilitation, the total active motion of each digit after 18 months is shown in Figure 2. The final outcome was satisfactory.

## DISCUSSION

Wrist-level replantation has the most favorable outcomes among major limb replantation surgeries, which rely on important basic principles, including immediate aggressive debridement, rigid bone fixation, limited warm ischemia, and sequential soft tissue reconstruction.<sup>2,3</sup> However, in wrist-level replantation, few studies have addressed tendon repair issues with particular reference to the final hand function and requirement of secondary procedures. Some surgeons only repaired the FDP tendons and routinely resected the FDS tendons to avoid future adhesions, and total active motion could be achieved to 50%–70% in Mahajan's study and 70%–80% in Hoang's study.<sup>4,5</sup> However, other authors repaired both FDP and



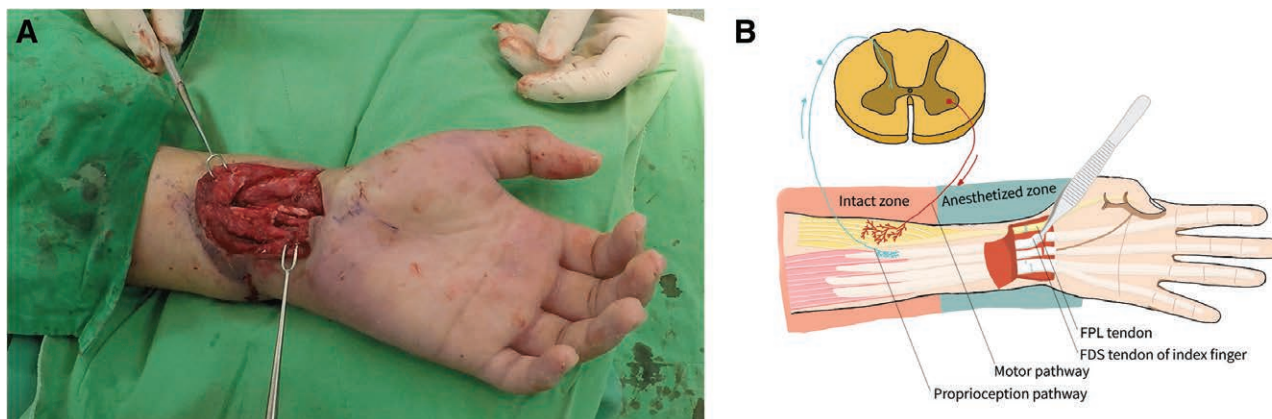
**Fig. 2.** Final result at 18 months. The total active motion of each digit is shown.

FDS tendons. Hanel has suggested using the profundus tendon of the index finger to power the FPL tendon in cases with avulsed FPL muscle belly.<sup>3</sup> However, repair of multiple tendons is time-consuming and will prolong the warm ischemia time before arterial anastomosis. Thus, expeditious repair is mandatory, which can lead to tendon misconnection, similar to our case.<sup>6</sup> To avoid such a complication, familiarity with the regional anatomy is important. Besides, a two-team approach should be used so that one team could focus on the proximal stump to identify and tag all the vessels, nerves, and tendons, while the other team could work on the amputated part. However, this was not feasible in our case because the amputation was not total.

As for the postreplantation tendon mismatch, to perform corrective surgery or let cortical adaptation occur was a dilemma in this case. Considering the patient's occupation (an electromechanical apprentice), we finally decided to perform corrective surgery to achieve better recovery of fine movement. Secondary tendon procedures are typically performed 3–4 months after injury, after obtaining skeletal stability and good soft tissue coverage.<sup>7</sup> However, because the tendons had to be cut and re-repaired to shorten the total tendon-healing duration, we performed the procedure at a relatively early stage. Although the secondary procedure per se would not lead to ischemia of the replanted part, using a tourniquet after 1.5 months replantation was still a risk; therefore, we chose local anesthesia instead. In Patel's study involving six wrist-level replantation cases, one patient had undergone extensive volar, and dorsal tenolysis 9 weeks after replantation. During the surgery, the patient had hand ischemia, requiring arterial reconstruction with a vein graft to restore circulation. Although the anesthesia method is unknown, general anesthesia with a tourniquet is speculated.<sup>8</sup> Local anesthesia with no tourniquet might have avoided this complication, although this would require more clinical evidence to prove.

At 1.5 months postreplantation, severe tendon adhesion was observed, compromising the preoperative examination. Performing the surgery under local anesthesia allowed the tendon conditions to be checked intraoperatively after tenolysis, ensuring the accuracy of the secondary tendon repair. The tendon origins were confirmed by the patient's active movement and passive stretch of certain muscles/tendons (Fig. 3A, B). The active and passive motions require intact motor and proprioception functions, respectively. Local anesthesia will not affect the motor neurons, Golgi tendon organ, and muscle spindle located in the proximal forearm flexors, whereas these will be impaired by general anesthesia or regional nerve block.<sup>9</sup>

Some studies have addressed the advantages of WALANT in primary tendon repair or secondary tendon reconstruction. Some authors have proposed modifying the technique, such as brief tourniquet use and sedation.<sup>10</sup> Brief use of a tourniquet at the beginning of the surgery can achieve bloodless dissection until the maximal epinephrine effect has occurred. In this postreplantation patient, we did not use a tourniquet at all, although there was still some bleeding. Dissection was performed



**Fig. 3.** Secondary tendon revision under local anesthesia. A, Intraoperative view. B, Schematic diagram showing the way to confirm proximal tendon origins: (1) passive stretch of the index flexor digitorum superficialis tendon and (2) active contraction of the flexor pollicis longus tendon. These relied on the intact proprioception and motor function, which were not affected by local anesthesia.

smoothly using suction and electrocautery. Temporary sedation, or the so-called monitored anesthesia care, can provide the patient a pain-free experience during local anesthetic injection. Monitored anesthesia care combined with local anesthesia is adopted for nervous patients or those requiring a larger amount of anesthetics, as with the first tendon revision surgery in this report. However, for other simple procedures (eg, single tendon tenolysis and trigger finger release), pure WALANT is preferred to save time and cost.

Besides the accuracy of tendon repair, patients undergoing surgery under local anesthesia can tolerate early active digital motion during rehabilitation, confirming that the repair is strong enough as assessed using extension–flexion tests. For tendon shortening or lengthening procedures, WALANT facilitates tension adjustment intraoperatively, similar to the revision surgery of the extensor pollicis longus tendon in the patient in this report. Furthermore, an awake patient will be responsive to communication from the operating surgeon during the procedure, which can be crucial. Finally, WALANT avoids using anesthesia machinery and requires fewer medical personnel; such features are desirable during the COVID-19 pandemic.

This report demonstrated the technique and benefit of performing secondary tendon reconstruction in a patient who underwent wrist replantation under local anesthesia. The feasibility and effectiveness of local anesthesia or WALANT have been proven by many studies. It can be more beneficial when dealing with multiple tendon injuries. It is not only a safe anesthesia but also provides the opportunity to foresee the results during surgeries.

**Dun-Hao Chang, MD**

Division of Plastic and Aesthetic Surgery  
Department of Surgery

Far Eastern Memorial Hospital  
New Taipei City  
Taiwan  
No. 21, Sec. 2, Nanya S. Rd.  
Banciao Dist., New Taipei City  
Taiwan

#### ACKNOWLEDGMENT

*The study has approved by the institutional review board of Far Eastern Memorial Hospital.*

#### REFERENCES

1. Tang JB. Wide-awake primary flexor tendon repair, tenolysis, and tendon transfer. *Clin Orthop Surg.* 2015;7:275–281.
2. Wang C, Askari M, Zhang F, et al. Long-term outcomes of arm replantation. *Ann Plast Surg.* 2020;84(3S Suppl 2):S151–S157.
3. Hanel DP, Chin SH. Wrist level and proximal-upper extremity replantation. *Hand Clin.* 2007;23:13–21.
4. Mahajan RK, Mittal S. Functional outcome of patients undergoing replantation of hand at wrist level-7 year experience. *Indian J Plast Surg.* 2013;46:555–560.
5. Hoang NT. Hand replantations following complete amputations at the wrist joint: first experiences in Hanoi, Vietnam. *J Hand Surg Br.* 2006;31:9–17.
6. Ng N, Das De S, Chong AKS. Secondary procedures after severe upper extremity injury. *J Hand Surg Asian Pac Vol.* 2021;26:152–157.
7. Sabapathy SR, Bhardwaj P. Secondary procedures in replantation. *Semin Plast Surg.* 2013;27:198–204.
8. Patel AA, Blount AL, Owens PW, et al. Functional outcomes of replantation following radiocarpal amputation. *J Hand Surg Am.* 2015;40:266–270.
9. Paqueron X, Leguen M, Gentili ME, et al. Influence of sensory and proprioceptive impairment on the development of phantom limb syndrome during regional anesthesia. *Anesthesiology.* 2004;100:979–986.
10. Gao LL, Chang J. Wide awake secondary tendon reconstruction. *Hand Clin.* 2019;35:35–41.