

Static versus Expandable Interbody Fusion Devices: A Comparison of 1-Year Clinical and Radiographic Outcomes in Minimally Invasive Transforaminal Lumbar Interbody Fusion

Jonathan Andrew Ledesma, Mark J. Lambrechts, Azra Dees, Terence Thomas,
Cannon Greco Hiranaka, Mark Faisal Kurd, Kris E. Radcliff, David Greg Anderson

Rothman Orthopaedic Institute, Thomas Jefferson University, Philadelphia, PA, USA

Study Design: Retrospective cohort study.

Purpose: To compare the radiographic and clinical outcomes of static versus expandable interbody cages in transforaminal lumbar interbody fusion using minimally invasive surgery (MIS-TLIF).

Overview of Literature: Expandable interbody cages may potentially improve radiographic and clinical outcomes following MIS-TLIF compared to static cages, but at a potentially higher cost and increased rates of subsidence.

Methods: A retrospective chart review of 1- and 2-level MIS-TLIFs performed from 2014 to 2020 was reviewed. Radiographic measurements were obtained preoperatively, 6 weeks postoperatively, and at final follow-up. Patient-reported outcome measures (PROMs) including the Oswestry Disability Index, Visual Analog Scale (VAS) back, and VAS leg were evaluated. Multivariate linear regression analysis determined the effect of cage type on the change in PROMs, controlling for demographic characteristics. Alpha was set at 0.05.

Results: A total of 221 patients underwent MIS-TLIF including 136 static and 85 expandable cages. Expandable cages had significantly greater anterior (static: 11.41 mm vs. expandable: 13.11 mm, $p < 0.001$) and posterior disk heights (static: 7.22 mm vs. expandable: 8.11 mm, $p < 0.001$) at 1-year follow-up. Expandable cages offered similar improvements in segmental lordosis at 6 weeks (static: 1.69° vs. expandable: 2.81°, $p = 0.243$), but segmental lordosis was better maintained with expandable cages leading to significant differences at 1-year follow-up (static: 0.86° vs. expandable: 2.45°, $p = 0.001$). No significant differences were noted in total complication (static: 12.5% vs. expandable: 16.5%, $p = 0.191$) or cage subsidence rates (static: 19.7% vs. expandable: 22.4%, $p = 0.502$) groups at 1-year follow-up.

Conclusions: Expandable devices provide greater improvements in radiographic measurements including anterior disk height, posterior disk height, and segmental lordosis, but this did not lead to significant improvements in PROMs, complication rates, subsidence rates, or subsidence distance.

Keywords: Spine; Minimally invasive; Fusion; Expandable; Radiographic

Received Dec 4, 2021; Revised Jan 17, 2022; Accepted Jan 26, 2022

Corresponding author: Jonathan Ledesma Andrew

Rothman Orthopaedic Institute, Thomas Jefferson University, Philadelphia, PA, USA

Tel: +1-4086271052, Fax: +1-267-479-1321, E-mail: jal044@students.jefferson.edu

Introduction

Transforaminal lumbar interbody fusion using minimally invasive surgery (MIS-TLIF) has become a popular method for treating various degenerative conditions of the lumbar spine [1,2]. The use of an interbody cage to maintain or expand the intervertebral distance allows for indirect neuroforaminal decompression, anterior intervertebral fusion, and sagittal alignment restoration [3,4]. Despite the usage of various cages, certain device-related concerns remain, such as cage subsidence and/or suboptimal postoperative lordosis [5], which may lead to suboptimal patient outcomes [5-7].

Expandable interbody technology has been a relatively recent development with current cages existing in a wide variety of materials, footprints, and geometries (Fig. 1). The collapsible profile of expandable cages allows for device introduction while collapsed, followed by expansion within the disk space, minimizing neural tissue retraction and optimizing disk space distraction. This concept has the potential to reduce impaction forces, which could theoretically damage the bony endplate, increasing the risk of device subsidence. Certain expandable cages also allow for increased segmental lordosis, which may also improve sagittal alignment. Finally, some expandable cages can enlarge the surface area of their footprint, thus improving the contact area of the device and reducing the risk for postoperative subsidence [8].

Some studies on this topic have reported greater improvements in disk height and segmental lordosis with expandable cages [9-13]. However, due to the limited

footprint and contact surface, there are concerns that excessive endplate stress could result in mechanical construct failure or interbody subsidence [14,15]. However, this is a controversial topic and has not been universally found [16]. As a result, current literature remains inconclusive regarding the overall efficacy of expandable compared to static implants [7,9,11]. Furthermore, expandable cages are frequently more expensive, with some costing as much as \$5,000 [17], prompting some to question whether expandable cages have a favorable cost-benefit ratio in today's value-based decision-making environment.

Therefore, the primary goal of this study is to retrospectively review the radiographic outcomes of expandable and static MIS-TLIF interbody devices. Our secondary goal was to see if using expandable or static interbody devices resulted in better patient-reported outcome measures (PROMs) or higher complication rates.

Materials and Methods

1. Study design and demographics

After obtaining Institutional Review Board approval (IRB control #19E.920, Thomas Jefferson University), a retrospective review for all patients undergoing MIS-TLIF at the Rothman Orthopaedic Institute and Thomas Jefferson University Hospitals was performed. The requirement for informed consent from individual patients was omitted because of the retrospective design of this study. From 2014 to 2020, 221 patients underwent elective 1- or 2-level MIS-TLIF by three surgeons, and demographic data in-

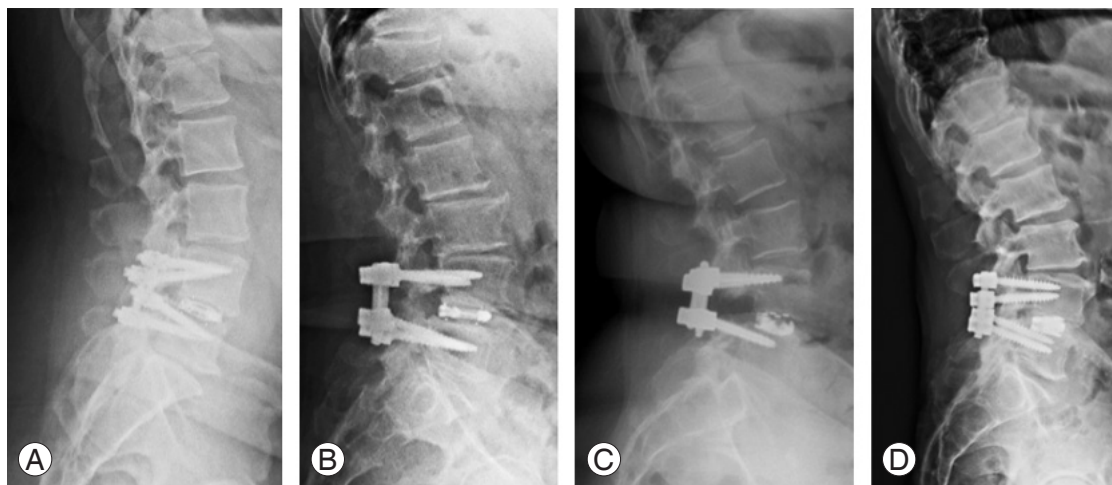


Fig. 1. (A-D) Postoperative radiographs demonstrating examples of expandable interbody devices used.

cluding age, body mass index (BMI), gender, and device details were obtained from electronic medical records. Patients with less than 3 months of radiographic follow-up and 1 year of clinical follow-up or those treated for trauma, tumor, or infection were excluded. Patients were stratified into two cohorts: those treated with a static interbody cage and those treated with an expandable cage.

2. Surgical technique

At our institution, MIS-TLIF is performed using a posterior paramedian incision of approximately 2 cm. The intervertebral disc space was widened using a trial expandable implant after discectomy and endplate preparation. The disk space was filled with local autograft and allograft chips after the appropriate trial was selected. The implant is then packed with local autograft and inserted into the disk space via a transforaminal approach. To achieve the best lordosis correction, all expandable devices were fully expanded. All procedures involved the use of bilateral pedicle screws.

3. Radiographic and clinical outcome measures

Standing lateral lumbar spine radiographs were evaluated to assess anterior and posterior disc heights, anterior and posterior cage heights, segmental lordosis, and cage position within the disc space (distance from the anterior cage marker to the anterior margin of the lower vertebral body) preoperatively, 6 weeks postoperatively, and 1 year postoperatively. A Δ value for each measurement was calculated and defined as the postoperative minus the preoperative measurement. IDS 7 imaging software for Windows (Sectra, Linköping, Sweden) was used to take radiographic measurements. Radiographic parameters were determined by placing metallic markers within the cages at the anterior and posterior device borders. Segmental lordosis was measured as the lateral Cobb angle from the inferior endplate of the superior vertebral body relative to the superior endplate of the inferior vertebral body (Fig. 2). Postoperative radiographs were examined for evidence of cage subsidence, defined as a vertical breach of the interbody device's margin into the superior or inferior endplate of the vertebral body >2 mm. Radiographic values for two-level procedures were obtained from the averages of the individual levels measured.

PROMs were obtained from the OBERD software sys-

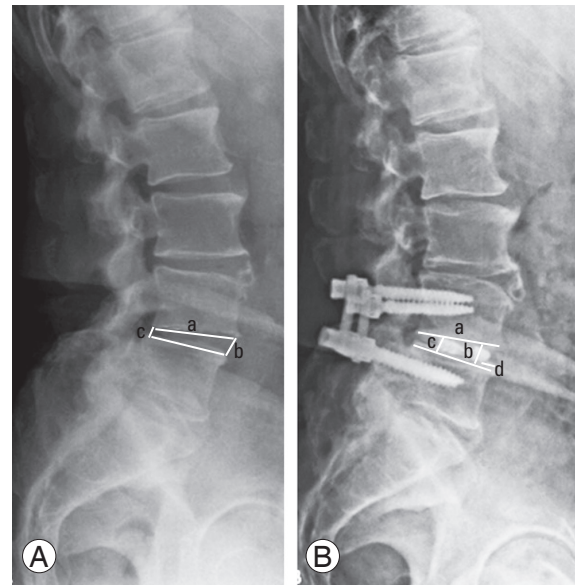


Fig. 2. (A) Preoperative and (B) postoperative lateral radiographs demonstrating measurements used. (A) Preoperative measurements include (a) segmental lordosis, (b) anterior disc height, and (c) posterior disc height. (B) Postoperative measurements include (a) segmental lordosis, (b) anterior disc height, (c) posterior disc height, and (d) anteroposterior cage position.

tem (Columbia, MO, USA) using Oswestry Disability Index (ODI), Visual Analog Scale (VAS) back, and VAS leg pain scores. A Δ value, as described above, was calculated for each PROM. The minimally clinically important difference (MCID) for each PROM was determined using previously established cutoffs: ODI 8.2 points, VAS back 2.2 points, and VAS leg 5.0 points [18,19]. Rates of 90-day readmissions, revision surgery, development of adjacent segment disease, durotomy, and radiculitis were among the complications investigated. Radiculitis was defined as the recurrence of radicular symptoms after the postoperative resolution, with no evidence of neurologic involvement on follow-up magnetic resonance imaging or computed tomography imaging.

4. Statistical methods

Statistical analysis was performed using IBM SPSS ver. 27.0.0 for Mac (IBM Corp., Armonk, NY, USA). Comparison of means for continuous variables between groups was performed using Student *t*-test. Mann-Whitney *U*-test was used to compare means for non-parametric variables and for distributions that did not pass the Shapiro-Wilk test for normality. Preoperative and postoperative variables for the same patients were compared using paired

Student *t*-test, whereas Wilcoxon signed-rank test was used for non-parametric variables. Spearman's correlation coefficient was used to assess the relationship between non-parametric variables. A multivariate linear regression analysis was used to determine the effect of cage type on perioperative PROM change while controlling for age, biological sex, BMI, and perioperative diagnosis. Statistical significance was set at $p < 0.05$ for all cases.

Results

1. Patient demographics and surgical characteristics

This study included 221 patients, of which, 136 patients had a static and 85 had an expandable cage. In the expandable and static cage groups, titanium and polyether ether ketone (PEEK) materials with varying degrees of built-in lordosis were used (Appendix 1). The static group was significantly younger (62.9 ± 11.7 years versus 67.6 ± 10.4 years, $p < 0.001$), but there was no difference in mean BMI (30.1 ± 5.59 kg/m² versus 30.8 ± 7.34 kg/m², $p = 0.33$), sex (55.1% versus 52.6% female, $p = 0.86$), or length of follow-up (13.3 ± 6.54 months versus 12.4 ± 8.12 months, $p = 0.31$). Of the 136 patients in the static group, 125 patients underwent single-level MIS-TLIF versus 68 of 85 in the expandable group ($p = 0.03$). Of the 28 patients with two-level MIS-TLIFs, 11 patients had a static cage versus 17 who had an expandable cage ($p = 0.25$). There was no difference in the total complication rate (static: 12.5% versus expandable: 16.5%, $p = 0.191$), 90-day readmission rate ($p = 0.641$), or rate of revision surgery ($p = 0.847$) (Table 1).

2. Radiographic outcomes

There were no significant differences in the preoperative anterior ($p = 0.552$) or posterior disk height ($p = 0.893$) between groups with both having significant increases at 6 weeks (static: 3.46 ± 2.94 versus expandable: 5.26 ± 3.44 , both $p < 0.001$) and 1 year postoperatively (static: 2.61 ± 3.06 versus expandable: 4.58 ± 3.51 , both $p < 0.001$). However, there were significant differences in the mean and Δ anterior disk height (all $p < 0.001$) and mean and Δ posterior disk height at both 6 weeks (postoperative: $p = 0.002$, Δ : $p = 0.007$) and 1 year (postoperative: $p = 0.001$, 1-year Δ : $p = 0.007$) postoperatively favoring the expandable group. Additionally, there were no significant differences in preoperative ($p = 0.832$), 6-week postoperative

Table 1. Patient demographics and operative data

Characteristic	Static (n=136)	Expandable device (n=85)	<i>p</i> -value
Age (yr)	62.9±11.7	67.6±10.4	<0.001*
Sex			
Male	61	40	0.86
Female	75	45	
Body mass index (kg/m ²)	30.1±5.59	30.8±7.34	0.33
Latest follow-up (mo)	13.3±6.54	12.4±8.12	0.31
Preoperative diagnosis			<0.001*
Spondylolisthesis	64 (46.7)	39 (46.4)	
Stenosis	56 (40.9)	32 (38.1)	
Disc herniation	12 (8.8)	8 (9.5)	
Deformity	4 (2.92)	6 (7.14)	
Total operative levels	148	102	0.11
T12–L1	1 (0.68)	0	
L1–L2	0	2 (1.9)	
L2–L3	3 (2.0)	6 (5.9)	
L3–L4	21 (14.2)	18 (17.7)	
L4–L5	89 (60.1)	58 (56.9)	
L5–S1	34 (22.9)	17 (16.7)	
Single level procedures			0.03*
T12–L1	1 (0.8)	0	
L1–L2	0	2 (2.9)	
L2–L3	3 (2.4)	6 (19.1)	
L3–L4	17 (13.6)	13 (20.6)	
L4–L5	78 (62.4)	41 (60.3)	
L5–S1	27 (16.5)	5 (7.4)	
Total	125	68	
Multi-level procedures			0.25
L3–L5	4 (36.4)	5 (29.4)	
L4–S1	7 (63.6)	12 (70.6)	
Total	11	17	
Postoperative complications (%)			
Total complications	12.5	16.5	0.191
90-Day readmission	1.5	2.3	0.641
Revision surgery	1.5	1.2	0.847
Adjacent segment disease	5.1	4.7	0.839
Durotomy	2.2	3.5	0.953
Radiculitis	2.2	4.5	0.538

Values are presented as mean±standard deviation, number, or number (%).
* $p < 0.05$; significant values.

Table 2. Comparison of radiographic parameters preoperatively, at 6-week follow-up, and 1-year follow-up

Variable	Static (n=136)	Expandable (n=85)	p-value
Anterior disc height (mm)			
Preoperative	8.8±3.47	8.53±3.52	0.552
6 Weeks postoperative	12.26±2.57	13.79±2.78	<0.001*
6-Week Δ value	3.46±2.94	5.26±3.44	<0.001*
p-value	<0.001*	<0.001*	<0.001*
1 Year postoperative	11.41±2.56	13.11±2.96	<0.001*
1-Year Δ value	2.61±3.06	4.58±3.51	<0.001*
p-value	<0.001*	<0.001*	
Posterior disc height (mm)			
Preoperative	5.56±2.23	5.63±2.25	0.893
6 Weeks postoperative	7.76±2.25	8.69±2.25	0.002*
6-Week Δ value	2.19±2.20	3.08±3.08	0.007*
p-value	<0.001*	<0.001*	
1 Year postoperative	7.22±2.15	8.11±2.09	0.001*
1-Year Δ value	1.65±2.47	2.50±2.56	0.007*
p-value	<0.001*	<0.001*	
Segmental lordosis (°)			
Preoperative	5.58±4.32	5.44±4.15	0.832
6 Weeks postoperative	7.28±8.49	8.25±4.18	0.294
6-Week Δ value	1.69±8.69	2.81±2.81	0.243
p-value	0.014*	0.002*	
1 Year postoperative	6.26±3.45	7.89±4.25	0.001*
1-Year Δ value	0.86±4.09	2.45±4.11	0.001*
p-value	<0.001*	0.002*	
Interval loss in lordosis (°)	-0.81±6.00	-0.18±1.53	0.012*
Device measurements			
Anterior device height at 6 weeks (mm)	7.10±3.87	11.8±2.84	<0.001*
Posterior device height at 6 weeks (mm)	6.93±2.70	10.0±1.79	<0.001*
Cage placement at 6 weeks (mm)	9.66±4.29	4.29±2.84	<0.001*
Cage placement at 1 year (mm)	9.56±5.13	4.97±4.42	<0.001*
Mean change in position	0.10±3.29	0.54±2.32	
p-value	0.62	<0.001*	
Subsidence measurements			
Subsidence at 6-week follow-up (%)	18.1	20.0	0.632
Mean subsidence at 6 weeks (mm)	4.50±1.91	4.25±2.16	0.591
Subsidence at 1-year follow-up (%)	19.7	22.4	0.502
Mean subsidence at 1 year (mm)	4.71±2.34	4.78±2.55	0.894

Values are presented as mean±standard deviation or %, unless otherwise stated.

* $p < 0.05$; significant values.

($p=0.294$), or 6-week Δ ($p=0.243$) segmental lordosis between groups, with both having a significant increase in 6-week (static: $1.69^\circ \pm 8.69^\circ$, $p=0.014$ versus expandable:

$2.81^\circ \pm 2.81^\circ$, $p=0.002$) and 1-year segmental lordosis (static: $0.86^\circ \pm 4.09^\circ$, $p < 0.001$ versus expandable: $2.45^\circ \pm 4.11^\circ$, $p=0.002$). Segmental lordosis was better maintained with

expandable cages leading to significant differences at 1-year follow-up (static: 0.86° versus expandable: 2.45° , $p=0.001$). The interval loss of lordosis between 6 weeks and 1 year was significantly less in the expandable group (static: $-0.81^\circ \pm 6.00^\circ$ versus expandable: $-0.18^\circ \pm 1.53^\circ$, $p=0.012$) (Table 2). No significant differences in any radiographic parameters including subsidence were noted between 1- and 2-level procedures within cage groups (Appendices 2, 3).

Cage subsidence was measured at 6 weeks and 1 year postoperatively, with comparisons made between these two-time points (Table 2). No significant differences were observed in percentage of patients demonstrating cage subsidence between static and expandable groups at 6-week (static: 18.1% versus expandable: 20.0%; odds ratio [OR], 0.89; 95% confidence interval [CI], 0.54–1.46; $p=0.632$) or 1-year follow-up (static: 19.7% versus expandable: 22.4%; OR, 0.85; 95% CI, 0.53–1.37; $p=0.502$), though both groups demonstrated a slight increase in subsidence throughout the postoperative period. No significant differences were found for the mean magnitude of subsidence between groups at 6-week (static: 4.50 ± 1.91 mm versus expandable: 4.25 ± 2.16 mm, $p=0.59$) and 1-year follow-up (static: 4.71 ± 2.34 mm versus expandable: 4.78 ± 2.55 mm, $p=0.894$).

3. Interbody device-related measures

The mean anterior and posterior cage heights for the static group at 6-week follow-up measured 7.10 ± 3.87 and 6.93 ± 2.70 mm, respectively (Table 2). The mean anterior and posterior cage heights for the expandable group at 6-week follow-up were 11.8 ± 2.84 and 10.0 ± 1.79 mm, respectively. The expandable group had significantly higher anterior and posterior device heights ($p < 0.001$ for each). There were no significant changes in anterior or posterior cage height between follow-up time points.

At 6-week follow-up, the mean position of static cages were more posterior than that of expandable cages (static: 9.66 ± 4.29 mm versus expandable: 4.29 ± 2.84 mm, $p < 0.001$) (Table 2). This difference was maintained at 1 year postoperatively (static: 9.56 ± 5.13 mm versus expandable: 4.97 ± 4.42 mm, $p < 0.001$). Significant differences in cage position at 6-week follow-up were noted between the individual surgeons participating in the study (8.25 ± 4.82 mm versus 4.25 ± 4.48 mm, $p < 0.001$), suggesting differences in technique that might partially explain this finding. No sig-

Table 3. Spearman correlation coefficients for association of cage positioning with anterior disc height, posterior disc height, and segmental lordosis in expandable cages

Variable	Spearman's Rho	p-value
6-Week follow-up		
Anterior disc height	0.014	0.892
Posterior disc height	0.18	0.079
Segmental lordosis	-0.08	0.405
1-Year follow-up		
Anterior disc height	0.11	0.292
Posterior disc height	-0.09	0.390
Segmental lordosis	0.15	0.125

nificant correlation was found between cage placement and anterior (6 weeks: $p=0.892$, 1 year: $p=0.292$) and posterior disk heights (6 weeks: $p=0.079$, 1 year: $p=0.390$) or segmental lordosis (6 weeks: $p=0.405$, 1 year: $p=0.125$) in the expandable group at 6-week and 1-year follow-up (Table 3).

4. Patient-reported outcome measures

Both cage types offered statistically significant improvements in all PROMs at 3-month and 1-year follow-up ($p < 0.001$ for all) (Table 4). No significant differences in ODI (3 months postoperative: $p=0.775$, 3-month Δ : $p=0.243$; 1 year postoperative: $p=0.783$, 1-year Δ : $p=0.247$), VAS back (3 months postoperative: $p=0.318$, 3-month Δ : $p=0.971$; 1 year postoperative: $p=0.331$, 1-year Δ : $p=0.074$), and VAS leg (3 months postoperative: $p=0.249$, 3-month Δ : $p=0.691$; 1 year postoperative: $p=0.891$, 1-year Δ : $p=0.748$) were noted between groups at both time points. When controlling for patient demographic data, linear regression analysis revealed no significant associations between cage type and changes in PROMs. There were no significant differences between static and expandable groups in the proportion of patients who reached the MCID at 1 year for ODI, VAS back, and VAS leg (Table 5).

Discussion

Although MIS-TLIF is a common procedure, differences in surgical technique and cage preferences have made it difficult to determine if static or expandable cages are superior. Previous studies have demonstrated mixed results regarding postoperative radiographic and clinical out-

Table 4. Patient-reported outcomes at 3-month and 1-year follow-up

Variable	Static (n=136)	Expandable (n=85)	p-value	Regression analysis	
				β (95% CI)	p-value
3-Month follow-up					
ODI				2.49 (1.46 to 3.45)	0.589
Preoperative	51.56±12.32	49.15±14.44	0.212		
Postoperative	24.56±18.06	25.29±18.49	0.775		
Δ Value	26.89±18.92	23.87±17.76	0.243		
p-value	<0.001*	<0.001*			
VAS back				3.84 (2.36 to 5.32)	0.696
Preoperative	7.06±1.88	6.70±1.81	0.174		
Postoperative	3.64±2.45	3.31±2.31	0.318		
Δ Value	3.39±2.69	3.38±2.42	0.971		
p-value	<0.001*	<0.001*			
VAS leg				-1.92 (-3.54 to 0.29)	0.696
Preoperative	6.61±2.07	6.32±2.58	0.361		
Postoperative	3.27±2.65	2.82±3.03	0.249		
Δ Value	3.34±2.62	3.51±2.93	0.691		
p-value	<0.001*	<0.001*			
1-Year follow-up					
ODI				2.47 (1.32 to 3.17)	0.424
Preoperative	51.56±12.32	49.15±14.44	0.212		
Postoperative	24.56±18.06	25.29±18.49	0.783		
Δ Value	26.89±18.92	23.87±17.76	0.247		
p-value	<0.001*	<0.001*			
VAS back				4.81 (3.19 to 6.42)	0.603
Preoperative	7.06±1.88	6.70±1.81	0.174		
Postoperative	3.15±2.36	3.49±2.68	0.331		
Δ Value	3.91±2.79	3.21±2.72	0.074		
p-value	<0.001*	<0.001*			
VAS leg				3.05 (1.39 to 4.70)	0.883
Preoperative	6.61±2.07	6.32±2.58	0.361		
Postoperative	2.66±2.69	2.61±2.93	0.891		
Δ Value	3.96±2.78	3.83±2.97	0.748		
p-value	<0.001*	<0.001*			

Values are presented as mean±standard deviation, unless otherwise stated. CI, confidence interval; ODI, Oswestry Disability Index; VAS, Visual Analog Scale. *p<0.05; significant values.

comes after utilization of expandable compared to static cages [9-13,20]. According to some studies, expandable cages are associated with an increased risk of intraoperative endplate subsidence due to the high expansion forces applied by expandable devices' relatively small footprint [14,15,21]. In our study, we analyzed our experience with

Table 5. Minimally clinically important difference at 1-year follow-up

Variable	Static (n=136)	Expandable (n=85)	p-value
ODI (%)	84.6	77.6	0.405
VAS back (%)	72.1	60.0	0.121
VAS leg (%)	30.9	34.1	0.511

ODI, Oswestry Disability Index; VAS, Visual Analog Scale.

static and expandable cages for MIS-TLIF to better understand the risks and benefits between cage types. Our findings indicate that expandable cages result in greater improvements in anterior and posterior disk heights at 3-month and 1-year follow-up, as well as improved segmental lordosis at 1-year follow-up. Our study found no differences between groups in PROMs, postoperative complication and subsidence rates, or mean subsidence distance.

Various studies have reported favorable radiographic results with expandable cages for MIS-TLIF [9,22,23]. Kim et al. [22] assessed the radiographic outcomes in a cohort of 50 expandable cages and reported significant increases in the disk and foraminal heights that were maintained 2 years postoperatively. Similarly, Massie et al. [24] examined the outcomes of 39 patients and found significant increases in disk height at all time points up to a maximum of 2 years after surgery. Overall, our findings are consistent with previous research, which found that our expandable group experienced significant restoration and maintenance of disk height after a year.

Conversely, a previous study indicated minimal benefit with expandable cages. A large meta-analysis that evaluated clinical and radiographic outcomes of both cage types across 12 studies identified a significant increase in mean disk height with static cages [12]. Two additional studies found no significant differences in disk height with expandable cages [20,24]. A recent multi-surgeon review found no significant differences in mean disk height or anterior and posterior disk heights change between cage types [20]. Additionally, they noted that cage design did not significantly affect changes in segmental lordosis ($p=0.237$) [20]. These results are in concordance with an earlier assessment that described no differences in disk height ($p=0.769$) or foraminal height ($p=0.771$) at 6 weeks postoperatively [25].

Expandable devices have been suggested as a solution to the challenge of obtaining adequate segmental lumbar lordosis in the setting of MIS-TLIF [12,26]. Failure to restore lordosis adequately increases the likelihood of continued lumbago, biomechanical instability, and uneven loading across the posterior spinal column [5,6,26]. Several studies documented significant increases in segmental lordosis with expandable cages [10,12,23-25,27]. Notably, one study found that using expandable devices across two levels resulted in greater segmental and regional lumbar lordosis [25]. However, there is still no agreement on the

efficacy of expandable cages in achieving adequate postoperative lordosis [10-12]. Vaishnav et al. [11] concluded that expandable cages do not improve segmental lordosis but provide significantly greater posterior disk height postoperatively. Despite reporting greater increases in disk height in their static cohort, Alvi et al. [12] reported approximately 3° of improved segmental lordosis in the expandable group after a mean 15.5-month follow-up with no difference in regional lordosis. Our study found that segmental lordosis was improved by approximately 1.5° in the expandable group. The clinical significance of a 1.5°–3.0° improvement in a single- or two-level procedure, on the other hand, is likely negligible, though this benefit may be additive in multi-level procedures. Long-term follow-up studies are therefore required to confirm the significance of marginal improvements in segmental lordosis and their overall impact on sagittal alignment and long-term patient outcomes.

Consistent with prior studies, we noted statistically significant perioperative improvements in PROMs in both groups at 3-month and 1-year follow-up [9,22-25]. However, there were no differences in PROMs at each time point when groups were compared. Multiple linear regression analysis revealed no significant relationships between cage type and PROM improvement. Furthermore, the proportion of patients who met MCID at 1 year did not differ significantly between groups. Smaller retrospective studies highlighted inconsistencies in PROM improvements with expandable versus static cages [9,10]. While one study noted greater improvements in ODI in expandable devices, the other study observed no significant differences in ODI, VAS back, or VAS leg at 5-week, 12-week, and 6-month follow-up [9]. The latter study also found that the proportions of patients achieving MCID in all three PROMs were similar across cage types. Furthermore, despite the theoretically higher adjacent segment disk pressure applied by expandable cages, no significant differences in rates of adjacent segment disease were observed [28]. These results are supported by the meta-analysis by Alvi et al. [12], which noted no significant difference in clinical outcomes between cage types.

This study also explored the relationship between cage placement and radiographic outcomes. Kepler et al. [29] described their findings over 45 single-level TLIFs and described a significant positive correlation between cage placement and change in disk height ($p=-0.37$, $p=0.01$), suggesting that more anterior cage positioning allows the

spacer to act as a fulcrum to achieve greater lordosis. They discovered no link between cage position and changes in lumbar lordosis. Similar findings were reported by Vaishnav et al. [11], who found no link between cage position and postoperative radiographic measures. In our study, expandable cages were preferentially placed more anteriorly in the disk space to maximize improvements in disk height and lordosis following expansion. Furthermore, when expanded, expandable devices shorten their anterior and posterior lengths, which may account for their more anterior placement. However, no correlations were found between cage position and changes in any radiographic parameters.

Endplate subsidence remains a common concern with MIS-TLIF. Although biplanar expandable devices have theoretically reduced subsidence risk due to larger footprints achieved through horizontal expansion [30], other studies demonstrated higher subsidence risk due to inadvertent application of excessive endplate pressures during cage deployment [14,15,20]. Notably, both cohorts in our study had comparable subsidence rates, implying that disk space preparation and bone quality were likely more important factors in subsidence risk than device type.

Limitations of this study stem from its retrospective non-randomized design. Selection bias could impact analysis due to the lack of elimination of surgeon preference for surgical technique. A higher proportion of older patients in the expandable group could also have influenced the analysis. Although it might be expected that poorer bone quality in older patients would result in greater subsidence with expandable devices, this was not observed. While multivariate linear regression was performed to control for demographic data, confounding variables such as heterogeneity in cage design and materials such as the use of both titanium and PEEK cages may have influenced our results. These limitations are mitigated in part by the large sample size, multi-surgeon experience, and careful examination of radiographic variables by multiple investigators.

Conclusions

Our study suggests that expandable cages in patients who underwent MIS-TLIF provided increased anterior and posterior disc heights at 6 weeks and 1 year postoperatively. Expandable cages also better-maintained improvements in segmental lordosis at 1 year postoperatively.

Although expandable devices were placed more anteriorly in the disc space, no associations were found between anteroposterior cage position and any radiographic parameter. Furthermore, there was no significant difference in subsidence rate, endplate disruption, the patient-reported outcome measures, or perioperative complications. Our study indicates that there is a substantial need for high-quality long-term studies evaluating the cost-benefit ratio of the improved radiographic parameters of expandable cages given their increased cost and lack of short-term clinical improvements.

Conflict of Interest

No potential conflict of interest relevant to this article was reported.

Acknowledgments

The authors wish to thank Matthew Sherman for his technical assistance with statistical analysis.

References

1. Khan NR, Clark AJ, Lee SL, Venable GT, Rossi NB, Foley KT. Surgical outcomes for minimally invasive vs open transforaminal lumbar interbody fusion: an updated systematic review and meta-analysis. *Neurosurgery* 2015;77:847-74.
2. Seng C, Siddiqui MA, Wong KP, et al. Five-year outcomes of minimally invasive versus open transforaminal lumbar interbody fusion: a matched-pair comparison study. *Spine (Phila Pa 1976)* 2013;38:2049-55.
3. Russo AJ, Schopler SA, Stetzner KJ, Shirk T. Minimally invasive transforaminal lumbar interbody fusion with expandable articulating interbody spacers significantly improves radiographic outcomes compared to static interbody spacers. *J Spine Surg* 2021;7:300-9.
4. Boktor JG, Pockett RD, Verghese N. The expandable transforaminal lumbar interbody fusion: two years follow-up. *J Craniovertebr Junction Spine* 2018;9:50-5.
5. Sorensen CJ, Norton BJ, Callaghan JP, Hwang CT, Van Dillen LR. Is lumbar lordosis related to low back pain development during prolonged standing? *Man*

- Ther 2015;20:553-7.
- Morningstar MW. Strength gains through lumbar lordosis restoration. *J Chiropr Med* 2003;2:137-41.
 - Glassman SD, Bridwell K, Dimar JR, Horton W, Ber-ven S, Schwab F. The impact of positive sagittal bal-ance in adult spinal deformity. *Spine (Phila Pa 1976)* 2005;30:2024-9.
 - Crandall DG, Chung AS, Lara N, Revella J. Risk factors for expandable cage subsidence in patients undergoing transforaminal lumbar interbody fusion. *Spine J* 2017;17(10 Suppl):S188-9.
 - Khechen B, Haws BE, Patel DV, et al. Static versus expandable devices provide similar clinical outcomes following minimally invasive transforaminal lumbar interbody fusion. *HSS J* 2020;16:46-53.
 - Hawasli AH, Khalifeh JM, Chatrath A, Yarbrough CK, Ray WZ. Minimally invasive transforaminal lumbar interbody fusion with expandable versus static interbody devices: radiographic assessment of sagittal segmental and pelvic parameters. *Neurosurg Focus* 2017;43:E10.
 - Vaishnav AS, Saville P, McAnany S, et al. Retrospec-tive review of immediate restoration of lordosis in single-level minimally invasive transforaminal lumbar interbody fusion: a comparison of static and expandable interbody cages. *Oper Neurosurg (Hag-erstown)* 2020;18:518-23.
 - Alvi MA, Kurian SJ, Wahood W, Goyal A, Elder BD, Bydon M. Assessing the difference in clinical and radiologic outcomes between expandable cage and nonexpandable cage among patients undergoing minimally invasive transforaminal interbody fusion: a systematic review and meta-analysis. *World Neuro-surg* 2019;127:596-606.
 - Yee TJ, Joseph JR, Terman SW, Park P. Expandable vs static cages in transforaminal lumbar interbody fusion: radiographic comparison of segmental and lumbar sagittal angles. *Neurosurgery* 2017;81:69-74.
 - Pekmezci M, Tang JA, Cheng L, et al. Comparison of expandable and fixed interbody cages in a human ca-daver corpectomy model: fatigue characteristics. *Clin Spine Surg* 2016;29:387-93.
 - Satake K, Kanemura T, Nakashima H, Yamaguchi H, Segi N, Ouchida J. Cage subsidence in lateral inter-body fusion with transpoas approach: intraopera-tive endplate injury or late-onset settling. *Spine Surg Relat Res* 2017;1:203-10.
 - Frisch RF, Luna IY, Brooks DM, Joshua G, O'Brien JR. Clinical and radiographic analysis of expandable versus static lateral lumbar interbody fusion devices with two-year follow-up. *J Spine Surg* 2018;4:62-71.
 - Jordan Y, Buchowski JM, Mokkarala M, Peters C, Bumpass DB. Outcomes and cost-minimization analysis of cement spacers versus expandable cages for posterior-only reconstruction of metastatic spine corpectomies. *Ann Transl Med* 2019;7:212.
 - Parker SL, Mendenhall SK, Shau DN, et al. Minimum clinically important difference in pain, disability, and quality of life after neural decompression and fusion for same-level recurrent lumbar stenosis: un-derstanding clinical versus statistical significance. *J Neurosurg Spine* 2012;16:471-8.
 - Ma C, Wu S, Xiao L, Xue Y. Responsiveness of the Chinese version of the Oswestry Disability Index in patients with chronic low back pain. *Eur Spine J* 2011;20:475-81.
 - Stickley C, Philipp T, Wang E, et al. Expandable cages increase the risk of intraoperative subsidence but do not improve perioperative outcomes in single level transforaminal lumbar interbody fusion. *Spine J* 2021;21:37-44.
 - Chang CC, Chou D, Pennicooke B, et al. Long-term radiographic outcomes of expandable versus static cages in transforaminal lumbar interbody fusion. *J Neurosurg Spine* 2020;34:471-80.
 - Kim CW, Doerr TM, Luna IY, et al. Minimally invasive transforaminal lumbar interbody fusion using expandable technology: a clinical and radio-graphic analysis of 50 patients. *World Neurosurg* 2016;90:228-35.
 - Mulvaney G, Monk S, Clemente JD, Pfortmiller D, Coric D. Expandable interbody spacers: a two-year study evaluating radiologic and clinical outcomes with patient-reported outcomes. *Int J Spine Surg* 2020;14:S31-8.
 - Massie LW, Zakaria HM, Schultz LR, Basheer A, Buraimoh MA, Chang V. Assessment of radiographic and clinical outcomes of an articulating expandable interbody cage in minimally invasive transforaminal lumbar interbody fusion for spondylolisthesis. *Neu-ro-surg Focus* 2018;44:E8.
 - Gelfand Y, Benton J, De la Garza-Ramos R, Yana-madala V, Yassari R, Kinon MD. Effect of cage type on short-term radiographic outcomes in transfo-

- raminal lumbar interbody fusion. *World Neurosurg* 2020;141:e953-8.
26. Humphreys SC, Hodges SD, Patwardhan AG, Eck JC, Murphy RB, Covington LA. Comparison of posterior and transforaminal approaches to lumbar interbody fusion. *Spine (Phila Pa 1976)* 2001;26:567-71.
 27. McMordie JH, Schmidt KP, Gard AP, Gillis CC. Clinical and short-term radiographic outcomes of minimally invasive transforaminal lumbar interbody fusion with expandable lordotic devices. *Neurosurgery* 2020;86:E147-55.
 28. Kaito T, Hosono N, Mukai Y, Makino T, Fujii T, Yonenobu K. Induction of early degeneration of the adjacent segment after posterior lumbar interbody fusion by excessive distraction of lumbar disc space. *J Neurosurg Spine* 2010;12:671-9.
 29. Kepler CK, Rihn JA, Radcliff KE, et al. Restoration of lordosis and disk height after single-level transforaminal lumbar interbody fusion. *Orthop Surg* 2012;4:15-20.
 30. Tan LA, Rivera J, Tan XA, Le VP, Khoo LT, Berven SH. Clinical and radiographic outcomes after minimally invasive transforaminal lumbar interbody fusion-early experience using a biplanar expandable cage for lumbar spondylolisthesis. *Int J Spine Surg* 2020;14:S39-44.