

## Pediatric urothelial carcinoma: A rare case of secondary genitorurinary malignancy in a Wilms Tumor patient



Alexandria M. Hertz<sup>a,\*</sup>, Andrew N. Salomon<sup>b</sup>, Melissa A. Forouhar<sup>c</sup>, Scott P. Cuda<sup>a</sup>

<sup>a</sup> Department of Urology, Madigan Army Medical Center, Tacoma, WA 98431, USA

<sup>b</sup> Department of Medicine, Eisenhower Army Medical Center, Fort Gordon, GA 30905, USA

<sup>c</sup> Department of Pediatrics, Madigan Army Medical Center, Tacoma, WA 98431, USA

### ARTICLE INFO

#### Article history:

Received 28 September 2017

Accepted 12 October 2017

Available online 28 October 2017

### 1. Introduction

Urothelial carcinoma (UCC) is rare during the first four decades of life, with less than 30 cases of UCC described in the literature during the first decade of life.<sup>1</sup> Most of these cases are low grade tumors and with largely indolent courses.<sup>1,2</sup>

Wilms Tumor (WT) is the most common renal malignancy in childhood. Long term survival is excellent due to advances in radiation and chemotherapy regimens. With improved long term survival there has been an increased risk of secondary malignancy. This is thought to result from adjuvant therapies as well as genetic mutations making them vulnerable to multiple malignancies. UCC has been identified in patients following treatment for WT, though there are less than 10 cases noted in the literature. To our knowledge, no cases have been previously reported before age 10 following WT.<sup>3,4</sup> We present a case of a 9-year-old female diagnosed with UCC 3 years following treatment for WT.

### 2. Case presentation

A 9-year-old female was referred to the urology clinic with a history of stage III WT with ultrasound concerning for bladder mass. She previously had undergone a left radical nephrectomy with intra-operative gross tumor spillage. Surgery was followed by treatment with doxorubicin, vincristine, and actinomycin-D (DD-

4A). Following chemotherapy, she was given 10.8 Gy of external beam radiation to the tumor bed. She was followed regularly by her pediatric oncologist with regular surveillance ultrasounds.

She was recurrence free for nearly 3 years when she was seen to have a 1.4 × 0.9 × 0.6cm echogenic, non-vascular lesion near the uretero-vesical junction on surveillance ultrasound (Fig. 1). The patient was otherwise asymptomatic with no lower urinary tract symptoms and an unremarkable urinalysis.

Cystoscopy revealed a 1cm papillary tumor adjacent to the left ureteral orifice (Fig. 2). The tumor was resected at that time. Initial pathologic evaluation reported a papillary urothelial neoplasm with prominent urothelial atypia, however the specimen was sent for expert evaluation at the Joint Pathology Center (JPC). Expert review concluded that the mass was papillary Grade III UCC (Fig. 3) based on a high degree of nuclear pleomorphism, abnormal mitoses, and loss of cell polarity. The tumor had diffusely positive immunohistochemical staining with p53 and Ki67. There was no evidence of invasion on the specimen, though without muscle seen in the sections. Given this, repeat transurethral resection of the tumor bed was performed. Ensuing pathologic examination did not identify additional tumor.

The patient has been followed with surveillance cystoscopy per National Comprehensive Cancer Network (NCCN) guidelines for high grade UCC since her resection without recurrence 42 months after her initial diagnosis.

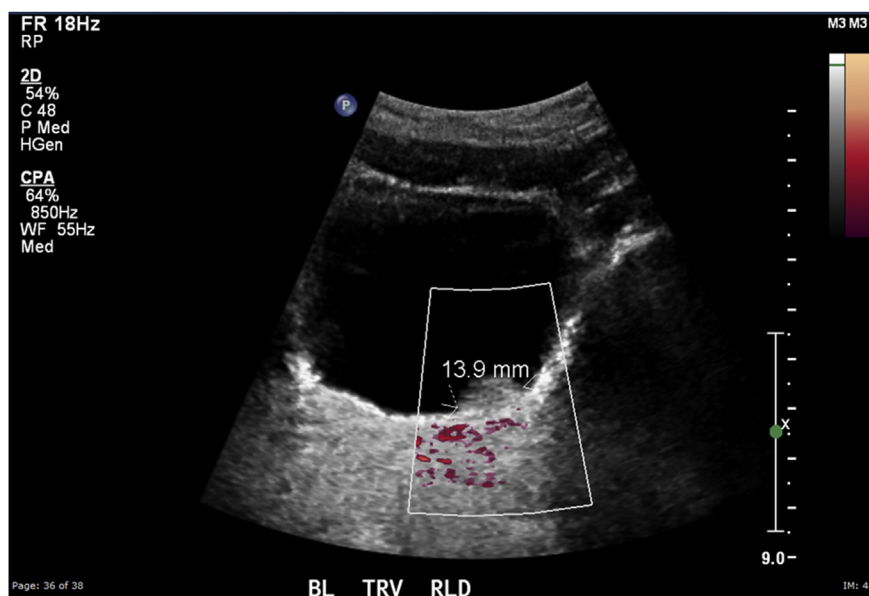
### 3. Discussion

Urothelial carcinoma is a rare diagnosis for children in the first decade of their life.<sup>1</sup> Urogenital tumors are a known secondary malignancy after WT, with a small number of urothelial carcinomas. It is uncommon for WT to have a secondary malignancy within 5 years of WT diagnosis.<sup>3</sup> This case represents an uncommon occurrence of UCC in a child under age 10 following treatment of WT; the first case of this type to the knowledge of the authors.

The majority of other UCC tumors diagnosed during the first four decades of life reported in the literature have been low grade. This represents a rare high-grade tumor, although it has behaved similarly to the low-grade tumors and at the time of this writing

\* Corresponding author.

E-mail addresses: [alexandria.m.hertz@mail.mil](mailto:alexandria.m.hertz@mail.mil) (A.M. Hertz), [andrew.n.salomon@mail.mil](mailto:andrew.n.salomon@mail.mil) (A.N. Salomon), [melissa.a.forouhar@mail.mil](mailto:melissa.a.forouhar@mail.mil) (M.A. Forouhar), [scott.p.cuda@mail.mil](mailto:scott.p.cuda@mail.mil) (S.P. Cuda).



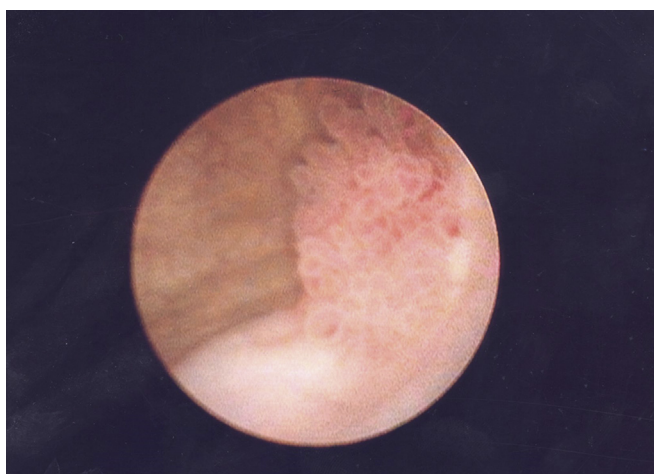
**Fig. 1.** Ultrasound image of lesion within urinary bladder.

has not recurred.<sup>1,2</sup> UCC often has a delay in diagnosis in this patient population with the most common symptom being hematuria. This delay is due primarily to the low incidence of malignancy in this population as well as the need for invasive cystoscopy requiring anesthesia. Comparatively, this patient had recognition of the malignancy before the onset of symptoms and had prompt intervention. The discovery of the tumor via ultrasound is consistent with previous reports of ultrasound being a sensitive exam without additional radiation risk for these patients.<sup>2</sup>

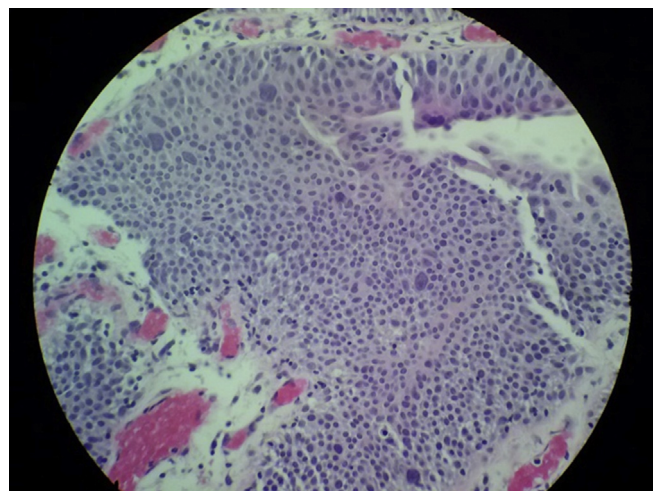
There is no recommended surveillance plan in children given the low incidence of UCC. Studies previously have advocated for largely non-invasive ways to surveil these patients. Several studies have provided surveillance with ultrasound alone, while others also included urine cytology for further evaluation. Use of urine cytology has been limited in previous cohorts, due to the majority of tumors being low grade and the established low sensitivity of urine cytology for low grade tumors.<sup>1</sup> In this report, we describe a combined regimen similar to adults diagnosed with high grade

UCC. Surveillance was performed via cystoscopy and upper tract imaging with ultrasound. We did not obtain surveillance urine cytology in this patient because atypical cells are a frequent result. Atypical cells would then translate clinically to more frequent unnecessary procedures under general anesthesia. Cystoscopy has been reliable in this patient, and frequency was kept according to normal NCCN recommendations. High grade lesions are exceedingly rare in this population and as such there is not data to compare their behavior in terms of recurrence or progression. As of this time, it appears that this high-grade lesion is behaving similarly to low grade tumors in this young patient population.<sup>1,2</sup> Of note, she has also not had signs of recurrence of her WT or other secondary malignancies.

Her current surveillance plan includes annual cystoscopy for her bladder and upper tract imaging following standard frequency recommendations for UCC. Frequency of cystoscopy will continue to decrease if no evidence of recurrence.



**Fig. 2.** Tumor near left ureteral orifice during cystoscopy.



**Fig. 3.** Low power view of pathologic slide of tumor with high grade dysplasia.

#### 4. Conclusion

UCC of the bladder is an infrequent occurrence in the pediatric population, and is a rarely described secondary malignancy following WT. In our report, we describe a case of UCC of the bladder in a child under age 10 less than 5 years from treatment of WT. We also propose a potential surveillance program with cystoscopy every six months with gradual decrease in frequency based on recurrence, with upper tract imaging with ultrasound every 6–12 months due to history of WT, though this could be decreased in the setting of UCC alone. At the time of this writing, the patient remains without recurrence despite a previous high grade lesion, supporting a more indolent nature in children.

#### Conflicts of interest

The authors have no financial or other conflicts of interest to disclose.

#### Funding source

This research did not receive any specific grant from funding

agencies in the public, commercial, or not-for-profit sectors.

#### Appendix A. Supplementary data

Supplementary data related to this article can be found at <https://doi.org/10.1016/j.eucr.2017.10.011>.

#### References

1. Paner GP, Zehnder P, Amin AM, Husain AN, Desai MM. Urothelial neoplasms of the urinary bladder occurring in young adult and pediatric patients. *Adv Anatomic Pathol.* 2011;18(1):79–89. <https://doi.org/10.1097/pap.0b013e318204c0cf>.
2. Lerena J, Krauel L, García-Aparicio L, Vallasciani S, Suñol M, Rodó J. Transitional cell carcinoma of the bladder in children and adolescents: six-case series and review of the literature. *J Pediatr Urol.* 2010;6(5):481–485. <https://doi.org/10.1016/j.jpurol.2009.11.006>.
3. Breslow NE, Lange JM, Friedman DL, et al. Secondary malignant neoplasms after Wilms tumor: an international collaborative study. *Int J Cancer.* 2010;127(3):657–666. <https://doi.org/10.1002/ijc.25067>.
4. Lee JS, Padilla B, Dubois SG, Oates A, Boscardin J, Goldsby RE. Second malignant neoplasms among children, adolescents and young adults with Wilms tumor. *Pediatr Blood Cancer.* 2015;62(7):1259–1264. <https://doi.org/10.1002/pbc.25484>.