

Evaluation of the efficacy of platelet-rich plasma and platelet-rich fibrin in alveolar defects after removal of impacted bilateral mandibular third molars

Amol M. Doiphode, Prashanth Hegde¹, Uma Mahindra², S. M. Santhosh Kumar¹, Pavan D. Tenglikar³, Vivek Tripathi⁴

Department of Oral and Maxillofacial Surgery, MIDSR Dental College and Hospital, Latur, ²Departments of Oral and Maxillofacial Surgery, Pravara Institute of Medical Sciences, Ahmednagar, Maharashtra, ¹Departments of Oral and Maxillofacial Surgery, AME's Dental College and Hospital, Raichur, Karnataka, ³HKDET's Dental College, Humnabad, Karnataka, ⁴Department of Periodontology, Azamgarh Dental College, Azamgarh, Uttar Pradesh, India

Corresponding author (email: <pth61166@gmail.com>)

Dr. Prashanth Hegde, Professor, Department of Oral and Maxillofacial Surgery, AME's Dental College and Hospital, Raichur, Karnataka, India.

Received: 31-12-15

Accepted: 12-01-16

Published: 26-04-16

Abstract

Aim and Objectives: This study attempted the evaluation of the efficacy of platelet-rich plasma (PRP) and platelet-rich fibrin (PRF) in alveolar defects after removal of bilateral mandibular third molars. **Materials and Methods:** A total of 30 patients reporting to Department of Oral and Maxillofacial Surgery and having bilateral mandibular third molar impaction in both male and female aged between 18 and 30 years were included in this study. PRF and PRP were placed in extraction site and recalled at 2nd, 4th, and 6th month postoperatively. Data were statistically analyzed using IBM SPSS software for Windows, version 19.0. IBM Corp., Armonk, NY, USA. **Results:** This study showed decreased probing depth in PRF group compared to PRP and control one. This signifies a better soft tissue healing of extraction sockets with PRF as compared to the PRP and the control group and increase in the bone density highlights the use of PRP and PRF certainly as a valid method in inducing hard tissue regeneration. **Conclusion:** This study indicates a definite improvement in the periodontal health distal to second molar after third molar surgery in cases treated with PRF as compared to the PRP group and control group. Hence, PRP and PRF can be incorporated as an adjunct to promote wound healing and osseous regeneration in mandibular third molar extraction sites.

Key words: Alveolar defect, plasma, platelet, platelet rich fibrin, platelet rich plasma, third molar impaction, wound healing

INTRODUCTION

Healing is the process of cure and restoring of integrity of injured tissues. During wound healing, cells communicate with each other through the use of specific molecules that are usually proteins. Proteins that are

used for cellular communications are called “cytokines.” Growth factors are a subclass of cytokines that specifically stimulates the proliferation of cells.^[1] A platelet present in blood of mammals is important for its role in blood coagulation. Platelets activated by the coagulation

This is an open access article distributed under the terms of the Creative Commons Attribution-NonCommercial-ShareAlike 3.0 License, which allows others to remix, tweak, and build upon the work non-commercially, as long as the author is credited and the new creations are licensed under the identical terms.

For reprints contact: reprints@medknow.com

How to cite this article: Doiphode AM, Hegde P, Mahindra U, Santhosh Kumar SM, Tenglikar PD, Tripathi V. Evaluation of the efficacy of platelet-rich plasma and platelet-rich fibrin in alveolar defects after removal of impacted bilateral mandibular third molars. J Int Soc Prevent Communit Dent 2016;6:S47-52.

Access this article online	
Quick Response Code:	Website: www.jispcd.org
	DOI: 10.4103/2231-0762.181167

cascade particularly thrombin and sub endothelial collagen; release a number of growth factors from their alpha granules into the wound site. These factors can activate the proliferation and differentiation of the local osteoprogenitor cells into bone forming cells leading to the formation of new bone matrix and mineralization.^[2]

Platelet-rich plasma (PRP) is an autologous concentrate of platelets suspended in plasma. It is a proven source of growth factors such as platelet-derived growth factors (PDGFs) and transforming growth factor-beta 1 and 2; vascular endothelial growth factors positively influence repair and regeneration of tissues.^[3] By combining with calcium chloride and thrombin, PRP releases these growth factors. PRP gel also contains a native concentration of fibrinogen. As a result of its fibrin content, PRP gel permits stabilized coagulation of blood thereby favoring regeneration of the osseous defects particularly in the early stage.^[4]

Soft tissue healing is also substantially improved through the application of PRP, by increasing collagen content and regulating key cellular processes, such as mitosis, cell differentiation, and metabolism.^[5] Preparation of PRP includes two stages of preparation and biochemical handling of blood. Whereas, platelet rich fibrin (PRF) - is a second generation platelet concentrate having several advantages over PRP; such as, ease of preparation and lack of biochemical handling of blood, which makes this preparation strictly autologous.^[6]

PRF is a leukocyte and PRF biomaterial with a specific composition and three-dimensional architecture. PRF has a dense fibrin network with leukocytes, cytokines, structural glycoproteins and also growth factors. Leukocytes that are concentrated in PRF scaffold play an important role in growth factor release, immune regulation, anti-infectious activities, and matrix remodeling during wound healing. The slow polymerization mode of PRF and cicatricial capacity creates a physiologic architecture favorable for wound healing.^[7] Kulkarni *et al.* (2014) stated that PRF is an excellent material for enhancing wound healing. The use of PRF dressings may be a simple and effective method of reducing the morbidity associated with donor sites of autogenous free gingival grafts.^[8] Yelamali and Saikrishna found better and faster wound healing and bone formation with PRF, and also he stated preparation of PRF is simpler than PRP.^[9]

MATERIALS AND METHODS

This study was undertaken at the Department of Oral and Maxillofacial Surgery, after obtaining ethical

clearance. Thirty patients having bilateral mandibular third molar impaction (fully/partially erupted with all type of angulations) in both male and female aged between 18 and 30 years were included in the present study with an informed consent and were divided into two groups. Each group consists of 15 patients.

1. Group I - Control group
2. Group II - This group was further divided into two subgroups Group IIa and Group IIb (split moth method was used on one side of each patient as a control group and another side as intervention group)
3. Group IIa - Was the one in which left extraction socket was filled with PRP gel
4. Group IIb - In which right extraction socket was filled with PRF.

Preoperative evaluation with intraoral periapical radiograph [Figure 1] and complete blood investigation was done for all patients.

Preparation of platelet rich plasma

Patient venous blood was collected and subjected for centrifugation then 2 ml of conventional PRP (cPRP) was treated with 60 µl of citrate inhibitor sterile 10% calcium chloride solution and allowed to coagulate. Then, squeezed to release the platelet-derived thrombin and collected in serum rich plasma. Then, autologous thrombin rich plasma was mixed with cPRP in the 1:4 ratios and allowed to coagulate. This forms PRP gel within 5–10 min [Figures 2-4].

Preparation of platelet-rich fibrin

Armamentarium required for PRF is same as that of PRP except citrate phosphate dextrose

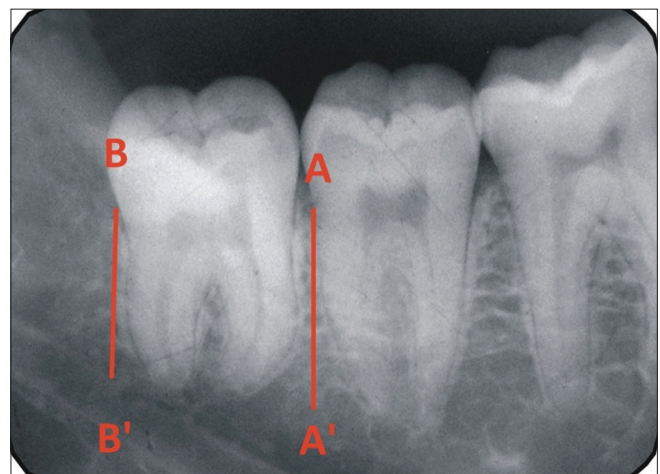


Figure 1: Intraoral periapical radiographs radiographic image showing method to evaluate bone density

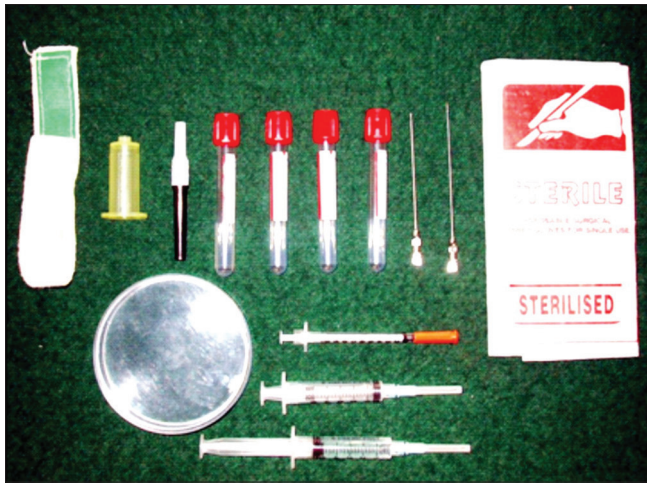

Figure 2: Armamentarium for platelet rich plasma and platelet rich fibrin preparation

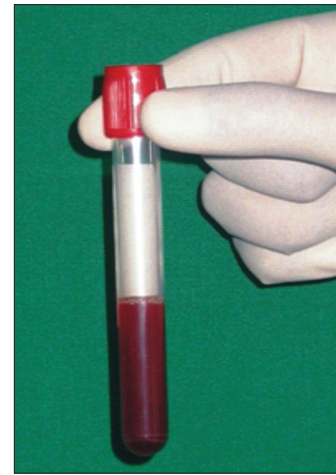


Figure 3: Concentrated platelet rich plasma

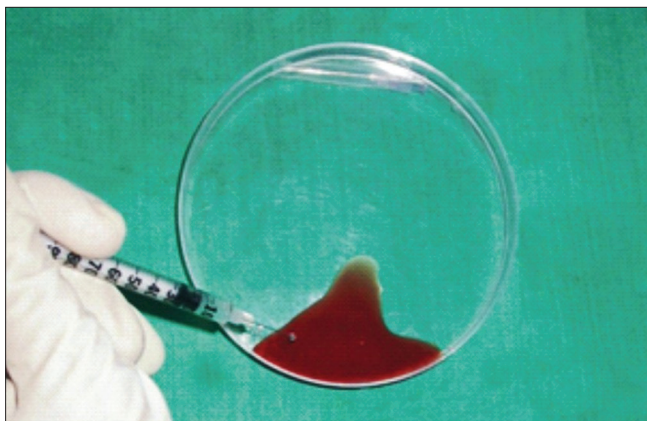


Figure 4: Platelet-rich plasma gel after addition of CaCl_2 and autologous thrombin

adenine (CPDA) anticoagulant solution and 10% CaCl_2 . Around 5 ml of whole venous blood was collected in each of two sterile vacutainer tube of 6 ml capacity without anticoagulant. The vacutainers were placed in the centrifuge at 3000 rpm for 10 min after which we obtained red lower fraction containing red blood cells, upper straw colored cellular plasma, and the fibrin clot was obtained in the middle. The straw colored upper layer was removed, and middle layer with fraction 2 mm below dividing line was collected which will be the PRF.

In Group I, the extraction socket was closed primarily without PRP and PRF in the socket. In Group IIa, PRP in the mandibular left extraction socket and in Group IIb mandibular right extraction socket 2–3 ml of PRF was placed.

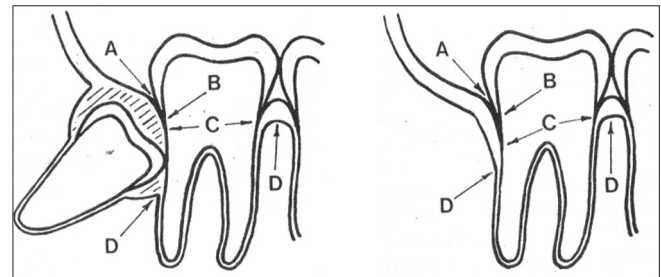


Figure 5: Radiographic schematic image showing method to evaluate bone density. A = Free gingival margin, B = Cementoenamel junction, C = Depth of the pocket, D = Alveolar crest

Measurement of various parameters

Measurement of wound dehiscence

The extraction socket evaluated on 1st, 2nd, and 7th postoperative day for any wound dehiscence and recorded as present/absent.

Probing depth

Probing depth (PD) measured using Michigan O Probe with William's markings from "free gingival margin (FGM)" to the bottom of the pocket in nearest mm. The average of PD was recorded at the three different positions, i.e. Distobuccal (DB), Distal (D), Distolingual (DL) on the distal surface of second molar taken preoperatively, 1st, 2nd, 4th, and 6th month postoperatively.

Alveolar bone height

Alveolar bone height (ABH) measured distal to second molar was measured with a caliper from cemento enamel junction (CEJ) to the alveolar crest on intraoral periapical radiographs (IOPA) at 1st, 2nd, 4th, and 6th month postoperatively.

Bone density

Bone density was measured on direct IOPA using Densitometric analysis device [Figures 1 and 5] pre- and post-operatively at 1st, 2nd, 4th, and 6th month.

The bone density calculated using below formula:^[10]

$$\text{Preoperative density} = \frac{\text{Average density from A to A'} + \text{Average density from B to B'}}{2}$$

Where, Point A = Point at alveolar crest just mesial to third molar.

Point A' = Point just mesial to third molar at the level of apical third.

Point B and B' = Points in similar fashion but distal to mandibular third molar.

$$\text{Postoperative density} = \frac{\text{Average density from C to C'} + \text{Average density from D to D'}}{2}$$

Where, Point C = Mesial Point in the third molar socket at the alveolar crest level.

Point C' - Mesial Point in the third molar socket at the level of apical third.

Mean gray level histogram values of the digitalized IOPA images of third molar extraction socket of both control and study groups were calculated at preoperative, 2nd, 4th, and at 6th month postoperative period in Adobe Photoshop (7.0) software (Adobe Systems for Windows and OS X). The digitalization of the IOPA radiographs was carried out using scanner (Lexmark International Corporation manufacturer for laser scanner and printers) and similarly densitometric analysis was done using densitometer (The Little Genius Densitometer #07-444, Cardinal Health) with standard protocol.

Point D and D' - points is in similar fashion but in the distal aspect of the third molar extraction site as shown in Figure 1. Collected data were statistically analyzed using IBM SPSS software for Windows, version 19.0. IBM Corp., Armonk, NY, USA. All results were calculated using the mean value and standard deviation for each of the parameters considered and checked for statistical significance using Student unpaired *t*-test. The differences in the results of PD, ABH, and bone density at 2, 4, and 6 months were compared between each group using Student unpaired *t*-test.

RESULTS

The results were evaluated based on clinical observation, radiographic analysis, and densitometric analysis of the recorded data. Table 1, shows dehiscence in 5 (33.3%) out of 15 cases, Group IIa showed dehiscence in 3 (20%) cases, whereas Group IIb did not show any sign of wound dehiscence. The decrease in PD, corresponding to the distal surface of the mandibular second molar is seen in all the three groups [Table 1]. We observed that the difference in the decrease in ABH at 2, 4, and 6 months postoperatively in the Group IIb was statistically significant [Table 2].

In Group IIa and Group IIb, there was a highly significant difference in bone density of the bone adjacent to the extraction socket and the bone formed in the extraction socket at 2nd, 4th, and 6th months postoperatively when compared with Group I. But Group IIa and Group IIb showed no significant difference in bone density of the bone adjacent to

Table 1: Mean and SD values of Probing Depth (PD) (FGM to bottom of the pocket, in mm) in group I, II (a) and II (b)

	Mean±SD (n=15)		
	Group I	Group II (a) (PRP)	Group II (b) (PRF)
Preoperative	4.35±0.39	4.20±0.52	2.68±0.55
2 months post operative	3.93±0.28	3.44±0.51	2.68±0.44
4 months post operative	3.20±0.33	2.80±0.28	1.93±0.23
6 months post operative	2.99±0.34	1.77±0.21	1.29±0.33

Student's unpaired 't' test highly significant (P<0.01). Tables indicates decrease in probing/pocket depth in all groups-I, II, and III at 2, 4 and 6 months post operatively. Lowest pocket depth was seen with PRF (Group-II (b))

Table 2: Mean and SD values of alveolar bone height (ABH) distal to 2nd molar (CEJ to Alveolar crest, in mm) in group I, II (a) and II (b)

	Mean±SD (n=15)		
	Group I	Group II (a) (PRP)	Group II (b) (PRF)
Preoperative	3.10±2.09	3.50±1.94	3.64±1.89
2 months post operative	3.10±2.09	3.27±1.74	3.37±1.72
4 months post operative	2.97±2.11	2.40±0.85	1.80±0.84
6 months post operative	2.77±2.24	2.1±1.49	1.57±0.62

Student's unpaired 't' test highly significant (P<0.05). Table indicates increase in alveolar bone height distal to 2nd molar in all groups at 2,4 and 6th months. In group-II (b) it was statistically significant

Table 3: Mean and SD values of bone density on IOPA (in Pixels) in group I, II (a) and II (b):

	Mean±SD (n=15)		
	Group I	Group II (a) (PRP)	Group II (b) (PRF)
Preoperative	144.33±13.76	148.87±11.09	149.47±10.90
2 months post operative	75.87±8.38	117.87±8.09	120.60±8.42
4 months post operative	99.94±14.91	128.14±9.26	133.74±9.30
6 months post operative	127.80±11.87	140.13±10.90	141.4±11.41

Note: student's unpaired 't' test highly significant ($P < 0.05$). Bone density was good in Group-II (b) compared to others at 6 months intervals

the extraction socket and the bone formed in the extraction socket at 2nd and 4th months and at 6th month postoperatively [Table 3].

DISCUSSION

Growth factors are a realistic way to improve and expedite both soft tissue and bony wound healing. Platelets contain angiogenic, mitogenic, and vascular growth factors in their granules. All these growth factors increase the population of wound healing cells and recruits other angiogenic growth factors to the wound site.^[11] It is, therefore, a reasonable hypothesis that increasing the concentration of platelets in bone defects may lead to improved, faster healing.

Extraction of impacted mandibular third molars causes multiple periodontal defects at the distal root of the second molar. The optimal management of impacted mandibular third molar continues to challenge clinicians. There are various augmentation procedures performed at the time of tooth extraction to maintain or enhance ridge form for prosthetic reconstruction, periodontal health or implant placement. One of the most recent and innovative technique which has come up is the use of PRP. The use of PRP has shown to be a valid technique for promoting bone regeneration at the distal surface of the mandibular second molar following extraction of impacted third molars.^[12,13] Kazemi and Fakhrou has referred that PRP could have a positive influence also on cartilage repair.^[14] Kim *et al.* concluded that addition of PRP, PRF and concentrated growth factor had significantly increased bone formation at the 6th week.^[15]

The PRP is activated to form PRP gel thus causing degranulation of α -granules present in the platelets and releasing the growth factors.^[16] Landesberg *et al.* have reported the possibility of hypersensitivity to

bovine thrombin which may cause antigenic reactions in many individuals.^[17] In our technique, autologous thrombin was prepared and was mixed with PRP to form an autologous platelet gel.^[18] This platelet gel was free of eliciting any antigen-antibody reaction as it was prepared from patients own blood. The anticoagulant used in our study was CPDA since it has been observed that ethylenediaminetetraacetic acid is potentially more harmful than CPDA.^[19]

In our study, the decrease in PD in Group I was 3.00 ± 0.3336 at 6 months and the ABH distal to second molar was 2.77 ± 2.430 at the end of 6 months [Table 1]. These results did not show a significant periodontal breakdown in terms of PD and ABH distal to second molar. In the present study, a significant decrease in the PD was observed in all the three groups at 2nd, 4th, and 6th months postoperatively, but the greatest decrease was present in Group IIb [Table 2] where the extraction sockets were treated with PRF. Sammartino *et al.* observed a notable reduction in PD and improvement in the probing attachment level distal to second molars at 12 and 18 weeks in those extraction cases treated with PRP compared with controls where PRP was not used.^[12]

Measurement of the ABH was performed periodically at 2nd, 4th and 6th month postoperatively, and it revealed no significant difference between mean values of ABH distal to second molar (CEJ to alveolar crest, in mm) at preoperative and 2nd months, but it is significant at 4th months and 6th months when compared with Group I and Group IIa, with Group I and Group IIb and with Group IIa and Group IIb which concludes that Group IIa and Group IIb significant ABH at 4th and 6th months when compared to Group I. Overall Group IIb shows significant ABH at 4th and 6th months when compared to group I and Group IIa [Table 2]. Similar results were shown in a study conducted by He *et al.*^[20]

Mean values of bone density on IOPA (in pixels) was highly significant at 2 months, 4 months and 6 months when compared with Group I and Group IIa and with Group I and Group IIb. However, there was no significant difference between mean values of bone density on IOPA (in pixels) at preoperative, 2 months, 4 months, and 6 months when compared with Group IIa and Group IIb. Similarly, it was highly significant at and 2 months, 4 months, and 6 months when compared with Group I and Group IIa and with Group I and Group IIb. However, there was no significant difference between mean values of bone

density on IOPA (with densitometer) at preoperative, 2 months, 4 months, and 6 months when compared with Group IIa and Group IIb. It shows new bone formation by PRP and PRF and encouraging results when compared to control group [Table 3]. Yelamali and Saikrishna found better bony density with PRF compared PRP after 4 months follow up.^[9] Similary Martínez *et al.* stated that various PDGFs (PPP, PRR and PRF) helps in promotion of wound healing and angiogenesis both *in vitro* and *in vivo*.^[21]

The limitation of this study was that the 6 months postoperative follow-up is a short duration to comment on the significance of periodontal breakdown distal to second molar. However, this duration of time was adequate enough to evaluate the effects of PRP and PRF in initiating and enhancing both hard and soft tissue healing. In future extra time, extra resources, and long term studies need for good results.

CONCLUSION

This study indicates a definite improvement in the periodontal health distal to second molar after third molar surgery in cases treated with PRF as compared to the PRP group and control group. The procedure of PRF preparation is simple, quick, and cost effective as compared to PRP, but PRP and PRF have demonstrated good results and both can be incorporated as an adjunct to promote wound healing and osseous regeneration in human mandibular third molar extraction sites.

Financial support and sponsorship

Nil.

Conflicts of interest

There are no conflicts of interest.

REFERENCES

- Greenhalg DG. The role of growth in wound healing. *The Journal of Trauma: Injury, Infection and Critical Care*. 1996;41:159-167.
- Tsay RC, Vo J, Burke A, Eisig SB, Lu HH, Landesberg R. Differential growth factor retention by platelet-rich plasma composites. *J Oral Maxillofac Surg* 2005;63:521-8.
- Fortier LA, Barker JU, Strauss EJ, McCarrel TM, Cole BJ. The role of growth factors in cartilage repair. *Clin Orthop Relat Res* 2011;469:2706-15.
- Intini G. The use of platelet-rich plasma in bone reconstruction therapy. *Biomaterials* 2009;30:4956-66.
- Gerard D, Carlson ER, Gotcher JE, Jacobs M. Effects of platelet-rich plasma on the healing of autologous bone grafted mandibular defects in dogs. *J Oral Maxillofac Surg* 2006;64:443-51.
- Dohan DM, Choukroun J, Diss A, Dohan SL, Dohan AJ, Mouhyi J, *et al.* Platelet-rich fibrin (PRF): A second-generation platelet concentrate. Part I: Technological concepts and evolution. *Oral Surg Oral Med Oral Pathol Oral Radiol Endod* 2006;101:e37-44.
- Preeja C, Arun S. Platelet-rich fibrin: Its role in periodontal regeneration. *Saudi J Dent Res* 2014;5:117-22.
- Kulkarni MR, Thomas BS, Varghese JM, Bhat GS. Platelet-rich fibrin as an adjunct to palatal wound healing after harvesting a free gingival graft: A case series. *J Indian Soc Periodontol* 2014;18:399-402.
- Yelamali T, Saikrishna D. Role of platelet rich fibrin and platelet rich plasma in wound healing of extracted third molar sockets: A comparative study. *J Maxillofac Oral Surg* 2015;14:410-6.
- Damante JH, Da S Guerra EN, Ferreira O Jr. Spontaneous resolution of simple bone cysts. *Dentomaxillofac Radiol* 2002;31:182-6.
- Aghaloo TL, Moy PK, Freymiller EG. Investigation of platelet-rich plasma in rabbit cranial defects: A pilot study. *J Oral Maxillofac Surg* 2002;60:1176-81.
- Sammartino G, Tia M, Marenzi G, di Lauro AE, D'Agostino E, Claudio PP. Use of autologous platelet-rich plasma (PRP) in periodontal defect treatment after extraction of impacted mandibular third molars. *J Oral Maxillofac Surg* 2005;63:766-70.
- Simon D, Manuel S, Geetha V, Naik BR. Potential for osseous regeneration of platelet-rich plasma – A comparative study in mandibular third molar sockets. *Indian J Dent Res* 2004;15:133-6.
- Kazemi D, Fakhrjou A. Leukocyte and platelet rich plasma (L-PRP) versus leukocyte and platelet rich fibrin (L-PRF) for articular cartilage repair of the knee: A comparative evaluation in an animal model. *Iran Red Crescent Med J* 2015;17:e19594.
- Kim TH, Kim SH, Sándor GK, Kim YD. Comparison of platelet-rich plasma (PRP), platelet-rich fibrin (PRF), and concentrated growth factor (CGF) in rabbit-skull defect healing. *Arch Oral Biol* 2014;59:550-8.
- Gonshor A. Technique for producing platelet-rich plasma and platelet concentrate: Background and process. *Int J Periodontics Restorative Dent* 2002;22:547-57.
- Landesberg R, Moses M, Karpatkin M. Risks of using platelet rich plasma gel. *J Oral Maxillofac Surg* 1998;56:1116-7.
- How to Make Autologous Platelet Gel? Available from: http://www.Londonperfusionscience.com/services_platelet_gel_make.html. [Last accessed on 2015 Dec 30].
- Landesberg R, Roy M, Glickman RS. Quantification of growth factor levels using a simplified method of platelet-rich plasma gel preparation. *J Oral Maxillofac Surg* 2000;58:297-300.
- He L, Lin Y, Hu X, Zhang Y, Wu H. A comparative study of platelet-rich fibrin (PRF) and platelet-rich plasma (PRP) on the effect of proliferation and differentiation of rat osteoblasts *in vitro*. *Oral Surg Oral Med Oral Pathol Oral Radiol Endod* 2009;108:707-13.
- Martínez CE, Smith PC, Palma Alvarado VA. The influence of platelet-derived products on angiogenesis and tissue repair: A concise update. *Front Physiol* 2015;6:290.