



# Management of vesicoureteral reflux in neurogenic bladder

Charlotte Q. Wu, Israel Franco

Department of Urology, Section of Pediatric Urology, Yale School of Medicine, New Haven, CT, USA

Vesicoureteral reflux (VUR) is a significant risk factor for pyelonephritis and renal scarring. VUR can occur through a defective ureterovesical junction (UVJ) or an overwhelmed normal UVJ mechanism such as in bladder dysfunction of congenital, acquired, or behavioral etiology. There are numerous causes for the development of a neurogenic bladder from spinal dysraphisms to spinal cord trauma and even centrally based abnormalities in children with apparently normal motor function (inappropriately termed nonneurogenic neurogenic bladder). The foundation of managing reflux in these neurogenic bladders is to maintain low bladder pressures which will commonly mean that compliance will be normal as well. There have been several publications that have shown that if bladder pressures are lowered simply with clean intermittent catheterization and medications that the reflux can resolve spontaneously. Alternatively, the patients that are in need of bladder augmentation can have spontaneous resolution of their reflux with the resulting increase in capacity. Surgical intervention is called for when bladder capacity is adequate and the reflux persists or if it is part of a larger operation to increase capacity and to manage outlet resistance. In some instances, reimplantation is necessary because the ureters interfere with the bladder neck procedure. Aside from open and robotic surgical intervention the use of endoscopic injectable agents is beginning to become more popular especially when combined with intravesical botulinum toxin A injections. Great strides are being made in the management of patients with neurogenic bladders and we are seeing more choices for the urologist to be able to manage these patients.

**Keywords:** Cohen cross trigonal reimplant; Neurogenic urinary bladder; Type A botulinum toxins; Vesicoureteral reflux

This is an Open Access article distributed under the terms of the Creative Commons Attribution Non-Commercial License (<http://creativecommons.org/licenses/by-nc/4.0>) which permits unrestricted non-commercial use, distribution, and reproduction in any medium, provided the original work is properly cited.

## INTRODUCTION

Vesicoureteral reflux (VUR) is a significant risk factor for pyelonephritis and renal scarring. VUR can occur through a defective ureterovesical junction (UVJ) or an overwhelmed normal UVJ mechanism such as in bladder dysfunction of congenital, acquired, or behavioral etiology. The former is termed primary reflux, the latter secondary. Many etiologic factors may coexist in any given patient;

as such, the classifications are not considered mutually exclusive. In all cases, the treatment goal is to eliminate urinary tract infections (UTIs) and preserve renal function.

Common causes of neurogenic bladder dysfunction in children are neurospinal dysraphisms such as spina bifida, sacral agenesis, tethered cord, and spinal cord injury [1]. Up to a third of children with neurogenic bladder have VUR [2,3]. Those affected may have detrusor external sphincter dyssynergia and/or poor bladder compliance, leading to

**Received:** 15 December, 2016 • **Accepted:** 6 March, 2017

**Corresponding Author:** Israel Franco

Department of Urology, Section of Pediatric Urology, Yale University, 789 Howard Ave, New Haven, CT 06520, USA  
TEL: +1-203-785-5339, FAX: +1-203-785-4043, E-mail: Israel.Franco@yale.edu

high bladder storage and voiding pressures. A commonly accepted view is that VUR in neurogenic bladder represents a secondary type of reflux whereby the primary cause is elevated bladder pressures rather than a defective UVJ [1,4,5]. Other theories regarding etiology in this population point to chronic infections, which may weaken the valve mechanism, and anatomic disruptions such as bladder trabeculations and diverticula occurring near the ureteral orifice [2,6]. The latter is postulated to prevent the passive compression of the submucosal ureteral tunnel, which plays a major role in reflux prevention [7]. Dysfunctional voiding can also perpetuate reflux, making secondary VUR of all grades less likely to resolve with age compared to primary VUR [8,9].

In the neurogenic bladder the initial management typically involves clean intermittent catheterization (CIC) with or without prophylactic antibiotic therapy in combination with an anticholinergic agent [10]. In children with VUR refractory to conservative measures, management includes surgery with ureteral reimplantation, bladder augmentation, or a combination of treatment modalities. The decision regarding choice in surgery is determined predominantly by the degree of trabeculation, urethral pressure, and bladder dynamics [6]. It is well known, for example, that ureteral reimplantation alone into a noncompliant high-pressure bladder is associated with a high VUR recurrence rate [11]. In select cases, however, ureteral reimplantation may alone

suffice. Alternatively, some clinicians have advocated for bladder augmentation without ureteral reimplantation, arguing that improvement in bladder compliance should allow VUR to resolve [6,12]. Realistically, a variety of surgical and endoscopic options can be pursued, and management decisions should ultimately be tailored to the individual patient. Fig. 1 summarizes the management algorithm.

## INITIAL MANAGEMENT

Timing of CIC initiation is clinician-dependent and may start in the newborn period if evidence of detrusor sphincter dyssynergia or significantly elevated leak point pressures are found given the high potential for upper tract deterioration in these scenarios [1,5]. Many clinicians favor early CIC to expectant management when both are options. With CIC, bladder pressures can be sustained in an acceptable range, while high pressure dyssynergic voiding may be avoided, and there is arguably a greater likelihood that the child's bladder will grow normally with improved long-term dynamics [1,13]. In fact, CIC and medical therapy alone is associated with up to a 30%–50% resolution of VUR within 2–3 years [1,14]. Favorable outcomes have been seen more often in children who start CIC earlier. Abnormal bladder remodeling due to persistently elevated bladder pressures is difficult if not impossible to reverse without

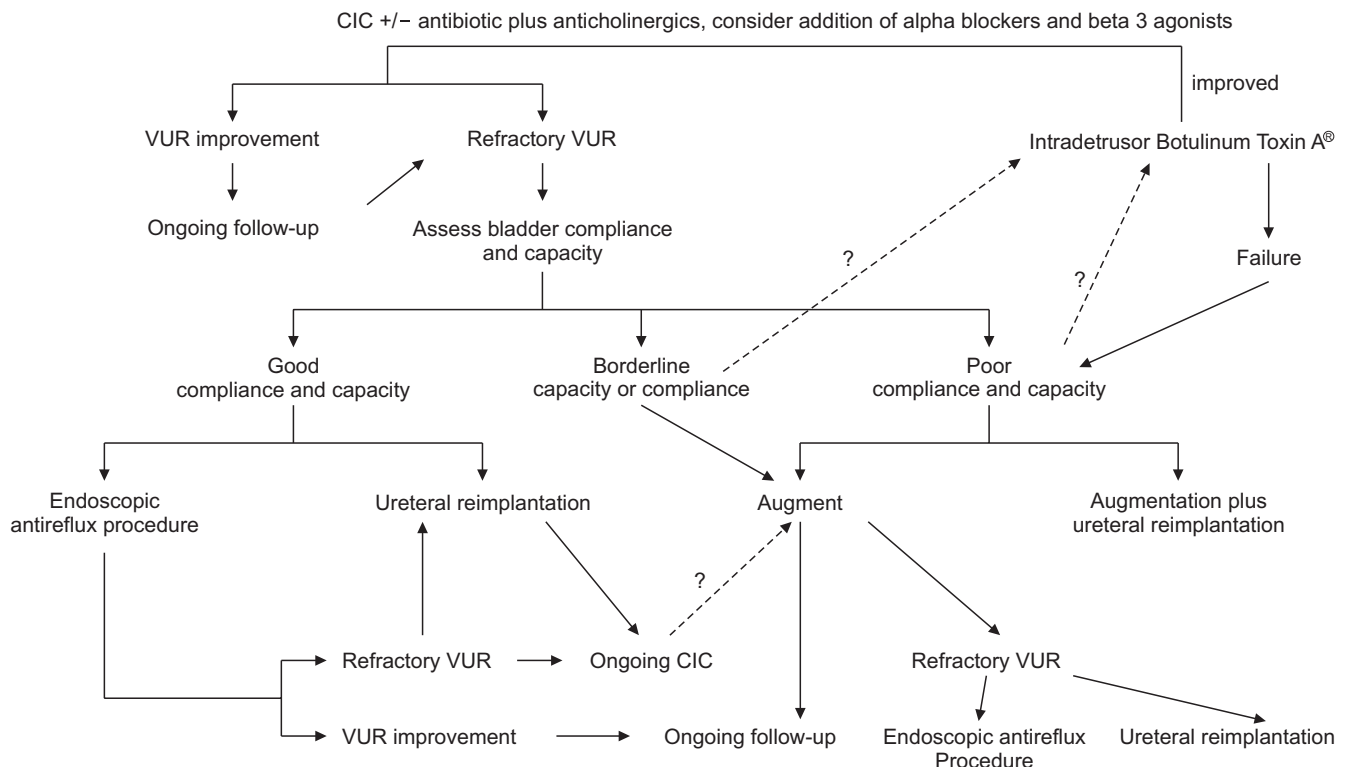


Fig. 1. Algorithm for management of vesicoureteral reflux (VUR) in neurogenic bladder. CIC, clean intermittent catheterization.

aggressive measures later on [1]. The child and parent also become more adaptable to the routine when started at a young age.

The main downside to CIC is increased rates of bacteriuria, though there appears to be fewer symptomatic UTIs when CIC is implemented correctly [15,16]. CIC also relies heavily on the availability of an able and willing family member to perform the technique. A large portion of patients who worsen on CIC are those who did not adhere to regular catheterizations [14].

## NONAUGMENTED BLADDERS

Ureteral reimplantation alone is an acceptable intervention for nonaugmented patients when there is adequate bladder capacity and compliance. Surgery in these bladders can be technically difficult and bloody, with an increased risk of ureteral obstruction especially with intravesical techniques. High relapse rates of VUR have been described when this was attempted otherwise. With a highly compliant ( $>7$  mL/cmH<sub>2</sub>O) bladder with preserved capacity (% EBC [estimated bladder capacity] $>70\%$ ), even high grades of reflux have been successfully treated with ureteral reimplantation alone [6,11]. The reduction of bladder pressures in patients who undergo reimplantation is felt to be essential for favorable outcomes, and for this reason CIC and anticholinergics are commonly implemented following surgery [14]. More recently the use of alpha blockers has shown some promise in reducing bladder pressures via 2 mechanisms. As expected a reduction in outlet resistance lowers intravesical pressures but there has been evidence that vesical volumes can be increased by nonselective alpha blockers (ClinicalTrials.gov identifier: NCT00549939).

With regard to ureteral reimplantation technique, a number of approaches exist. The Politano-Ledbetter technique was the first described for management of primary VUR and was the predominant technique performed prior to the description of the cross-trigonal technique by Cohen in 1977 [7,17]. The latter is now considered the gold standard in uncomplicated VUR and the most commonly performed technique in the United States and Europe. The role for other techniques including the Lich-Gregoire extravesical technique and Glenn-Anderson technique has been poorly described in neurogenic bladder to date.

Politano-Ledbetter technique involves creation of a new ureteral hiatus cranial to the original hiatus, then tunneling the ureter through the submucosal layer down towards the original orifice. The creation of a new hiatus carries a greater risk for ureteral kinking [7]. Cohen cross-trigonal

technique preserves the original hiatus of the ureter. The ureter is tunneled through a submucosal layer across the trigone bringing its new location closer to that of the contralateral ureteral orifice. The disadvantage is that this procedure makes it exceedingly difficult to access the ureter in retrograde manner in the future. In neurogenic bladder patients, the Cohen cross-trigonal technique has produced successful results dating back to the late 1970s, with the primary advantages being simplicity due to decreased need for extravesical dissection, reduced risk of ureteral kinking, and increased space with which to create an adequate length submucosal tunnel particularly in smaller bladders [7]. In patients that have developed bladder trabeculations, the trigone is typically spared from distortion [18]. The cross-trigonal technique is also advantageous in this subset of patients [19]. While the Cohen cross-trigonal technique approaches a 100% success rate for primary VUR, its success in secondary VUR is cited as only approximately 85%–96% [11,20].

## ENDOSCOPIC ANTIREFLUX PROCEDURES

Despite the very high success rates of open ureteral reimplantation in primary VUR, endoscopic antireflux surgery such as with subureteral injection of Deflux (dextranomer/hyaluronic acid) has been popularized due to relative ease of use and substantially reduced morbidity. Its role in secondary VUR is evolving, though it has drawn appeal for similar reasons. Success rates for these procedures in neurogenic bladder patients has been reported at anywhere from 53% to 86%, which are lower than success rates in primary VUR [21,22]. Exact data is difficult to extrapolate as historically, various bulking agents have been studied and compared. What has been concluded is that this procedure is generally less effective in higher grades of reflux and typically produces transient rather than permanent successes. Patients do require long-term follow-up due to the potential for late VUR recurrences [21]. However, these shortcomings are offset in that the procedure requires substantially reduced operative time, involves minimal complexity, and patients can be seen in the outpatient setting with no associated hospital stay, minimal pain, and minimal complications [11,21]. Additionally, if reflux fails to resolve, the injection does not preclude the patient from having a definitive surgery, and for the most part, should not make a definitive surgery more difficult to perform [11,21,23]. Unfortunately, there have been numerous reports by surgeons that significant difficulties can be encountered in some patients due to the bulking agents causing fibrotic

reactions encasing the ureter (the senior author included).

Very limited studies have suggested similar selection criteria for intervention with endoscopic VUR surgery as with ureteral reimplantation in neurogenic bladder patients. Namely, bladder capacity should be adequately preserved and compliance should be near normal [24]. This minimally invasive procedure has historically proven to be resilient despite moderately compromised bladder compliance [11,21]. Particular challenges are seen in those with trabeculated bladders whose ureteral orifices may not be identifiable or may be patulous from bladder distortion. Postprocedure complications such as obstruction at the UVJ have been more common in neurogenic bladders compared to non-neurogenic bladders [23,25]. Despite the risks, benefits may be substantial in this patient population, and some advocate for endoscopic antireflux surgery to be considered before resorting to open surgeries when CIC fails [22].

## AUGMENTED BLADDERS

In patients who have high-grade reflux in the setting of a dysfunctional neurogenic bladder, augmentation cystoplasty is typically performed with ureteral reimplantation [6]. Reimplantation of the ureters into a thick-walled bladder is technically challenging, and adds operative time and morbidity to an already complex augmentation surgery. Some have argued that if detrusor pressures can be lowered with augmentation alone, there may not be a role for concurrent antireflux surgery [12,18,26]. This theory was initially supported by several small series. Nasrallah et al. [18] demonstrated in 14 patients with varying degrees of reflux from grade II to V, poor bladder capacity (functional capacity of 40–210 mL), and poor compliance (leak point pressure >40 and <80 cmH<sub>2</sub>O) that reflux resolution could be achieved with augmentation alone, at least during a follow-up period of 72 months. Later studies with increased number of patients and longer follow-ups reinforced these findings [12,27]. It has been postulated that persistence of reflux postoperatively in these patients may simply be a measure of the quality of the augmentation surgery, similar to the persistence of incontinence following these surgeries [18].

The downside of an augmentation-only method of management is that it does not account for other mechanisms that may factor into VUR in these patients such as UVJ incompetence from surrounding distortions (trabeculations or diverticula) or from chronic infection. After enterocystoplasty, bacteriuria is common and risk of infection remains significant [6]. It is unclear whether these factors play a role when VUR persists after augmentation

surgery. Long-term complications of augmentation cystoplasty are also not insignificant, and include reduced bone mineral density and osteoporosis [28] along with bladder calculi. Bladder rupture is another risk that can potentially lead to death in these patients. Decision to proceed with this major surgery should be weighed heavily against the risks and benefits.

More recently, there have been studies demonstrating efficacy of intradetrusor botulinum-A toxin when combined with Deflux subureteral injection to target elevated pressures and reflux using minimally invasive techniques [24]. Additional studies will be needed to determine whether these are safe interventions that can produce durable results in the long-term.

## CONCLUSIONS

Compared to primary VUR, secondary VUR in neurogenic bladder patients is less likely to spontaneously resolve, less likely to be cured with antireflux surgery independent of technique or surgical approach. The common denominator that likely separates this patient population from achieving the success rates of the primary VUR population is suboptimal bladder dynamics. Whether reflux in neurogenic bladder is addressed by CIC/anticholinergics, selective and nonselective alpha blockers, ureteral reimplantation, endoscopic surgery, or bladder augmentation alone, the key to improved outcomes appears to be optimization or preservation of adequate bladder capacity and compliance. The risks and benefits of management options must be weighed with consideration of each individual case.

## CONFLICTS OF INTEREST

The authors have nothing to disclose.

## REFERENCES

1. Bauer SB. Neurogenic bladder: etiology and assessment. *Pediatr Nephrol* 2008;23:541-51.
2. Brereton RJ, Narayanan R, Ratnatunga C. Ureteric re-implantation in the neuropathic bladder. *Br J Surg* 1987;74:1107-10.
3. Sidi AA, Peng W, Gonzalez R. Vesicoureteral reflux in children with myelodysplasia: natural history and results of treatment. *J Urol* 1986;136(1 Pt 2):329-31.
4. Koff SA. Relationship between dysfunctional voiding and reflux. *J Urol* 1992;148(5 Pt 2):1703-5.
5. Seki N, Akazawa K, Senoh K, Kubo S, Tsunoda T, Kimoto Y, et al. An analysis of risk factors for upper urinary tract deteriora-

- tion in patients with myelodysplasia. *BJU Int* 1999;84:679-82.
6. Morioka A, Miyano T, Ando K, Yamataka T, Lane GJ. Management of vesicoureteral reflux secondary to neurogenic bladder. *Pediatr Surg Int* 1998;13:584-6.
  7. Gierup J, Esscher T, Jorulf H. Experience of the Cohen method for ureteral reimplantation in complicated cases. *Z Kinderchir* 1981;34:255-9.
  8. Agarwal SK, Khoury AE, Abramson RP, Churchill BM, Argiropoulos G, McLorie GA. Outcome analysis of vesicoureteral reflux in children with myelodysplasia. *J Urol* 1997;157:980-2.
  9. Cohen RA, Rushton HG, Belman AB, Kass EJ, Majd M, Shaer C. Renal scarring and vesicoureteral reflux in children with myelodysplasia. *J Urol* 1990;144(2 Pt 2):541-4.
  10. López Pereira P, Martínez Urrutia MJ, Lobato Romera R, Jaureguizar E. Should we treat vesicoureteral reflux in patients who simultaneously undergo bladder augmentation for neuropathic bladder? *J Urol* 2001;165(6 Pt 2):2259-61.
  11. Granata C, Buffa P, Di Rovasenda E, Mattioli G, Scarsi PL, Podesta E, et al. Treatment of vesico-ureteric reflux in children with neuropathic bladder: a comparison of surgical and endoscopic correction. *J Pediatr Surg* 1999;34:1836-8.
  12. Simforoosh N, Tabibi A, Basiri A, Noorbala MH, Danesh AD, Ijadi A. Is ureteral reimplantation necessary during augmentation cystoplasty in patients with neurogenic bladder and vesicoureteral reflux? *J Urol* 2002;168(4 Pt 1):1439-41.
  13. Kaefter M, Pabby A, Kelly M, Darbey M, Bauer SB. Improved bladder function after prophylactic treatment of the high risk neurogenic bladder in newborns with myelomeningocele. *J Urol* 1999;162(3 Pt 2):1068-71.
  14. Merlini E, Beseghi U, De Castro R, Perlasca E, Podesta E, Riccipetroni G. Treatment of vesicoureteric reflux in the neurogenic bladder. *Br J Urol* 1993;72:969-71.
  15. Schlager TA, Clark M, Anderson S. Effect of a single-use sterile catheter for each void on the frequency of bacteriuria in children with neurogenic bladder on intermittent catheterization for bladder emptying. *Pediatrics* 2001;108:E71.
  16. Schlager TA, Dilks S, Trudell J, Whittam TS, Hendley JO. Bacteriuria in children with neurogenic bladder treated with intermittent catheterization: natural history. *J Pediatr* 1995;126:490-6.
  17. Cohen SJ. The Cohen reimplantation technique. *Birth Defects Orig Artic Ser* 1977;13:391-5.
  18. Nasrallah PF, Aliabadi HA. Bladder augmentation in patients with neurogenic bladder and vesicoureteral reflux. *J Urol* 1991;146(2 Pt 2):563-6.
  19. Belloli GP, Musi L, Campobasso P, Cattaneo A. Ureteral reimplantation in children with neurogenic bladder. *J Pediatr Surg* 1979;14:119-27.
  20. Kondo A, Otani T. Correction of reflux with the ureteric crossover method. Clinical experience in 50 patients. *Br J Urol* 1987;60:36-8.
  21. Engel JD, Palmer LS, Cheng EY, Kaplan WE. Surgical versus endoscopic correction of vesicoureteral reflux in children with neurogenic bladder dysfunction. *J Urol* 1997;157:2291-4.
  22. Perez-Brayfield M, Kirsch AJ, Hensle TW, Koyle MA, Furness P, Scherz HC. Endoscopic treatment with dextranomer/hyaluronic acid for complex cases of vesicoureteral reflux. *J Urol* 2004;172(4 Pt 2):1614-6.
  23. Misra D, Potts SR, Brown S, Boston VE. Endoscopic treatment of vesico-ureteric reflux in neurogenic bladder: 8 years' experience. *J Pediatr Surg* 1996;31:1262-4.
  24. Neel KF, Salem M, Soliman S. Total endoscopic management (TEM approach) of children with non-compliant neuropathic bladder: a preliminary report. *J Pediatr Urol* 2008;4:124-6.
  25. Vandersteen DR, Routh JC, Kirsch AJ, Scherz HC, Ritchey ML, Shapiro E, et al. Postoperative ureteral obstruction after subureteral injection of dextranomer/hyaluronic Acid copolymer. *J Urol* 2006;176(4 Pt 1):1593-5.
  26. Krishna A, Gough DC. Evaluation of augmentation cystoplasty in childhood with reference to vesico-ureteric reflux and urinary infection. *Br J Urol* 1994;74:465-8.
  27. Zhang HC, Yang J, Ye X, Hu HF. Augmentation enterocystoplasty without reimplantation for patients with neurogenic bladder and vesicoureteral reflux. *Kaohsiung J Med Sci* 2016;32:323-6.
  28. Hafez AT, McLorie G, Gilday D, Laudenberg B, Upadhyay J, Bagli D, et al. Long-term evaluation of metabolic profile and bone mineral density after ileocystoplasty in children. *J Urol* 2003;170(4 Pt 2):1639-41.