

Early thrombolytic failure in a patient with massive pulmonary embolism combined with multiple organ dysfunction syndrome: what next?

Journal of International Medical Research

2018, Vol. 46(8) 3440–3445

© The Author(s) 2018

Article reuse guidelines:

sagepub.com/journals-permissions

DOI: 10.1177/0300060518778120

journals.sagepub.com/home/imr



Furong Liu^{1,#}, Song Yang^{1,#}, Weishuo Liu²,
Baiyun Tang¹, Wenbo Zhang¹, Cheng Zhang³,
Wenwei Liao³ and Anbin Hu³

Abstract

Carbon monoxide (CO) poisoning, the most frequent type of poisoning, alters hemodynamics and creates tissue hypoxia that ultimately leads to thromboembolism. We herein describe a previously healthy 17-year-old male patient who developed acute CO poisoning while bathing in the same room as a gas heater. He was first treated with urokinase thrombolytic therapy at a local hospital, which proved ineffective. The patient was admitted to our hospital with unstable circulation and was diagnosed with massive pulmonary embolism combined with multiple organ dysfunction syndrome. His Acute Physiology and Chronic Health Evaluation II score was 22, and his Sequential Organ Failure Assessment score was 15. We faced a difficult decision regarding whether to perform surgical embolectomy or to repeat the thrombolysis. We opted to repeat the thrombolysis with successful results. Our experience may help clinicians manage similar cases in the future.

Keywords

Carbon monoxide, pulmonary embolism, multiple organ dysfunction syndrome, tissue hypoxia, urokinase, thrombolysis

Date received: 31 July 2017; accepted: 30 April 2018

³Department of General Surgery, The First Affiliated Hospital of Sun Yat-sen University, Guangzhou, China

[#]These authors contributed equally to this work.

Corresponding author:

Anbin Hu, Department of General Surgery, The First Affiliated Hospital of Sun Yat-sen University, No. 58 Zhongshan 2nd Road, Yuexiu District, Guangzhou 510080, China.

Email: anbinhu@163.com

¹Department of Cardiac Surgical Intensive Care, The First Affiliated Hospital of Sun Yat-sen University, Guangzhou, China

²Department of Pathology of the First Affiliated Hospital of Soochow University, Suzhou, China



Introduction

Carbon monoxide (CO) binds to hemoglobin with an affinity 200 times higher than that of oxygen,¹ producing carboxyhemoglobin and thereby blocking hemoglobin from carrying oxygen. This causes hemodynamic disturbances and leads to tissue hypoxia, resulting in thromboembolism in various parts of the body; pulmonary embolism occurs most frequently, and intracardiac thromboembolism and systemic embolism are less common.^{2,3} Diagnosis of pulmonary embolism is based mainly on clinical symptoms, laboratory examination, and imaging findings.^{4,5} Few reports have described pulmonary embolism complicated with multiple organ dysfunction syndrome in which early thrombolytic therapy failed. We herein report such a case, which we ultimately treated through repeat thrombolysis with a successful outcome. This case is being reported to illustrate that thrombolytic therapy may be superior to surgery for patients with high-risk pulmonary embolism. Such information may be very useful in the clinical setting.

Case report

A healthy 17-year-old male patient was referred to our hospital for treatment of

CO poisoning that had occurred while he was bathing near a gas heater. Half an hour after the poisoning, he was found foaming at the mouth, delirious, and cold to the touch, but he had no physical tics or incontinence. He was admitted to a local hospital 1 hour after the poisoning, where he recovered consciousness. Approximately 2 hours after the poisoning, he was transferred to the intensive care unit of a local traditional Chinese medicine hospital. Upon admission, he felt dizziness, chest tightness, chills, and shortness of breath. His blood pressure could not be measured, and laboratory examinations revealed dysfunction of the heart, liver, kidney, pancreas, and blood coagulation. Computed tomography of the brain showed normal findings, but computed tomography angiography (CTA) of the pulmonary arteries suggested multiple embolisms in the bilateral pulmonary arteries, upper and lower pulmonary artery trunk, and various blood vessel branches (Figure 1(a)). Computed tomography of the chest showed the same results as pulmonary CTA, and computed tomography of the abdomen suggested thrombosis in the inferior vena cava near the liver (Figure 2(a)). Cardiac echocardiography indicated an enlarged right

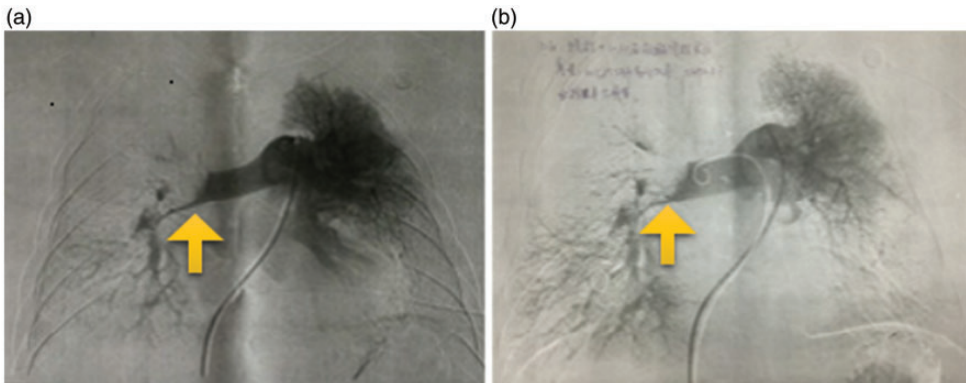


Figure 1. Pulmonary artery computed tomography angiography showed a lack of obvious effects of thrombolysis treatment in the right pulmonary artery trunk. (a) Before interventional therapy. (b) After therapy.

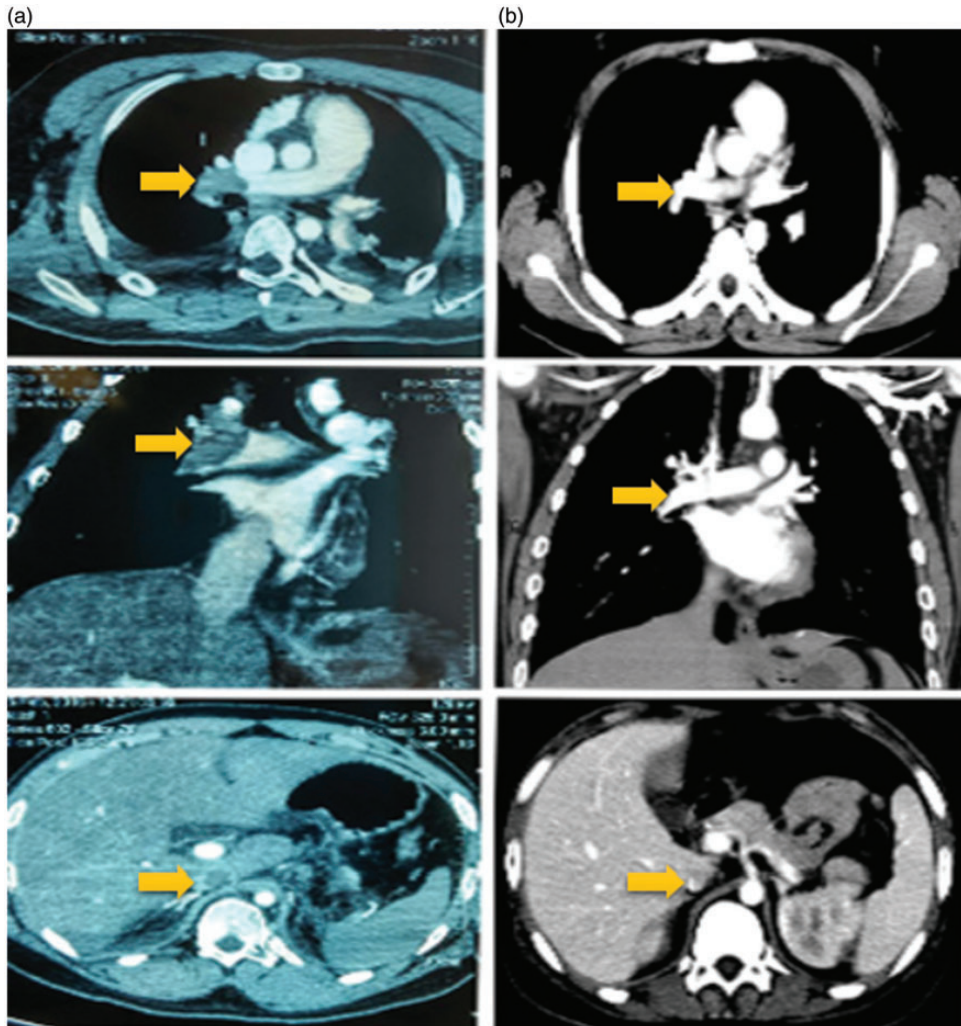


Figure 2. Chest and abdominal computed tomography showing (from top to bottom) chest axial, chest coronal, and abdomen axial views. (a) Views on admission to our hospital. These views suggested multiple embolisms in the bilateral pulmonary artery, upper and lower pulmonary artery trunk, and branches of blood vessels as well as in the inferior vena cava near the liver section thrombosis. (b) Views at discharge. These views indicated residual thrombi in the left pulmonary artery trunk and in the basal segments of the lower lobe of the left lung and inferior vena cava near the liver-filling defect. Differences in the thrombus before and after treatment are indicated using arrows.

atrium and right ventricle, moderate tricuspid regurgitation, and mild hypertension in the pulmonary artery. Bilateral lower extremity arteriovenous color Doppler imaging showed no obvious abnormalities.

After these examinations, the patient's vital signs again became unstable. He was immediately intubated and mechanically ventilated and sent to the emergency department for urokinase therapy (600,000 IU)

together with norepinephrine to maintain his blood pressure. CTA after thrombolysis showed improvement in the right lower pulmonary artery branches, but not in the right pulmonary artery trunk (Figure 1(b)). The patient's hemodynamics remained unstable, suggesting ineffective thrombolysis. At 18 hours after poisoning, he was transferred to the cardiac surgery intensive care unit of our hospital. He arrived in a coma and was given noradrenaline (0.7 µg/kg/min) to maintain stable blood circulation. The patient's laboratory findings are shown in Table 1. His Acute Physiology and Chronic Health Evaluation (APACHE) II score was 22, and his Sequential Organ Failure Assessment (SOFA) score was 15.

The patient was diagnosed with acute massive pulmonary embolism combined with multiple organ dysfunction syndrome. His condition was critical, so we conducted multidisciplinary consultations to guide further treatment. Clinicians from cardiac surgery considered that the embolisms should be removed through emergency surgery with the aid of extracorporeal membrane oxygenation because the patient had massive pulmonary embolism, poor oxygenation, and hemodynamic instability. Clinicians from the medical intensive care unit considered that the patient's previous thrombolytic treatment had been insufficient and that given the indications for repeat thrombolysis, he would benefit from repeat venous thrombolytic therapy. After comprehensive evaluation and careful consideration, we decided to repeat the thrombolytic therapy. On the following afternoon, we treated the patient with actilyse (50 mg intravenously, 25 mg/h) together with nitric oxide, sildenafil, and treprostinil to reduce his pulmonary artery pressure. We also administered drugs to reduce his intracranial pressure and performed continuous renal replacement therapy for acute renal failure to alleviate whole-body edema. After all of these

Table 1. Blood gas analysis and laboratory results on admission and during treatment.

Time	pH	PO ₂ /FIO ₂	WBC (×10 ⁹ /L)	PLT (×10 ⁹ /L)	D-Dimer	PCT (ng/ml)	BNP (pg/ml)	CK-MB (ng/ml)	ALT (U/L)	AST (U/L)	AMYL (U/L)	CREA (µmol/L)
On admission	7.38	114	25	23	89.49	59	6834	27.98	8845	6911	474	166
Day 1	7.03	186	20	53	768.56			12.51	11,953	7561		357
Day 2	7.37	399	17	66	321.25	220	18,337	11.46	4598	4113		456
Day 3	7.41	436	11	59	124.31	146	9256	7.22	1596	2762		380
Day 4	7.39	365	11	79					690	1995		350
Day 5	7.34	438	11	95	18.18	81	17,693		340	1335	198	
Day 6	7.35	554	10	186		37	21,167	0.95	154	714		352
Day 7	7.35	419	11	261		18	28,295		95	449		513

pH, potential of hydrogen; PO₂, oxygen partial pressure; FIO₂, fraction of inspired oxygen; WBC, white blood cells; PLT, platelets; PCT, procalcitonin; BNP, brain natriuretic peptide; CK-MB, creatine kinase-MB; ALT, alanine transaminase; AST, aspartate transaminase; AMYL, amylase; CREA, creatinine.

treatments, his blood gas analysis results indicated significant improvement in his oxygenation index (Table 1), and his hemodynamics gradually stabilized.

On day 2, we administered the anticoagulant drug enoxaparin, and the patient woke up on day 3. On day 4, we administered the oral anticoagulant drug warfarin (1.5 mg), and by day 5 his hemodynamics had stabilized completely without the need for booster drugs. He was extubated after the blood gas findings were satisfactory. One week later, the patient's laboratory findings indicated significant improvement (Table 1), and he was transferred out of the cardiac surgery intensive care unit. Twenty-five days later, he was discharged from our hospital with stable vital signs and a normal urine volume. Computed tomography of the chest and abdomen indicated a residual thrombi in the left pulmonary artery trunk, in basal segments of the lower lobe of the left lung, and in the inferior vena cava near the liver-filling defect (Figure 2(b)).

Both verbal and written informed consent was obtained from the patient described in this case report. Because consent was obtained and this was a clinical case report, ethical approval was not required for this study.

Discussion

It is unusual for CO poisoning to cause thromboembolic accidents, and how this occurs is unclear; mechanisms involving oxygen free radicals and cell apoptosis have been suggested.⁵ It is even more unusual for CO poisoning to lead to massive pulmonary embolism combined with multiple organ dysfunction syndrome that does not respond to early thrombolytic therapy. We have herein described such a case, which we successfully treated by repeat thrombolytic therapy.

Massive pulmonary embolism is usually treated by surgical embolectomy or

thrombolysis. For acute massive pulmonary embolism, some researchers believe that surgical embolectomy is superior to thrombolysis,^{6,7} and it has been proposed as the first treatment option when thrombolysis is contraindicated and echocardiography suggests an embolus.⁸ Several interventional thrombolysis methods have been described, each with its own advantages and disadvantages, and there is little consensus about how to choose among them.^{9,10}

When deciding on the best treatment for our patient, we considered his young age, his lack of coagulation history, the rapid onset of his condition, and his extremely high APACHE II and SOFA scores associated with extremely high mortality. These factors, together with his severe hypoxemia and hemodynamic instability, led us to classify the patient as having high-risk pulmonary embolism according to the 2014 European Society of Cardiology (ESC) Guidelines on the Diagnosis and Management of Acute Pulmonary Embolism.¹¹ These guidelines recommend thrombolytic therapy to resolve pulmonary obstruction and reduce pulmonary artery pressure and resistance, thereby improving right ventricular function.¹²

In addition, according to the recommendations of the American Heart Association,¹³ the patient could have also undergone surgical thrombus denudation for his unstable hemodynamics, worsening respiratory failure, and severe right ventricular dysfunction. However, the 2014 ESC Guidelines¹¹ recommend thrombus resection for patients in whom anticoagulation therapy previously failed or is contraindicated.

We considered that the effect of the previous thrombolytic therapy received by our patient was poor, and there were no contraindications for choosing thrombolytic treatment again. Therefore, we opted to repeat the thrombolysis, and this proved effective.

Our case suggests that thrombolytic therapy may be superior to surgery for patients with high-risk pulmonary embolism, and it

highlights the importance of adequate thrombolysis as soon as possible. The patient's condition after such therapy should be carefully monitored, and extracorporeal membrane oxygenation may be useful for improving blood circulation and oxygenation.

Declaration of conflicting interest

The authors declare that there is no conflict of interest.

Funding

This research received no specific grant from any funding agency in the public, commercial, or not-for-profit sectors.

References

1. Wu PE and Juurlink DN. Carbon monoxide poisoning. *CMAJ* 2014; 186: 611.
2. Nagy Z, Kenez J, Simon L, et al. [Partial thrombosis of the superior sagittal sinus following carbon monoxide poisoning]. *Orv Hetil* 1984; 125: 3181–3184[in Hungarian, English Abstract].
3. Ryoo SM, Sohn CH, Kim HJ, et al. Intracardiac thrombus formation induced by carbon monoxide poisoning. *Hum Exp Toxicol* 2013; 32: 1193–1196.
4. Hampson NB, Piantadosi CA, Thom SR, et al. Practice recommendations in the diagnosis, management, and prevention of carbon monoxide poisoning. *Am J Respir Crit Care Med* 2012; 186: 1095–1101.
5. Stein PD, Fowler SE, Goodman LR, et al. Multidetector computed tomography for acute pulmonary embolism. *N Engl J Med* 2006; 354: 2317–2327.
6. Cho YH, Sung K, Kim WS, et al. Management of acute massive pulmonary embolism: Is surgical embolectomy inferior to thrombolysis? *Int J Cardiol* 2016; 203: 579–583.
7. Cho YH and Kim WS. Surgical embolectomy as a first line treatment for acute massive pulmonary embolism. *Int J Cardiol* 2016; 222: 785.
8. Celik T, Balta S, Ozturk C, et al. The best treatment option in the management of patients with acute massive pulmonary embolism: surgery or thrombolysis? *Int J Cardiol* 2016; 214: 286–287.
9. Weeda ER, Wells PS, Peacock WF, et al. Outcomes associated with observation status versus inpatient management of pulmonary embolism patients anticoagulated with rivaroxaban. *Int J Cardiol* 2016; 222: 846–849.
10. Ho HH, Chong V, Mok KH, et al. Successful treatment of 2 complex cases of international traveller's pulmonary embolism using conventional therapy and novel oral anticoagulant. *Int J Cardiol* 2016; 222: 254–256.
11. Konstantinides SV, Torbicki A, Agnelli G, et al. 2014 ESC guidelines on the diagnosis and management of acute pulmonary embolism. *Eur Heart J* 2014; 35: 3033–3069, 3069a–3069k.
12. Goldhaber SZ, Haire WD, Feldstein ML, et al. Alteplase versus heparin in acute pulmonary embolism: randomised trial assessing right-ventricular function and pulmonary perfusion. *Lancet* 1993; 341: 507–511.
13. Jaff MR, McMurtry MS, Archer SL, et al. Management of massive and submassive pulmonary embolism, iliofemoral deep vein thrombosis, and chronic thromboembolic pulmonary hypertension: a scientific statement from the American Heart Association. *Circulation* 2011; 123: 1788–1830.