



Case report

Chronic excruciating forearm pain in a child with intra-neural hemangioma: A challenging case report

Ramin Zargarbashi^a, Arezou Hashem Zadeh^b, Fardis Vosoughi^{c,*}

^a Department of Pediatric Orthopedy, Faculty of Medicine, Tehran University of Medical Sciences, Tehran, Iran

^b Advanced Diagnostic and Interventional Radiology Research Center (ADIR), Medical Imaging Center, Imam Khomeini Hospital, Tehran University of Medical Sciences, Tehran, Iran.

^c Fellowship of Knee Sport and Reconstruction Surgery, Department of Orthopaedic and Trauma Surgery, Shariati Hospital and School of Medicine, Tehran University of Medical Sciences, Tehran, Iran.

ARTICLE INFO

Keywords:

Hemangioma
Shoulder
Dislocation
Pain
Recurrence
Case report

ABSTRACT

Introduction and importance: Cavernous hemangioma is a rare form of hemangioma. It usually arises in the central nervous system, but the tumor has also been reported in the liver, retina and skin with a lower prevalence. Its occurrence into the peripheral nerves has only been reported a few times. Herein, we report an extremely rare case of intra-neural hemangioma in the ulnar nerve and discuss the complications we faced following surgery. **Case presentation:** We present a 6-year-old boy with history of severe progressive left forearm pain in the last two years. Imaging studies revealed a soft tissue mass and histopathological exam was in favor of a cavernous hemangioma. Patient underwent surgery to excise the tumor. Despite temporary response, he began to experience excruciating pain shortly after surgery which caused him to adopt bizarre postures. **Clinical discussion:** In the more common form of nerve involvement in a hemangioma, the nerve is displaced and surrounded by the tumor. However, in cases with intra-neural involvement, the nerve would have to be sacrificed. This case report brings some rare but important characteristics of a hemangioma in to attention, such as the intra-neural location, possibility of recurrence and aggravating pain with bizarre positions as a result. **Conclusion:** In cases of intra-neural hemangioma, there is a chance that the patient experiences recurrence and/or excruciating pain following surgery. The orthopedic surgeon should be prepared for the possibility of nerve transfer, repeat surgeries and the need for prolonged palliative pain suppression modalities in the approach to intra-neural hemangioma.

1. Introduction

Hemangiomas are distinguished by hyperplasia of endothelial, multi-laminated basement membrane formation beneath. Hemangiomas are rare benign vascular tumors, characterized by endothelial hyperplasia, which mostly arise during infancy and childhood [1]. Advanced maternal age, placental abnormalities, female gender, white race, prematurity and twin pregnancy increase the risk of developing hemangiomas. Classification of benign vascular tumors are based on: (1) the type of fluid they contain; as either hemangioma (blood-containing lesion) or lymphangioma (lymph-containing lesion). (2) the size of the vascular structures; as either capillary for small diameter or cavernous for large diameter vessels [2].

Hemangiomas mostly arise in the head and neck (60%), trunk (25%) and the extremities (15%) [3]. Cavernous hemangioma is a rare form of hemangioma. It mostly arises in the central nervous system, but the tumor has also been reported in the liver, retina and skin with a lower prevalence. Its occurrence in the peripheral nerves has been previously reported a few times [4–7]. It often presents as a painful mass which could be accompanied by paresthesia, paresis, localized or referral pain or neurological deficits [8,9].

Herein, we present a case of intraneural hemangioma of the ulnar nerve in the left forearm of a 6-year-old boy which was removed surgically by nerve resection and using the Mackinnon technique for nerve transfer to treat the resulting ulnar claw hand deformity.

Abbreviations: SCARE guideline, Surgical CAse REport; MRI, Magnetic resonance imaging; GA, General anesthesia.

* Corresponding author at: Fellowship of Knee Sport and Reconstruction Surgery, Department of Orthopaedic Surgery, Shariati Hospital, Tehran University of Medical Sciences, Tehran, Iran.

E-mail address: fardis.vosoughi@gmail.com (F. Vosoughi).

<https://doi.org/10.1016/j.ijscr.2021.106561>

Received 17 September 2021; Received in revised form 30 October 2021; Accepted 30 October 2021

Available online 3 November 2021

2210-2612/© 2021 The Authors. Published by Elsevier Ltd on behalf of IJS Publishing Group Ltd. This is an open access article under the CC BY-NC-ND license

(<http://creativecommons.org/licenses/by-nc-nd/4.0/>).

2. Report of the case

The current work has been reported in line with the SCARE 2020 criteria [10].

A 6-year-old boy presented with a 2-year history of severe progressive left forearm pain, swelling and paresthesia on the ulnar-side fingers. The pain was intense and minimal relief was achieved with the use of analgesics. He did not have any similar symptoms in the past and did not mention any history of recent trauma. Past medical history was not significant. He had a twin brother with no relevant medical history. His mother, on the other hand, had been diagnosed and treated for follicular thyroid carcinoma.

Physical examination showed a firm soft tissue mass on the ulnar side of the volar surface of his left forearm. The mass was easily mobile and slightly tender on palpation. He had hyper-sensitivity and paresthesia in his 4th and 5th fingers with a positive Tinel's sign. Atrophy and paresis of the muscles innervated by the ulnar nerve was also evident.

Simple forearm radiographs showed no bony pathology (Fig. 1). The ultrasound study revealed a well-defined, solid heterogenous mass on the volar aspect of the left forearm. Color Doppler study also reported vascularized heterogenous mass with approximate dimensions of 5.4 × 1.7 cm.

MRI with and without injection of intra-venous gadolinium was highly suggestive of cavernous hemangioma on the ulnar aspect of the forearm, with involvement of the neurovascular bundles (Fig. 2). Volar muscles including the deep and superficial finger flexors, pronator teres, flexor carpi ulnaris and palmaris longus were involved by the lesion. Neurovascular bundles also appeared to be encased by the mass. Although in close proximity to radius and ulna, there was no sign of bony invasion. Incisional biopsy confirmed the diagnosis of a cavernous hemangioma with the ulnar nerve trapped in the tumor. Thereafter, the patient was admitted for surgical resection of the tumor. Gross examination revealed a dark blue/purplish intra-neural mass with elastic consistency which encased the ulnar nerve completely (Fig. 3). Enbloc resection was performed and the ulnar nerve was sacrificed. All procedures were performed by a fellowship trained pediatric orthopedic surgeon (R.Z.).

Following the operation, the patient's pain was relieved to some extent and ulnar claw hand deformity became evident. He was

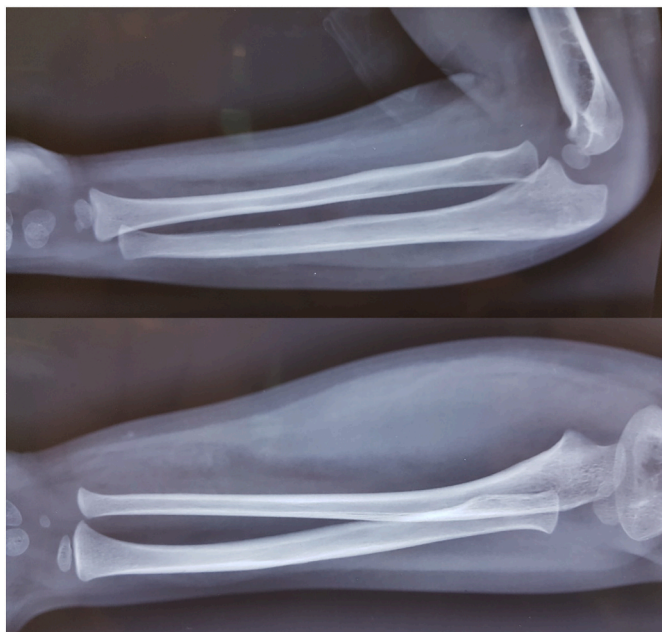


Fig. 1. Simple AP and lateral radiographs of the patient's left forearm on presentation.

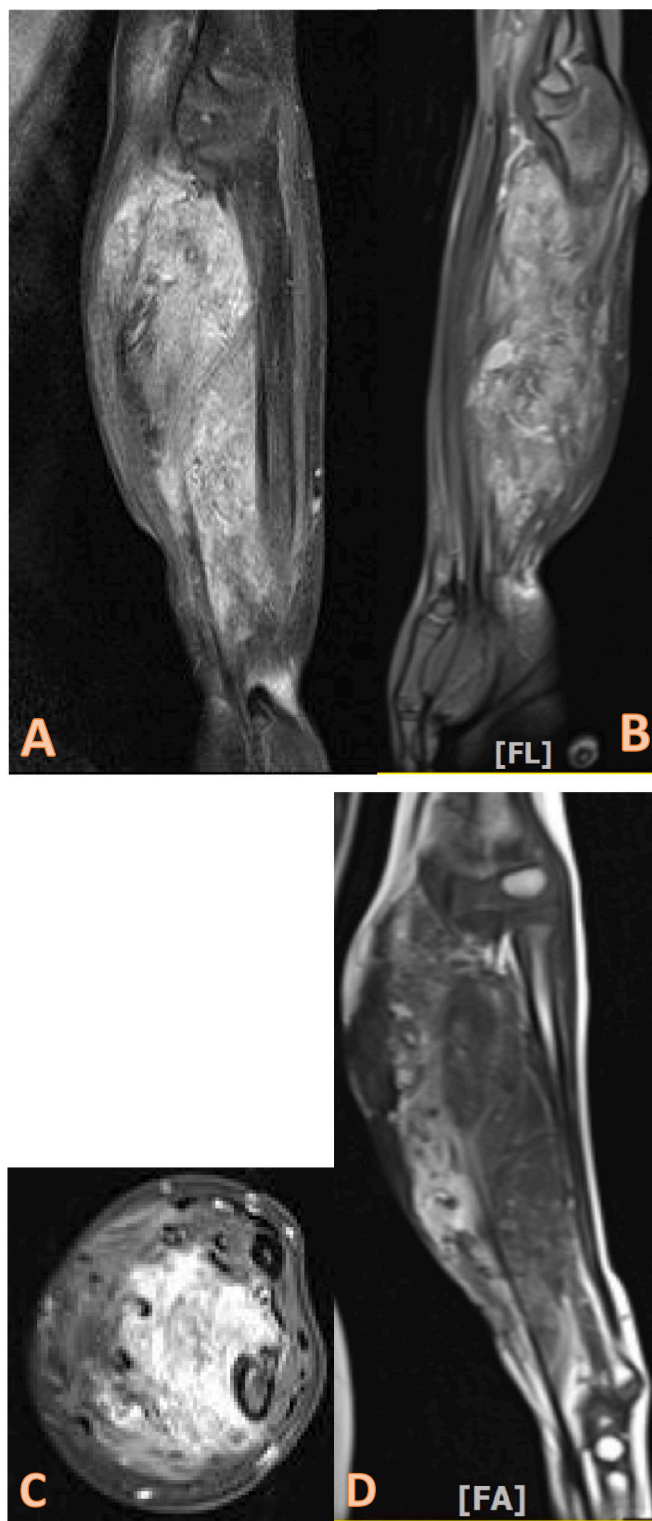

Fig. 2. MRI images of the left forearm showing a hypersignal mass in T2 sequences (B, D) and after injection of contrast media (A,C).

ultimately able to regain ulnar nerve motor function after undergoing a nerve transfer from the motor branch of the anterior interosseus nerve (Mackinnon's technique) [11].

Unfortunately, the pain relief was only temporary and after 2 months from the surgery, the patient began to re-experience severe forearm pain. The pain was unresponsive to common analgesics (either oral or by injection). Soon he began adopting a bizarre posture of the upper limb

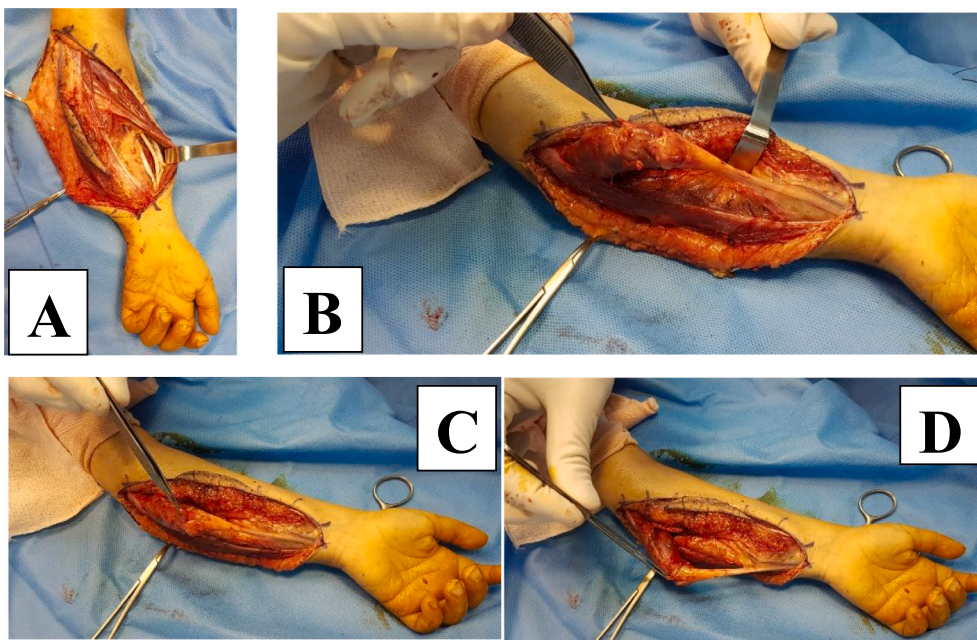


Fig. 3. Intra-operative of the left forearm showing the volar compartment (A), exploration of the ulnar nerve (B) and the soft tissue mass encompassing the ulnar nerve (C, D).

behind his neck to reduce the pain. When he returned to the clinic, his upper limb was completely behind his neck with the shoulder joint in hyper-adduction and external rotation (Fig. 4). Apparently, this position made the pain to go away. The malposition of the limb was so severe that we suspected inferior shoulder dislocation. Simple shoulder radiographs revealed inferior dislocation of the shoulder which is the rarest form. We decided to perform closed reduction under general anesthesia (GA). As soon as the patient went under GA, the position of his limb was corrected. In order to control his pain, regional nerve block was administered which has been effective so far, although he occasionally continues to experience pain in the intervals between the nerve blocks. The possibility of a limb amputation was discussed with the parents but they would rather continue controlling the pain by nerve blocks.

3. Clinical discussion

Cavernous hemangiomas are composed of dilated, blood-filled

spaces, lined by flattened endothelium. Hemangiomas account for 6.5%–8% of all benign soft tissue tumors [8]. They usually arise within the first three decades of life and are classified into 5 histopathological groups: (1) capillary, (2) cavernous, (3) arteriovenous, (4) venous, and (5) mixed [2]. Cavernous hemangioma is composed of blood-filled ‘lakes’ and channels and is considered to be one of the rare soft tissue tumors that occur mainly in the central nervous system. Peripheral nerve involvement by this tumor is a rare finding. Involvement varies from perineural to intraneural. In the more common scenario, the nerve is displaced and surrounded by the tumor and intra-neural involvement of a peripheral nerve by hemangioma is an extremely rare finding with a few reports existing in the current literature. The most common involved nerve in the literature is the median nerve [12,13]. Most patients presented with a palpable mass, along with sensory and/or motor deficits related to the involved nerve [14].

Ultrasound and magnetic resonance Imaging (MRI) are acceptable diagnostic tools which provide valuable information on the tumor’s

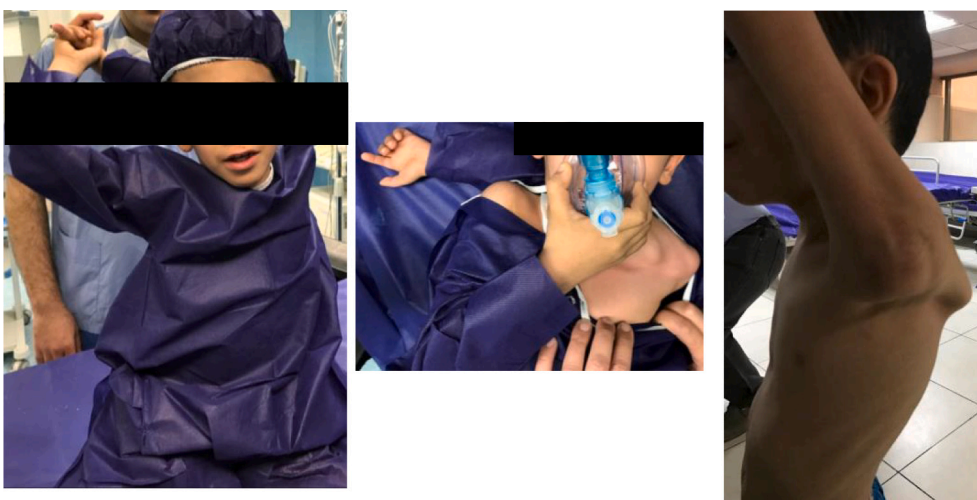


Fig. 4. Patient assumed his left upper limb in a bizarre posture with hyperabduction and external rotation of the shoulder which had resulted in inferior shoulder dislocation.

vascularity, anatomic location, size and its relationship to the surrounding neurovascular structures [13,14]. Features such as well-defined margins and posterior acoustic enhancement in a hypoechoic mass on an ultrasound exam as well as a well-defined, rounded, hyperintense, heterogeneous mass with contrast enhancement are compatible with the diagnosis of hemangioma [2].

Albeit, similar features can also present in other neoplasms like schwannoma and malignant peripheral nerve sheath tumors along with vascular malformations [15].

In many cases physicians prefer to manage these lesions conservatively but mostly the outcomes were not satisfying and more invasive treatments seem to be necessary. Complete surgical excision with or without nerve graft or nerve transfer is the treatment of choice even though depending on the size of the tumor, involved nerve and soft tissue attachments it might not be always feasible. In cases which complete resection is not an option, partial resection as a temporary management to control the symptoms can be done but the recurrence is probable [8,13,14,16,17]. For unresectable hemangiomas radiotherapy can be done to reduce the tumor size and symptom relief [18].

4. Conclusion

Herein, we reported a rare case of forearm intraneural cavernous hemangioma. After en bloc excision patient experienced recurrence of severe pain which was resistant to conservative measures and had to undergo nerve block. This case alerts the orthopedic surgeons on the recurrent nature of pain after excising hemangioma of the limb.

Sources of funding

No funding was received for the current study.

Consent for publication

Written informed consent was obtained from the patient for publication of this case report and accompanying images. A copy of the written consent is available for review by the Editor-in-Chief of this journal on request.

Research registration

N/A.

Guarantor

Dr. Ramin Zargarbashi.

Provenance and peer review

Not commissioned, externally peer-reviewed.

Ethical approval

Not applicable

Consent

Written informed consent was obtained from the patient for publication of this case report and accompanying images. A copy of the written consent is available for review by the Editor-in-Chief of this

journal on request.

CRediT authorship contribution statement

RZ developed the conceptualization of the study, was the senior surgeon and contributed to drafting the final manuscript. FV helped in data gathering and final review and editing of the manuscript. AH contributed in literature review and writing of the original manuscript. All authors read and approved the final manuscript.

Declaration of competing interest

All authors declare that there were no competing interests for this study.

Acknowledgements

None.

References

- [1] R. Restrepo, R. Palani, L.F. Cervantes, A.M. Duarte, I. Amjad, N.R. Altman, Hemangiomas revisited: the useful, the unusual and the new. Part 1: overview and clinical and imaging characteristics, *Jul, Pediatr. Radiol.* 41 (7) (2011) 895–904.
- [2] A.K. Larsen, T.E. Damsgaard, L. Hedelund, Classification of vascular anomalies, *Ugeskr. Laeger* 180 (36) (2018). Sep 3.
- [3] P. Redondo, Vascular malformations (I). Concept, classification, pathogenesis and clinical features, *Actas Dermosifiliogr.* 98 (3) (2007) 141–158. Apr.
- [4] D.H. Kim, J.W. Kang, J.W. Park, Multilevel ulnar neuropathy caused by multiple intraneural hemangiomas, *Apr, Muscle Nerve* 41 (4) (2010) 562–566.
- [5] A. Puca, C. Colosimo, B. Tirpakova, L. Lauriola, F. Di Rocco, Cavernous hemangioma extending to extracranial, intracranial, and orbital regions, *Case report. J. Neurosurg.* 101 (6) (2004) 1057–1060. Dec.
- [6] C. Brand, M.T. Pedro, M. Schick, A. Scheuerle, K. Scheglmann, C.R. Wirtz, G. Antoniadis, Intraneural hemangioma of the ulnar nerve, *Feb, Nervenarzt* 86 (2) (2015) 197–201.
- [7] U. Linde, M.R. Gaab, Hemangioma of the ulnar nerve, *Handchir. Mikrochir. Plast. Chir.* 14 (1) (1982) 20–22.
- [8] S. Bacigaluppi, P. Fiaschi, A. Prior, N.L. Bragazzi, P. Merciadri, S. Gennaro, Intraneural haemangioma of peripheral nerves, *Mar, Br. J. Neurosurg.* 14 (2018) 1–7.
- [9] P.J. Papagelopoulos, A.F. Mavrogenis, E. Skarpidi, I. Nikolaou, P.N. Soucasos, A 56-year-old woman with a right arm mass, *Nov, Clin. Orthop. Relat. Res.* 466 (11) (2008) 2892–2898.
- [10] R.A. Agha, T. Franchi, C. Sohrabi, G. Mathew, A. Kerwan, The SCARE 2020 guideline: updating consensus surgical CAse REport (SCARE) guidelines, *Dec, Int. J. Surg.* 84 (2020) 226–230.
- [11] J. Barbour, A. Yee, L.C. Kahn, S.E. Mackinnon, Supercharged end-to-side anterior interosseous to ulnar motor nerve transfer for intrinsic musculature reinnervation, *Oct, J. Hand. Surg. [Am.]* 37 (10) (2012) 2150–2159.
- [12] M. Al-Garnawee, M. Najjar, Median nerve cavernous hemangioma, *Basic Clin Neurosci* 8 (3) (2017) 255–259. May-Jun.
- [13] S. Kwong, L.L. Seeger, K. Motamedi, S.D. Nelson, B. Golshani, Intraneural hemangioma: case report of a rare tibial nerve lesion, *Cureus* 10 (12) (2018), e3784. Dec 27.
- [14] Y. Doğramacı, A. Kalaci, T.T. Sevinç, A.N. Yanat, Intraneural hemangioma of the median nerve: a case report, *J. Brachial Plex Peripher. Nerve Inj.* 22 (3) (2008) 5. Feb.
- [15] N.K. Prasad, A. Chawla, S. Lalezari, G.C. de Ruyter, B.M. Howe, K.K. Amrami, R. J. Spinner, A radiological classification system for intraneural vascular anomalies: assessment of potential for resection with high-resolution MRI, *Feb, Acta Neurochir. (Wien)* 158 (2) (2016) 329–334. discussion 34.
- [16] S. Düzgün, A. Ozdemir, E. Unlü, I. Pekdemir, S. Yilanci, B. Alhan, The intraneural hemangioma of the digital nerve: case report, *Jun, J. Hand. Microsurg.* 5 (1) (2013) 27–29.
- [17] B. Eivazi, M. Ardelean, W. Bäumlner, H.P. Berlien, H. Cremer, R. Elluru, P. Koltai, J. Olofsson, G. Richter, B. Schick, J.A. Werner, Update on hemangiomas and vascular malformations of the head and neck, *Feb, Eur. Arch. Otorhinolaryngol.* 266 (2) (2009) 187–197.
- [18] C.E. Châtillon, M.C. Guiot, L. Jacques, Lipomatous, vascular, and chondromatous benign tumors of the peripheral nerves: representative cases and review of the literature, *Neurosurg. Focus* 22 (6) (2007) E18. Jun 15.