

# Comparison of leakage test and ultrasound imaging to validate ProSeal supraglottic airway device placement

Sachin E. Ajithan, Archana Puri, Mukul C. Kapoor

Department of Anesthesiology, Max Smart Super Speciality Hospital, Saket, Delhi, India

## Abstract

**Background and Aims:** To validate the placement of ProSeal supraglottic airway device using ultrasound (USG) with leakage test in adult population of both sexes.

**Material and Methods:** This single-arm observational study was conducted on 80 American Society of Anesthesiology (ASA) I-III patients, undergoing elective surgery under general anesthesia with ProSeal supraglottic airway device. Leakage pressure test was conducted in all cases. The position of the ProSeal laryngeal mask airway (LMA) was assessed by USG in the pharyngeal, laryngeal, and the cranial-caudal axis plane. The fiberoptic examination was done to confirm the position of ProSeal if the seal pressure was  $<27$  cm H<sub>2</sub>O, to confirm suboptimal placement. The position of the ProSeal in the three USG planes was allocated a predetermined score. This score was compared with the leakage test to determine the strength of the correlation, sensitivity, and specificity for predicting a need for reinsertion.

**Results:** Leakage seal pressure was recorded as  $<27$  cm H<sub>2</sub>O in 6 (7.5%) patients and fiberoptic bronchoscopy was done in these cases to determine the need for reinsertion. ProSeal was reinserted in 5 (6.25%) cases. Patients with a composite ultrasound score of 0–1 required ProSeal reinsertion while those with a score of 2–3 did not require reinsertion. Seventy-one patients had seal pressure  $>27$  cm H<sub>2</sub>O and a score of 3. USG examination is comparable with leakage test in predicting the requirement of reinsertion ( $P = 0.003$ ) and a score of 19 equating 0–1 predicted the need for reinsertion with a sensitivity and specificity of 80% and 100%, respectively.

**Conclusion:** USG is comparable with the leakage test for confirmation of ProSeal placement.

**Keywords:** Cuff pressure, fiberoptic examination, leakage test, ProSeal supraglottic airway device, ultrasound imaging

The development of supraglottic airway devices (SADs) has revolutionized airway management during general anesthesia. The use of SADs is now standard in airway management, and they fill the niche between the face mask and tracheal tube in terms of both airway anatomy and degree of invasion. SADs are easy to insert and do not need a visualization aid for placement but are prone to misplacement and displacement.

High SAD oropharyngeal leakage pressure is required for airway protection during laparoscopic surgery, surgery

on obese patients and in patients with restrictive lung disease.<sup>[1-4]</sup> Inflation of airways at pressures above 20 cm of H<sub>2</sub>O can open the esophageal sphincter causing gastric insufflation, exposing the patient to the risk of pulmonary aspiration of gastric contents.<sup>[5]</sup> If airway sealing is inadequate, the use of SADs is a potential risk, such as cause gastric insufflation, aspiration, inadequate ventilation, and operating room pollution. Anesthetists must thus assess the clinical performance and airway sealing safety of SADs in clinical practice.

**Address for correspondence:** Dr. Mukul C Kapoor,  
Department of Anesthesiology, Max Smart Super Speciality Hospital,  
Saket, Delhi-110 017, India.  
E-mail: mukulanjali@gmail.com

### Access this article online

Quick Response Code:



**Website:**  
www.joacp.org

**DOI:**  
10.4103/joacp.JOACP\_332\_19

This is an open access journal, and articles are distributed under the terms of the Creative Commons Attribution-NonCommercial-ShareAlike 4.0 License, which allows others to remix, tweak, and build upon the work non-commercially, as long as appropriate credit is given and the new creations are licensed under the identical terms.

**For reprints contact:** reprints@medknow.com

**How to cite this article:** Ajithan SE, Puri A, Kapoor MC. Comparison of leakage test and ultrasound imaging to validate ProSeal supraglottic airway device placement. J Anaesthesiol Clin Pharmacol 2020;36:227-32.

**Submitted:** 08-Oct-2019 **Revised:** 01-Mar-2020 **Accepted:** 06-Mar-2020  
**Published:** 15-Jun-2020

The leakage test is usually used to judge proper SAD placement, but it may not recognize improper deployment early, especially in protracted cases. Direct visualization by a bronchoscope is considered the preferred validation tool.<sup>[6,7]</sup> However, regular bronchoscope use to confirm SAD placement is restricted as it is invasive, requires tedious sterilization, and is expensive.<sup>[7]</sup> Ultrasound (USG) based machines are now portable and relatively inexpensive, making them commonly available in operating rooms for regional anesthesia. These machines can be used to assess the airway of the patient and the position of the endotracheal tube and SAD.<sup>[8-12]</sup>

Our primary study objective was to determine if USG examination was comparable with conventional leakage test to determine proper ProSeal SAD (Teleflex Medical, Westmeath, Ireland) placement. The secondary study objectives were to determine if fiberoptic examination is required in addition to reinsert the SAD when leak test is positive; to determine the USG score for reinsertion; and to determine the time duration required to conduct the tests to confirm ProSeal SAD placement.

## Material and Methods

A single-arm observational study was conducted on 80 adult patients undergoing surgery under general anesthesia, after approval of the institutional scientific and ethics committee. The study was approved by the Institutional Ethics Committee. The inclusion criteria were adult patients, in the American Society of Anesthesiologists (ASA) functional class I-III, scheduled for elective surgery under general anesthesia using SAD. Exclusion criteria were patients with anticipated difficult airway; restrictive/obstructive pulmonary disease; previous thoracic surgeries; pregnancy; body mass index (BMI) >30; and patients at risk of gastric aspiration.

The sample size was calculated to be 68 with a margin of 10% on either side, a 95% confidence limit and power of 80% based on the study by Song *et al.* who studied the confirmation of laryngeal mask airway (LMA) placement by USG.<sup>[13]</sup> We recruited 80 cases to cater for possible dropouts.

A routine pre-anesthetic evaluation was done and the airway classified using the Mallampati grading. All patients were kept fasting for at least 6 hours. All patients were administered general anesthesia using a standardized protocol for induction and maintenance of anesthesia. The induction sequence included intravenous fentanyl (1–2 mcg/kg) and propofol (1.5–2 mg/kg). Atracurium (0.5 mg/kg) was administered for neuromuscular blockade. The airway was

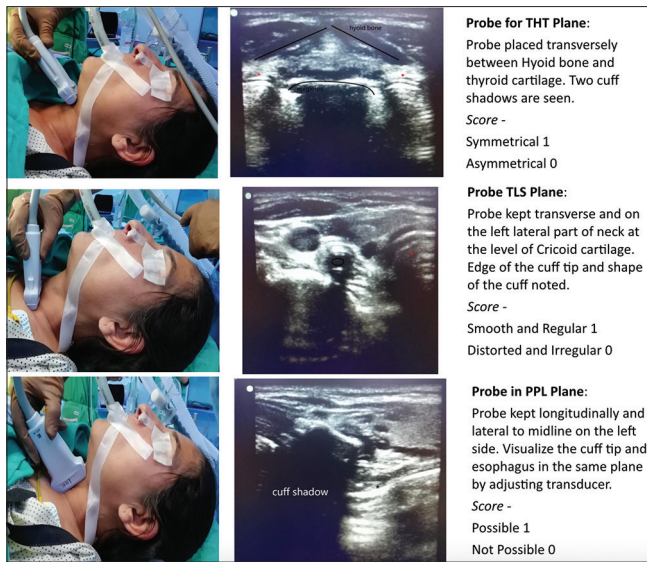secured with a ProSeal SAD (size based on patient weight as recommended by the manufacturer). All ProSeal SAD insertions were performed by a single investigator (SEA) using standard described insertion procedure after achieving neuromuscular blockade. A maximum of two attempts was permitted for successful placement. The SAD cuff was inflated with maximum volume for size (#3–20 ml, #4–30 ml, and #5–40 ml) as recommended by the manufacturer. The ProSeal SAD position was assessed by observing airway pressure; chest movement with manual ventilation; reservoir bag refill during expiration; auscultation; and capnography.

The SAD was evaluated by leakage tests in all cases and the leakage pressure recorded. The airway leakage pressure was defined as the pressure beyond, which graded closure of the adjustable pressure limiting valve, with the fresh gas flowing and without manual compression of the reservoir bag, did not result in a rise in airway pressure. A maximum of 40 cm H<sub>2</sub>O of airway pressure was permitted during the leakage test.

Anesthesia was maintained with desflurane in oxygen, and nitrous oxide titrated to maintain FiO<sub>2</sub> of 0.5 at all times. Volume control ventilation was delivered with the tidal volume set at 8 ml/kg, to maintain minute ventilation of 100 ml/kg and an end-tidal carbon dioxide (EtCO<sub>2</sub>) between 30–40 mm Hg.

USG examination of the neck was done using a Sonosite USG machine with a 13-6 MHz transducer (Sonosite M Turbo with HFX36 × Transducer, Fujifilm SonoSite Inc., Bothell, WA). All imaging was done by a senior anesthesiologist (AP) proficient in USG use and had performed at least 10 airway USG. Imaging was done in three planes and USG score assigned to the placement view using a modification of the criteria proposed by Song *et al.*<sup>[13]</sup> [Figure 1]. The scoring system used and the calculation of composite scores are displayed in Table 1.

1. The transverse plane between the hyoid bone and thyroid bone (THT). Probe for THT Plane: Probe was placed transversely between hyoid bone and thyroid cartilage and two cuff shadows are seen in this view. Score - Symmetrical 1; Asymmetrical 0
2. Transverse plane of the lateral suprasternal notch (TLS): Probe for TLS Plane was placed transversely in the left lateral part of the neck at the level of the cricoid cartilage. Edge of the cuff tip and the shape of the cuff were assessed. Score - Smooth and Regular 1; Distorted and Irregular - 0
3. Parasagittal plane of pharynx and larynx (PPL): Probe was kept longitudinally and lateral to the midline on the left side to visualize the cuff tip and esophagus in the same plane by adjusting transducer. Score - Possible 1; Not Possible 0.



**Figure 1:** Figure showing the three planes in which ultrasound airway examination was done with the image viewed and the score allowed to different views

**Table 1: Scoring in the three planes on ultrasound examination and the distribution of patients based on the composite ultrasound score**

	View Seen	Score	n	Percentage
THT n=80	Assymetrical	0	7	8.8%
	Symmetrical	1	73	91.3%
TLS n=80	Distorted	0	6	7.5%
	Smooth/regular	1	74	92.5%
PPL n=80	Impossible	0	6	7.5%
	Possible	1	74	92.5%
Composite USG Score n=80		0	4	5.0%
		1	1	1.3%
		2	3	3.8%
		3	72	90.0%

THT=Transverse plane between hyoid bone and thyroid bone; TLS=Transverse plane of lateral suprasternal notch; PPL=Parasagittal plane of pharynx and larynx; USG=Ultrasonography

The bronchoscopy examination was done through ProSeal SAD to confirm the position of ProSeal LMA if the leakage pressure was below 27 cm H<sub>2</sub>O. The fiberoptic bronchoscope (FOB) (Olympus BF Type TE2, Olympus Medical Systems, Tokyo, Japan) was positioned just proximal to the end of the ventilator conduit and then advanced under the epiglottis to see the vocal cords. Timmerman classified the FOB view as either optimal or suboptimal, and we followed the same classification.<sup>[14]</sup> The ProSeal placement was considered optimal if its tip was lying behind the arytenoids; the epiglottis was visible; no folding or intrusion into the airway was seen; and if the vocal cords were visible when the fiberscope was advanced under the epiglottis. All other situations were considered suboptimal.

The time required for leakage tests, USG, and fiberoptic examination were noted. The data points for recording time were as follows:

- For leakage test: Start - on setting up the O<sub>2</sub> flow and Stop - 10 sec after manometric stabilization
- For USG examination: Start - after setting up a machine with the probe in hand and Stop - after completion of USG neck examination in all three planes
- For FOB examination: Start - after setting up the bronchoscopy machine and white balance of the scope and Stop - after the withdrawal of the FOB from the ProSeal.

Statistical analysis of the data was done by Student's 't' test and Spearman rank correlation test using Statistical Package for Social Science (SPSS) software version 20.0. The Spearman rank correlation test was used to analyze the correlations between the USG examination and the leakage test and a *P* value <0.05 was considered statistically significant.

## Results

A total of 80 adult patients, 39 males and 41 females, were recruited and studied. The age of the patients studied ranged from 18 to 64 years, with a mean of 36.65 ± 12.38 years, and the mean weight was 57.98 ± 8.01 kg. The airway of 30% of patients was graded as Mallampati class I, 62.5% class II, and 7.5% class III. ProSeal SAD size 3 was used in 23.8% patients and size 4 in 76.3%. Leakage test was done in all cases, and seal pressure noted. Mean seal pressure was 28.34 ± 2.84 cm H<sub>2</sub>O with a range from 14 to 32 cm H<sub>2</sub>O. The seal pressure <27 cm H<sub>2</sub>O was seen in 6 (7.5%) patients while it was >27 cm H<sub>2</sub>O in 74 (92.5%) cases.

Ultrasound examination in the THT plane revealed symmetrical placement in 91.3% cases, and it was asymmetrical placement in the balance of 8.8%. In the TLS plane, 92.5% had smooth shadows and 7.5% of cases had distorted shadows. In the PPL plane, it was possible to visualize the cuff tip and esophagus in the same plane by adjusting the transducer in 93.8% of cases and was impossible to visualize in 6.2% cases. In total, 90% of the cases scored the maximum composite score of 3 on USG scanning in the three planes [Table 1].

The fiberoptic examination was needed in only 6 of the 80 cases where leakage pressure was less than 27 cm of H<sub>2</sub>O. The fiberoptic examination showed a suboptimal view in 5 five of these 6 patients and ProSeal was reinserted in them. The view was found optimal in 1 patient [Figure 2]. The composite USG score was 0-1 in all the 5 cases where ProSeal was reinserted.



The mean time taken for leak test was  $47.54 \pm 1.86$  sec (range 42–51 sec) and for USG examination was  $198.9 \pm 162.672$  sec (range 120–190 sec), which was significantly longer.

The Spearman coefficient of rank correlation between the leakage test and ultrasound examination showed a statistically significant correlation between the two (correlation coefficient = 0.329 and  $P = 0.003$ ) [Table 2 and Figure 3]. When statistical sensitivity and specificity of composite USG score were calculated with respect to reinsertion for true positives and true negatives, its sensitivity was 4/5, i.e., 80% and specificity was 1/1, i.e., 100%. When statistical sensitivity and specificity of leakage tests were calculated with respect to reinsertion for true positives and true negatives, its sensitivity was 1/5, i.e., 20% but the specificity was 1/1, i.e., 100%.

## Discussion

Achieving a leak-free breathing system is the goal for SAD placement, to optimize breathing and anesthetic gas delivery to the lungs and prevent the risk of aspiration. A good seal facilitates effective pulmonary ventilation, maintenance of the desired anesthetic gas concentrations at lower fresh gas flows, and prevents pollution of the operating room environment by expelled leaked gases.<sup>[1]</sup> Restricting breathing gas entry into the esophagus prevents the rise of intragastric pressure and reduces regurgitation risk. The arithmetic of a good seal for complete airway protection is not defined except that the seal pressure should be more than the airway pressure. However, evidence of complete protection of the airway, from blood and secretions, using this as seal criteria is limited.

The correct placement of a SAD requires confirmation of adequate laryngeal seal and assurance of pulmonary ventilation. In a well-placed SAD, the cuff tip lies at the base

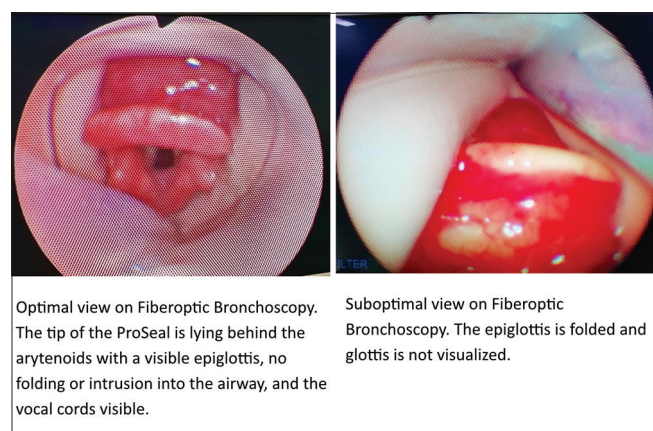
of the hypopharynx, the sides of the cuff lie in the pyriform fossae, and the superior border of the mask lies at the base of the tongue.<sup>[15]</sup> Clinical criteria may not reflect the exact anatomic placement of SAD, although they assess the airway sealing pressure and have been labeled as good indices of successful lung ventilation.<sup>[16]</sup> Direct guidance of confirmation tools helps detect SAD malposition and prevent a potential adverse event.

The second-generation SAD have high airway seal pressure and have an esophageal drainage tube to preventive gastric aspiration. Various methods described to assess SAD placement include auscultation; leak test; soap-bubble test; suprasternal notch tap test; gel displacement test; thread test; and self-inflating bulb technique.<sup>[17-19]</sup> On correct placement, ProSeal should make a good seal in the laryngopharynx for adequate ventilation. Seal pressure measurement, invasive bronchoscopic visualization, and USG neck examination can confirm the seal.

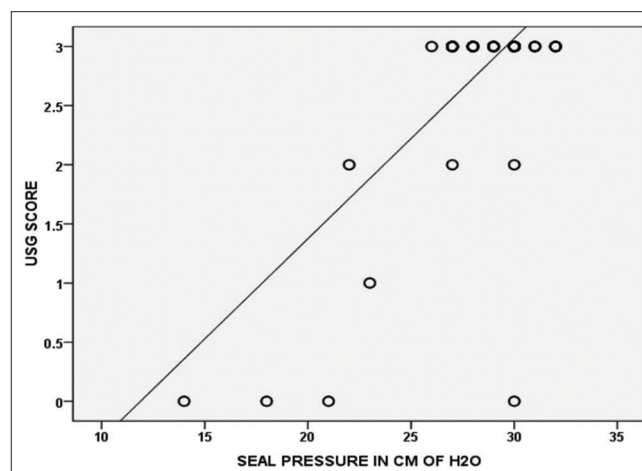
The use of USG in anesthesia is immense today. The adoption of USG for airway examination is, however, limited because of poor propagation and attenuation of USG waves while traversing the hyoid bone and the air column in the laryngopharynx. USG reflections at the air-mucosa

**Table 2: Spearman's Rank Correlation (rho) analysis of Ultrasound score and seal pressure by leakage test**

	Seal Pressure	Composite USG score		
Spearman's rho	Seal Pressure	Correlation Coefficient	1.000	0.329
		<i>P</i>	-	0.003
		<i>n</i>	80	80
Composite USG Score	Composite USG Score	Correlation Coefficient	0.329	1.000
		<i>P</i>	0.003	-
		<i>n</i>	80	80



**Figure 2:** The view of the larynx on fiberoptic examination through the ProSeal showing the optimal and suboptimal views



**Figure 3:** Spearman's Rank Correlation (rho) analysis of Ultrasound score and seal pressure by leakage test

border also create acoustic shadowing and artifacts. Several recent publications have found the use of USG to be a promising technique for visualization of the upper airway.<sup>[9,20]</sup> However, for confirming the position of ProSeal LMA, all that is required are views that can show surrounding structures, which can detect the tip of the cuff to confirm its correct orientation and contact with the larynx. With USG imaging one can rapidly visualize the tongue, epiglottis, and esophagus, making it a highly sensitive tool to determine the positioning of SAD.<sup>[15]</sup> The nasogastric tube inserted is seen as a “dual-track sign” between the cuff tip and the esophagus on USG imaging.<sup>[13]</sup>

We performed the leakage test and USG in all cases. Kundra *et al.* classified the leakage test into four grades based on leakage test and adequacy of ventilation.<sup>[21]</sup> Based on the work of Cook and Gibbison, who reported the average ProSeal seal pressures to be 28–32 cm H<sub>2</sub>O, we considered seal pressure below 27 cm H<sub>2</sub>O as an inadequate seal.<sup>[22]</sup> The mean oropharyngeal seal pressure in our study was  $28.34 \pm 2.83$  cm H<sub>2</sub>O.

FOB grading of SAD placement is considered ‘gold standard’. However, FOB suffers from the disadvantage of long set-up time (including time for ‘white balance’) as compared to a USG machine; being expensive; and discontinuation of ventilation during its use. Of the 80 cases studied, we needed FOB verification in six cases. Five of these patients had suboptimal placement view and needed ProSeal reinsertion. The FOB also needs to be sterilized after every use, which is not only tedious but also has economic implications.

At the laryngeal level, the tip of the cuff and its spatial relationship with the proximal esophagus was noted in the TLS plane. Trachea lies directly anterior to the esophagus at this level, so a left lateral approach is required to image the esophagus. Esophagus, with the nasogastric tube *in situ*, was noted in the TLS plane.

At the pharyngeal level, rotation of the LMA could be detected easily by noting asymmetrical cuff shadows in the THT plane. Severe rotation of the LMA would cause one of the cuff shadows to be much smaller and deeper than the other. We found that, in male patients with prominent ‘Adam’s apple,’ it was difficult to get the THT plane view as it was difficult to place the probe, which may be considered as a limitation of USG airway examination.

The ProSeal could be fully visualized in the images that were acquired in the PPL plane, and a smooth, regular cuff profile indicates optimal placement. It was possible to visualize the cuff tip and esophagus in the same plane in 92.5% subjects in

our study. The inability to pass a suction tube should arouse suspicion of ProSeal misplacement, but the ability to pass it is not confirmatory of optimal placement.

Song *et al.* found that the USG score predicted the need for reinsertion with a sensitivity and specificity of 85.7% and 94.1%, respectively. We found the composite USG score sensitivity and specificity for reinsertion to be 80% and 100%. The composite USG score and seal pressure by leakage test statistically correlated very significantly.

We took a significantly longer time to determine the USG score vis-a-vis the leakage test. We took more time to conduct the USG examination for the initial cases, but as we got accustomed to the conducting airway USG examination, we took lesser time. The extensive time range required for conducting the USG examination reflects this learning curve.<sup>[23]</sup>

The limitations of our study are that USG examination is subjective, and so observer bias is inevitable. To overcome observer bias, two consultants with expertise in using USG imaging practiced airway USG before we enrolled subjects for the study.

To conclude, we compared USG airway examination with conventional leakage test to determine proper placement of ProSeal SAD and found that a USG score of 0-1 is indicative of requirement for ProSeal reinsertion. The USG score was statistically highly sensitive and specific to determine the reinsertion of the SAD as compared to the seal pressure, which was highly specific but inadequately sensitive. USG score is a useful tool to validate SAD placement.

### Financial support and sponsorship

Nil.

### Conflicts of interest

There are no conflicts of interest.

### References

1. Goyal R. Small is the new big: An overview of newer supraglottic airways for children. *J Anaesthesiol Clin Pharmacol* 2015;31:440-9.
2. Sharma B, Sood J, Sahai C, Kumar VP. Efficacy and Safety Performance of ProSeal™ laryngeal mask airway in laparoscopic surgery: Experience of 1000 cases. *Indian J Anaesth* 2008;52:288-96.
3. Sharma B, Sehgal R, Sahai C, Sood J. PLMA vs. I-gel: A comparative evaluation of respiratory mechanics in laparoscopic cholecystectomy. *J Anaesthesiol Clin Pharmacol* 2010;26:451-7.
4. Shin HW, Yoo HN, Bae GE, Chang JC. Comparison of oropharyngeal leak pressure and clinical performance of LMA ProSeal and i-gel<sup>®</sup> in adults: Meta-analysis and systematic review. *J Int Med Res* 2016;44:405-18.
5. Barker J, Langton JA, Murphy PJ, Rowbotham DJ. Regurgitation of gastric contents during general anaesthesia using the laryngeal

- mask airway. *Br J Anaesth* 1992;69:314-5.
6. Schmidbauer W, Bercker S, Volk T, Bogusch G, Mager G, Kerner T. Oesophageal seal of the novel supralaryngeal airway device I-Gel in comparison with the laryngeal mask airways classic and ProSeal using a cadaver model. *Br J Anaesth* 2009;102:135-9.
7. Campbell RL, Biddle C, Assudmi N, Campbell JR, Hotchkiss M. Fiberoptic assessment of laryngeal mask airway placement: Blind insertion versus direct visual epiglottoscopy. *J Oral Maxillofac Surg* 2004;62:1108-13.
8. Bolyard EA, Tablan OC, Williams WW, Pearson ML, Shapiro CN, Deitchmann SD. Guideline for infection control in health care personnel, 1998. Hospital Infection Control Practices Advisory Committee. *Infect Control Hosp Epidemiol* 1998;19:407-63.
9. Sustic A. Role of ultrasound in the airway management of critically ill patients. *Crit Care Med* 2007;35:S173-7.
10. Prasad A, Singh M, Chan VW. Ultrasound imaging of the airway. *Can J Anaesth* 2009;56:868-9.
11. Singh M, Chin KJ, Chan VW, Wong DT, Prasad GA, Yu E. Use of sonography for airway assessment: An observational study. *J Ultrasound Med* 2010;29:79-85.
12. Gupta D, Srirajakalidindi A, Habli N, Haber H. Ultrasound confirmation of laryngeal mask airway placement correlates with fiberoptic laryngoscope findings. *Middle East J Anaesthesiol* 2011;21:283-7.
13. Song K, Yi J, Liu W, Huang S, Huang Y. Confirmation of laryngeal mask airway placement by ultrasound examination: A pilot study. *J Clin Anaesth* 2016;34:638-46.
14. Timmermann A, Cremer S, Eich C, Kazmaier S, Brauer A, Graf BM, *et al.* Prospective clinical and fiberoptic evaluation of the Supreme laryngeal mask airway. *Anesthesiology* 2009;110:262-5.
15. Zhou ZF, Xia CZ, Wu M, Yu LN, Yan GZ, Ren QS, *et al.* Comparison of three methods for confirmation of laryngeal mask airway placement in female patients undergoing gynecologic surgery. *Ultrasound Med Biol* 2015;41:1212-20.
16. Keller C, Brimacombe J, Keller K, Morris R. A comparison of four methods for assessing airway sealing pressure with the laryngeal mask airway in adult patients. *Br J Anaesth* 1999;82:286-7.
17. Sharma B, Sood J, Sahai C, Kumra VP. Troubleshooting ProSeal LMA. *Indian J Anaesth* 2009;53:414-24.
18. O'Connor CJ Jr, Borromeo CJ, Stix MS. Assessing ProSeal laryngeal mask positioning: The suprasternal notch test. *Anesth Analg* 2002;94:1374-5.
19. Patil PC, Chikkapillappa MA, Pujara VS, Anandswamy TC, Parate LH, Bevinaguddaiah Y. ProSeal laryngeal mask airway placement: A comparison of blind versus direct laryngoscopic insertion techniques. *Anesth Essays Res* 2017;11:380-4.
20. Kristensen MS. Ultrasonography in the management of the airway. *Acta Anaesthesiol Scand* 2011;55:1155-73.
21. Kundra P, Deepak R, Ravishankar M. Laryngeal mask insertion in children: A rational approach. *Paediatr Anaesth* 2003;13:685-90.
22. Cook TM, Gibbison B. Analysis of 1000 consecutive uses of the ProSeal laryngeal mask Airway™ by one anaesthetist at a district general hospitals. *Br J Anaesth* 2007;99:436-9.
23. Osman A, Sum KM. Role of upper airway ultrasound in airway management. *J Intensive Care* 2016;4:52.