

Paraneoplastic edematous dermatomyositis: A rare syndrome observed in a case of small cell lung cancer

Kevin Zarrabi,¹ Terence Choy,¹
Keith Sweeney,² Ved Desai,¹
Roger Keresztes¹

¹Department of Medicine, Stony Brook
University Hospital; ²Department of
Pathology, Stony Brook University
Hospital, Stony Brook, NY, USA

Abstract

Dermatomyositis with subcutaneous edema is a rare process with few reported cases. We report a 63-year-old with lung cancer who presented with an erythematous skin rash and was found to have biopsy-proven dermatomyositis. Her course was complicated by generalized edema, myalgias, muscle weakness, dysphagia, and laryngeal edema. The edema was severe and caused respiratory distress requiring intubation. The patient underwent therapy with high-dose glucocorticoids and intravenous immunoglobulin but failed treatment. Altogether, she presented as an extreme case and rare variant of dermatomyositis, known as edematous dermatomyositis. Diagnostic and treatment guidelines do not account for this variant and literature pertaining to edematous dermatomyositis is sparse. Moreover, this disease was a paraneoplastic manifestation of her small cell lung cancer, which is rarely observed. There are no cases reporting edematous dermatomyositis as a paraneoplastic manifestation of small cell lung cancer, and we highlight the high rate of morbidity and mortality in such patients.

Introduction

Dermatomyositis (DM) is an idiopathic inflammatory myopathy, which presents with varying degrees of muscle weakness in addition to a characteristic rash. Classically, patients exhibit a heliotrope eruption, gottron's papules, in addition to an erythematous rash in the sun-exposed areas of the anterior chest, neck, and shoulders. The underlying pathophysiology of the rash and myopathy entails activation of complement protein leading to lysis of endomysial capillaries. The resulting microangiopathy is severe enough to lead to skin and muscle ischemia.

Although muscle weakness and inflammation are hallmarks of the DM syndrome, the disease process can be more dramatic. To this end, a rare manifestation of DM can include development of florid subcutaneous edema. Patients with this severe variant of the disease have been identified by the medical community as having *edematous dermatomyositis* (EDM). Although there are an estimated 21.4 cases of DM per 100,000 persons per year, EDM is a rare entity with a mere 23 cases reported in the literature to date.^{1,2}

There exists a well-established link between DM and malignancy with original reports dating back as early as 1916. Recent cohort studies reveal an underlying malignancy in approximately 24% of cases of DM.³ Further studies from multinational cohorts suggest that even in cases where there is no underlying malignancy, the relative risk of developing malignancy within one year of DM onset is nearly six-fold and remains elevated for up to five years.^{2,4} This has led some clinicians to describe DM as a *prodrome* to cancer. Most observed cases of paraneoplastic DM are due to underlying adenocarcinoma of the ovary, lung, and gastrointestinal tract.³ Small cell lung cancer (SCLC) is not commonly associated with DM as there are only 14 reported cases since 1947.⁵ However, none of the reported cases described EDM. In this report, we present a 63-year-old female with a unique and rare case of EDM as a paraneoplastic manifestation of SCLC.

Case Report

A 63-year-old woman with biopsy-confirmed SCLC metastatic to the liver developed rash and lesions to the face, chest, back, and oral mucosa that coincided with initiating topotecan therapy (Figure 1A and B). A physical examination revealed erythematous edematous plaques with central tense bullae and crusting on the forehead, posterior auricular region, and chest. Multiple bullae drained serosanguinous fluid, Nikolsky's sign was absent, and multiple ulcers were found within the oral mucosa.

A skin biopsy revealed dermatitis that was initially suspected to be due to a drug reaction. However, her symptoms worsened despite oral prednisone therapy and discontinuation of topotecan. One week after rash onset, she developed angioedema, generalized weakness, and myalgia most prominent in her proximal extremities. The patient also reported difficulty transferring from her bed or lifting her upper extremities. Laboratory findings revealed abnormal levels of: crea-

Correspondence: Kevin Zarrabi, Department of Internal Medicine, Health Science Center T16, Room 020, Stony Brook, NY 11790-8160, USA.

Tel.: +1.(631).444.7411 -

Fax: +1.(631).444.2493.

E-mail: kevin.zarrabi@stonybrookmedicine.edu

Key words: Edematous dermatomyositis; paraneoplastic; small cell lung cancer.

Acknowledgments: there are no acknowledgments for this case report.

Contributions: the authors contributed equally.

Conflict of interest: the authors declare no potential conflict of interest.

Received for publication: 25 May 2017.

Accepted for publication: 12 October 2017.

This work is licensed under a Creative Commons Attribution NonCommercial 4.0 License (CC BY-NC 4.0).

©Copyright K. Zarrabi et al., 2017

Licensee PAGEPress, Italy

Clinics and Practice 2017; 7:982

doi:10.4081/cp.2017.982

tine phosphokinase (CPK) 25,865 IU/L (normal range 26-174), aldolase 40.3 U/L, sodium 125 mmol/L (normal range 135-146), chloride 71 mmol/L (normal range 96-107), bicarbonate 17 mmol/L (normal range 21-31), lactic acid 7.1 mmol/L (normal range 0.5-22), aspartate transaminase (AST) 878 IU/L (normal range 0-32), alanine transaminase (ALT) 312 IU/L (normal range 10-35), white blood cells 15.45 K/uL (normal 4.8-10.8). Urine analysis found large blood on dipstick and <1 red blood cell per high-powered field.

Bedside sonogram showed trace pericardial effusion and grossly preserved cardiac contractility. Magnetic resonance imaging of her neck revealed soft tissue thickening and diffuse heterogeneous enhancement of muscles. Histopathologic examination of her left bicep muscle showed strongly-positive HLA Class I immunohistochemistry without myofiber necrosis and mild-to-moderate type 2 myofiber atrophy (Figure 2A and B). Antinuclear antibody titer was positive at a 1:640 dilution with a speckled pattern. Anti-p155/140 antibody was positive. The remainder of the myositis antibody comprehensive panel, extractable nuclear antigen screening (anti-ENA), and paraneoplastic autoantibody panel were negative (anti-Jo-1, anti-SSA 52, anti-SSA 60, anti-Mi-2, anti-PL-7, anti-PL-12, anti-EJ, anti-Ku, anti-U2 sn RNP, anti-SRP, anti-OJ, anti

PM/Scl complex, anti-neuronal nuclear antibody types 1, 2, and 3; anti-glial nuclear antibody, anti-PCA-1, anti-PCA2, anti-PCA-Tr, anti-Amphiphysin, anti-CRMP-5, anti-striational, anti-P/Q-type calcium channel, anti-N-type calcium channel, anti-Ach receptor binding antibody, anti-ACHr Ganglionic neuronal antibody).

The patient was initially treated with intravenous fluids and oral prednisone. She was then advanced to intravenous methylprednisolone and intravenous immunoglobulin therapy, resulting in a gradual decline of the CPK level to less than 1300 IU/L and improvement of her rash and erythematous plaques. During this time, she had progressive dysphagia, odynophagia, and oral thrush concerning for esophageal candidiasis. Despite treatment with oral nystatin rinses, which resolved her oral thrush, the patient continued to have worsening symptoms of dysphagia. Videocopy revealed acutely-worsening dysphagia and CT-imaging demonstrated laryngeal edema. She was intubated to protect her airway, started on plasmapheresis, and fed through a nasogastric tube. Although the CPK level declined to less than 1000 IU/L, her edema and weakness persisted. Thereafter, the patient was transferred to hospice care and comfort measures were implemented.

pathognomonic cutaneous manifestations. The Bohan and Peter criteria for the diagnosis of DM were consequently developed and are widely used as a diagnostic tool for this multifaceted disease. Missing from these criteria, however, is mention of diffuse generalized edema or anasarca as was observed in this patient. Widespread subcutaneous edema, as part of the dermatomyositis syndrome, was first reported in 1988. It has since been further characterized and accepted as rare and severe variant of DM.⁶ We report a case of biopsy-proven DM associated with subcutaneous edema so severe that the patient required intubation and tracheotomy secondary to angioedema and laryngeal edema. Case analyses by Tu *et al.* suggest a poor prognosis and higher morbidity and mortality amongst patients who present with diffuse subcutaneous edema as a manifestation of DM.⁶ In a 2007 study, Dunkley and colleagues suggested up

to a five-fold increase in the rate of mortality when edema is a feature of the disease.⁷ This patient's observed angioedema and laryngeal edema were consistent with symptomatology reported in previous cases of EDM requiring intubation.⁶ The prolonged hospital course involving ICU level of care experienced by this patient is further evidence that EDM should be considered as a more severe form of DM, in which early and aggressive intervention may be beneficial. In support of the growing number of cases of EDM, efforts are underway to elucidate the underlying mechanism behind this dramatic third spacing. Recent hypotheses as to the causative process include elevated VEGF expression,⁸ increased vascular permeability in an inflammatory state,⁹ and elevated serum type I interferon.⁶ However, none of these hypotheses have sufficient data delineating differences in the underlying pathogenesis that would distin-

Discussion

Dermatomyositis is a systemic inflammatory myopathy involving the skin, muscle, and connective tissue. DM is similar to polymyositis as they are both idiopathic inflammatory conditions; however, DM differs from polymyositis in that it exhibits

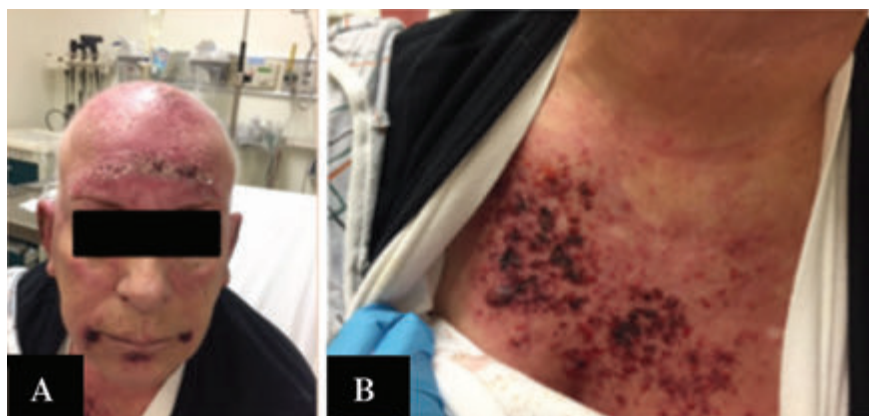

Figure 1. Images of the patient's skin rash and crusting lesions; A) periorbital edema and forehead skin breakdown; B) characteristic anterior chest wall (V sign) rash.

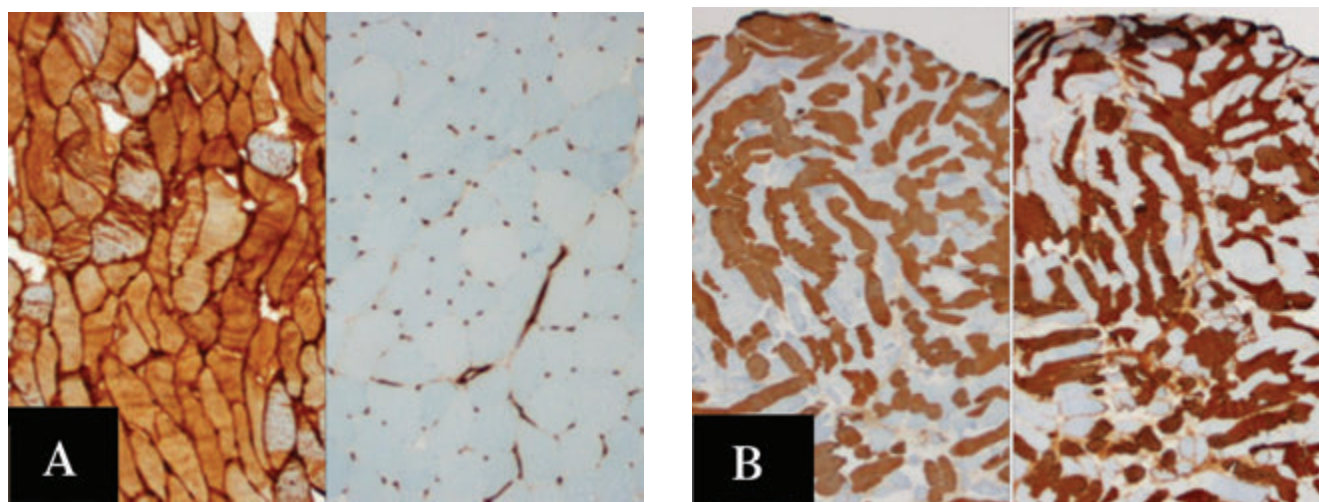


Figure 2. A) Strongly positive HLA class I immunohistochemistry (left), normal control (right) (100× magnification); B) myosin heavy chain I (left) and II (right) immunohistochemical stains show mild type 2 myofiber atrophy (right) (40× magnification).

guish DM from EDM.

In this report, we bring attention to a rare process whereby DM presents alongside florid generalized edema. Aside from the edematous process, this patient's presentation and disease is also extraordinary in that her paraneoplastic syndrome was associated with SCLC, which is an unusual event in itself. The association between DM and SCLC is infrequently observed with few reported cases.⁵

Interestingly, treatment of myositis associated with malignancy follows a paradigm whereby successful treatment of the tumor improves the myositis. This parallel between DM resolution and malignancy treatment is suggestive of a paraneoplastic phenomenon.³ Biopsy from this patient's lesion yielded positivity for anti-p155/140 antibody, an antinuclear autoantibody strongly associated with cancer-associated DM with a specificity of 95.9%.¹⁰ Objective findings (elevated CPK, biopsy results), together with the patient's severe presentation, were highly convincing of paraneoplastic DM, despite the rarity of such an event in a patient with SCLC. As such, the patient underwent aggressive treatment, including intravenous steroids, plasmapheresis, and IVIG. In concordance with previous reports on the poor prognosis of DM-associated SCLC,⁵ the patient passed away within two months of presentation despite aggressive treatment efforts.

Conclusions

In conclusion, florid subcutaneous edema is a severe presentation and variant of DM, and such cases carry a high rate of morbidity and mortality. We report a case of EDM in which the patient experienced respiratory distress secondary to laryngeal edema, required intubation, and failed conventional treatment. In summary, this case highlights EDM as a paraneoplastic manifestation of SCLC with no reported cases to date of these two rare processes occurring simultaneously in one patient.

References

- Jacobson DL, Gange SJ, Rose NR, Graham NM. Epidemiology and estimated population burden of selected autoimmune diseases in the United States. *Clin Immunol Immunopathol* 1997;84:223-43.
- Goussot R, Wettlé C, Le Coz C, et al. [Severe edematous dermatomyositis]. *Ann Dermatol Venereol* 2016;143:202-9. [Article in French]
- Zahr ZA, Baer AN. Malignancy in myositis. *Curr Rheumatol Rep* 2011;13:208-15.
- Chow WH, Gridley G, Mellekjaer L, et al. Cancer risk following polymyositis and dermatomyositis: a nationwide cohort study in Denmark. *Cancer Causes Control* 1995;6:9-13.
- Lee WY, Kastelik J, Campbell A, et al. A case report of dermatomyositis associated with small cell lung cancer. *Tumori* 2012;98:158e-61e.
- Tu J, McLean-Tooke A, Junckerstorff R. Increasing recognition of dermatomyositis with subcutaneous edema - is this a poorer prognostic marker? *Dermatol Online J* 2014;20:21244.
- Dunkley LJA. Subcutaneous oedema as a presenting feature of polymyositis/dermatomyositis: a poor prognostic indicator? *Grand Rounds* 2007;7:21-5.
- Ito Y, Kawabata D, Yukawa N, et al. Severe subcutaneous generalized edema in a patient with dermatomyositis. *Mod Rheumatol* 2007;17:171-3.
- Somani AK, Swick AR, Cooper KD, McCormick TS. Severe dermatomyositis triggered by interferon beta-1a therapy and associated with enhanced type I interferon signaling. *Arch Dermatol* 2008;144:1341-9.
- Targoff IN, Mamyrova G, Trieu EP, et al. A novel autoantibody to a 155-kd protein is associated with dermatomyositis. *Arthritis Rheum* 2006;54:3682-9.