

# The Effective Treatment with Cyclosporine of a Ulcerative Colitis Patient with Concurrent Idiopathic Thrombocytopenic Purpura Who Subsequently Developed Spontaneous Pneumomediastinum

Tsutomu Iwasa, Kazuhiko Nakamura, Eikichi Ihara, Akira Aso and Tetsuhide Ito

---

## Abstract

---

Although extraintestinal manifestations of inflammatory bowel diseases are not uncommon, few reports have described concurrent idiopathic thrombocytopenic purpura (ITP). Spontaneous pneumomediastinum is also a rare complication of ulcerative colitis (UC). This report describes the case of a 14-year-old boy who experienced recurrent ulcerative colitis 3 months after temporary improvement following treatment with prednisolone (20 mg/day) and granulocyte/monocyte adsorption apheresis. His platelet counts decreased, suggesting ITP. The dosage of prednisolone was increased to 60 mg/day; however, his thrombocytopenia did not improve and he suddenly developed pneumomediastinum. A continuous infusion of cyclosporine increased his platelet counts and improved his ulcerative colitis. Cyclosporine should be considered when steroid-resistant ITP accompanies UC.

**Key words:** cyclosporine, ulcerative colitis, extraintestinal manifestation, idiopathic thrombocytopenic purpura, spontaneous pneumomediastinum

(Intern Med 56: 1331-1337, 2017)

(DOI: 10.2169/internalmedicine.56.7909)

---

## Introduction

---

Inflammatory bowel diseases (IBD), such as ulcerative colitis (UC) and Crohn's disease (CD), are characterized by chronic relapsing inflammation of the gastrointestinal tract; their precise etiology remains obscure. IBDs have also been associated with extraintestinal manifestations, including musculoskeletal diseases (e.g., peripheral arthritis), mucocutaneous diseases (e.g., erythema nodosum), hepatobiliary diseases (e.g., primary sclerosing cholangitis), blood and vascular diseases (e.g., autoimmune hemolytic anemia), and bronchopulmonary diseases (1-3). However, idiopathic thrombocytopenic purpura (ITP) is a rare extraintestinal manifestation in patients with UC. In addition, there are few reports of spontaneous pneumomediastinum as a complication of UC. There are currently no recommended treatments for ITP with UC, and the effectiveness of cyclosporine has not been determined. This report describes a patient with

UC who developed ITP, followed by spontaneous pneumomediastinum. Cyclosporine was effective in treating both UC and ITP.

---

## Case Report

---

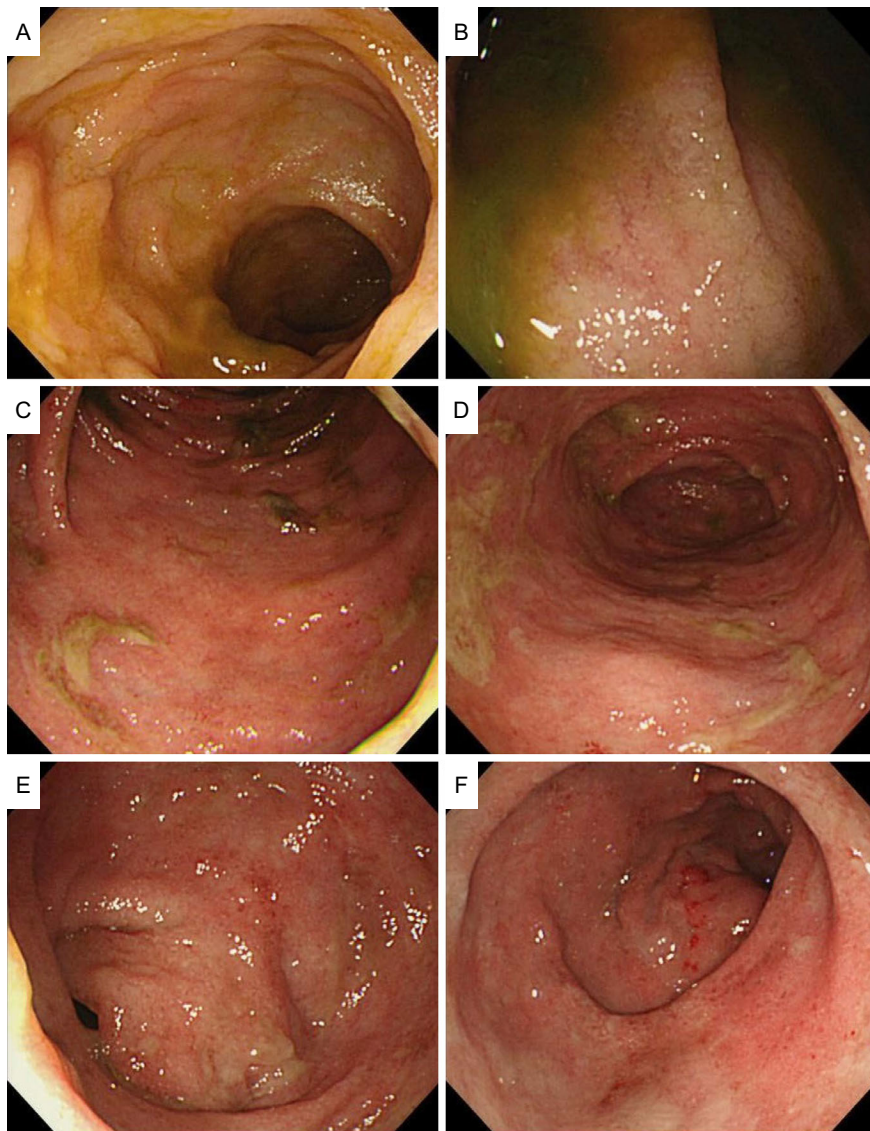
A 14-year-old boy was diagnosed with UC in April 20XX and started on treatment with mesalazine and prednisolone. Mesalazine was discontinued because he developed acute pancreatitis, and he was started on granulocyte/monocyte adsorption apheresis (GMA); nafamostat mesilate was used as an anticoagulant. Total colonoscopy before GMA showed mucosal roughness and the loss of the mucosal vascular appearance, progressing from the rectum to the ascending colon (Fig. 1). His UC activity and symptoms temporarily decreased after the start of GMA. He was maintained as an outpatient on prednisolone (20 mg/day), but he experienced abdominal pain and hematochezia 3 months later and was admitted to a local hospital.

---

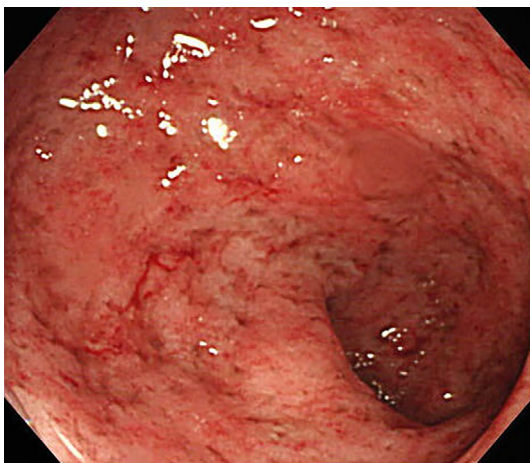
Department of Medicine and Bioregulatory Science, Graduate School of Medical Sciences, Kyushu University, Japan

Received for publication June 27, 2016; Accepted for publication October 6, 2016

Correspondence to Dr. Tsutomu Iwasa, tiwasa@intmed3.med.kyushu-u.ac.jp

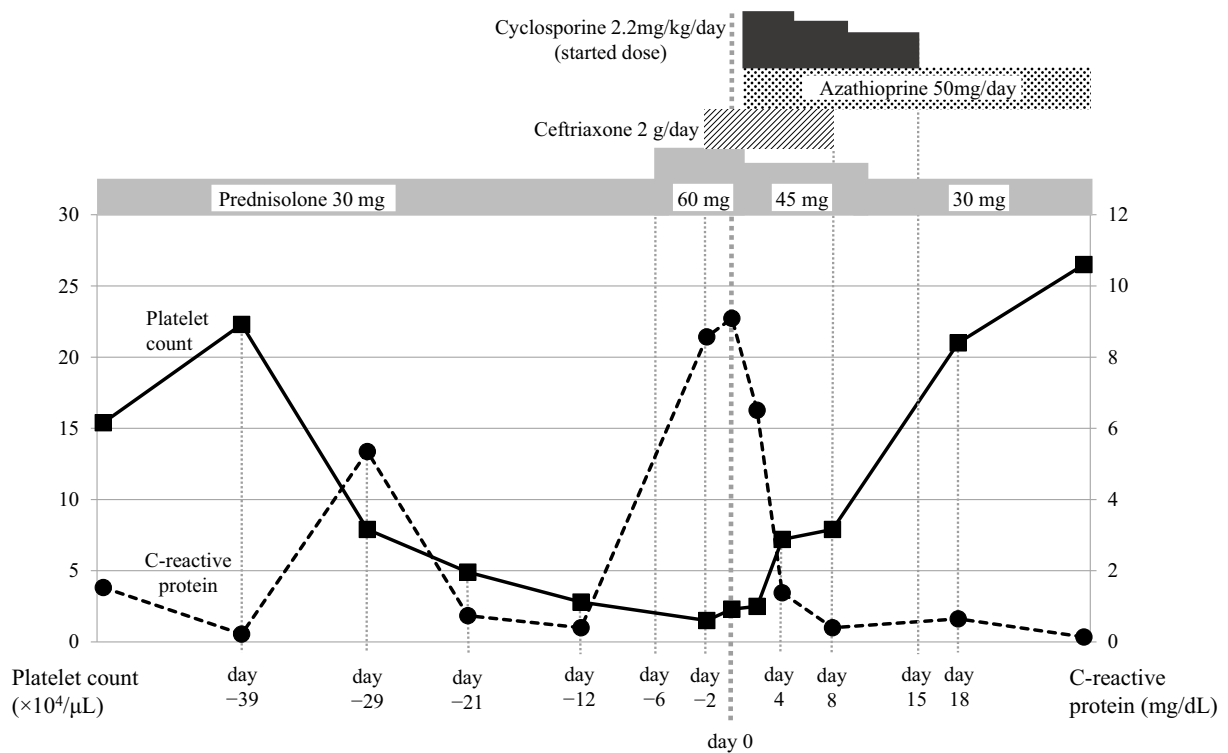


**Figure 1.** Total colonoscopy in the patient of the present study showed mucosal roughness and the loss of the mucosal vascular appearance progressing from the rectum to the ascending colon. The results were compatible with UC. The terminal ileum was negative for these findings. This patient was pretreated with only a glycerin enema. A: terminal ileum, B: ascending colon, C: transverse colon, D: descending colon, E: sigmoid colon, F: rectum.

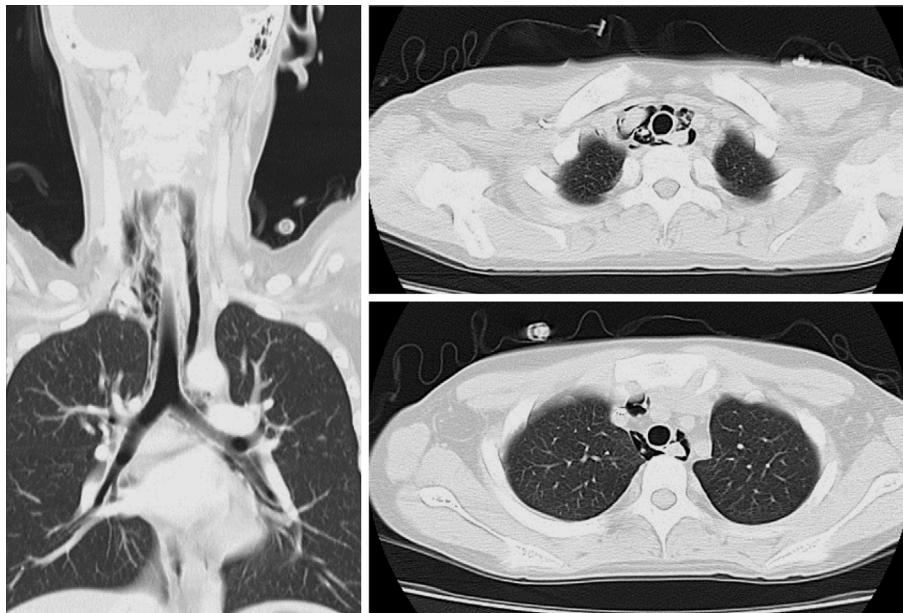


**Figure 2.** The rectal examination of the patient of the present study, showed rough hemorrhagic mucosal changes with multiple erosions.

At the time of his hospital admission, the patient's clinical symptoms included watery diarrhea (approximately ten times per day), mild hematochezia, and slight lower abdominal pain. His white blood cell (WBC) count ( $13,900/\mu\text{L}$ ) and C-reactive protein (CRP) level ( $1.53 \text{ mg/dL}$ ) were elevated. His hemoglobin level was  $11.3 \text{ g/dL}$  and his platelet count was normal ( $15.4 \times 10^4/\mu\text{L}$ ). A rectal examination showed rough hemorrhagic mucosal changes with multiple erosions; however, deep ulceration was not observed (Fig. 2). He was diagnosed with an acute exacerbation of UC. Although his prednisolone dose was increased to  $30 \text{ mg/day}$  and steroid enemas were administered daily, his UC did not improve. Moreover, his platelet counts decreased to  $7.9 \times 10^4/\mu\text{L}$  on day -29 this was followed by further subsequent reductions (Fig. 3). Despite the discontinuation of drugs that can cause thrombocytopenia, such as rabeprazole and camostat mesilate, his platelet counts did not increase.



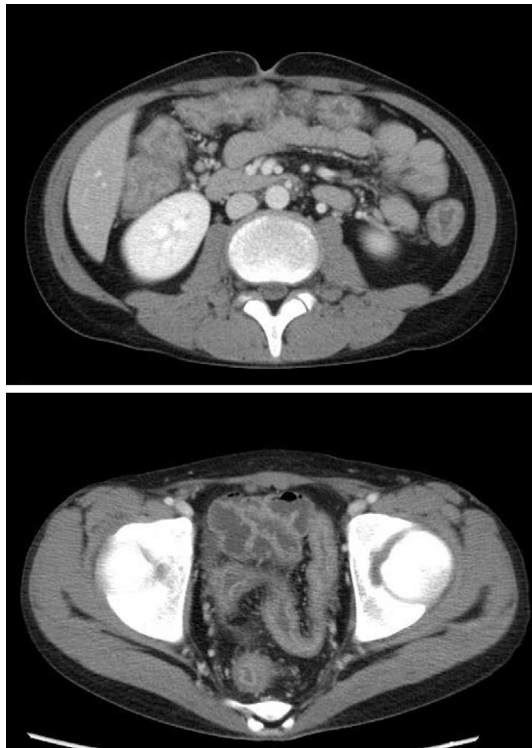**Figure 3.** The clinical course of the patient at his local hospital. The day the patient was transferred to our hospital was defined as day 0.



**Figure 4.** Axial and coronal chest CT, showing mediastinal air around the trachea and bronchus.

These clinical findings suggested ITP. His prednisolone dose was increased to 60 mg/day on day -6, but there were no improvements in the patient's thrombocytopenia or UC. Four days later, on day -2, he developed precordial pressure, pharyngeal pain, and odynophagia. Chest computed tomography (CT) revealed pneumomediastinum (Fig. 4), and abdominal CT revealed slight all-around thickening of the entire large intestine, except for the ileocecum (Fig. 5). The patient was then transferred to our hospital.

The laboratory data on admission to our hospital are shown in Table. The patient's body mass index was 16.9 kg/m<sup>2</sup>, and his total serum protein and albumin concentrations were 5.2 g/dL and 2.0 g/dL, respectively, indicating malnutrition and emaciation. His WBC count (20,880/ $\mu\text{L}$ ) and CRP concentration (9.09 mg/dL) were elevated, and his platelet count was markedly decreased ( $2.3 \times 10^4/\mu\text{L}$ ). His platelet-associated IgG (PAIgG) level was 480.5 ng/ $10^7$  cells (normal range, 5.0-25.0 ng/ $10^7$  cells), and a bone marrow



**Figure 5.** Abdominal CT showing slight, all-around thickening of the entire large intestine, except for the ileocecum. Findings such as toxic dilatation of the colon, intraperitoneal free air, and retroperitoneal emphysema were not observed.

examination revealed normocellular marrow with increased numbers of megakaryocytes (Fig. 6). His clinical symptoms, including watery diarrhea and mild hematochezia, had not improved. A physical examination revealed spontaneous pain and slight tenderness of the lower abdominal region, and edematous limbs, likely due to hypoalbuminemia. The patient did not show purpura, however, his platelet count fell to  $1.5 \times 10^4/\mu\text{L}$  on day -2. We therefore decided to treat both UC and ITP with cyclosporine. His pneumomediastinum was monitored without additional treatment, because his pharyngeal pain and odynophagia were mild and his respiratory condition was stable.

One day after admission to our hospital, he was started on a continuous infusion of cyclosporine (100 mg/day; 2.2 mg/kg/day) and azathioprine (50 mg/day; 1.1 mg/kg/day), and his prednisolone dose was gradually reduced. His UC activity decreased immediately with the disappearance of hematochezia and abdominal pain (Fig. 7), and his platelet counts gradually increased, resulting in a dramatic improvement in his general condition. Ceftriaxone, which had been started at his local hospital, was discontinued on the 8th day after admission to our hospital because his CRP level had decreased, and chest CT showed the disappearance of mediastinal air (Fig. 8). He was discharged at 1 month after admission and has since then been followed up as an outpatient.

**Table.** Laboratory Data on Admission.

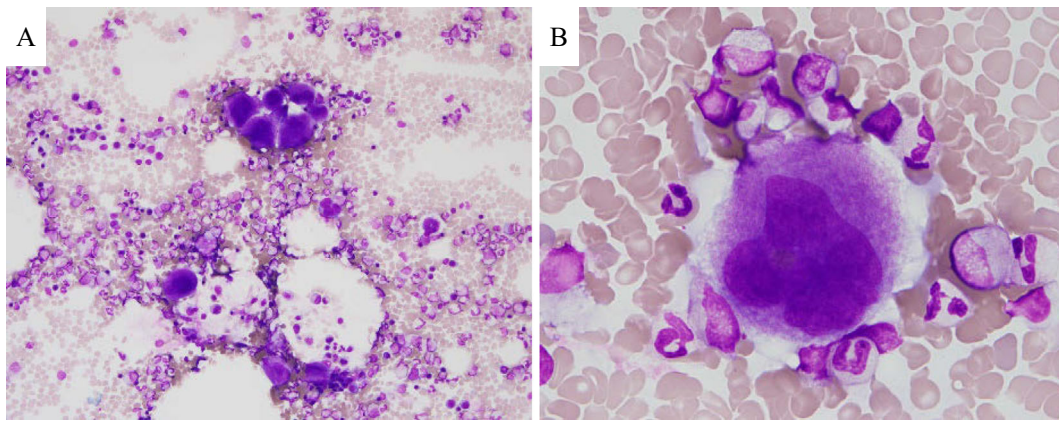
Peripheral Blood		Blood Chemistry	
WBC	20,880 / $\mu\text{L}$	TP	5.2 g/dL
Neut	76.5 %	Alb	2 g/dL
Lymp	16.8 %	T-Bil	0.1 mg/dL
Mon	6.2 %	AST	19 IU/L
Eos	0.4 %	ALT	30 IU/L
Baso	0.1 %	ALP	532 IU/L
RBC	$445 \times 10^4$ / $\mu\text{L}$	LDH	178 IU/L
Hb	11.6 g/dL	$\gamma$ -GTP	124 IU/L
Platelets	$2.3 \times 10^4$ / $\mu\text{L}$	AMY	42 IU/L
		BUN	5 mg/dL
Coagulation tests		Cr	0.4 mg/dL
PT	94 %	T-Chol	95 mg/dL
APTT	35.1 sec	Na	132 mmol/L
FDP	10.5 $\mu\text{g}/\text{mL}$	K	3.5 mmol/L
Fibrinogen	425 mg/dL	Cl	97 mmol/L
		Ca	7.1 mg/dL
Immunological tests		UA	3.1 mg/dL
PA-IgG	$480.5 \text{ ng}/10^7 \text{ cells}$	Fe	22 $\mu\text{g}/\text{dL}$
C7-HRP	negative	CK	38 IU/L
		CRP	9.09 mg/dL

WBC: white blood cells, Neut: neutrophils, Lymp: lymphocytes, Mon: monocytes, Eos: eosinophils, Baso: basophils, RBC: red blood cells, Hb: hemoglobin, Plt: platelets, PT: prothrombin time, APTT: activated partial thromboplastin time, FDP: fibrin-fibrinogen degradation products, TP: total protein, Alb: albumin, T-Bil: total bilirubin, AST: aspartate aminotransferase, ALT: alanine aminotransferase, ALP: alkaline phosphatase, LDH: lactate dehydrogenase,  $\gamma$ -GTP: gamma-glutamyltranspeptidase, AMY: amylase, BUN: blood urea nitrogen, Cr: creatinine, T-Chol: total cholesterol, UA: uric acid, CK: creatine kinase, CRP: C-reactive protein, PA-IgG: platelet-associated Immunoglobulin G

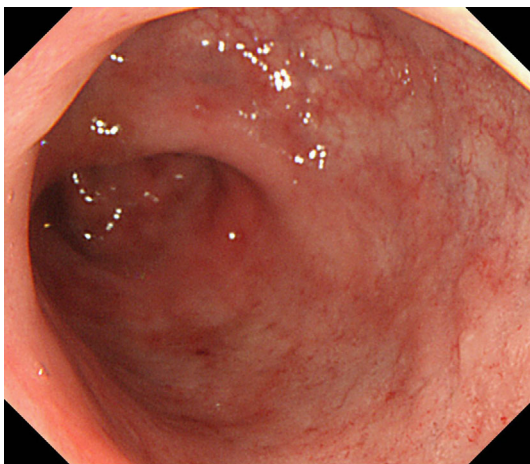
## Discussion

UC is a chronic IBD associated with extraintestinal manifestations in various target tissues (1, 3). Although primary sclerosing cholangitis and erythema nodosum are frequent extraintestinal manifestations of UC, ITP is rare. A study of 624 adult patients with UC found that only three (0.5%) patients also had ITP (4). In addition, few patients with UC have been reported to have spontaneous pneumomediastinum without colonic perforation or toxic megacolon (5, 6).

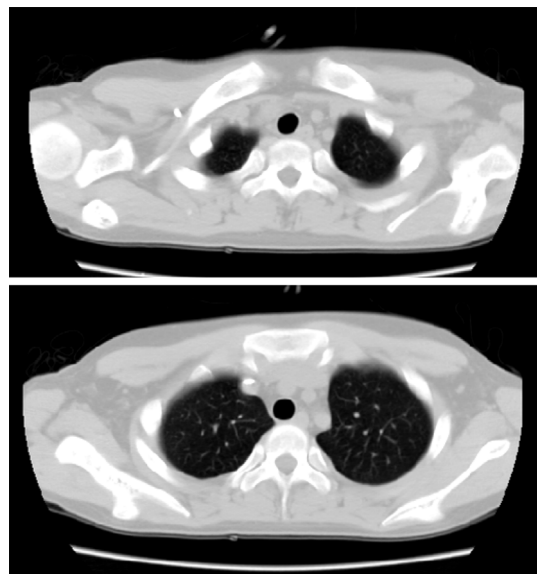
The thrombocytopenia in our patient was likely not secondary thrombocytopenia, as it was not preceded by any events or relevant history. For example, he had not taken any drugs that could induce thrombocytopenia, and there were no indications of viral infection or disseminated intravascular coagulation. Heparin-induced thrombocytopenia was also unlikely, as GMA was performed using nafamostat mesilate (not heparin) as an anticoagulant. The finding of normocellular bone marrow with increased megakaryocyte counts indicated a diagnosis of ITP. Although ITP has been associated with *Helicobacter pylori* infection, including in patients with UC (7), our patient was negative for anti-*H. pylori* IgG. Thus, the ITP in our patient was considered to



**Figure 6.** A bone marrow scan of the patient of the present study showing (A) a large number of aggregated megakaryocytes ( $\times 200$ ) and (B) the absence of platelet adhesion around the megakaryocytes ( $\times 1,000$ ).



**Figure 7.** A rectal examination, showed improvements in the mucosa along with reductions in the rough hemorrhagic mucosal changes.



**Figure 8.** Chest CT showing that the mediastinal air had disappeared.

be an extraintestinal manifestation of UC; however, it should be noted that the actual association between ITP and UC has yet to be determined. In previous reports assessing UC patients with ITP, UC preceded the onset of ITP by days or years, or appeared at the same time (8, 9). The onset of ITP has frequently been observed during an active stage of colitis, with ITP only improving following the successful control of UC by medications or surgical treatment. Similarly, our patient developed UC 7 months before the onset of ITP, with ITP developing during an active stage of UC. Cyclosporine treatment not only controlled the UC activity, but also ITP. These findings strongly suggest that UC may play a role in the pathogenesis of ITP. The increased colonic mucosal permeability in UC may facilitate immune responses, leading to the production of antibodies against bacterial antigens in the intestinal lumen; these antibodies may in turn cross-react with platelet antigens with peptide sequences that are similar to those of bacterial antigens (8-10).

Our patient's pneumomediastinum was considered to be spontaneous because it was not accompanied by any obvious

primary source, including trauma, intrathoracic infection, or a violation of the aerodigestive tract (11). Abdominal CT showed no evidence of toxic dilatation of the colon, intraperitoneal free air, or retroperitoneal emphysema in our patient. In contrast, although air breaking due to the overdistension of the alveoli resulting from an increased alveolar pressure may cause secondary pneumomediastinum (12, 13), this was considered to be unlikely in our patient, as he did not have any symptoms that would have increased the alveolar pressure, such as coughing and vomiting. Our patient's spontaneous pneumomediastinum may have occurred due to the fragility of the alveolar wall (14). The intestinal and bronchial epithelia are morphologically similar, and both are derived from the primitive gut (15, 16). Numerous genes associated with IBD have been identified (17). Thus, a genetic background that affects both the bronchial and intestinal epithelia may allow systemic factors to induce similar responses in both of these organs in IBD patients, including

IBD patients with UC. Another possible cause of spontaneous pneumomediastinum in our patient was malnutrition. Spontaneous pneumomediastinum has been observed in patients with anorexia nervosa, as the malnutrition associated with anorexia may weaken the alveolar walls, with the loss of connective tissue (18). The alveolar walls in our patient could have been weakened by his malnutrition and emaciation, or the chronic administration of prednisolone (approximately 4,600 mg over 6 months) - which could have triggered the onset of pneumomediastinum.

Cyclosporine was effective in treating both UC and UC-associated ITP in this patient. Cyclosporine is a small cyclic peptide of fungal origin that inhibits the activation of transcription factors, including the nuclear factors of activated T cells, by inhibiting calcineurin (19). The first-line therapy for patients who are newly diagnosed with primary ITP includes steroids or intravenous IgG; cyclosporine treatment is considered a second-line therapy (20). Cyclosporine treatment results in the clinical improvement of 83.3% of patients with primary ITP resistant to first-line therapy (21). In addition, cyclosporine may be effective in patients with severe UC. The day 8 response rate of low-dose cyclosporine (2 mg/kg/day) in the treatment of patients with severe UC was 85.7% (22). These findings indicate that cyclosporine treatment results in marked improvements in patients with ITP alone or UC alone. However, most patients with UC-associated ITP are treated with steroids or intravenous IgG as a first-line therapy, followed by total colectomy as a second-line therapy when the first-line therapy is ineffective (23). To our knowledge, no patients with UC-associated ITP have been reported effectively treated with cyclosporine as second-line therapy.

Cyclosporine likely did not have a direct effect on our patient's pneumomediastinum. Rather, it had an indirect effect because his general condition was improved by the reduction of UC activity and ITP that occurred following cyclosporine treatment.

In conclusion, this report describes a patient with UC and concurrent ITP, who later developed spontaneous pneumomediastinum. The administration of cyclosporine was effective in treating his UC and ITP, and his pneumomediastinum resolved without additional treatment. Second-line treatment with cyclosporine may result in a better quality of life than second-line total colectomy in patients with steroid-resistant UC and ITP resulting from the exacerbation of UC.

**The authors state that they have no Conflict of Interest (COI).**

## References

- Greenstein AJ, Janowitz HD, Sachar DB. The extraintestinal complications of Crohn's disease and ulcerative colitis: a study of 700 patients. *Medicine* **55**: 401-412, 1976.
- Rothfuss KS, Stange EF, Herrlinger KR. Extraintestinal manifestations and complications in inflammatory bowel diseases. *World J Gastroenterol* **12**: 4819-4831, 2006.
- Nakamura K, Ito T, Kotoh K, et al. Hepatopancreatobiliary manifestations of inflammatory bowel disease. *Clin J Gastroenterol* **5**: 1-8, 2012.
- Edwards FC, Truelove SC. The course and prognosis of ulcerative colitis: Part III Complications. *Gut* **5**: 1-15, 1964.
- Annaházi A, Polyák I, Nagy F, Wittmann T, Molnár T. "Ulcerative crepitus": a case with subcutaneous emphysema and pneumomediastinum without colonic perforation or toxic megacolon in ulcerative colitis successfully treated conservatively. *J Crohns Colitis* **6**: 717-719, 2012.
- Gupta DC, Jenaw RK, Koolwal S, Khippal N. A rare case of ulcerative colitis with diffuse parenchymal lung disease, spontaneous pneumomediastinum and subcutaneous emphysema. *Indian J Chest Dis Allied Sci* **56**: 109-111, 2014.
- Etou T, Iizuka M, Ohshima A, et al. Ulcerative colitis accompanied by idiopathic thrombocytopenic purpura and *Helicobacter pylori* infection. *Intern Med* **52**: 547-549, 2013.
- Mizuta Y, Isomoto H, Kadokawa Y, et al. Immune thrombocytopenic purpura in patients with ulcerative colitis. *J Gastroenterol* **38**: 884-890, 2003.
- Zlatanic J, Korelitz BI, Wisch N, et al. Inflammatory bowel disease and immune thrombocytopenic purpura: is there a correlation? *Am J Gastroenterol* **92**: 2285-2288, 1997.
- Yoshida EM, Chaun H, Freeman HJ, Whittaker JS, Galbraith PF. Immune thrombocytopenic purpura in three patients with preexisting ulcerative colitis. *Am J Gastroenterol* **91**: 1232-1235, 1996.
- Caceres M, Ali SZ, Braud R, Weiman D, Garrett HE Jr. Spontaneous pneumomediastinum: a comparative study and review of the literature. *Ann Thorac Surg* **86**: 962-966, 2008.
- Macklin CC. Transport of air along sheaths of pulmonic blood vessels from alveoli to mediastinum. *Arch Intern Med* **64**: 913-926, 1939.
- Okada M, Adachi H, Shibuya Y, Ishikawa S, Hamabe Y. Diagnosis and treatment of patients with spontaneous pneumomediastinum. *Respir Investig* **52**: 36-40, 2014.
- Hamman L. Mediastinal emphysema. *JAMA* **128**: 1-6, 1945.
- Higenbottam T, Cochrane GM, Clark TJ, Turner D, Millis R, Seymour W. Bronchial disease in ulcerative colitis. *Thorax* **35**: 581-585, 1980.
- Desai D, Patil S, Udawadia Z, Maheshwari S, Abraham P, Joshi A. Pulmonary manifestations in inflammatory bowel disease: a prospective study. *Indian J Gastroenterol* **30**: 225-228, 2011.
- McGovern DP, Kugathasan S, Cho JH. Genetics of inflammatory bowel diseases. *Gastroenterology* **149**: 1163-1176, 2015.
- van Veelen I, Hogeman PH, van Elburg A, Nielsen-Abbring FW, Heggelman BG, Mahieu HF. Pneumomediastinum: a rare complication of anorexia nervosa in children and adolescents. A case study and review of the literature. *Eur J Pediatr* **167**: 171-174, 2008.
- Gerber DA, Bonham CA, Thomson AW. Immunosuppressive agents. recent developments in molecular action and clinical application. *Transplant Proc* **30**: 1573-1579, 1998.
- Provan D, Stasi R, Newland AC, et al. International consensus report on the investigation and management of primary immune thrombocytopenia. *Blood* **115**: 168-186, 2010.
- Emilia G, Morselli M, Luppi M, et al. Long-term salvage therapy with cyclosporin A in refractory idiopathic thrombocytopenic purpura. *Blood* **99**: 1482-1485, 2002.
- Van Assche G, D'Haens G, Noman M, et al. Randomized, double-blind comparison of 4 mg/kg versus 2 mg/kg intravenous cyclosporine in severe ulcerative colitis. *Gastroenterology* **125**: 1025-1031, 2003.
- Chandra S, Finn S, Obah E. Immune thrombocytopenic purpura in ulcerative colitis: a case report and systematic review. *J Community Hosp Intern Med Perspect* **4**: 23386, 2014.

The Internal Medicine is an Open Access article distributed under the Creative Commons Attribution-NonCommercial-NoDerivatives 4.0 International License. To view the details of this license, please visit (<https://creativecommons.org/licenses/by-nc-nd/4.0/>).

---

© 2017 The Japanese Society of Internal Medicine  
<http://www.naika.or.jp/imonline/index.html>