



# Autonomic Dysreflexia following Spinal Cord Injury

Vladimír Balik<sup>1</sup> Igor Šulla<sup>2</sup>

<sup>1</sup>Department of Neurosurgery, Svet Zdravia Hospital, Michalovce, Slovakia

<sup>2</sup>Department of Anatomy, University of Veterinary Medicine and Pharmacy, Histology and Physiology, Košice, Slovakia

Address for correspondence Balik Vladimír, MD, PhD, Department of Neurosurgery, Svet Zdravia Hospital, Špitálska 2, 07101, Michalovce, Slovak Republic (e-mail: balik.vladimir@gmail.com).

AJNS 2022;17:165–172.

## Abstract

Autonomic dysreflexia (AD) is a potentially life-threatening condition of the autonomic nervous system following spinal cord injury at or above T6. One of the most common symptoms is a sudden increase in blood pressure induced by afferent sensory stimulation owing to unmodulated reflex sympathetic hyperactivity. Such episodes of high blood pressure might be associated with a high risk of cerebral or retinal hemorrhage, seizures, heart failure, or pulmonary edema. In-depth knowledge is, therefore, crucial for the proper management of the AD, especially for spine surgeons, who encounter these patients quite often in their clinical practice. Systematical review of the literature dealing with strategies to prevent and manage this challenging condition was done by two independent reviewers. Studies that failed to assess primary (prevention, treatment strategies and management) and secondary outcomes (clinical symptomatology, presentation) were excluded. A bibliographical search revealed 85 eligible studies that provide a variety of preventive and treatment measures for the subjects affected by AD. As these measures are predominantly based on noncontrolled trials, long-term prospectively controlled multicenter studies are warranted to validate these preventive and therapeutic proposals.

## Keywords

- ▶ autonomic dysreflexia
- ▶ autonomic hyperreflexia
- ▶ autonomic nervous system
- ▶ spinal cord injury

## Introduction

Autonomic dysreflexia, also known as autonomic hyperreflexia, AD syndrome, or AD symptom complex is a perilous autonomic nervous system (ANS) reaction associated with morbidity and mortality.<sup>1–4</sup> It occurs in 70 to 90% of patients with spinal cord injury (SCI) at or above T6.<sup>2,5–8</sup> Although rarely, AD-like symptoms were also observed in patients with degenerative disc disease, intramedullary tumors, or multiple sclerosis plaques in the cervical or thoracic region.<sup>9–12</sup> AD is typically presented as a sudden, uncontrolled

high blood pressure accompanied by cardiac arrhythmia, blurred vision, intense headache, skin erythema, and profuse sweating in the part of the body above the SCI.<sup>5,13,14</sup> Episode of the high blood pressure might be associated with a high risk of intracranial or retinal hemorrhage, seizures, heart failure, or pulmonary edema.<sup>2,14–17</sup> This fact represents an emergent situation demanding immediate medical attention. The paucity of familiarity with this clinical entity may cause misdiagnosis, hesitancy, delay in the appropriate management, and thus irreversible harm to the patient.<sup>5,17,18</sup> The aforementioned reasons inspired the authors to review literature

DOI <https://doi.org/10.1055/s-0042-1751080>.  
ISSN 2248-9614.

© 2022. Asian Congress of Neurological Surgeons. All rights reserved.

This is an open access article published by Thieme under the terms of the Creative Commons Attribution-NonDerivative-NonCommercial-License, permitting copying and reproduction so long as the original work is given appropriate credit. Contents may not be used for commercial purposes, or adapted, remixed, transformed or built upon. (<https://creativecommons.org/licenses/by-nc-nd/4.0/>)

Thieme Medical and Scientific Publishers Pvt. Ltd., A-12, 2nd Floor, Sector 2, Noida-201301 UP, India

dealing with current treatment strategies of the serious clinical condition.

## Materials and Methods

Literature published between January 1, 2000, and December 31, 2020, was searched in the NCBI/NLM PubMed/MEDLINE and ISI Web of Science databases using specific strings of terms with restriction to full text and English language. The following string of terms was used: (“autonomic dysreflexia,” “spinal cord injury,” “autonomic nervous system”). Time restriction allowed the inclusion of studies employing refined imaging and treatment strategies. Studies failed to assess primary (prevention, treatment, management) and secondary outcomes (clinical symptomatology and presentation) were excluded. The titles and abstracts were screened by two independent reviewers and subsequently selected studies were critically reviewed and assessed for their methodological quality and outcomes. Any disagreements were resolved by consensus of the reviewers. Our literature search yield 1,101 articles of which 85 studies concerning patients with AD met the inclusion criteria.

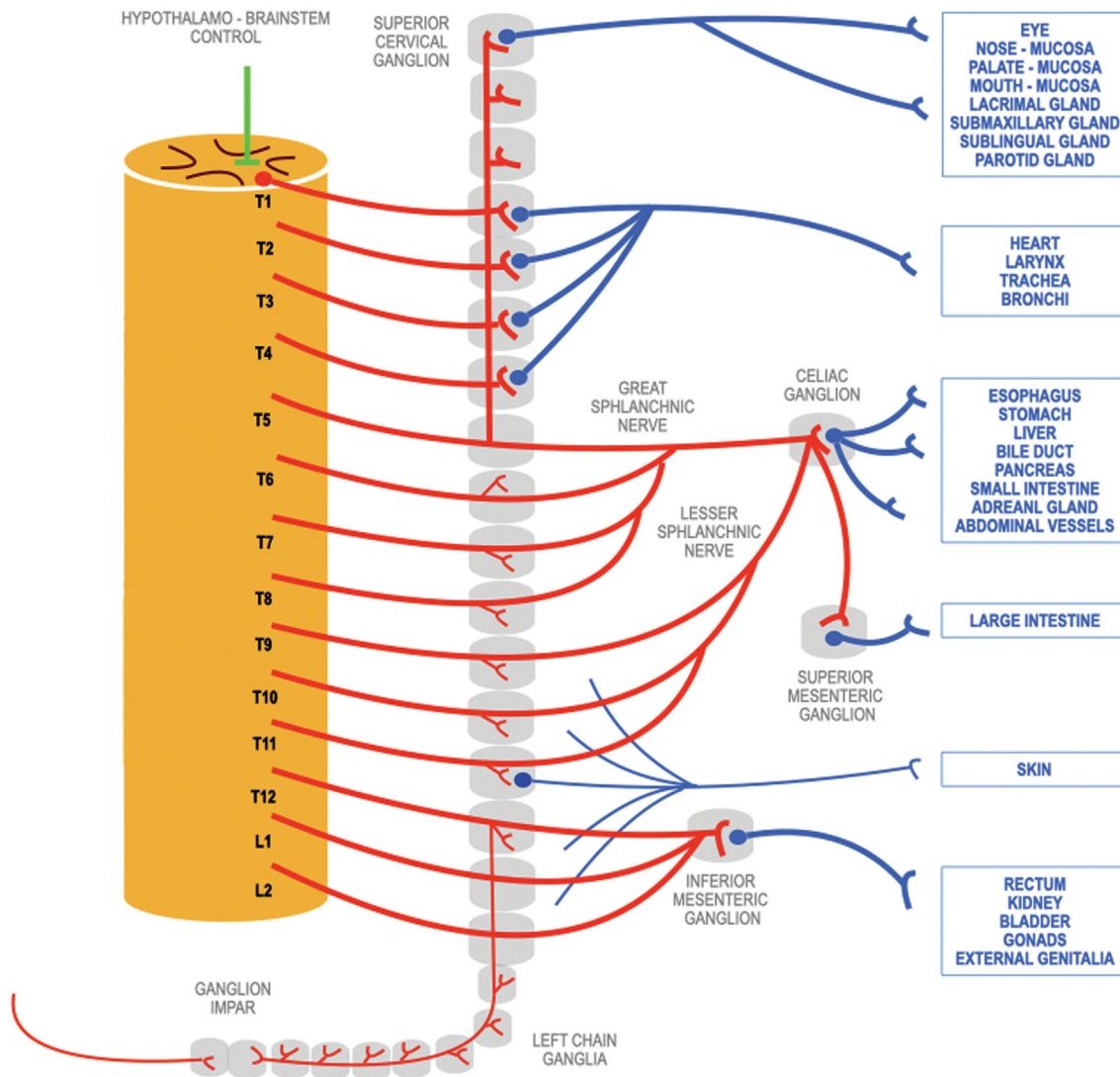
## Anatomy of Sympathetic Nervous System

A sympathetic part, one of the two main parts of the ANS and more fundamental for AD, functions on the basis of the reflex arc with an afferent and efferent arm, and a central integrating system.<sup>19,20</sup> The sensory information from receptors are transmitted to the homeostatic control centers in the brain via cranial nerves, or in the spinal cord via dorsal root ganglia. The simplest reflex actions of the ANS may be completed in the involved organ system (bowel motions, production of digestive enzymes), others at the level of spinal cord (urination, defecation), while more complex autonomic reactions are regulated by centers located in the brainstem and hypothalamus.<sup>20–23</sup> The hypothalamic–brainstem control system is also under the influence of higher central areas, such as insula, anterior cingulate cortex, substantia innominata, amygdala, and the ventromedial prefrontal cortex. They mediate specific autonomic reactions (blushing, piloerection, tachycardia, sweat cold, nausea, and/or vomiting) activated by emotions or distress.<sup>20,23</sup> The sympathetic pathways leave the central nervous system via preganglionic neurons located in the intermediolateral columns of the spinal cord from T1 to L2/L3 level<sup>19,20</sup> and respond to the threats of the external environment by the “fight-or-flight” reaction, whereas the parasympathetic part provides with the “rest-and-digest” activities.<sup>20,23</sup> The sympathetic neurons play a critical role in maintaining tonic activity in sympathetic vasomotor nerves, whereby most of these neurons respond to visceral stimulation.<sup>20,21,24,25</sup> The impulses project via the anterior spinal nerve roots to ganglionic neurons forming paravertebral and prevertebral ganglia,<sup>22</sup> namely ganglion impar,<sup>24</sup> celiac, aorticorenal, superior mesenteric, and inferior mesenteric ganglia,<sup>20</sup> and the plexuses of internal carotid arteries.<sup>24</sup> In addition, some axons

end in the adrenal medulla and regulate releasing of catecholamines into the bloodstream (–Fig. 1).<sup>20–22,24,26</sup>

## Sympathetic Nervous System and Spinal Cord Injury

The sympathetic ANS supplying blood vessels with vasoconstrictor axons operate in balance with parasympathetic pathways.<sup>20,22,23</sup> Since the SCI located above the mid-thoracic segments obstructs brainstem control over the spinal autonomic circuitry, innocuous or subthreshold noxious afferent impulses reaching the medulla below the lesion via intact sensory nerves may elicit an uninhibited reaction of sympathetic preganglionic neurons.<sup>14,15,27–31</sup> Injuries located below T6 segment less likely cause AD because the intact splanchnic innervation usually ensures the compensatory dilatation of the intraabdominal vascular bed providing the sufficient mass of blood vessels apt to manage arterial hypertension.<sup>6,8,17</sup> A critically increased blood pressure caused by the uncontrolled release of norepinephrine, dopamine-β-hydroxylase, and dopamine<sup>21,27,32</sup> is detected by baroreceptors in the aortic arch, carotid sinus, and coronary arteries, projecting to the nucleus of the solitary tract located in the medulla oblongata.<sup>21,23</sup> This leads to the response of the integration center by a strong vagal reaction.<sup>22</sup> However, the impulses are blocked by the lesion, so they only affect vessels innervated by neurons located above the SCI.<sup>29</sup> That is why the vagal stimulation induces vasodilatation in the upper part of the body, provokes headache, nasal congestion, skin flushing, and profuse sweating of the head, face, neck, shoulders, the upper part of the trunk, as well as bradycardia.<sup>23,31</sup> Of note, the bradycardia may be only “relative,” not less than 60 heart beats per minute. Yet, even a significant reduction of heart rate is not able to compensate for the massive splanchnic vasoconstriction.<sup>14,17</sup> Clinical practice shows that frequency, as well as the intensity of AD attacks usually increases over time.<sup>18,29,33,34</sup> This is attributed to the synaptic reorganization of sympathetic preganglionic neurons, primary afferent sprouting, aberrant propriospinal plasticity caudal to the lesion, and peripheral adrenergic hypersensitivity.<sup>18</sup> Following the blockade of descending modulatory impulses by the SCI, the performance of sympathetic preganglionic neurons (regulated in healthy individuals by a mutual activity of supraspinal and intraspinal stimuli) becomes wholly dependent on interneurons located in spinal cord laminae V to VIII and X.<sup>24</sup> Since there are not any direct synaptic connections between primary afferents and sympathetic preganglionic neurons, it is anticipated that sensory neurons affect the sympathetic neurons via aforementioned spinal interneurons.<sup>35</sup> The secondary intensifying phase of AD is attributed to the plasticity below the lesion. What promotes such a maladaptive development is still not clear, but experimental works indicate that a tumor necrosis factor alpha signaling plays a role in the injury-induced neuroplasticity.<sup>18</sup> The additional contributing factor may be enhanced intraspinal sprouting of unmyelinated c-fiber nociceptive afferents promoted by expression of nerve growth factor (NGF), and pro-NGF.<sup>36,37</sup>



**Fig. 1** Schematic drawing of sympathetic nervous system.

The experimental model also showed that  $\gamma$ -aminobutyric acid (GABA) neurotransmission transforms from an inhibitory to excitatory pattern. Specifically, GABA-ergic neurons instead of physiological suppression, promote the development of nociceptive sensitization after SCI.<sup>38</sup> In addition to a maladaptive plasticity of viscerosympathetic circuitry, there is also evidence of peripheral changes responsible for an exaggerated pressor reaction to the afferent stimulation. In tetraplegic or high-level paraplegic subjects, the resting blood pressure and plasma catecholamine levels are significantly lower than in healthy individuals. Nevertheless, in patients with a history of AD, the vasomotor response to administration of norepinephrine is significantly enhanced.<sup>39</sup>

## Mechanisms Initiating Autonomic Dysreflexia

Various stimuli can trigger an unregulated sympathetic reaction causing AD.<sup>27,31,40,41</sup> The onset of AD is usually

provoked by the distension of urinary bladder, genitourinary tract infections, urolithiasis, renal colic, catheterization, urodynamic studies, cystoscopy, sexual stimulation, gynecological problems, vaginal examination, distal bowel or rectal stimulation (enema, mechanical stool removal, fecal impaction), hemorrhoids, gastrointestinal morbidity (pancreatitis, gastroduodenal ulcers, cholelithiasis), tissue damage (bone fracture, decubital necrosis), or skin irritation from tight clothing, sunburn, ingrown toe nails, insect bites, dressing changes, rehabilitation, and physiotherapeutic measures.<sup>17,28,40,42</sup> The compression of surrounding organs by enlarged uterus, as well as labors, delivery, breast-feeding, and changes arising during puerperal period are also strong triggering factors in women with cervical or high-thoracic lesions.<sup>5,7,40,43,44</sup>

## Acute Clinical Presentation

AD may have an episodic nature or attacks that occur several times a day while persisting from minutes to hours, or even

days.<sup>4,31,34</sup> They are characterized by a sudden increase in systolic blood pressure by at least 20 to 40 mm Hg above the baseline in adults, 15 to 20 mm Hg in adolescents, and more than 15 mm Hg in children. Heart rate changes usually include bradycardia; however, tachycardia, especially in children, has been also observed frequently accompanied by pulsating headache, intermittent tremor, dizziness, malaise, nausea, blurred vision, restlessness, and anxiety.<sup>11,14,15,31,45</sup> The symptomatology may be replenished by nasal congestion, miosis, and diaphoresis, hot flushes of the face, neck, shoulders, and upper part of the chest cranially to the level of lesion due to parasympathetic response. On the other hand, pale, cool skin, and piloerection are observed caudally to the level of SCI due to increased sympathetic tone, and lack of descending inhibitory parasympathetic modulation.<sup>14,31,46</sup> Headache and sweating are observed in more than 80% of cases, whereas the others are present inconstantly.<sup>46</sup> Yet, in rare cases of so-called silent AD, the concomitant symptoms may be minimal, or absent. Nevertheless, this type of AD may also advance to the true emergency characterized by extreme hypertension (systolic blood pressure may exceed 300 mm Hg and diastolic 200 mm Hg), cardiac arrhythmia, pulmonary edema, and lethal outcome.<sup>5,12,14,15,17,34,40</sup> In the review of 26 studies analyzing 32 cases of life-threatening or fatal complications associated with AD, Wan and Krassioukov<sup>28</sup> identified 23 as central nervous system-related, 7 cardiovascular-related, and 2 pulmonary-related. Seven patients died; six due to intracerebral hemorrhage and one due to heart failure and pulmonary edema. The first attack of AD usually occurs after the spinal shock wears off and spinal reflexes return. It may take weeks, months, or even years after the high-level injury.<sup>31,44,47</sup> However, in approximately 6% of SCI, AD emerges during an early postinjury period.<sup>39,48</sup> Such a situation is potentially very dangerous since patients with a complete acute/subacute SCI located at or above T6 usually suffer from hypotension.<sup>49</sup> Hence, their management requires vasopressors to maintain sufficient oxygenation of vital organs.<sup>14,47</sup> An unexpected AD attack in such patients, whose condition necessitates the regular administration of pressor agents, may have catastrophic consequences.

## Chronic Clinical Presentation

### Deterioration of Cardiac Function

The echocardiographic examinations in rats following experimental T3 transections showed that repeated AD attacks had a marked negative impact on basal myocardial performance, and a growing number of daily hypertonic crises proportionally deteriorate systolic as well as diastolic function. Experimental studies suggested that depressed cardiac contractile reserve developed due to desensitization of  $\beta$ -adrenergic receptors.<sup>50</sup> Similar results were observed in humans with cervical SCI suffering from multiple daily AD episodes.<sup>50</sup> The data explain mechanisms participating in the development of an acute pulmonary edema induced by a severe AD assault.<sup>51,52</sup>

### Induced Immune Deficiency Syndrome

Animal models as well as clinical practice indicate that repeated episodes of AD suppress immune functions, impair cardiac mechanics, and alter cerebrovascular and cognitive functions.<sup>3,33,53</sup> The phenomenon known in paraplegic/tetraplegic patients as the spinal cord injury induced immune deficiency syndrome (SCI-IIDS) depends on the level of SCI; the lesions located above T6 are associated with more serious immunosuppression.<sup>33,53</sup> The SCI-IIDS is characterized by reduced activity of macrophages, T and B lymphocytes, as well as an impaired proliferation of hematopoietic progenitor cells.<sup>53</sup> Due to well-known immunosuppressive role of sympathetic nervous system and catecholamines, Zhang et al<sup>33</sup> imply the existence of a causal link between recurrent AD episodes, spleen atrophy, decreased immune cell production, limited antibodies production, and a diminished anti-inflammatory response of the organism. All aforementioned negative factors explain the considerably increased predisposition of patients with high-level SCI to infectious complications.<sup>53</sup>

### Alteration of Cerebrovascular and Cognitive Functions

It is well known that hypertension alters the structure and function of cerebral blood vessels. The repeated AD bouts cause arteriolar damage, brain edema, and brain tissue necrosis. Clinical symptomatology is characterized by neurological deficit and altered cognitive functions.<sup>54,55</sup>

## Autonomic Dysreflexia and Pregnancy

The epidemiological study of Lee et al<sup>56</sup> showed that more than 50% of SCI in women are at or above T6. Moreover, many of them are young and able to get pregnant. Whereas the occurrence, causes, and symptomatology of AD are similar in men and women, the pregnancy represents the unique situation, requiring a different approach and special attention.<sup>40,43</sup> The most common complications of pregnancy in tetraplegic/paraplegic women with high-level thoracic SCI are urinary tract infections and constipation accompanied with fecal bowel impaction. In the third trimester of gestation, problems with respiration, increased spasticity, preeclampsia, as well as preterm labor and delivery usually between the 32nd and 37th week of gravidity may occur.<sup>40,43,44</sup> The preeclampsia characterized by the triad of hypertension, proteinuria, and edemas<sup>57</sup> might represent a very serious condition when associated with AD.

## Paralympic Athletes with Autonomic Dysreflexia

In patients with high-level SCI, cardiovascular system has a tendency to react to increased physical demands by lowering blood pressure,<sup>14</sup> leading to reduced endurance and limited performance.<sup>58</sup> Therefore, some paralympic athletes enhance their performance through the self-induction of AD, the activity referred to as "boosting." The boosting is achieved by constriction of feet, legs, or genitals, clamping

the catheter to impose an overfilling of the bladder with urine, eventually other types of peripheral nervous system irritation.<sup>58,59</sup> The studies comparing physiological functions of paraplegic athletes showed that their blood pressure, heart rate, oxygen consumption, and circulating catecholamines were markedly elevated in a boosted state, and the physical performance increased by 7 to 10%.<sup>60</sup> Yet, a deliberate and repeated induction of AD may cause serious complications, even death. For health safety reasons, the boosting is officially banned by the International Paralympic Committee.<sup>58–60</sup>

## Management of Autonomic Dysreflexia

Various therapeutic measures, such as hypothermia, neuroprotective drugs, genetic manipulation of intraspinal plasticity, or reparative strategies, have been proposed to ameliorate, suppress, or reverse the activity of numerous negative factors contributing to the expansion of necrosis, and accentuating the tissue damage within the secondary phase of SCI.<sup>61–66</sup>

### Prevention of Sympathetic Hyperactivity

The majority of treatment options primarily rely on prevention and suppression of sympathetic hyperactivity. Since the most common cause of AD is urinary bladder distension followed by the recto-sigmoid fecal impaction, the employment of regular voiding and bowel care programs is essential for the well-being of the patients.<sup>25,27,34,40,67–69</sup>

### Suppression of Sympathetic Hyperactivity

If symptoms of AD occur, the initial management should begin with the change of patients position from supine to sitting, and lowering legs across the edge of the bed.<sup>16,27,40,51</sup> The upright posture helps to reduce high blood pressure by transfer of circulating blood to the lower part of the body.<sup>34</sup> The next step is the identification and removal of triggering factors.<sup>5,31,39,40,70</sup> Because the Credé maneuver may trigger an AD, its use to empty urinary bladder in this situation is too risky. So, if the patient has not an indwelling catheter, the catheterization of the urinary bladder is indicated.<sup>34,40</sup> Because any manipulation with a urinary catheter can start an AD reaction, it should be performed in local anesthesia utilizing 2 to 3 minutes instillation of trimecaine hydrochloride or lidocaine hydrochloride lubricating jelly into the urethra<sup>40,71,72</sup> If the urinary bladder is empty, but symptoms of AD persist, the fecal impaction of the distal colon must be suspected. The complete bowel evacuation after mucosal anesthesia should, therefore, follow.<sup>67,69,71</sup> If the aforementioned measures do not alleviate symptoms and reduce blood pressure sufficiently, pharmacological management must be initiated.<sup>39,40</sup> Because the administration of antihypertensive drugs in patients with unstable cardiovascular functions may lead to sudden hypotension, the selection of medicaments, as well as their initial dosage should be cautious and attended by monitoring blood pressure every 2 to 5 minutes for at least 2 hours after resolution of AD episode.

### Antihypertensive Therapy

The most frequently used medicaments for an acute attack of AD are organic nitrates—nitroglycerine, isosorbide dinitrate, or isosorbide mononitrate. The mode of action of nitroglycerine or isosorbides is their conversion to nitric oxide with the help of mitochondrial aldehyde dehydrogenase. Nitric oxide imposes relaxation of smooth muscles in arteries and arterioles leading to vasodilation and rapid reduction of blood pressure.<sup>73</sup> The intravenous administration of high doses of nitroglycerine proved well in the management of hypertensive heart failure accompanied by pulmonary edema.<sup>52</sup> The hypertonic crisis can also be handled by intravenous infusion of sodium nitroprusside.<sup>74</sup> Nifedipine belonging to a group of calcium channel blockers reduces the influx of  $Ca^{2+}$  into vascular smooth muscle cells and decreases blood pressure.<sup>34</sup> Pretreatment with another calcium channel blocker nimodipine by a standard oral dose 1 hour before urological procedures or sexual activity proved to be an effective AD prophylactic measure.<sup>30,75</sup> The side effects of nifedipine include headache and arterial hypotension. Especially in patients predisposed to resting and/or orthostatic hypotension, which typically occurs in those with high-level SCI, nitrates are favored to nifedipine, because the drug may cause renal, brain, and/or cardiac ischemia due to an excessive reduction of blood pressure.<sup>10,34</sup> Prazosin hydrochloride, a specific  $\alpha_1$ -adrenergic receptor antagonist, acting through the blockade of constrictive action of norepinephrine on smooth muscle cells in vessel walls and urethra is a second-line choice for the treatment of arterial hypertension.<sup>29,67</sup> Prazosin also alleviates the symptoms associated with prostatic hyperplasia and suppresses nightmares in patients with posttraumatic stress disorder.<sup>29,76</sup> The side effects of the drug include dizziness, sleepiness, nausea, palpitations, spontaneous erection, and exceptionally priapism.<sup>76</sup> The indication of prazosin is preferred in high-level SCI patients with chronic hypotension due to its minimal influence on cardiac functions and resting blood pressure.<sup>30</sup> Specifically, the administration of prazosin may be effective as a prophylactic measure during iatrogenic procedures often triggering AD, such as sperm retrieval by penile vibrostimulation, cystoscopy, urodynamic studies, and colorectal manipulations.<sup>30,68,75,77</sup> Similar positive results can be achieved by infusion of dexmedetomidine hydrochloride, a highly selective  $\alpha_2$ -adrenergic agonist with sympatholytic and anxiolytic effects. While its principal indication is sedation and lowering blood pressure by central mechanisms, its principal side effects are bradycardia, nausea, and dry mouth.<sup>78</sup> Especially positive results in relation to the reduction of AD attacks were achieved with the combination of dexmedetomidine and magnesium sulfate.<sup>16</sup> For recurrent AD, administration of clonidine orally or hydralazine hydrochloride intravenously or intramuscularly is recommended.<sup>34</sup> Clonidine, a selective agonist of  $\alpha_2$ -adrenergic receptors in the brainstem vasomotor center, lowers blood pressure by its sympatholytic effect. It is not only indicated in arterial hypertension, but also in the treatment of attention deficits, hyperactivity disorders, withdrawal symptoms, and menopausal flushing. The side effects of the drug are

sedation, bradycardia, hypotension, dry mouth, nausea, and hallucinations.<sup>79</sup> Hydralazine hydrochloride lowers blood pressure by exerting a peripheral vasodilatation effect through a direct relaxation of vascular smooth muscles. The drug decreases predominantly diastolic blood pressure. Its side effects are headache, anorexia, nausea, diarrhea, palpitations, tachycardia, angina pectoris, dyspnea, and nasal congestion.<sup>51</sup> It is important to stress that until the underlying cause of AD is not identified and removed, the recurrent hypertensive crises will reappear.<sup>40</sup>

### Urinary Dysfunction

*Clostridium botulinum* is a group of four types of anaerobic bacteria producing neurotoxins able to cleave synaptic proteins necessary for neuromuscular transmission.<sup>80</sup> The paralytic effects of the toxins are used for the inhibition of muscle spasms and improvement in physiognomy by the reduction of wrinkles. It is well known that neurogenic detrusor overactivity can increase afferent stimulation and trigger AD episodes in patients with high-level lesion.<sup>81</sup> Botulinum neurotoxin or onabotulinum toxin administered into the wall of the urinary bladder increases its capacity and decreases maximum detrusor pressures.<sup>82</sup> The treatment by the neurotoxin in these patients gained growing popularity due to its effectiveness, long duration of action (12–18 months), relative ease of administration, reproducibility of positive results on repeated application, and low incidence of complications.<sup>81,82</sup> There was not observed any significant difference in effectiveness between injection administered directly into the detrusor or just to the bladder submucosa.<sup>83</sup>

### Sexual Dysfunction

The men with high-level SCI frequently use sildenafil, vardenafil, or tadalafil with the aim to improve their sexual performance.<sup>77</sup> If any of these drugs have been administered within the last 24 hours before an AD attack, the medications containing nitrates (nitroglycerin, isosorbide dinitrate, or sodium nitroprusside) are strictly contraindicated and the utilization of short-acting and rapid-onset antihypertensive agents, such as prazosin or captopril, is recommended instead.<sup>30,34</sup>

### Sacral Deafferentation

In refractory forms of AD, the surgical transection of posterior S2–S4 spinal cord nerve roots is recommended. This strategy, also known as sacral deafferentation, eliminates the conduction of sensory impulses to the spinal cord.<sup>84</sup>

### Pregnancy

The care-givers and physicians of pregnant women should apply all the above-mentioned measures and their obstetricians should be consulted regarding the appropriate long-term medication.<sup>40</sup> If an AD attack arises, the best option is to refer a pregnant woman to an obstetric health-care facility for continuous monitoring during the residual gestation, childbirth, and postpartum period.<sup>44,57,85</sup> Regarding labor and delivery, epidural anesthesia is very effective to prevent or suppress AD symptoms associated with uterine contrac-

tions. Three out of six women with a high-level SCI and the history of AD were able to deliver their babies vaginally; in the remaining three cases the caesarean section was required utilizing epidural, spinal, or general anesthesia.<sup>85</sup>

### Conclusion

Awareness of AD as a potentially life-threatening condition is essential for clinicians involved in the care of patients suffering from SCI at or above T6 level. Education of health care staff along with in-depth knowledge of the relevant pathophysiology, pharmacology, or surgical options can aid in prevention, early recognition, and successful management of AD. A relatively huge number of studies provide a variety of preventive and treatment modalities; however, as they are predominantly noncontrolled trials, long-term prospectively controlled multicenter studies are needed for the validation of the proposed therapeutical measures, especially from their effectiveness and prevention of chronic morbidity point of view.

### Funding

This study was supported by the Agency of the Ministry of Education, Science, Research and Sport of the Slovak Republic for the Structural Funds of EU, ITMS 26220220202.

### Conflict of Interest

None declared.

### References

- 1 Calder KB, Estores IM, Krassioukov A. Autonomic dysreflexia and associated acute neurogenic pulmonary edema in a patient with spinal cord injury: a case report and review of the literature. *Spinal Cord* 2009;47(05):423–425
- 2 Eker A, Yigitoglu PH, Ipekdağ HI, Tosun A. Acute onset of intracerebral hemorrhage due to autonomic dysreflexia. *J Korean Neurosurg Soc* 2014;55(05):277–279
- 3 Bjelakovic B, Dimitrijevic L, Lukic S, Golubovic E. Hypertensive encephalopathy as a late complication of autonomic dysreflexia in a 12-year-old boy with a previous spinal cord injury. *Eur J Pediatr* 2014;173(12):1683–1684
- 4 Salim MS, Mazlan M, Hasnan N. Intracerebral haemorrhage following uncontrolled autonomic dysreflexia post suprapubic catheter placement surgery. *Spinal Cord Ser Cases* 2017;3:17043
- 5 Milligan J, Lee J, McMillan C, Klassen H. Autonomic dysreflexia: recognizing a common serious condition in patients with spinal cord injury. *Can Fam Physician* 2012;58(08):831–835
- 6 Jain A, Ghai B, Jain K, Makkar JK, Mangal K, Sampley S. Severe autonomic dysreflexia induced cardiac arrest under isoflurane anesthesia in a patient with lower thoracic spine injury. *J Anaesthesiol Clin Pharmacol* 2013;29(02):241–243
- 7 Hou S, Rabchevsky AG. Autonomic consequences of spinal cord injury. *Compr Physiol* 2014;4(04):1419–1453
- 8 Garces J, Mathkour M, Scullen T, et al. First case of autonomic dysreflexia following elective lower thoracic spinal cord transection in a spina bifida adult. *World Neurosurg* 2017;108:988.e1–988.e5
- 9 Bateman AM, Goldish GD. Autonomic dysreflexia in multiple sclerosis. *J Spinal Cord Med* 2002;25(01):40–42
- 10 Furlan JC, Fehlings MG, Halliday W, Krassioukov AV. Autonomic dysreflexia associated with intramedullary astrocytoma of the spinal cord. *Lancet Oncol* 2003;4(09):574–575

- 11 Kulcu DG, Akbas B, Citci B, Cihangiroglu M. Autonomic dysreflexia in a man with multiple sclerosis. *J Spinal Cord Med* 2009;32(02):198–203
- 12 Khanna K, Theologis AA, Tay B. Autonomic dysreflexia caused by cervical stenosis. *Spinal Cord Ser Cases* 2017;3:17102
- 13 Lindan R, Joiner E, Freehafer AA, Hazel C. Incidence and clinical features of autonomic dysreflexia in patients with spinal cord injury. *Paraplegia* 1980;18(05):285–292
- 14 Partida E, Mironets E, Hou S, Tom VJ. Cardiovascular dysfunction following spinal cord injury. *Neural Regen Res* 2016;11(02):189–194
- 15 Dolinak D, Balraj E. Autonomic dysreflexia and sudden death in people with traumatic spinal cord injury. *Am J Forensic Med Pathol* 2007;28(02):95–98
- 16 Nasr IA, Elnaghy KM. Control of autonomic dysreflexia in patients with high level of chronic spinal cord injury during cystoscopy. *Ain-Shams J Anaesthesiol* 2016;9:606–611
- 17 Qavi AH, Assad S, Shabbir W, et al. Cardiovascular dysfunction presenting as autonomic dysreflexia in a patient with spinal cord injury. *Cureus* 2017;9(07):e1456
- 18 Mironets E, Osei-Owusu P, Bracchi-Ricard V, et al. Soluble TNF $\alpha$  signaling within the spinal cord contributes to the development of autonomic dysreflexia and ensuing vascular and immune dysfunction after spinal cord injury. *J Neurosci* 2018;38(17):4146–4162
- 19 Rexed B. A cytoarchitectonic atlas of the spinal cord in the cat. *J Comp Neurol* 1954;100(02):297–379
- 20 Wehrwein EA, Orer HS, Barman SM. Overview of the anatomy, physiology, and pharmacology of the autonomic nervous system. *Compr Physiol* 2016;6(03):1239–1278
- 21 Dampney RA, Horiuchi J, Tagawa T, Fontes MA, Potts PD, Polson JW. Medullary and supramedullary mechanisms regulating sympathetic vasomotor tone. *Acta Physiol Scand* 2003;177(03):209–218
- 22 McCorry LK. Physiology of the autonomic nervous system. *Am J Pharm Educ* 2007;71(04):78
- 23 Bankenahally R, Krovvidi H. Autonomic nervous system: anatomy, physiology, and relevance in anaesthesia and critical care medicine. *BJA Educ* 2016;16:381–387
- 24 Deuchars SA, Lall VK. Sympathetic preganglionic neurons: properties and inputs. *Compr Physiol* 2015;5(02):829–869
- 25 Brierley SM, Hibberd TJ, Spencer NJ. Spinal afferent innervation of the colon and rectum. *Front Cell Neurosci* 2018;12:467
- 26 Gibbins I. Functional organization of autonomic neural pathways. *Organogenesis* 2013;9(03):169–175
- 27 Weaver LC, Marsh DR, Gris D, Brown A, Dekaban GA. Autonomic dysreflexia after spinal cord injury: central mechanisms and strategies for prevention. *Prog Brain Res* 2006;152:245–263
- 28 Wan D, Krassioukov AV. Life-threatening outcomes associated with autonomic dysreflexia: a clinical review. *J Spinal Cord Med* 2014;37(01):2–10
- 29 Canon S, Shera A, Phan NM, et al. Autonomic dysreflexia during urodynamics in children and adolescents with spinal cord injury or severe neurologic disease. *J Pediatr Urol* 2015;11(01):32.e1–32.e4
- 30 Phillips AA, Elliott SL, Zheng MM, Krassioukov AV. Selective alpha adrenergic antagonist reduces severity of transient hypertension during sexual stimulation after spinal cord injury. *J Neurotrauma* 2015;32(06):392–396
- 31 Brown R, Burton AR, Macefield VG. Autonomic dysreflexia: Somatosympathetic and viscerosympathetic vasoconstrictor responses to innocuous and noxious sensory stimulation below lesion in human spinal cord injury. *Auton Neurosci* 2018;209:71–78
- 32 Al Dera H, Habgood MD, Furness JB, Brock JA. Prominent contribution of L-type Ca<sup>2+</sup> channels to cutaneous neurovascular transmission that is revealed after spinal cord injury augments vasoconstriction. *Am J Physiol Heart Circ Physiol* 2012;302(03):H752–H762
- 33 Zhang Y, Guan Z, Reader B, et al. Autonomic dysreflexia causes chronic immune suppression after spinal cord injury. *J Neurosci* 2013;33(32):12970–12981
- 34 Caruso D, Gater D, Harnish C. Prevention of recurrent autonomic dysreflexia: a survey of current practice. *Clin Auton Res* 2015;25(05):293–300
- 35 Schramm LP. Spinal sympathetic interneurons: their identification and roles after spinal cord injury. *Prog Brain Res* 2006;152:27–37
- 36 Hou S, Duale H, Rabchevsky AG. Intraspinal sprouting of unmyelinated pelvic afferents after complete spinal cord injury is correlated with autonomic dysreflexia induced by visceral pain. *Neuroscience* 2009;159(01):369–379
- 37 Cheng YY, Zhao HK, Chen LW, et al. Reactive astrocytes increase expression of proNGF in the mouse model of contused spinal cord injury. *Neurosci Res* 2020;157:34–43
- 38 Huang YJ, Lee KH, Murphy L, Garraway SM, Grau JW. Acute spinal cord injury (SCI) transforms how GABA affects nociceptive sensitization. *Exp Neurol* 2016;285(Pt A):82–95
- 39 Eldahan KC, Rabchevsky AG. Autonomic dysreflexia after spinal cord injury: Systemic pathophysiology and methods of management. *Auton Neurosci* 2018;209:59–70
- 40 Consortium for Spinal Cord Medicine. Acute management of autonomic dysreflexia: individuals with spinal cord injury presenting to health-care facilities. *J Spinal Cord Med* 2002;25(Suppl 1):S67–S88
- 41 Rabchevsky AG. Segmental organization of spinal reflexes mediating autonomic dysreflexia after spinal cord injury. *Prog Brain Res* 2006;152:265–274
- 42 Zielinska P, Soroko M, Zwyrzykowska A, et al. The use of laser biostimulation in human and animal physiotherapy – a review. *Acta Vet Brno* 2017;86:91–96
- 43 Courtois F, Alexander M, McLain ABJ. Women's sexual health and reproductive function after SCI. *Top Spinal Cord Inj Rehabil* 2017;23(01):20–30
- 44 Soh SH, Lee G, Joo MC. Autonomic dysreflexia during pregnancy in a woman with spinal cord injury: a case report. *J Int Med Res* 2019;47(07):3394–3399
- 45 Hickey KJ, Vogel LC, Willis KM, Anderson CJ. Prevalence and etiology of autonomic dysreflexia in children with spinal cord injuries. *J Spinal Cord Med* 2004;27(Suppl 1):S54–S60
- 46 Lee ES, Joo MC. Prevalence of autonomic dysreflexia in patients with spinal cord injury above T6. *BioMed Res Int* 2017;2017:2027594
- 47 Gunduz H, Binak DF. Autonomic dysreflexia: an important cardiovascular complication in spinal cord injury patients. *Cardiol J* 2012;19(02):215–219
- 48 Krassioukov AV, Furlan JC, Fehlings MG. Autonomic dysreflexia in acute spinal cord injury: an under-recognized clinical entity. *J Neurotrauma* 2003;20(08):707–716
- 49 Claydon VE, Krassioukov AV. Orthostatic hypotension and autonomic pathways after spinal cord injury. *J Neurotrauma* 2006;23(12):1713–1725
- 50 West CR, Squair JW, McCracken L, et al. Cardiac consequences of autonomic dysreflexia in spinal cord injury. *Hypertension* 2016;68(05):1281–1289
- 51 Rodriguez MA, Kumar SK, De Caro M. Hypertensive crisis. *Cardiol Rev* 2010;18(02):102–107
- 52 Piqueras-Flores J, Jurado-Román A, López-Lluna M, Sánchez-Pérez I, Pinarido-Zabala A, Lozano-Ruiz-Poveda F. Acute pulmonary edema secondary to a hidden hypertensive emergency. *J Cardiol Cases* 2016;14(02):56–58
- 53 Brommer B, Engel O, Kopp MA, et al. Spinal cord injury-induced immune deficiency syndrome enhances infection susceptibility dependent on lesion level. *Brain* 2016;139(Pt 3):692–707

- 54 Sachdeva R, Gao F, Chan CCH, Krassioukov AV. Cognitive function after spinal cord injury: a systematic review. *Neurology* 2018; 91(13):611–621
- 55 Iadecola C, Gottesman RF. Neurovascular and cognitive dysfunction in hypertension. *Circ Res* 2019;124(07):1025–1044
- 56 Lee BB, Cripps RA, Fitzharris M, Wing PC. The global map for traumatic spinal cord injury epidemiology: update 2011, global incidence rate. *Spinal Cord* 2014;52(02):110–116
- 57 Eiland E, Nzerue C, Faulkner M. Preeclampsia 2012. *J Pregnancy* 2012;2012:586578
- 58 Mills PB, Krassioukov A. Autonomic function as a missing piece of the classification of paralympic athletes with spinal cord injury. *Spinal Cord* 2011;49(07):768–776
- 59 Krassioukov A. Autonomic dysreflexia: current evidence related to unstable arterial blood pressure control among athletes with spinal cord injury. *Clin J Sport Med* 2012;22(01):39–45
- 60 Gee CM, West CR, Krassioukov AV. Boosting in elite athletes with spinal cord injury: a critical review of physiology and testing procedures. *Sports Med* 2015;45(08):1133–1142
- 61 Cameron AA, Smith GM, Randall DC, Brown DR, Rabchevsky AG. Genetic manipulation of intraspinal plasticity after spinal cord injury alters the severity of autonomic dysreflexia. *J Neurosci* 2006;26(11):2923–2932
- 62 Fehlings MG, Tetreault LA, Wilson JR, et al. A clinical practice guideline for the management of acute spinal cord injury: introduction, rationale, and scope. *Global Spine J* 2017;7(3, Suppl):84S–94S
- 63 Bimbova K, Bacova M, Kisucka A, et al. A single dose of atorvastatin applied acutely after spinal cord injury suppresses inflammation, apoptosis, and promotes axon outgrowth, which might be essential for favorable functional outcome. *Int J Mol Sci* 2018;19(04):1106
- 64 Zavodska M, Galik J, Marsala M, et al. Hypothermic treatment after computer-controlled compression in minipig: a preliminary report on the effect of epidural vs. direct spinal cord cooling. *Exp Ther Med* 2018;16(06):4927–4942
- 65 Šulla I, Ledecy V, Hornak S, et al. A review of novel trends in management of canine spinal cord injury. *Acta Vet Brno* 2019; 88:207–217
- 66 Jin MC, Medress ZA, Azad TD, Doulames VM, Veeravagu A. Stem cell therapies for acute spinal cord injury in humans: a review. *Neurosurg Focus* 2019;46(03):E10
- 67 Hughes M. Bowel management in spinal cord injury patients. *Clin Colon Rectal Surg* 2014;27(03):113–115
- 68 Taweel WA, Seyam R. Neurogenic bladder in spinal cord injury patients. *Res Rep Urol* 2015;7:85–99
- 69 Vaidyanathan S, Soni BM, Hughes PL, Oo T. Fatal cerebral hemorrhage in a tetraplegic patient due to autonomic dysreflexia triggered by delay in emptying urinary bladder after unsuccessful intermittent catheterization by carer: lessons learned. *Int Med Case Rep J* 2018;11:53–58
- 70 Walter M, Lee AHX, Kavanagh A, Phillips AA, Krassioukov AV. Epidural spinal cord stimulation acutely modulates lower urinary tract and bowel function following spinal cord injury: a case report. *Front Physiol* 2018;9:1816
- 71 Wallin BG, Burton AR, Elam M, Tamaddon K, Millard R, Macefield VG. Viscerosympathetic reflexes in human spinal cord injury: relationships between detrusor pressure, blood pressure and skin blood flow during bladder distension. *Exp Physiol* 2013;98(06):1081–1091
- 72 Solinsky R, Linsenmeyer TA. Intravesical lidocaine decreases autonomic dysreflexia when administered prior to catheter change. *J Spinal Cord Med* 2018;42:1–5
- 73 Chen Z, Foster MW, Zhang J, et al. An essential role for mitochondrial aldehyde dehydrogenase in nitroglycerin bioactivation. *Proc Natl Acad Sci U S A* 2005;102(34):12159–12164
- 74 Palmer RF, Lasseter KC. Drug therapy. Sodium nitroprusside *N Engl J Med* 1975;292(06):294–297
- 75 Sinha V, Elliott S, Ibrahim E, Lynne CM, Brackett NL. Reproductive health of men with spinal cord injury. *Top Spinal Cord Inj Rehabil* 2017;23(01):31–41
- 76 Kung S, Espinel Z, Lapid MI. Treatment of nightmares with prazosin: a systematic review. *Mayo Clin Proc* 2012;87(09):890–900
- 77 Aikman K, Oliffe JL, Kelly MT, McCuaig F. Sexual health in men with traumatic spinal cord injuries: a review and recommendations for primary health-care providers. *Am J Men Health* 2018;12(06):2044–2054
- 78 Arcangeli A, D'Alò C, Gaspari R. Dexmedetomidine use in general anaesthesia. *Curr Drug Targets* 2009;10(08):687–695
- 79 Viera AJ. Hypertension update: resistant hypertension. *FP Essent* 2018;469:20–25
- 80 Peck MW, Stringer SC, Carter AT. Clostridium botulinum in the post-genomic era. *Food Microbiol* 2011;28(02):183–191
- 81 Linsenmeyer TA. Use of botulinum toxin in individuals with neurogenic detrusor overactivity: state of the art review. *J Spinal Cord Med* 2013;36(05):402–419
- 82 Jung IY, Mo KI, Leigh JH. Effect of intravesical botulinum toxin injection on symptoms of autonomic dysreflexia in a patient with chronic spinal cord injury: a case report. *J Spinal Cord Med* 2019; 42(06):806–809
- 83 Li GP, Wang XY, Zhang Y. Efficacy and safety of onabotulinumtoxin A in patients with neurogenic detrusor overactivity caused by spinal cord injury: a systematic review and meta-analysis. *Int Neurourol J* 2018;22(04):275–286
- 84 Pannek J, Göcking K, Bersch U. Sacral rhizotomy: a salvage procedure in a patient with autonomic dysreflexia. *Spinal Cord* 2010;48(04):347–348
- 85 Sharpe EE, Arendt KW, Jacob AK, Pasternak JJ. Anesthetic management of parturients with pre-existing paraplegia or tetraplegia: a case series. *Int J Obstet Anesth* 2015;24(01):77–84