

Resistant thyrotoxicosis: A case of sarcoidosis of thyroid

Uday Yanamandra, Narendra Kotwal¹, Anil Menon, Velu Nair

Department of Internal Medicine, Armed Forces Medical College, ¹Command Hospital (Southern Command), Pune, Maharashtra, India

ABSTRACT

Autoimmune endocrinopathies and, less commonly, thyroid autoimmune disease have been reported in patients with sarcoidosis. Similarities exist in the pathogenesis of these two conditions. Concomitant sarcoidosis in the thyroid gland in patients with Graves' disease may contribute to the resistance to antithyroid drugs and radioiodine therapy. We present the clinical, laboratory, imaging, and pathologic findings of a patient with Graves' disease who was unresponsive to medical management. This 37-year-old man presented with thyrotoxicosis. Thyroid hormone assays and ^{99m}Technetium findings were consistent with Graves' disease. He was also found to have hilar lymphadenopathy. Patient failed to achieve remission with high doses of antithyroid drugs and 2 sessions of radioiodine ablative therapy. Histopathology of lymph nodes disclosed noncaseating granulomas, consistent with sarcoidosis. Patient's thyrotoxicosis subsided only following steroid administration. The histopathology of the thyroid gland on aspiration and the subsidence of symptoms with steroids reiterate the possibility of thyroid sarcoidosis. This diagnosis needs biopsy for confirmation, which our patient didn't consent for.

Key words: Graves' disease, hyperthyroidism, sarcoidosis, thyroid sarcoid

INTRODUCTION

Sarcoidosis, a disease characterized by noncaseating granulomas, has been shown to be associated with other autoimmune disorders, especially autoimmune thyroid disease. Although endocrine autoimmunity has been reported in about 20% of the patients with sarcoidosis,^[1] direct involvement of the thyroid gland with sarcoidosis is rare. Postmortem studies indicate that the thyroid gland is involved in 4.2-4.6% of patients with sarcoidosis.^[2,3] The first case of involvement of the thyroid gland with sarcoidosis was reported in 1938.^[4] This report describes a case of pulmonary sarcoidosis in a patient with Graves' disease who was resistant to treatment with antithyroid

agents and radioiodine (RAI) therapy but responded to steroids. We discuss the pathogenesis of both entities and the possible link between them.

CASE REPORT

A 37-year-old male presented with weight loss, heat intolerance, excessive sweating, and palpitations of 6 months duration. Clinically, he was anxious, had tachycardia, brisk reflexes, and tremors. Thyroid profile revealed T₃ 2.58 ng/ml, T₄ 21.41 µg/dl, and TSH 0.02 mIU/L. Both lobes of thyroid were diffusely enlarged (measuring 5 × 2 cm) on USG. ^{99m}Technetium scan has shown uniformly increased uptake (36%). TSH receptor antibodies and anti-TPO antibodies were negative.

He was incidentally found to have bilateral hilar lymphadenopathy on chest X-ray [Figure 1a]. Clinically, the patient was reevaluated and was found to have no peripheral lymphadenopathy or any respiratory abnormality. Examination of the respiratory system was unremarkable. No evidence of involvement of skin, eyes, or central

Access this article online

Quick Response Code:



Website:
www.ijem.in

DOI:
10.4103/2230-8210.109662

Corresponding Author: Dr. Kotwal Narendra, Senior Adviser (Medicine and Endocrinology), Command Hospital (Southern Command), Pune - 411 040, Maharashtra, India. E-mail: narendrakotwal@gmail.com

nervous system was present. Montoux test and interferon gamma release assay were normal and sputum examination was negative for AFB by ZN stain. There was a fall of ESR by 8 mm in first hour. CECT chest done has revealed multiple homogenously enhancing enlarged lymph nodes [Figure 1b] in the mediastinum (maximum size 24 mm) and multiple well-defined nodules (2-4 mm in size) in perilymphatic distribution [Figure 1c and d]. Spirometry was normal, and diffusion/lung volumes were normal. Serum ACE was 106.0 IU/L (normal <60 IU/L). Ultrasound abdomen was normal and serum calcium was 8.9 mg/dl. 24-hour urinary calcium excretion was 3.96 g/day. Fiber optic bronchoscopy and transbronchial lung biopsy from right lower lobe superior segment was done. Histopathological examination revealed noncaseating granulomas consistent with sarcoidosis [Figure 2a-d]. Based on these, an impression of Graves' disease with sarcoidosis stage II was made. As he did not have any functional disability or vital organ involvement, no active treatment was contemplated for sarcoidosis at this juncture and was advised regular follow-up.

Patient underwent radioablation with 29 mCi of ^{131}I after initial trial of antithyroids for 2 years. In view of persistent clinical and hormonal profile of thyrotoxicosis, repeat dose of 26 mCi of ^{131}I was given 8 months later. The patient was kept under follow-up. However, symptoms persisted and hormonal profile continued to show hyperfunctioning thyroid gland. Repeat thyroid profile revealed T3 1.82 ng/ml, T4 22.9 $\mu\text{g/dl}$, and TSH 0.03 mIU/L. Thus, a possibility of thyroid sarcoidosis was considered in which the clinical features of toxicosis may be refractory to antithyroids and

radioablation. Patient was subjected to FNAC thyroid which revealed ill-formed elements of granulomatous tissue. Patient refused to undergo the biopsy of the thyroid gland. He was subjected to PET scan which revealed increased uptake in liver, spleen, and thyroid with "Lambda" and "Panda" sign [Figure 3].

Patient was given a trial with steroids (oral prednisolone at 1 mg/kg) and patient achieved euthyroidism 3 months after steroid therapy. Steroid therapy was gradually tapered over 6 months period. Patient persisted to be euthyroid on 1 year follow-up. Temporal profile of the thyroid status and various modalities of therapy are depicted in Figure 4.

DISCUSSION

Sarcoidosis is a multisystemic, chronic granulomatous disease of unknown cause, characterized by noncaseating granulomas affecting primarily lungs. Extrapulmonary involvement has commonly been seen in the skin, lymph nodes, eyes, and liver; however, any organ can be involved. Sarcoid involvement of the endocrine glands has seldom been found.^[5] Among the endocrine glands, infiltration of the pituitary, thyroid, and adrenal glands has been reported.^[6] Sarcoid involvement of the thyroid has been identified at the time of thyroidectomy, autopsies, and fine-needle aspiration biopsies.^[7-9] The first case of sarcoid infiltration of the thyroid was reported in 1938.^[4]

Concomitant occurrence of sarcoidosis of the thyroid gland and Graves' hyperthyroidism has rarely been reported. On review of the literature, we identified cases of sarcoidosis involving the thyroid gland in patients with Graves' disease, found after thyroidectomy or at autopsy.^[7,8,10,11] We found

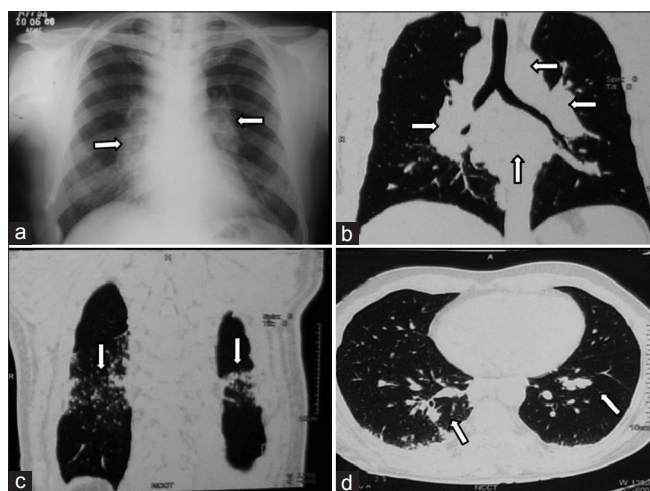


Figure 1: (a) Chest radiograph depicting bilateral hilar enlargement suggesting hilar lymphadenopathy. (b) Computed tomography chest reveals gross enlargement of pre- and paratracheal lymph nodes. (c) Computed tomography chest showing parenchymal involvement in bilateral lung fields in sagittal view. (d) Computed tomography chest showing nodular opacities with parenchymal involvement in bilateral lung fields in coronal view

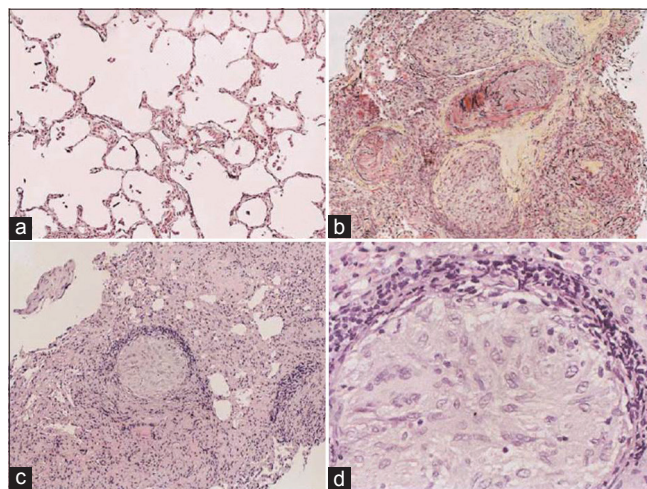


Figure 2: (a-d) Histopathology of the hilar lymph nodes on transbronchial biopsy. Hematoxylin and eosinophil staining suggests non caseating granulomas suggestive of sarcoidosis

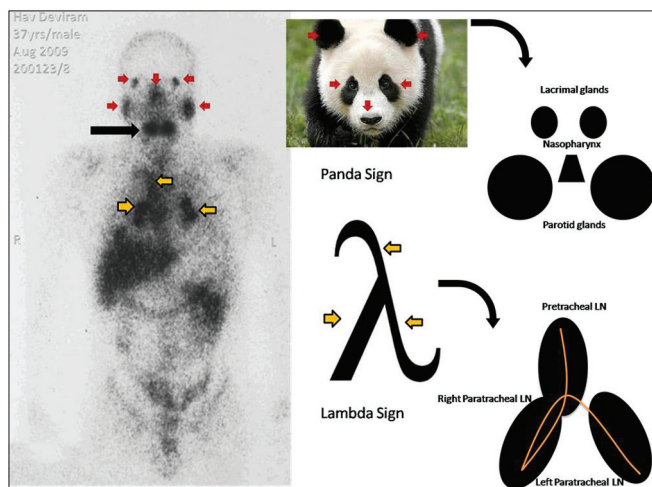


Figure 3: ⁶⁷Ga citrate PET scan revealing increase bilateral radionuclide uptake in the lacrimal and parotid glands and normal nasopharyngeal uptake showing the Panda sign (red arrows). Lambda sign is evident by increased uptake in the pre- and para tracheal lymph nodes (yellow arrows). Black arrow depicts the increased uptake in the thyroid glands

no case in which the presence of sarcoid granulomas in the thyroid gland influenced the clinical course of Graves' disease or the response to therapy.

Concomitant sarcoidosis of the thyroid and Graves' hyperthyroidism have rarely been reported.^[7,8,10,11] In a review of the world literature in 1993, Vailati *et al.*^[8] reported 40 cases of sarcoid involvement of the thyroid gland, and 13 of the patients presented with hyperthyroidism probably Graves' disease.^[7,11]

The pathogenesis of sarcoidosis resembles that of Graves' disease in some respects. Sarcoidosis is characterized by an increase in number of T cells in the granulomatous process. These T cells participate in the production of several cytokines and chemokines that are mediators of inflammation and cellular immune responses.^[12] The inability of the immune system to down regulate the proinflammatory process may be the basis for the observed increased prevalence of endocrine autoimmunity in the context of sarcoidosis.^[11] In Graves' disease, the intrathyroidal lymphocytic infiltrate is the initial abnormality where the T and B cells become activated. These activated cells express cytokines, which expand locally infiltrated thyroid antigen-specific cells capable of initiating the disease.^[13] It is possible that coexistence of sarcoidosis in the thyroid with Graves' disease could cause an exaggerated thyroid-specific T-cell activation and hyperthyroidism may ensue, with a suboptimal response to therapy.

Our patient presented with features of Graves' disease. He was incidentally detected to have sarcoidosis. He had poor response to radio-iodine ablation. We kept a suspicion of

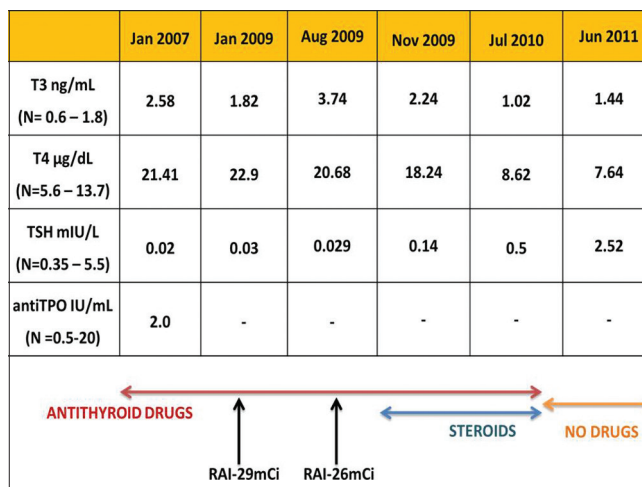


Figure 4: Temporal profile of the thyroid functions and the various modalities of therapy the patient was subjected to are depicted in a pictorial form

sarcoidosis involving the thyroid and exhibited steroids to the patient to which he responded. We believe that the sarcoid of the thyroid was responsible for persistence of his symptoms despite adequate radioablation. The patient responded well to steroids (prednisolone 1 mg/kg) with complete resolution of thyrotoxic symptoms and pulmonary lesions. This therapeutic resolution further reiterates the diagnosis of sarcoidosis of thyroid which requires biopsy for firm diagnosis.

It is likely that simultaneous thyrostatic medication reduces the efficacy of ¹³¹I, as does restarting it within 7 days.^[14] Propylthiouracil would seem to have a more prolonged radioprotective effect than carbimazole, necessitating higher doses of ¹³¹I, unless discontinued at least 2 weeks beforehand.^[15] Methimazole was shown to have a radioprotective effect not only by its scavenger capacity but also by interaction with sodium iodine symporter (NIS).^[16] For these above mentioned reasons, our patient was subjected to high doses of RAI when compared with the conventional doses. Also, there is anecdotal evidence that patients maintained on antithyroid drugs for many years before being treated with ¹³¹I (as in our case) often fail to respond to repeated doses of 400 MBq (11 mCi) or more.^[17-19] This apparent radioresistance is likely to be a consequence of a relative iodine deficiency within the gland and resultant increase in thyroidal iodine turnover rate, reducing the anticipated dose of radiation.^[17-26] The duration of therapy required to involve such a mechanism is not known, but presumably will also depend upon the iodine status of the population being treated.^[16]

CONCLUSION

Autoimmune endocrinopathies and, less commonly, thyroid autoimmune disease have been reported in patients

with sarcoidosis. The initial clinical manifestation in cases of sarcoid involvement of the thyroid gland may be hypothyroidism, thyroiditis, or Graves' disease. Similarities in the pathogenesis of Graves' disease and sarcoidosis may explain the prevalence of thyroid autoimmunity in patients with sarcoidosis, even in the absence of thyroid involvement. Thyroid sarcoidosis should be considered in a patient of thyrotoxicosis with concomitant pulmonary sarcoidosis not responding to antithyroid drugs/RAI therapy. Concomitant Graves' disease and sarcoidosis of the thyroid may lead to an unusual or suboptimal clinical response of Graves' disease to different treatment modalities, such as in our current patient.

ACKNOWLEDGEMENT

We thank the Department of Pathology and Respiratory Medicine of our college for the support provided in management of this case. We also thank the patient for providing permission to publish this case.

REFERENCES

- Papadopoulos KI, Hornblad Y, Liljebadh H, Hallengren B. High frequency of endocrine autoimmunity in patients with sarcoidosis. *Eur J Endocrinol* 1996;134:331-6.
- Vogt H. Morbus Besnier-Boeck-Schaumann: Klinische und pathologische-anatomische Studie. *Helv Med Acta* 1949; 25 Suppl: S1-110.
- Branson JH, Park JH. Sarcoidosis hepatic involvement: Presentation of a case with fatal liver involvement; including autopsy findings and review of the evidence for sarcoid involvement of the liver as found in the literature. *Ann Intern Med* 1954;40:111-45.
- Spencer J, Warren S. Boeck's sarcoid: Report of a case, with clinical diagnosis confirmed at autopsy. *Arch Intern Med* 1938;62:285-96.
- Baughman RP, Teirstein AS, Judson MA, Rossman MD, Yeager H Jr, Bresnitz EA, *et al.*; Case Control Etiologic Study of Sarcoidosis [ACCESS] Research Group. Clinical characteristics of patients in a case control study of sarcoidosis. *Am J Respir Crit Care Med* 2001;164:1885-9.
- Bell NH. Endocrine complications of sarcoidosis. *Endocrinol Metab Clin North Am* 1991;20:645-54.
- Zimmermann-Belsing T, Christensen L, Hansen HS, Kirkegaard J, Blichert-Toft M, Feldt-Rasmussen U. A case of sarcoidosis, sarcoid granuloma, papillary carcinoma, and Graves' disease in the thyroid gland. *Thyroid* 2000;10:275-8.
- Vailati A, Marena C, Aristia L, Sozzé E, Barosi G, Inglese V, *et al.* Sarcoidosis of the thyroid: Report of a case and a review of the literature. *Sarcoidosis* 1993;10:66-8.
- Winnacker JL, Becker KL, Katz S. Endocrine aspect of sarcoidosis. *N Engl J Med* 1998;278:483-92.
- Karlish AJ, Mac Gregor GA. Sarcoidosis, thyroiditis, and Addison's disease. *Lancet* 1970;2:330-3.
- Yarman S, Kahraman H, Tanakol R, Kapran Y. Concomitant association of thyroid sarcoidosis and Graves' disease. *Horm Res* 2003;59:43-6.
- Ziegenhagen MW, Muller-Quernheim J. The cytokine network in sarcoidosis and its clinical relevance. *J Intern Med* 2003;253:18-30.
- Braverman LE, Utiger RD. Introduction to thyrotoxicosis. In: Braverman LE, Utiger RD, editors. *Werner and Ingbar's The Thyroid: A Fundamental and Clinical Text*. 9th ed. Philadelphia, PA: Lippincott Williams and Wilkins; 2005. p. 457-73.
- Imseis RE, Vanmiddlesworth L, Massie JD, Bush AJ, Vanmiddlesworth NR. Pretreatment with propylthiouracil but not methimazole reduces the therapeutic efficacy of iodine-131 in hyperthyroidism. *J Clin Endocrinol Metab* 1998;83:685-7.
- Kahmann C, Wunderlich G, Freudenberg R, Zöphel K, Oehme L, Kotzerke J. Radioprotection of thyroid cells mediated by methimazole. *Int J Radiat Biol* 2010;86:811-6.
- Bonnema SJ, Bartalena L, Toft AD, Hegedü SL. Controversies in radioiodine therapy: Relation to ophthalmopathy, the possible radioprotective effect of antithyroid drugs, and use in large goiters. *Eur J Endocrinol* 2002;147:1-11.
- Tamagna EI, Levine GA, Hershman JM. Thyroid-hormone concentrations after radioiodine therapy for hyperthyroidism. *J Nucl Med* 1979;20:387-91.
- McDermott MT, Kidd GS, Dodson LE Jr, Hofeldt FD. Radioiodine-induced thyroid storm: Case report and literature review. *Am J Med* 1983;75:353-9.
- Stensvold AD, Jorde R, Sundsfjord J. Late and transient increases in free T4 after radioiodine treatment for Graves' disease. *J Endocrinol Invest* 1997;20:580-4.
- Santos RB, Romaldini JH, Ward LS. Propylthiouracil reduces the effectiveness of radioiodine treatment in hyperthyroid patients with Graves' disease. *Thyroid* 2004;14:525-30.
- Crooks J, Buchanan WW, Wayne EJ, Macdonald E. Effect of pretreatment with methylthiouracil on results of I131 therapy. *Br Med J* 1960;5167:151-4.
- Hancock LD, Tuttle RM, LeMar H, Bauman J, Patience T. The effect of propylthiouracil on subsequent radioactive iodine therapy in Graves' disease. *Clin Endocrinol (Oxf)* 1997;47:425-30.
- Tuttle RM, Patience T, Budd S. Treatment with propylthiouracil before radioactive iodine therapy is associated with a higher treatment failure rate than therapy with radioactive iodine alone in Graves' disease. *Thyroid* 1995;5:243-7.
- Allahabadi A, Daykin J, Sheppard MC, Gough SC, Franklyn JA. Radioiodine treatment of hyper-thyroidism--prognostic factors for outcome. *J Clin Endocrinol Metab* 2001;86:3611-7.
- Andrade VA, Gross JL, Maia AL. The effect of methimazole pretreatment on the efficacy of radioactive iodine therapy in Graves' hyperthyroidism: One-year follow-up of a prospective, randomized study. *J Clin Endocrinol Metab* 2001;86:3488-93.
- Braga M, Walpert N, Burch HB, Solomon BL, Cooper DS. The effect of methimazole on cure rates after radioiodine treatment for Graves' hyperthyroidism: A randomized clinical trial. *Thyroid* 2002; 12:135-9.

Cite this article as: Yanamandra U, Kotwal N, Menon A, Nair V. Resistant thyrotoxicosis: A case of sarcoidosis of thyroid. *Indian J Endocr Metab* 2013;17:332-5.

Source of Support: Nil, **Conflict of Interest:** None declared.