

Vascular Anatomy and Clinical Application of the Free Proximal Ulnar Artery Perforator Flaps

Yitao Wei, MD*
 Xiaotian Shi, MD†
 Yaling Yu, MD‡
 Guiwu Zhong, MD§
 Maolin Tang, MD‡
 Jin Mei, MD, MSc‡

Background: There is a dearth of detailed published work on the anatomy of ulnar artery perforators. The objective of this study was to fully document the vascular basis of the free proximal ulnar artery perforator flap and report its use in reconstruction of the hand.

Methods: (1) The ulnar artery perforators were studied in 25 fresh cadavers and 10 cast preparations. Cadavers were injected with lead oxide for 3-dimensional reconstruction. The origin, course, and distribution of the ulnar artery perforators were comprehensively documented. (2) Between August 2011 and January 2013, 29 free proximal ulnar artery perforator flaps were utilized for reconstruction of soft-tissue defects of the hand in 25 patients. Flap size varied from 3.5 × 2.0 cm to 24.0 × 4.0 cm, with a consistent thickness of approximately 3 mm.

Results: (1) There were 7 ± 2.0 ulnar artery perforators. The average external diameter was 0.6 ± 0.2 mm. Each perforator supplied an average area of 26 ± 7.0 cm². Extensive anastomoses were found between the ulnar artery perforators and multiple adjacent source arteries. (2) All flaps survived. The clinical results were satisfactory after 10.2 ± 5.3 months of follow-up. The flaps were considered cosmetically acceptable by both patients and doctors.

Conclusions: The main advantage of the proximal ulnar artery perforator flap is that it is a thin flap that is ideal for upper extremity reconstruction, either as proximally or distally based local perforator flap or as a free flap. The donor site is excellent, and the vascular anatomy is very consistent. (*Plast Reconstr Surg Glob Open* 2014;2:e179; doi: 10.1097/GOX.000000000000113; Published online 9 July 2014.)

Wounds of the hands and fingers are a common challenge for most hand surgeons, and frequently, the wounds are complex and extensive. Larger soft-tissue defects of the fingers and hands are generally reconstructed by pedicled or free flaps.¹⁻³ Gao et al⁴ described a trilobar combined flap based on the circumflex scapular vessels to cover an extensive defect of the palm and volar aspect of the fingers. Stahl et al⁵ reported the

reconstruction of complex hand trauma using an iliac crest bone graft and 2 pedicled fasciocutaneous skin flaps. Recently, Wang et al⁶ and Yang et al⁷ reported the reconstruction of hand defects with the free medial sural artery perforator flaps and anterolateral leg perforator flaps, respectively. These ideas are good in theory, but the flap donor sites are far from the hand. There are possible reconstructive options that could be undertaken in the upper limb,

From the *Hand and Foot Trauma Surgery Hospital, Nanhai, Guangdong, People's Republic of China; †Department of Anatomy, Hainan Medical College, Haikou, Hainan, People's Republic of China; ‡Department of Anatomy, Wenzhou Medical University, Wenzhou, Zhejiang, People's Republic of China; and §Department of Orthopedics, Affiliated Hospital of Air Force Institute of Aviation Medicine, Beijing, People's Republic of China.

Received for publication July 16, 2013; accepted April 8, 2014.

Copyright © 2014 The Authors. Published by Lippincott Williams & Wilkins on behalf of The American Society of Plastic Surgeons. *PRSGO Global Open* is a publication of the American Society of Plastic Surgeons. This is an open-access article distributed under the terms of the Creative Commons Attribution-NonCommercial-NoDerivatives 3.0 License, where it is permissible to download and share the work provided it is properly cited. The work cannot be changed in any way or used commercially.

DOI: 10.1097/GOX.000000000000113

including the posterior interosseous forearm flap,⁸ the dorsal ulnar artery flap,⁹ the radial artery pedicle perforator flap,³ the ulnar artery perforator flap,¹⁰ and the neurocutaneous flap in upper extremities.¹¹ The advantages of using upper limb flaps include superior color and thickness match and the possibility of using a local pedicled perforator flap rather than a free microvascular transfer.

Several authors have recently reported on the anatomy of the perforators of the ulnar artery.^{12–14} Yu et al¹⁴ described the anatomy of the ulnar artery perforators and classed them as A, B, and C in 3 areas from the pisiform to epicondyle. Mathy et al¹² showed the position and number of the ulnar artery perforators in the area within 3 cm of the midpoint between the medial epicondyle and the pisiform. Sun et al¹³ demonstrated that the ulnar artery has 2 main clusters of perforators in the proximal one-third and distal one-fourth of the forearm. These showed that the ulnar artery perforator flap is an excellent source of thin, pliable, and sensate skin with favorable tissue characteristics, easy to harvest, and low donor-site morbidity. However, a large, systematic, and detailed investigation of the ulnar artery perforators has not been performed. To date, no study has shown that each perforator supplied an area and extensive anastomoses between the ulnar artery perforators and multiple adjacent source arteries. There also has not been a 3-dimensional anatomical study of the ulnar artery perforators. Therefore, we describe a digitalized model of perforator flaps of the forearm using angiography and a 3-dimensional imaging technique, Mimics (Materialise, Leuven).¹⁵ The advantage of this technique includes its clear display of vascular network of the source artery with its adjacent vessels. The objective of this report is to comprehensively document the 3-dimensional anatomy of the proximal ulnar artery perforators and to demonstrate the clinical applications of proximal ulnar artery perforator flap.

Disclosure: *This work was supported by the National Natural Science Foundation of China (31371214); the Science Technology Department of Zhejiang Province (LY13H150008); the Hand and Foot Surgery Department of Nanhai Hospital; and the Department of Anatomy, Wenzhou Medical University. The Article Processing Charge was paid for by Grants from the National Natural Science Foundation of China (31371214) and the Science Technology Department of Zhejiang Province (LY13H150008).*

ANATOMY PROTOCOL

The ulnar artery perforators were investigated in 25 fresh cadavers and 10 casts of arteries. Twenty-five cadavers (50 sides, 8 women and 17 men; mean age, 71 years; range, 50–88 years; mean height, 168 cm; range, 156–182 cm) were obtained through the Wenzhou Medical University Donor Program. Ten arterial casts of arteries of the upper limb were prepared. The project was approved by the institutional health sciences human Ethics Committee.

Fifteen fresh cadavers underwent whole-body lead oxide injection. The injection technique was originally described by Rees and Taylor¹⁶ and modified by Tang et al.^{17,18} Then, cadavers were scanned using spiral computed tomography (General Electric Lightspeed H16; General Electric Medical Systems, Milwaukee, Wis.). Three-dimensional reconstructions of the forearm were then performed using MIMICS software (Materialise, Leuven).¹⁵ Ten specimens received whole-body injection with red latex.

All 25 specimens were dissected and 3-dimensional radiography was performed in a layer-by-layer fashion to document each perforator in the proximal forearm.¹⁷ The origin, course, and distribution of the perforators in the forearm region were observed.

Dissection and Image Processing

The anterior forearm was defined by the following anatomical landmarks (Fig. 1): proximal horizontal line across the level of the medial epicondyle and distal horizontal line across the level of the pisiform. The region between the superior and inferior border was divided into 3 equal zones (proximal, middle, and distal).

Digitalization and assembly of the angiograms were performed in Adobe Photoshop.¹⁷ To outline vascular territories, we combined the cutaneous angiosome concept with the 6 physiologic criteria of Cormack and Lamberty.^{19,20} The vascular territory of one angiosome ends at the anastomotic site of the next angiosome.

Cutaneous angiosomes and perforator zones were measured using Scion Image (Scion Corporation, Frederick, Md.),¹⁷ which is an image processing and analysis program. It can acquire, display, edit, enhance, analyze, and animate images. Scion Image can be used to measure area, mean, centroid, perimeter, and other characteristics of user-defined regions of interest. Spatial calibration is supported to provide area and length measurements. In addition, the options dialog box can be used to enable other measurements, such as perimeter. The area of the selection will be given in calibrated units, such as square millimeters, if the set scale command has been used to establish the spatial scale. Finally, the

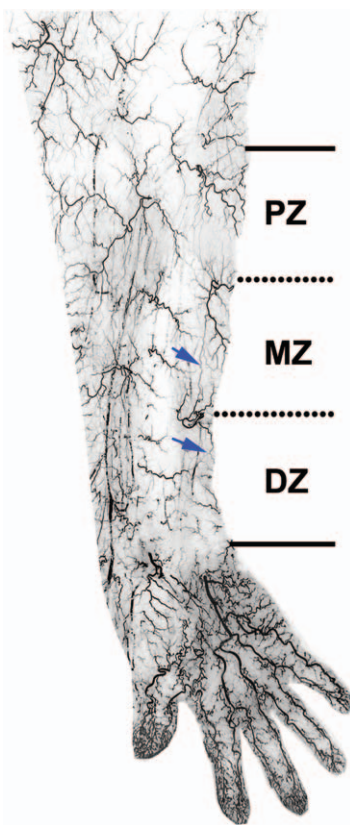


Fig. 1. Angiogram of the integument of the anterior forearm and hand. The region between the superior and inferior border was divided into 3 equal zones: proximal horizontal line across the level of the medial epicondyle, distal horizontal line across the possible level of the pisiform. PZ indicates proximal zone; MZ, middle zone; DZ, distal zone. Blue arrows indicate the links of the ulnar artery perforators. Ulnar recurrent artery was shown in the proximal zone.

show results feature can be used to display the list of measurement results.

PATIENTS AND METHODS

Between August 2011 and January 2013, we used 29 free proximal ulnar artery perforator flaps for reconstruction of soft-tissue defects of the hand in 25 patients. The patients' clinical data are summarized in Table 1. There were 18 men (72%) and 7 women (28%) with a mean age of 32.3 ± 7.7 years (range, 18–48 years). The size of the defects ranged from 2.5×2.0 cm to 12.0×3.0 cm. The soft-tissue defects were on the fingers [23 of 25 (92%)], on the palm [1 of 25 (4%)], and on the dorsum of the hand [1 of 25 (4%)]. The causes of the defects were crush injury [13 of 25 (52%)], machine injury [11 of 25 (44%)], and burn [1 of 25 (4%)]. The size of the flaps ranged from 3.5×2.0 cm to 24.0×4.0 cm. All the transferred perforator flaps were nourished with the perforator vessel of the ulnar artery. Most flaps were

long strips, and donor sites were closed primarily in 25 of 29 cases (86%) and skin grafted in 4 of 29 cases (14%). The patient follow-up was between 4 and 20 months (mean, 10 months).

Operative Technique

A line connecting the pisiform and the volar aspect of the medial epicondyle was drawn. Based on our digitalized model of the perforators, the point of emergence of the major perforator was usually located in the area of the anteromedial forearm. It was at the intersection of the proximal and middle thirds or at the junction of the middle and distal thirds along the axis between the pisiform and the medial epicondyle (Figs. 1–3). The flap design was modified once the perforator location was determined by high-frequency color ultrasound.

Flap elevation begins with an incision along the radial aspect of the flap. Suprafascial dissection proceeds ulnarward until the perforators can be visualized. The medial cutaneous nerve of the forearm is preserved in the flap as far as possible. The flap design is recentered, if necessary, based on the actual location of the perforators. Slightly radial to the perforators, the fascia is incised and the septum entered, exposing the ulnar vessels and nerve. Once an adequate pedicle length and suitable caliber of the perforator and its vena comitans has been achieved, the medial (ulnar) border of the flap is incised and the flap is detached. Great care is taken to avoid injury to the ulnar nerve. The tourniquet is then released to allow the hand and flap to reperfuse before dividing the vascular pedicle. After detaching the flap, the pedicle vessels are anastomosed with those of the recipient site. When possible, we attempt to improve innervation with sensory nerve anastomosis. The donor-site defect can be closed directly if the flap width is less than approximately 5 cm.

RESULTS

The cutaneous blood supply of the forearm is provided by a rich vascular network lying beneath the subcutaneous tissue and the underlying fascia (Figs. 1 and 2). The anteromedial area of the forearm is supplied by the ulnar artery. The proximal ulnar artery has several branches, including perforators that are directly derived from the ulnar artery and anterior ulnar recurrent arteries. There are 4–9 perforators from the ulnar artery, supplying an area of approximately 190 cm^2 . Each perforator supplied an average area of $26 \pm 7.0 \text{ cm}^2$. The mean superficial perforator pedicle length was $27 \pm 14 \text{ mm}$. There were 7 ± 2.0 ulnar artery perforators with diameters of greater than or equal to 0.5 mm. The average external diameter

Table 1. Summary of Clinical Details*

Case	Age (yr)	Sex	Etiology	Location	Defect Size (cm)	Flap/Size (cm)	Thickness (mm)	Pedicle Length (cm)	Donor-site Closure
1	48	M	Crush injury	Right index finger	3.3×2.3	4.0×3.1	3.0	3.6	Direct suture
2	23	M	Planer injury	Right middle, ring, and little fingers	Ring 4.5×2.0	5.0×2.0	3.2	3.6	Direct suture
3	32	F	Crush injury	Left thumb	3.0×2.0	3.5×2.0	3.0	2.5	Direct suture
4	25	M	Crush injury	Left middle finger	4.0×3.0	4.5×3.5	2.6	3.0	Direct suture
5	32	M	Avulsion injury	Left thumb	7.0×3.0	7.0×3.5	2.5	3.8	Direct suture
6	32	F	Crush injury	Right finger	6.5×3.0	7.0×3.5	3.2	3.5	Direct suture
7	26	M	Hot crush injury	Left hand back	9.0×5.0	10.0×5.0	2.5	3.5	Direct suture
8	32	F	Crush injury	Left middle finger	2.5×2.0	3.0×2.5	3.5	3.0	Direct suture
9	32	F	Crush injury	Right middle finger	5.0×3.0	5.5×3.0	2.5	3.5	Direct suture
10	38	M	Crush injury	Left thumb	5.0×1.5	5.0×2.0	3.0	3.0	Direct suture
11	45	F	Crush injury	Left index finger	5.0×3.0	5.5×3.0	2.8	3.0	Direct suture
12	25	M	Crush injury	Left index finger	6.5×4.5	11.0×3.5	2.8	3.0	Direct suture
13	45	M	Crush injury	Right thumb	3.0×4.5	3.5×4.5	2.5	3.5	Direct suture
14	23	M	Crush injury	Left thumb	6.0×3.0	8.0×2.5	3.0	3.9	Direct suture
15	32	M	Industrial accident	Left index finger	2.5×5.0	6.0×2.5	2.8	3.0	Direct suture
16	30	F	Crush injury	Right middle finger	6.5×5.0	9.0×3.5	3.0	2.8	Direct suture
17	45	M	Electric saw injury	Right index finger	3.0×6.0	6.5×3.0	2.8	3.0	Direct suture
18	35	M	Planer injury	Right middle finger	9.0×3.0	10.0×3.0	3.0	3.5	Direct suture
19	35	M	Destructive industrial accident	Right index, middle, and ring fingers	Index 5.5×6.0 Middle 7.0×6.0 Ring 7.0×6.0	Left forearm 13.0×3.0 Right forearm 24.0×4.0	Left 2.5 Right 2.5	Left 3.0 Right 3.2	Direct suture
20	25	M	Crush injury	Right index finger	6.0×6.0	10×3.5	2.8	3.2	Direct suture
21	25	M	Industrial accident	Right middle and ring fingers	Middle 10×4.0 Ring 8.0×6.5	20.0×5.0	3.0	Proximal based 3.5 Distal based 3.0	Direct suture
22	35	M	Strangulation injury	Left index and middle fingers	Middle 5.0×6.0 Index 2.0×6.0	Proximal based 5.0×3.0 Distal based 10.0×3.0	2.8	Proximal based 3.5 Distal based 3.0	Skin graft
23	18	M	Third-degree burns	Right index and middle fingers	Middle 5.0×2.0 Index 4.0×2.0	11.0×2.5	3.0	3.5	Direct suture
24	34	M	Electric saw injury	Right middle finger	6.0×3.5	6.0×4.0	3	4.0	Direct suture
25	36	F	Strangulation injury	Left second to fifth fingers and palm	Palm 12.0×3.0 Index 3.0×6.0 Ring 4.5×6.0 Little 4.0×6.0	Left forearm 23.0×3.5 Right forearm 24.0×3.5	Left 3.0 Right 3.0	Left 3.0 Right 2.8	Skin graft

*There were no complications.

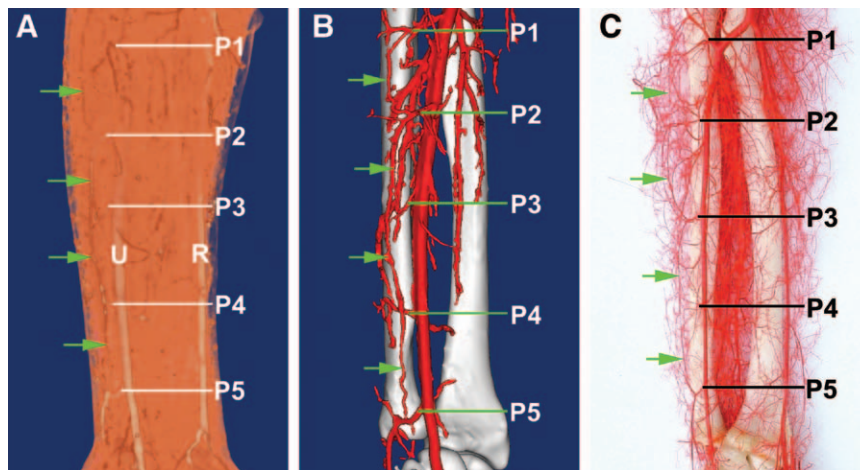


Fig. 2. The ulnar artery perforators and perforator chain (green arrows). A, Three-dimensional reconstruction of forearm by fast volume rendering technique (VRT) to show subcutaneous vascular network. B, Three-dimensional reconstruction by surface rendering technique (same specimen with A). C, A vascular cast specimen of arteries of the forearm. U indicates ulnar artery; R, radial artery; P1–5, ulnar artery perforators.

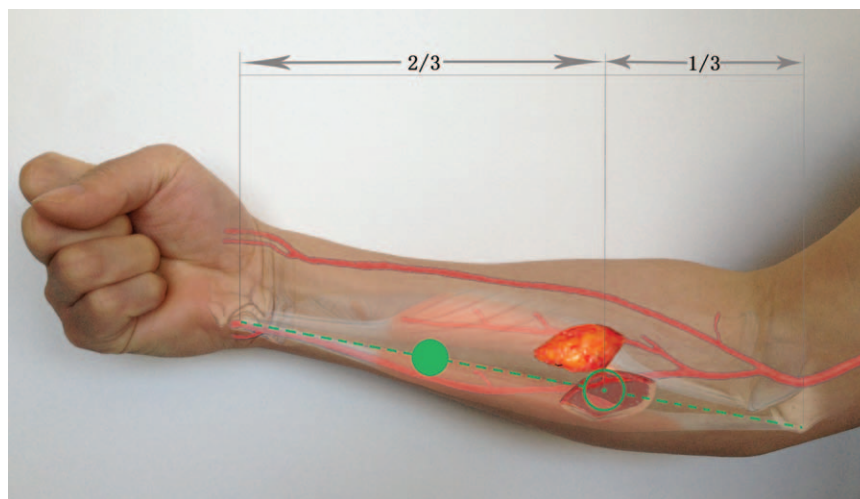


Fig. 3. Schematic diagram of the free proximal ulnar artery perforator flap. Green circles indicate the junction of the proximal and middle thirds and the junction of the middle and distal thirds of the distance between the pisiform and the medial epicondyle, respectively. Both are locations of the consistent ulnar artery perforators, and a free proximal ulnar artery perforator flap is shown.

was 0.6 ± 0.2 mm. Our data clearly show that greater and constant perforators are located at the junction of the proximal and middle thirds of the axis between the pisiform and the medial epicondyle (Figs. 1–3).

The Ulnar Artery Perforators

The ulnar artery was present in all specimens. The larger branch of the ulnar artery was the anterior ulnar recurrent artery at the proximal third of anteromedial forearm. It supplied the medial aspect of the elbow (Figs. 1 and 2). There were 2 ± 1 perforators in

the ulnar recurrent artery territory. The mean vessel diameter was 0.8 ± 0.2 mm. In 85% (51 of 60) of the specimens, we found 5 consistent perforators, which we marked as P1–5. P2 and P4 were located around the junction of the proximal and middle thirds and the junction of the middle and distal thirds of the distance between the pisiform and the medial epicondyle, respectively. P3 was found in middle third zone. In fact, P1 is the anterior ulnar recurrent artery,²¹ and P5 is the dorsal ulnar artery^{22,23} or the so-called above-wrist cutaneous branch of the ulnar artery.²⁴

The diameter of P2, P4, and P5 was 0.7 ± 0.2 , 0.6 ± 0.3 , and 1.0 ± 0.4 mm, respectively. These perforators anastomosed with each other to form a longitudinal perforator chain (Fig. 2).

Case Reports

All proximal ulnar artery perforator flaps were transferred to defects in the hand without any complications. The clinical results were satisfactory after 4–20 months of follow-up (Table 1). All flaps in this series were thin, 2.9 ± 0.3 mm (range, 2.5–3.5 mm). The pedicle length was 3.3 ± 0.4 mm (range, 2.5–4.0 mm). The flaps were considered cosmetically acceptable by both patients and physicians. The flaps healed well, and the color match between flap and surrounding skin was excellent (Figs. 4 and 5). The donor site also healed well, and the scars were quite inconspicuous in the forearm.

Case 1 (Patient 2). A 23-year-old man was admitted emergently with a soft-tissue defect over the right middle, ring, and little fingers that resulted from a planer injury. The distal third of the little finger was destroyed, and the middle and ring fingers were contused, with skin defects 4.5×2.0 cm. The middle finger was repaired by a full-thickness skin graft. The

ring finger was covered by a free proximal ulnar artery perforator flap (5.0×2.0 cm, 2.5 mm thick). The pedicles of the flap were anastomosed to the ulnar digital artery and the superficial dorsal vein. The flap and donor site healed well, with no complications. Six months after surgery, the flap and the recipient site matched well (Fig. 4).

Case 2 (Patient 19). A 35-year-old man was admitted emergently with right index, middle, and ring fingers destruction that was the result of an industrial accident. Debridement and fracture fixation were performed in the 3 fingers. After the operation, nonviable and nonreplantable soft tissue was removed (Fig. 5). The skin defect sizes were 5.5×6.0 cm, 7.0×6.0 cm, and 7.0×6.0 cm in the index, middle, and ring finger, respectively. Two free proximal ulnar artery perforator flaps were designed and harvested from both forearms. The size of the flap was 24.0×4.0 cm and 13.0×3.0 cm from right and left forearms, respectively (Fig. 5). The right ring finger was covered by the left forearm flap (13.0×3.0 cm, 2.5 mm thick). The pedicle of the flap was anastomosed to the ulnar digital artery and the superficial dorsal vein. The medial cutaneous nerve

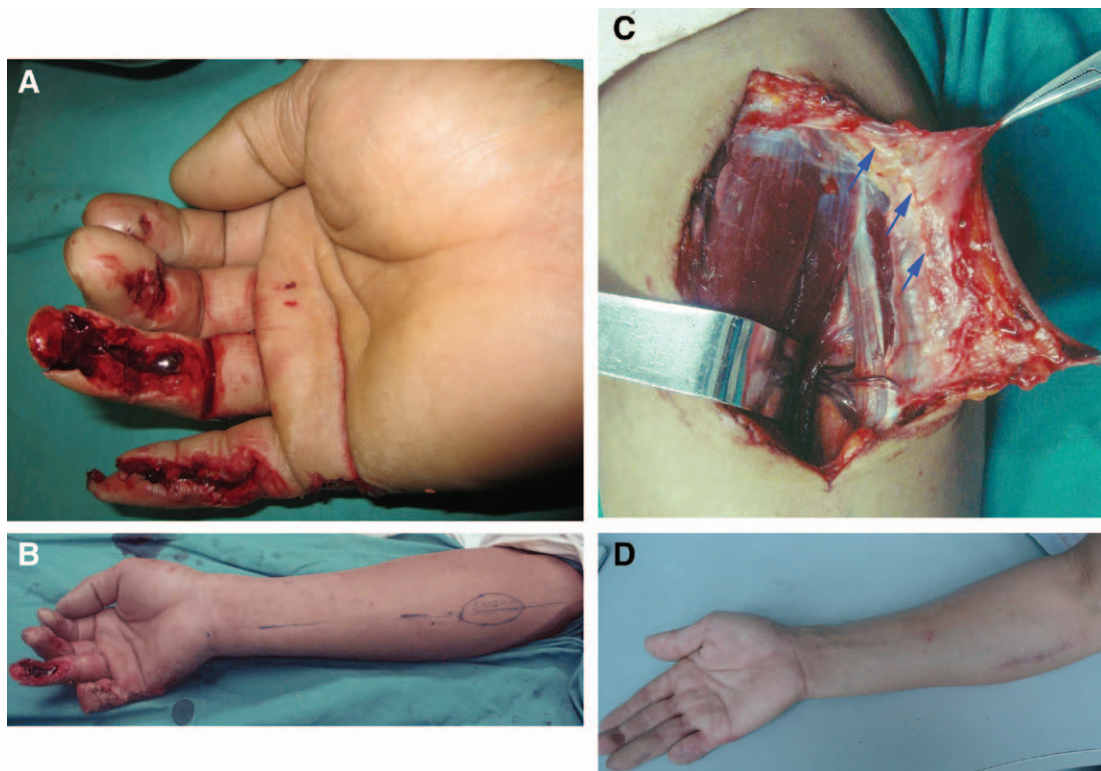


Fig. 4. Case 1. A free proximal ulnar artery perforator flap was used for coverage of a defect over the right ring finger. A, Preoperative view of the soft-tissue defect over the right middle, ring, and little fingers. B, Anatomical landmark and perforator flap design after the little finger amputation. C, The perforator nourishing the proximal ulnar artery perforator flap had been dissected. Blue arrows pointed to the medial cutaneous nerve of the forearm in the flap. D, Appearance of the flap and donor site 6 months after surgery.

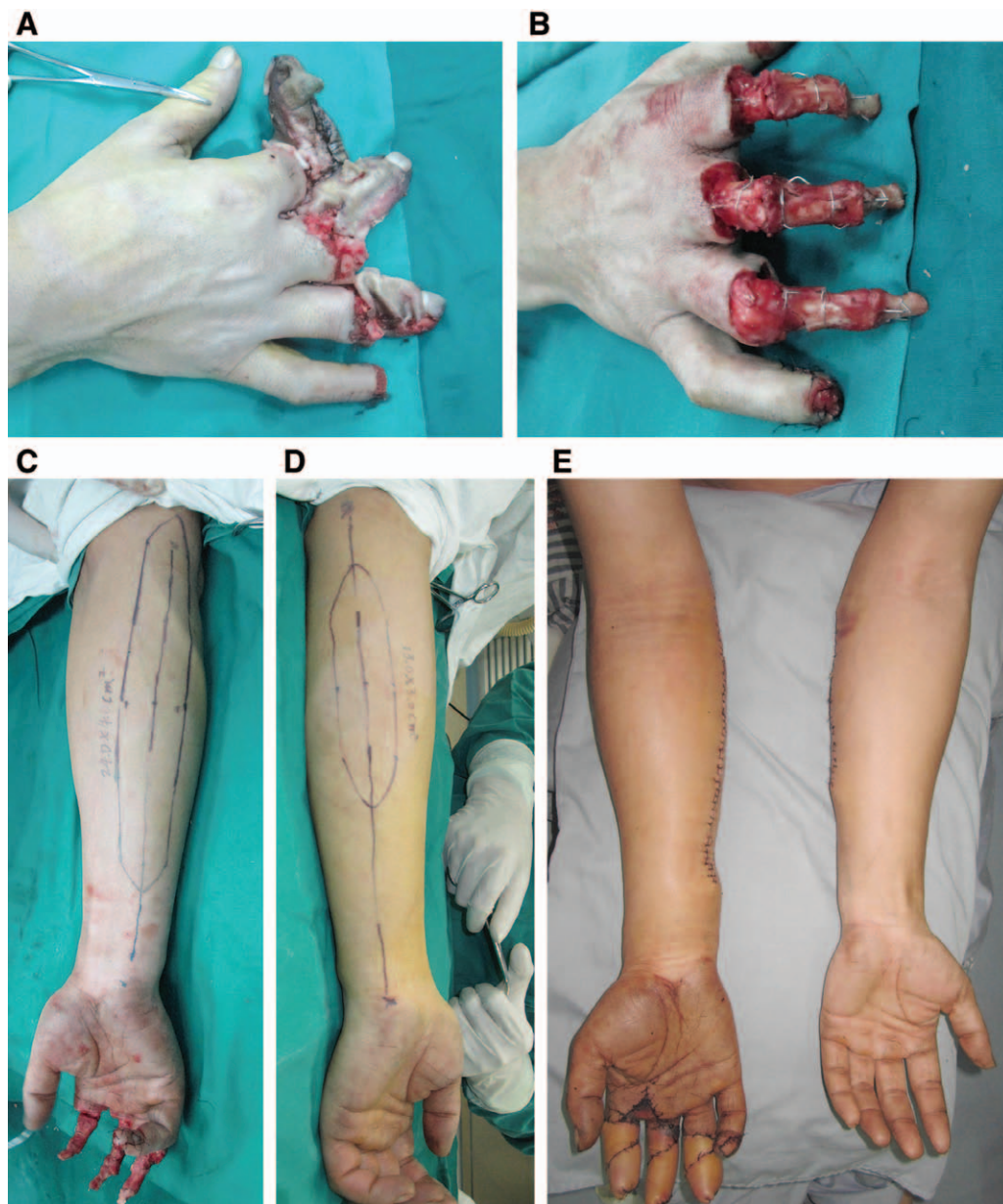

Fig. 5. Case 2. Two free ulnar artery perforator flaps were used for coverage of a right index, middle, and ring fingers destruction. A, Preoperative view of the extensive devastating injuries that was the result of an industrial accident. B, After debridement and fracture fixation of the 3 fingers. C and D, Anatomical landmark and 2 perforator flap design. E, View of the flaps postoperatively.

of the forearm was anastomosed to the ulnar digital nerve. There were 2 pedicles in the right forearm flap (24.0×4.0 cm, 2.5 mm thick). The proximal pedicle was anastomosed to the ulnar digital artery and the superficial dorsal vein of the index finger to repair the index finger. The medial cutaneous nerve of the forearm was anastomosed to the ulnar digital nerve. Another pedicle was anastomosed to the radial digital artery and superficial dorsal vein of the middle finger. The flaps and the donor sites healed well, with no complications. Four months

after surgery, the flaps and the recipient sites were well matched.

DISCUSSION

Characteristics of the Ulnar Artery Perforators

The perforators of the ulnar artery pierce the deep fascia in longitudinal rows along with the medial cutaneous nerve of the forearm. The majority (69%) are musculocutaneous perforators.^{21,25} The musculocutaneous perforators in the proximal forearm passed to

the skin after a short intramuscular course through the flexor carpi ulnaris or flexor digitorum superficialis muscle belly. The others were septocutaneous perforators. Because skin and nerves both originate from the ectoderm, their intimate relationship in the vascular supply is not surprising.¹¹ In general, the paraneural vascular arcade was more developed in the proximal and middle thirds of the forearm. The paraneural vessels linked the cutaneous perforators to form a longitudinal perforator chain (Fig. 2). We found 5 consistent perforators; 2 perforators were located around the junction of the proximal and middle thirds and the junction of the middle and distal thirds of the distance between the pisiform and the medial epicondyle, respectively. The perforators increase in number and decrease in size more distally except the dorsal ulnar artery. Generally, the distribution of the musculocutaneous perforators is branch style and the distribution of the septocutaneous perforators is axial. With the same diameter, the area of the flap supplied by branch-style artery is larger than the one supplied by the axial-style artery.²⁶ Due to the reliability of the vasculature of the proximal ulnar artery perforator flap, its thinness, and the ability to close the donor site, it has become our first choice to cover soft-tissue defects of the hand.

The New Design of the Ulnar Artery Perforator Flaps

In this study, the greater and constant perforators are located at 2 junctions: the junction of the proximal and middle thirds and the junction of the middle and distal thirds of the distance between the pisiform and the medial epicondyle (Figs. 1–3). Extensive anastomoses were found between the perforators and multiple adjacent source arteries. Most of these vessels also communicate in the skin. This offers surgeons multiple perforator options for any given paddle of skin in this area, although we have only used free proximal ulnar artery perforator flap, as follows:

1. Free ulnar artery perforator flap based on P1–3 or others close to proximal as near as possible.
2. Proximally based perforator flap or propeller flap based on P1, which is also known as the ulnar recurrent artery. This perforator has true anastomoses with P2 and/or P3 along the medial cutaneous nerve of the forearm, so its cutaneous perforator allows a long arc of rotation, extending the flap as far proximally as the medial side of the elbow.
3. Distally based perforator flap based on P5, the dorsal ulnar artery. The P4 anastomoses with ascending branch of the dorsal ulnar artery. It is easy to harvest a perforator-based propeller flap for repairing hand defects.

Both the proximally and distally based perforator flaps have 2 distinct advantages. Not only do they save the ulnar artery but they also allow arterial and venous flow in physiologic directions. This avoids the need for a venous anastomosis at the recipient site.

The maximum size possible for ulnar artery perforator flap is unknown. However, the largest flap in this series was 24.0 × 4.0 cm. Until now, we have used only the free proximal ulnar artery perforator flaps, although we defined 3 types of anteromedial forearm flaps—free perforator flap, proximally based perforator flap, and distally based perforator flap.

Advantages and Drawbacks of the Proximal Ulnar Artery Perforator Flap

The advantages of the proximal ulnar artery perforator flap include the following:

1. Most of the proximal ulnar artery perforators are musculocutaneous perforators; with the same diameter, the area of the flap supplied by the musculocutaneous perforator is larger than the one supplied by the septocutaneous perforator.²⁶
2. The forearm is bigger proximally, and this facilitates the larger skin flap.
3. The flap can be innervated if the medial cutaneous nerve of the forearm is included.²⁷ The sensory deficit is minimal because there is a sensory overlap in the cutaneous territory.¹¹
4. Compared with the radial forearm flap, the ulnar forearm flap has several advantages, including ease of donor-site management, more inconspicuous scar location, and there was a lower incidence of skin graft loss at the ulnar forearm donor site.¹⁴

However, if this flap is harvested with a width greater than 5 cm, the donor site cannot be closed and requires skin grafting. Therefore, we believe that the proximal ulnar artery perforator flap is suitable for wound repair, especially for repair of small- to medium-sized shallow skin defects of hand or head.

CONCLUSIONS

The proximal ulnar artery perforator flaps have a consistent, reliable blood supply, and good texture. The donor site not only supplies a thin free flap but also provides the option of harvesting cross-boundary proximally or distally based perforator flaps that could be useful for repairing widespread traumatic soft-tissue defects.

Jin Mei, MD, MSc

Department of Anatomy
Wenzhou Medical University
Wenzhou
Zhejiang 325035
People's Republic of China
E-mail: tibetcn@aliyun.com

ACKNOWLEDGMENTS

The authors gratefully acknowledge the suggestions and advice of Dr. Steven F. Morris.

REFERENCES

- Atzei A, Pignatti M, Udali G, et al. The distal lateral arm flap for resurfacing of extensive defects of the digits. *Microsurgery* 2007;27:8–16.
- Pan ZH, Jiang PP, Wang JL. Posterior interosseous free flap for finger re-surfacing. *J Plast Reconstr Aesthet Surg*. 2010;63:832–837.
- Saint-Cyr M, Mujadzic M, Wong C, et al. The radial artery pedicle perforator flap: vascular analysis and clinical implications. *Plast Reconstr Surg*. 2010;125:1469–1478.
- Gao W, Hong J, Li Z, et al. Hand reconstruction with lobulated combined flaps based on the circumflex scapular pedicle. *Microsurgery* 2008;28:355–360.
- Stahl S, Lotter O, Stahl AS, et al. Immediate reconstruction of complex hand trauma with iliac crest bone graft and 2 pedicled fasciocutaneous skin flaps: a case report. *Eplasty* 2010;10:e21.
- Wang X, Mei J, Pan J, et al. Reconstruction of distal limb defects with the free medial sural artery perforator flap. *Plast Reconstr Surg*. 2013;131:95–105.
- Yang X, Zhang G, Liu Y, et al. Vascular anatomy and clinical application of anterolateral leg perforator flaps. *Plast Reconstr Surg*. 2013;131:534e–543e.
- Penteado CV, Masquelet AC, Chevrel JP. The anatomic basis of the fascio-cutaneous flap of the posterior interosseous artery. *Surg Radiol Anat*. 1986;8:209–215.
- Antonopoulos D, Kang NV, Debono R. Our experience with the use of the dorsal ulnar artery flap in hand and wrist tissue cover. *J Hand Surg Br*. 1997;22:739–744.
- Kim SW, Jung SN, Sohn WI, et al. Ulnar artery perforator free flap for finger resurfacing. *Ann Plast Surg*. 2013;71:72–75.
- Bertelli JA, Kaleli T. Retrograde-flow neurocutaneous island flaps in the forearm: anatomic basis and clinical results. *Plast Reconstr Surg*. 1995;95:851–859.
- Mathy JA, Moaveni Z, Tan ST. Perforator anatomy of the ulnar forearm fasciocutaneous flap. *J Plast Reconstr Aesthet Surg*. 2012;65:1076–1082.
- Sun C, Hou ZD, Wang B, et al. An anatomical study on the characteristics of cutaneous branches-chain perforator flap with ulnar artery pedicle. *Plast Reconstr Surg*. 2013;131:329–336.
- Yu P, Chang EI, Selber JC, et al. Perforator patterns of the ulnar artery perforator flap. *Plast Reconstr Surg*. 2012;129:213–220.
- Tang M, Yin Z, Morris SF. A pilot study on three-dimensional visualization of perforator flaps by using angiography in cadavers. *Plast Reconstr Surg*. 2008;122:429–437.
- Rees MJ, Taylor GI. A simplified lead oxide cadaver injection technique. *Plast Reconstr Surg*. 1986;77:141–145.
- Tang M, Yang D, Geddes CR, et al. Anatomical techniques. In: Blondeel PN, Morris SF, Hallock GG, et al, eds. *Perforator Flaps: Anatomy, Technique and Clinical Applications*. St. Louis, MO: QMP; 2006:53–67.
- Bergeron L, Tang M, Morris SF. A review of vascular injection techniques for the study of perforator flaps. *Plast Reconstr Surg*. 2006;117:2050–2057.
- Taylor GI, Pan WR. Angiosomes of the leg: anatomic study and clinical implications. *Plast Reconstr Surg*. 1998;102:599–616; discussion 617–618.
- Cormack GC, Lamberty BG. Cadaver studies of correlation between vessel size and anatomical territory of cutaneous supply. *Br J Plast Surg*. 1986;39:300–306.
- Mateev MA, Trunov L, Hyakusoku H, et al. Analysis of 22 posterior ulnar recurrent artery perforator flaps: a type of proximal ulnar perforator flap. *Eplasty* 2009;10:e2.
- Bertelli JA, Pagliei A. The neurocutaneous flap based on the dorsal branches of the ulnar artery and nerve: a new flap for extensive reconstruction of the hand. *Plast Reconstr Surg*. 1998;101:1537–1543.
- Vergara-Amador E. Anatomical study of the ulnar dorsal artery and design of a new retrograde ulnar dorsal flap. *Plast Reconstr Surg*. 2008;121:1716–1724.
- Jihui JU, Liu Y, Hou R. Ulnar artery distal cutaneous descending branch as free flap in hand reconstruction. *Injury* 2009;40:1320–1326.
- Thomas BP, Geddes CR, Tang M, et al. The vascular supply of the integument of the upper extremity. In: Blondeel P, Morris SF, Hallock GG, et al, eds. *Perforator Flaps: Anatomy, Technique and Clinical Applications*. St. Louis, MO: QMP; 2006:129–246.
- Tao Y, Hu S, Lui KW, et al. Quantitative regression analysis of the cutaneous vascular territories in a rat model. *Surg Radiol Anat*. 2011;33:789–799.
- Jawad AS, Harrison DH. The island sensate ulnar artery flap for reconstruction around the elbow. *Br J Plast Surg*. 1990;43:695–698.