

Available online at [www.sciencedirect.com](http://www.sciencedirect.com)

ScienceDirect

journal homepage: [www.elsevier.com/locate/radcr](http://www.elsevier.com/locate/radcr)

## Case Report

# Primary diffuse large B-cell non-Hodgkin's lymphoma of the breast—A case report and review of the literature

Ola A. Harb<sup>a,\*</sup>, Safa A. Balata<sup>b</sup>, Hassan Ashour<sup>c</sup>, Eman Eltokhy<sup>c</sup>, Loay M. Gertallah<sup>c</sup>, Rham Z. Ahmed<sup>d</sup>, Ali M. Hassanin<sup>e</sup>

<sup>a</sup> Department of Pathology, Faculty of Medicine, Zagazig University, Egypt

<sup>b</sup> Department of Clinical Oncology and nuclear medicine, Faculty of Medicine, Zagazig University, Egypt

<sup>c</sup> Department of General surgery, Faculty of Medicine, Zagazig University, Egypt

<sup>d</sup> Department of Medical Oncology, Faculty of Medicine, Zagazig University, Egypt

<sup>e</sup> Department of Radiology, Faculty of Medicine, Zagazig University, Egypt

## ARTICLE INFO

## Article history:

Received 4 July 2018

Revised 3 September 2018

Accepted 3 September 2018

Available online 4 October 2018

## Keywords:

Primary large B-cell lymphoma

Breast

Immunohistochemistry

## ABSTRACT

Primary breast lymphoma (PBL) is considered a rare clinical entity forming about 0.4%–0.5% of all breast tumors.

In this report we have presented a case of PBL in a 56-year-old female complaining of a mass in the upper medial quadrant of the breast.

PBL suspicion of our case was made by breast radiology and the sure diagnosis was reached by the immunohistochemistry results; CD (cluster of differentiation) 20: was diffusely positive; Pan-CK (pan-cytokeratin): was diffusely negative in tumor cells. Hence, the case was finally diagnosed as a primary breast a primary breast diffuse large B-cell non-Hodgkin's lymphoma of lymphoma.

The management and outcome of PBL and carcinoma are totally different. Accurate diagnosis of PBL by true cut needle biopsy and immunocytochemistry is important to avoid unnecessary mastectomies.

© 2018 The Authors. Published by Elsevier Inc. on behalf of University of Washington.

This is an open access article under the CC BY-NC-ND license.

(<http://creativecommons.org/licenses/by-nc-nd/4.0/>)

## Introduction

Primary non-Hodgkin's lymphoma of the breast is very rare, accounting for about 0.1%–0.5% of all malignant breast tumors, and forming about 1.7%–2.2% of extra nodal NHL [1,2].

In most reported case reports and case series, primary breast lymphoma (PBL) usually presented as a palpable mass which is rarely detected during clinical and radiological screening, which mimic benign masses. Diagnosis can be confirmed by a true cut needle biopsy followed by immunohistochemistry. By contrast to primary breast carcinoma; performing mastectomy is not the primary line of management of PBL.

\* Corresponding author.

E-mail addresses: [olaharb2015@gmail.com](mailto:olaharb2015@gmail.com) (O.A. Harb), [coyhut@gmail.com](mailto:coyhut@gmail.com) (S.A. Balata), [Dremantokhy@gmail.com](mailto:Dremantokhy@gmail.com) (E. Eltokhy), [Loayelhady@gmail.com](mailto:Loayelhady@gmail.com) (L.M. Gertallah), [rhamzaki1975@gmail.com](mailto:rhamzaki1975@gmail.com) (R.Z. Ahmed), [Dr\\_alih2000@hotmail.com](mailto:Dr_alih2000@hotmail.com) (A.M. Hassanin).  
<https://doi.org/10.1016/j.radcr.2018.09.004>

1930-0433/© 2018 The Authors. Published by Elsevier Inc. on behalf of University of Washington. This is an open access article under the CC BY-NC-ND license. (<http://creativecommons.org/licenses/by-nc-nd/4.0/>)

Treatment is mainly by combination of chemotherapy and radiotherapy. So, accurate diagnosis of PBL by true cut needle biopsy and immunocytochemistry is important to avoid unnecessary mastectomies.

There are many subtypes of PBL, but the most common subtype is the B-cell non-Hodgkin's lymphoma.

At presentation, most patients are suspected to have breast carcinoma, then the primary diagnosis of a PBL is made by histopathological examination of the true cut needle biopsy from the mass and reaching the final accurate diagnosis and subtyping are reached by immunocytochemistry [1].

In this report we have presented a rare case of primary breast a primary breast diffuse large B-cell non-Hodgkin's lymphoma of lymphoma and a review of literature of PBL.

### Case report

Our case is a 56-year-old female who was presented to General Surgery Department, Faculty of Medicine, Zagazig University with a right breast lump since 7 months and having no constitutional symptoms. Patient was not complaining of pain or nipple discharge.

On local physical examination, we have detected a firm lump of about  $5 \times 4 \times 3$  cm in upper inner quadrant of right breast which was not fixed to the overlying skin. There was no history of trauma to the affected breast. Systemic physical patient's examination revealed no abnormality.

Ultrasonography breast imaging showed a solid mass measuring about  $5 \times 4 \times 3$  cm with wall calcification at 2-o'clock position in right breast.

On mammography, there was an oval radio-opaque lesion with irregular margins in upper inner quadrant of right breast with free retro-areolar space (Fig. 1 A and B).

Fine needle aspiration cytology was done in Pathology Department, Faculty of Medicine, Zagazig University that was positive for malignant cells.

Sonar guided true cut needle biopsy was needed for accurate diagnosis.

Microscopic examination of sections prepared from the true cut biopsy revealed; infiltration of the fibro fatty stroma of the breast by cords, sheets of large pleomorphic discohesive malignant cells with hyperchromatic nuclei, and scanty cytoplasm.

Areas of hemorrhage and necrosis were found between the masses (Fig. 2 A–D).

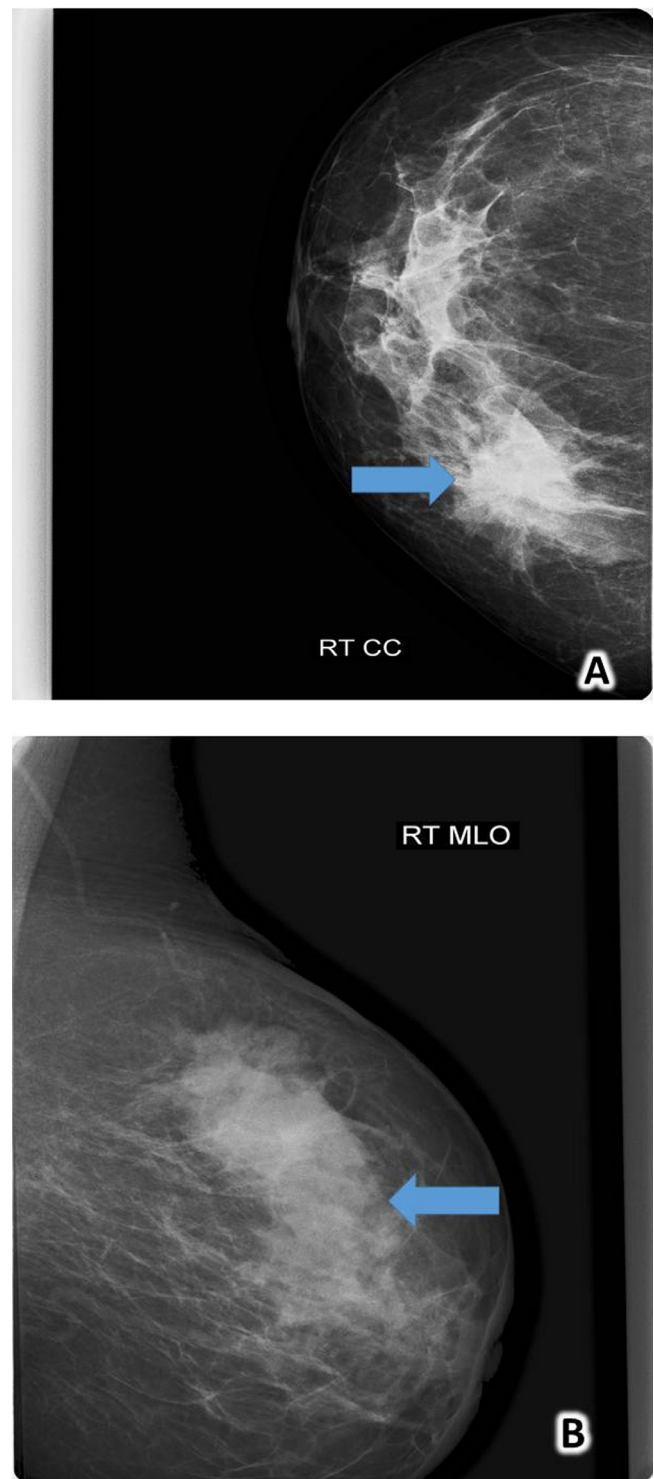
Diagnosis of non-Hodgkin lymphoma versus invasive lobular carcinoma:

Immunohistochemistry with CD45, CD20, CD3, CD5, CD30, and Pan-Keratin were highly recommended to confirm the diagnosis.

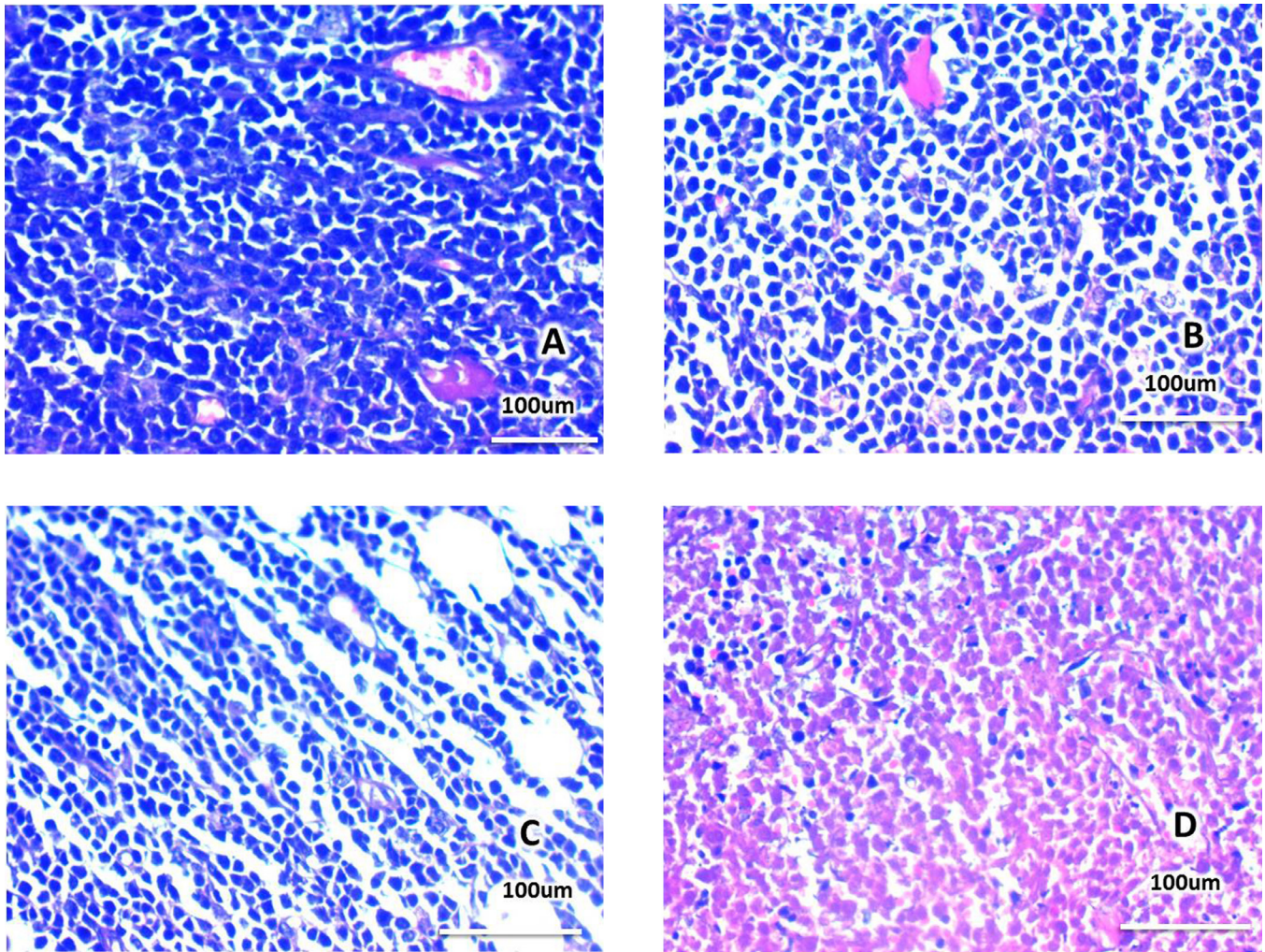
Immunohistochemistry results (Fig. 3 A–G).

Pan-Keratin: was negative in tumor cells, CD 45: was diffusely positive in all tumor cells, CD 20: was diffusely positive, CD 5: was focally positive; CD3: was negative; CD15: was negative; CD30: was negative.

Hence, the case was finally diagnosed as a primary breast diffuse large B-cell non-Hodgkin's lymphoma of lymphoma.



**Fig. 1** – Mammography of the case revealed that there was an oval radio-opaque lesion with irregular margins in upper inner quadrant of right breast with free retro-areolar space No skin thickening or nipple retraction. (A) Cranio-caudal position (CC); (B) Mediolateral oblique position (MLO).



**Fig. 2 – Histopathological examination of sections prepared from the true cut biopsy revealed: (A, B, and C) infiltration of the fibro fatty stroma of the breast by cords, sheets of large pleomorphic discohesive malignant cells with hyperchromatic nuclei and scanty cytoplasm. (D) Areas of hemorrhage and necrosis were found between the masses. Hematoxylin & Eosin stain  $\times 400$ .**

Investigations revealed:

- Liver and kidney function tests were within normal limits.
- Chest X-ray and ultrasonography abdomen were normal with no evidence of metastatic disease.

The patient was on regular follow-up, doing well, and was planned for adjuvant radiotherapy and chemotherapy in Clinical Oncology & Nuclear Medicine Department and in Medical Oncology Department Faculty of Medicine, Zagazig University.

## Discussion

Lymphomas are the most common hematologic cancers, but breast association with lymphoma is rare and PBL is even rarer, forming about 0.04%-0.5% of all primary breast cancers and about 0.85%-2.2% of extranodal lymphomas.

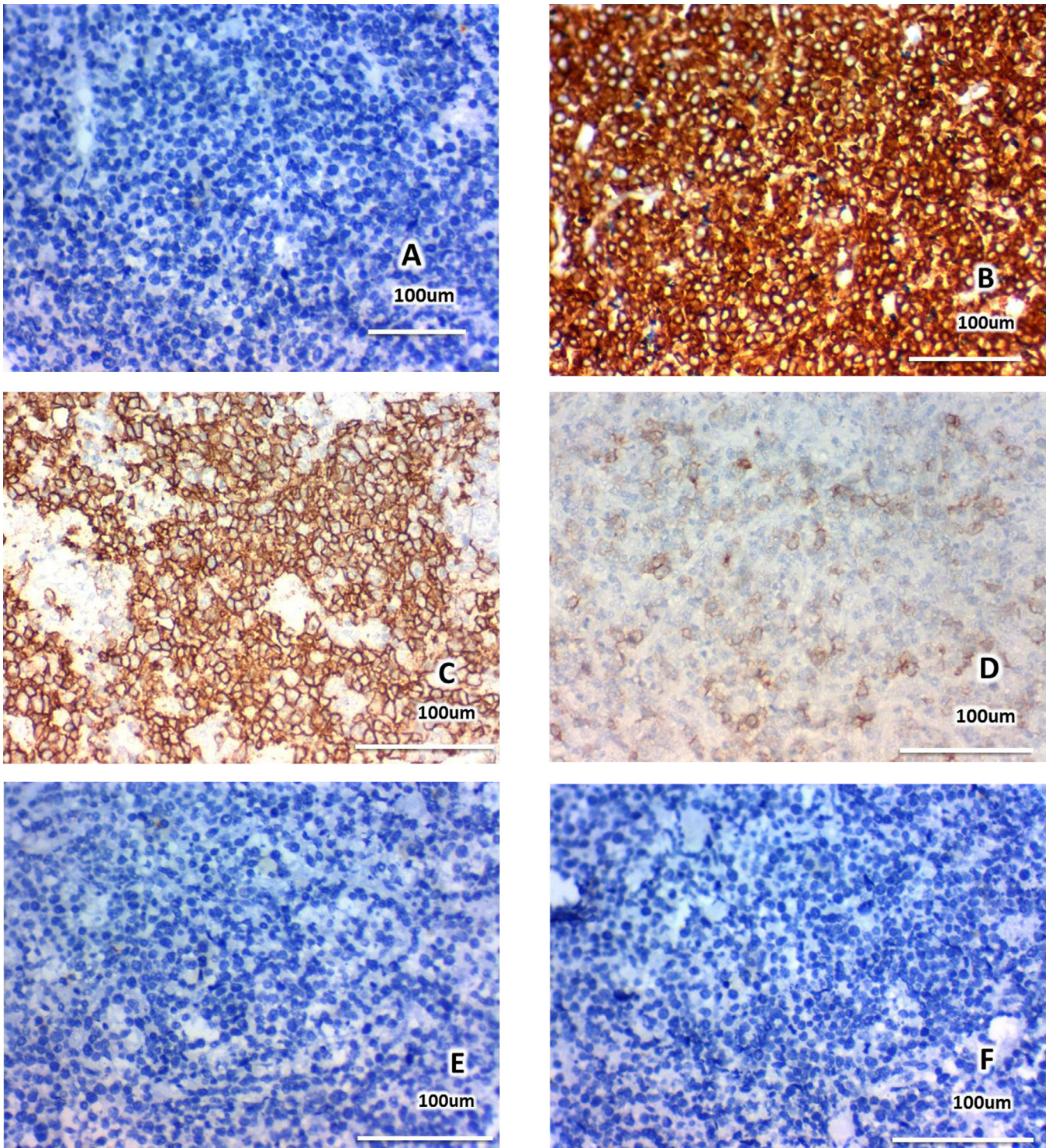
Non-Hodgkin's diffuse large B-cell lymphoma (DLBCL) is the most common histo-pathological subtype of PBL, followed by follicular and mucosal-associated lymphoid tissue associated lymphomas; breast involvement with Hodgkin's disease or T-cell lymphomas is very rare [2].

Clinicians that are managing breast cancers must be aware of this rare entity to detect its clinical presentation and management which is totally different from breast carcinoma cases [3].

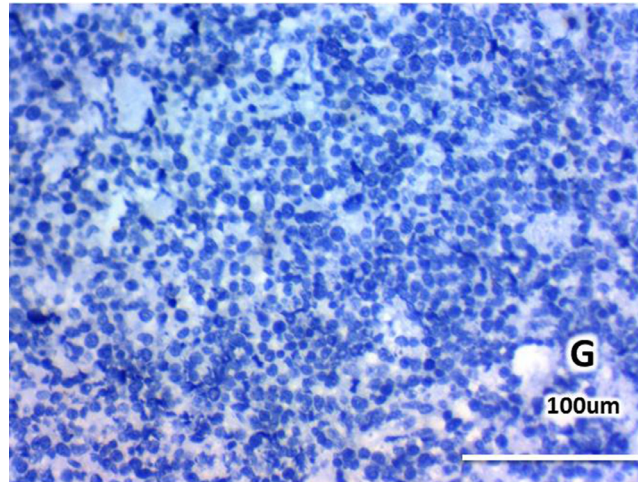
With the advancement in diagnostic modalities, the incidence of PBL is increasing and about 95%-100% of reported cases are diagnosed in women, while it is very rare in men [4].

Unilateral affection of the upper right quadrant of the breast is the most common reported presentation of PBL [5,6], while only 1%-14% of all reported PBL cases have bilateral disease [7].

In this study we report a rare case of primary non-Hodgkin lymphoma of the breast, with B-cell phenotype, suspected by sonography and mammography, then confirmed by



**Fig. 3 – Immunohistochemistry results (A) Pan-Keratin diffuse negative expression, (B) CD45 diffuse positive membranous expression in all tumor cells, (C) CD20 diffuse positive membranous expression in all tumor cells, (D) CD5 focal positive expression in some tumor cells, (E) CD3 negative expression in all tumor cells, (F) CD 15 negative expression in all tumor cells, (G) CD30 negative expression in all tumor cells. Streptavidin biotin stain, hematoxylin counterstain original magnification x400.**



**Fig. 3 – Continued**

histopathological examination of a true cut needle biopsy. The patient was successfully treated nonsurgically according to the breast multidisciplinary team.

The patient was given 4 cycles of combination chemotherapy with R-CODOX/IVAC. A PET scan for follow-up revealed mild F-18 fluorodeoxyglucose uptake at the periphery of the residual breast mass, pointing to a radiological favorable response.

Performing mastectomy is not the primary line of management of PBL and role of surgery should be limited to a biopsy to establish the correct histological diagnosis, leaving the curative treatment to radiotherapy and chemotherapy [1]. The role of central nervous system (CNS) prophylaxis in DLBCL of the breast is controversial [1].

In our case, FNAC (fine needle aspiration cytology) then sonar guided true cut needle biopsy allows us to avoid unnecessary mastectomy.

Wadhwa and Senebouttarath [2] described 3 cases of this rare disease. None of them had a prior history of lymphoma or B-symptoms, including night fever, sweats, or weight loss.

Diagnosis of our present case was established on sonar-guided true cut needle biopsy and no evidence of metastatic disease was identified.

The imaging features were not specific, but the radiologists must be aware of the imaging presentation of such rare entity to recommend appropriate management and establish radiological-pathological concordance.

Jabbour et al., [8] report another case of PBL of DLBCL in a 43-year-old Indonesian woman in the left breast. That was diagnosed by a core needle biopsy which has revealed diffuse infiltration of large atypical lymphoid cells. They similarly have confirmed the diagnosis by immunohistochemical biomarkers.

Jennings et al., [7] collected all reported and published PBL cases from 3 decades (1972-2005) and concluded that mastectomy gives no benefits to the management of PBL. The presence of positive nodal metastases predicts patients' outcome and directs the clinician to the optimal use of radiation and chemotherapy.

The imaging data of PBL are nonspecific and resemble any other malignant and even benign breast tumors. The commonest mammographic finding is a single noncalcified breast mass that is circumscribed or may have indistinct margins [2]. No calcifications, nipple retraction, or architectural distortion are detected. Global asymmetry is another presentation of PBL which is detected by mammography in one-third of the PBL patients reported in the study by Wadhwa and Senebouttarath [2] and is associated with high-grade lymphomas. There are no established guidelines for PBL management; it might include combination of surgery, chemotherapy, and radiotherapy.

Radical mastectomy that was described formerly as a part of PBL management, recently have been proved to have no benefits, and may delay the start of chemotherapy. Chemo-immunotherapy with consolidation radiation therapy (using CHOP or CHOP-like protocols) is the mainstay in the PBL management now.

This may be followed with radiation to the same breast and regional nodes [1].

In the study by Avilés et al., [9], the 10-year overall survival rate in patients managed with radiation or chemotherapy alone was 50% vs 76% in those who received combination of radiation and chemotherapy. PBL is a serious tumor with high relapse rates, mainly involving extranodal sites. As there is a high CNS relapse rate in 20% patients, hence, adding CNS prophylaxis to systemic treatment in PBL is highly recommended in certain case to avoid CNS spread [10,11].

The clinical and radiological presentations of breast lymphoma and carcinoma are nearly the same; both presenting as painless enlarging breast lump.

As their managements are totally different, accurate diagnosis is mandatory.

Despite the fact that lymphoma may lack the irregular border of infiltrating carcinoma on mammogram, more than half exhibit no calcification; consequently, pathology remains the gold standard to differentiate these 2 malignancies. All histological types of lymphoma have been described.

B-cell lymphoma is the most common presentation of PBLs; approximately one-half are DLBCL type, mostly CD20+ [1].

---

## Summary

Primary malignant lymphoma of the breast (PBL) is rare, but it is still a substantial differential diagnosis of a breast lump.

We have detected and reported another case of PBL in a 56-year-old female patient.

A clinical suspicion for accurate diagnosis of PBL is important to avoid unnecessary mastectomies.

Histopathological examination of FNAC and true cut needle biopsy samples supplemented by immunocytochemistry allow accurate diagnosis of PBL.

The management depends on the histological subtype, disease extent, and patient's performance status.

Chemotherapy remains the most acceptable option, alone or in combination with radiotherapy and/or surgery.

Surgery should be limited only to a biopsy to confirm the final histological diagnosis of PBL, leaving the curative treatment to radiotherapy and chemotherapy [1].

---

## Conclusion

Early and accurate diagnosis of PBL is crucial for selecting the appropriate multidisciplinary team treatment strategies to avoid harmful surgical interventions. The role of FNAC and true-cut biopsy in breast lump is essential in case of PBL to avoid unnecessary mastectomies.

---

## REFERENCES

- [1] Gupta V, Bhutani N, Singh S, Chhabra S, Sen R. Primary non-Hodgkin's lymphoma of breast - A rare cause of breast lump. *Human Pathology: Case Reports* 2017;7:47–50.
- [2] Wadhwa A, Senebouttarath K. Primary lymphoma of the breast: a case series. *Radiol Case Rep* 2018;13(4):815–21.
- [3] Jabbour G, El-Mabrok G, Al-Thani H, El-Menyar A, Al-Hijji I, Napaki S. Primary Breast Lymphoma in a Woman: A Case Report and Review of the Literature. *Am J Case Rep* 2016;17:97–103.
- [4] Yang H, Lang R-G, Fu L. Primary breast lymphoma (PBL): a literature review. *Clin Oncol Cancer Res* 2011;8:128–32.
- [5] Inic Z, Inic M, Zegarac M, Inic I, Pupic G, et al. Three cases of combined therapy in primary breast lymphoma (PBL) with successful outcomes. *Clin Med Insights Oncol* 2013;7:159–63.
- [6] Garg NK, Bagul NB, Rubin G, Shah EF. Primary lymphoma of the breast in-volving both axillae with bilateral breast carcinoma. *World J Surg Oncol* 2008;6:52.
- [7] Jennings WC1, Baker RS, Murray SS, Howard CA, Parker DE, Peabody LF, Vice HM, Sheehan WW, Broughan TA, et al. Primary breast lymphoma: the role of mastectomy and the importance of lymph node status. *Ann Surg* 2007;245(5):784–9.
- [8] Jabbour G, El-Mabrok G, Al-Thani H, El-Menyar A, Al Hijji I, Napaki S, et al. Primary Breast Lymphoma in a Woman: A Case Report and Review of the Literature. *Am J Case Rep* 2016;17:97–103.
- [9] Avilés A, Castañeda C, Neri N, Cleto S, Nambo MJ, et al. Rituximab and dose dense chemotherapy in primary breast lymphoma. *Haematologica* 2007;92(8):1147–8.
- [10] Shao YB, Sun XF, He YN, Liu CJ, Liu H. Clinicopathological features of thirty patients with primary breast lymphoma and review of the literature. *Med Oncol* 2015;32(2):448.
- [11] Yhim HY, Kang HJ, Choi YH, Rubin G. Clinical outcomes and prognostic factors in patients with breast diffuse large B cell lymphoma; Consortium for Improving Survival of Lymphoma (CISL) study. *BMC Cancer* 2010;10:321.