

# Complex treatment of vascular prostheses infections

Octavian Andercou, PhD<sup>a</sup>, Dorin Marian, PhD<sup>b,\*</sup>, Gabriel Olteanu, PhD<sup>a</sup>, Bogdan Stancu, PhD<sup>a</sup>, Beatrix Cucuruz, PhD<sup>c</sup>, Thomas Noppeney, PhD<sup>c</sup>

## Abstract

Infections after vascular reconstructions are very rare; however, when they occur, they are associated with a high risk of morbidity. In order to obtain the best results possible, the treatment needs to be initiated as early as possible, from the very first signs of infection, and it needs to be carried out in centers specializing in vascular surgery. The aim of the present study was to assess the incidence of infections in a single university center.

This retrospective analysis over a 2-year period is based on the medical reports of hospitalized patients who were diagnosed with infection following revascularization.

From 2013 to 2014, a number of 151 open reconstructive surgical procedures were performed. 15 patients suffered from infection (10%) of the vascular reconstruction. Of these patients, 40% have had an aorto-bifemoral bypass, 53% — a femoro-popliteal bypass, and 7% (n = 1) — an axillo-femoral bypass. According to the Samson classification, the patients were categorized as follows: group 2: 6 cases, group 3: 2 cases, group 4: 4 cases, and group 5: 3 cases. The most frequent bacteria found were methicillin-resistant *Staphylococcus aureus* (MRSA) (n = 6, 40%), followed by *S aureus* (n = 5, 33%). The treatment options were: application of antibiotics alone without any invasive treatment in 3 patients, local irrigation and debridement in 6 patients, complete explantation of the prosthesis with a new extra-anatomic bypass in 6 cases, and partial excision of the prosthesis, which was replaced and covered with muscle flap, in 3 cases. The amputation rate in our study was 18%, which corresponds to the rates published in the literature.

The treatment of infections in vascular surgery needs to be complex and adapted to each individual patient, because infections being in a permanent dynamic state. The treatment needs to be performed in specialized centers that have large experience in vascular surgery, in order for the patient to have the best chances of survival and protection from amputation.

**Abbreviations:** CDC = Center for Disease Control, CT = computer tomography, MRSA = methicillin-resistant *Staphylococcus aureus*, NPWT = negative pressure wound therapy, PET-CT = positron emission tomography and computer tomography, PTFE = polytetrafluorethylen, VAC = vacuum assisted closure.

**Keywords:** amputation, infection, methicillin-resistant *Staphylococcus aureus*, muscular flap, reconstruction, vascular prostheses

## 1. Introduction

Infections represent a severe, often life threatening complication, after any vascular surgical intervention. They are to be feared, because they are associated with high rates of morbidity and mortality, which may result not only in the loss of the limb, but may also lead to death in more severe cases. For this reason, the

treatment of infections in vascular surgery is a challenge even to an experienced vascular surgeon. Infections are associated with long hospitalization and increased costs.

The incidence of infections in vascular surgery is very low in the literature; it ranges between 1% and 6%,<sup>[1,2]</sup> with an increased frequency, of up to 44%, when the vascular reconstruction was performed in the inguinal area.<sup>[3]</sup> The risk of amputation associated with vascular prosthesis infection may reach 70%, while the risk of death may reach even up to 75%.<sup>[3,4]</sup>

Multiple infecting microorganisms have been detected to be involved, but the most frequent ones, responsible for over 75% of infections, are *Staphylococcus aureus*; however, the most severe infections are those with methicillin-resistant *Staphylococcus aureus* (MRSA).<sup>[5–7]</sup> Gram-negative bacteria, such as *Pseudomonas aeruginosa*, *Escherichia coli*, *Klebsiella*, *Enterobacter*, or *Proteus*, are not found as often, but are associated with more serious infections which may result in ruptures of the anastomosis through the destruction of the arterial wall by the toxins synthesized by these bacteria.

The diagnosis of an infection can be established based on the clinical symptoms and signs when specific findings are present (e.g., fistula). Very often it is difficult to distinguish a simple surgical site infection from a deeper infection. The diagnosis should be verified by radiological examination, for example leucocyte scintigraphy or positron emission tomography and computer tomography (PET-CT). The best diagnostic modality is CT, which has a sensitivity of 94% and a specificity of 85% for

Editor: Danny Chu.

This article does not contain any studies with human participants or animals performed by any of the authors.

The authors declare no conflicts of interest.

<sup>a</sup> Second Surgical Clinic, Iuliu Hatieganu University of Medicine and Pharmacy, Cluj-Napoca, <sup>b</sup> Second Surgical Department, University of Medicine and Pharmacy, Targu Mures, Romania, <sup>c</sup> Center for Vascular Diseases and Department for Vascular Surgery Martha-Maria Hospital, Nuremberg, Germany.

\* Correspondence: Dorin Marian, Emergency County Hospital Mures, Second Surgical Department, University of Medicine and Pharmacy, Targu Mures, Romania (e-mail: dorinmarms@gmail.com).

Copyright © 2018 the Author(s). Published by Wolters Kluwer Health, Inc. This is an open access article distributed under the terms of the Creative Commons Attribution-Non Commercial-No Derivatives License 4.0 (CCBY-NC-ND), where it is permissible to download and share the work provided it is properly cited. The work cannot be changed in any way or used commercially without permission from the journal.

Medicine (2018) 97:27(e11350)

Received: 1 April 2017 / Accepted: 8 June 2018

<http://dx.doi.org/10.1097/MD.00000000000011350>

high grade infections but CT is less useful for low-grade infections. Furthermore, it is necessary to verify the arterial flow distal to the infected reconstruction.<sup>[8,9]</sup> A microbiological diagnosis confirming the infection and identifying the etiological agent is mandatory.

In many cases vascular prosthesis infections are difficult to treat. So far, there isn't yet a standard with regard to treatment.<sup>[10]</sup> However, there exist different therapeutic options. In a first stage infection without involvement of the vascular reconstruction, a conservative antibiotic treatment according to the antibiogram seems to be adequate; however, in more advanced stages or in the case of deep infection, a more aggressive treatment, which includes irrigation and a wide debridement of affected tissue and even the explantation of the prosthesis. The restoration of the blood flow of the limb is achieved either at the same time or in a subsequent surgical intervention, using in situ or extra-anatomic bypass techniques.<sup>[11–14]</sup>

In order to achieve the best possible therapeutic efficacy, is necessary to classify the grade of and the depth of the infection exactly. There is no internationally accepted classification for vascular graft infection. The most widely-used classification is the one proposed by Szilagyi.<sup>[15]</sup> and later modified by Samson,<sup>[16]</sup> adapted after the classification for surgical sites infection by the Center for Disease Control and Prevention (CDC) (Table 1).<sup>[15]</sup>

The aim of the present study is to describe the incidence of infections in a vascular surgery center and the degree of the infection, the prophylactic methods, and the therapeutic options obtained by a multidisciplinary approach.

## 2. Methods

We have performed a retrospective study based on the patients' medical records, which extends over a 2-year period, from 2013 to 2014. We have included in this study the patients in whose medical history an open peripheral arterial reconstruction had been performed, and in the case of the patients with an aortobifemoral bypass, only the infections in the inguinal area were taken into consideration, while the patients with intracavitary infection were excluded because of the low number of intracavitary infections. In order to estimate the degree of infection, we used the Samson classification (Table 1). By analyzing the medical records, we collected data regarding the patients' age, associated diseases, previous operations, type of prosthesis used, the time span from the initial intervention to the onset of the infection, the treatment methods, and the outcome of the patients. Because of the low number of patients we do not used statistical analyses. The study was approved by the local ethic committee of the university hospital, an informed consent of

the patients was not necessary, because the data were collected anonymously.

### 2.1. Patients and results

During this period we identified a number of 15 patients diagnosed with infection, out of a total number of 151 bypass operations (9.93%). All patients were males aged 43 to 79 years, with a higher frequency in the case of patients aged 60 to 69 years (7 cases). The main comorbidities that were identified are shown in Table 2.

The previous operations performed in patients with infection were aorto-bifemoral bypass in 40% (n=6), femoro-distal bypass I in 33% (n=5), femoro-popliteal bypass in 20% (n=3) and in 1 case (6%) an axillo-bifemoral bypass.

The majority of prostheses used for revascularization were Dacron prostheses with 53% (n=8) but also PTFE and reversed great saphenous vein graft each of them in 20% (n=3) (Table 3).

The indications for primary revascularization were: critical ischemia (n=9) and claudication (n=6). No emergency revascularization procedures were performed for acute ischemia. The time interval from the initial intervention to the diagnosis of infection ranged from 9 to 60 days. The diagnosis of infection was established by clinical symptoms and signs, as well as by laboratory tests: the number of leukocytes, C-reactive protein.

In addition to these findings, an ultrasound examination and an abdominal CT examination were performed, to verify or exclude an intracavitary infection. According to the Samson classification, the patients with infection were categorized as shown in Table 4, where one may notice that in almost half of the cases (n=6), only the superficial tissues were affected, while deep tissue and/or the prosthesis was not affected. In the other half of the cases there had already been an exposure of the prosthesis to infection, of which in 3 cases the patients were septic or even have had a hemorrhage at the level of the anastomosis.

The localization of the infection was in the inguinal area in 13 cases, while in 2 cases it was below the knee.

The microorganisms causing the infection were identified based on the microbiological examination of all patients. The culture material was collected from the wound exudate or from pus when present. In one third of the cases *S aureus* was identified (n=5); MRSA was identified in 40% of the cases (n=6); gram-negative bacteria (*E coli*) were identified in only 2 cases. In 2 cases no bacteria could be proven (Table 5).

Upon hospitalization, all patients were treated with wide-spectrum antibiotics, even though the causing bacteria was identified or not known at hospitalization. The antibiotic-only treatment was used in 3 cases (20%) (only patients from Group Samson 2), whereas in the rest 80%, (n=12) of the patients a

**Table 1**

#### Classification of vascular prosthesis infections.

Szilagyi	Definition	Samson	Definition
Group 1	Infection involves only dermis	Group 1	Infection extends no deeper than dermis
Group 2	Infection involves subcutaneous tissue but does not invade arterial implant	Group 2	Infection involves subcutaneous tissue but does not come into direct contact with the graft
Group 3	Infection involving the vascular prosthesis	Group 3	Infection involves body of the graft but not an anastomosis
		Group 4	Infections surround an exposed anastomosis but bacteraemia or bleeding has not occurred
		Group 5	Infections involve an anastomosis and are associated with septicemia and bleeding

**Table 2**

**Patients' characteristics.**

No. of cases	15 (100%)
Sex, male	100%
Hypertension	5 (33%)
Ischemic cardiac disease	4 (26%)
Dyslipidemia	7 (46%)
Diabetes mellitus	5 (33%)
Kidney failure	2 (13%)
Smoker	7 (46%)

**Table 3**

**Types of prostheses used.**

Dacron	8 (53%)
PTFE	3 (20%)
Reversed great saphenous vein	3 (20%)
Composite	1 (6%)

PTFE = polytetrafluorethylen.

**Table 4**

**Classification of the patients according to Samson.**

Samson group 2	Samson group 3	Samson group 4	Samson group 5
6	2	4	3

**Table 5**

**Microorganisms identified causing infection after vascular reconstruction.**

<i>Staphylococcus aureus</i>	5 (33%)
MRSA	6 (40%)
<i>Escherichia coli</i>	2 (13%)
None	2 (13%)

MRSA = Methicillin resistant *Staphylococcus aureus*.

**Table 6**

**Treatment of patients with infection.**

Irrigation and debridement	6
Explantation of graft and new extra-anatomic bypass	6
Antibiotic therapy alone	3
Muscle flap	3

**Table 7**

**Treatment according to bacteria involved.**

	AB only	Irrigation + debridement	Graft explantation + new bypass	Muscle flap	Amputation	Limb salvage
MRSA (n=6)	–	1	4	3	3	4
<i>Staphylococcus aureus</i> (n=5)	1	3	1	–	–	5
<i>Escherichia coli</i> (n=2)	–	2	–	–	–	2

MRSA = Methicillin resistant *Staphylococcus aureus*.

surgical treatment was also performed (Table 6). For irrigation we used povidone-iodine solution. Additionally we performed repeated large debridement of tissue necrosis and inflamed surrounding tissues until we obtained a granulated wound. In some cases multiple and various surgical techniques were necessary in order to salvage the limb.

We have made a correlation between the types of treatment and the bacteria involved. It was noted that the MRSA infections had the most unfavorable outcome: the limb had to be amputated in 3 of the cases (20%). Moreover, these infections also require the most complex treatment. (Table 7)

Another correlation could be found in relation to the degree of infection, based on the Samson classification (Table 8). The results of deep infections in Samson groups 4 and 5 are not the most favorable, since in 3 of these patients (42.9%) the limbs had to be amputated.

Special attention has been paid to 4 particular cases which raised special treatment problems and in 3 of them the solution was to cover the prosthesis with a muscle flap.

Case number 1 is a 69-year-old patient, who has undergone a femoropopliteal bypass operation with 7 mm PTFE prosthesis 53 days before onset of infection. Upon hospitalization, the patient's operative wounds were slightly dehiscent, with a discrete hemorrhage at the level of the distal incision and with the prosthesis completely exteriorized but functional (Fig. 1).

From the history we concluded that the patient, who had been treated only with antibiotics, irrigation, and debridement in a local general surgery center with no vascular surgery experience, have had an infection of the wounds in the postoperative period. We decided to explant the prosthesis completely in combination with a wide debridement of the affected tissues. After explanation of the prosthesis the lower limb was well compensated, therefore it was possible for us to perform a late revascularization with the saphenous vein taken from the contralateral limb; the outcome was favorable and the limb could be saved.

Case number 2 is a patient aged 65 with an axillo-femoral bypass operation in his medical history. Forty-five days after surgery, the patient's postoperative wounds were completely healed, but the prosthesis was completely exteriorized at the level of the left thorax (Fig. 2).

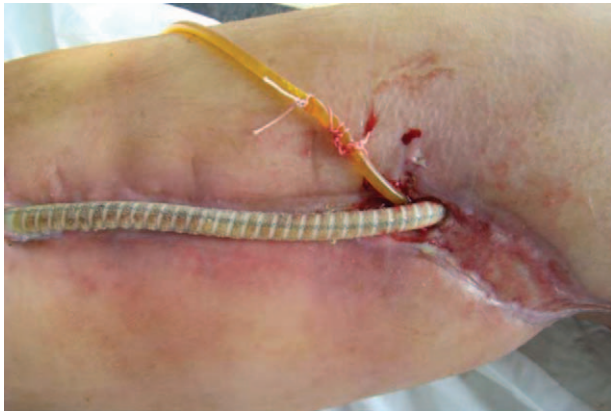In this case, we decided to perform a partial resection of the exteriorized part of the prosthesis, replacing and covering the new silver impregnated Dacron type graft with a flap taken from the latissimus dorsi (Fig. 3); the operation was performed in cooperation with plastic surgeons. The postoperative outcome was favorable in this case too, and the limbs could be saved.

The third case is a deep infection (Samson group 6) localized in the inguinal area, following a femoro-crural bypass operation with a reversed saphenous vein graft. The patient has a dehiscent and purulent inguinal wound. The microbiological examination confirms the presence of MRSA and the microscopic examination of a vein segment taken from the vicinity of the anastomosis

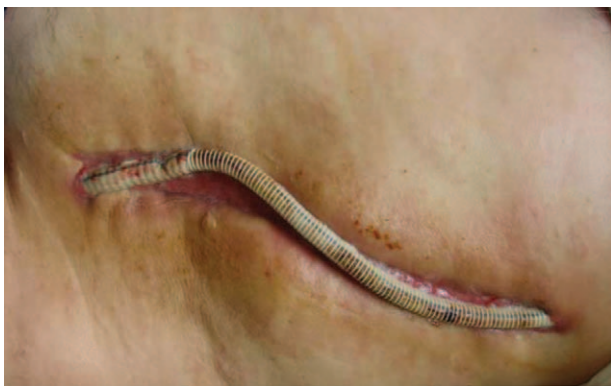**Table 8**

**Treatment according to infection classification.**

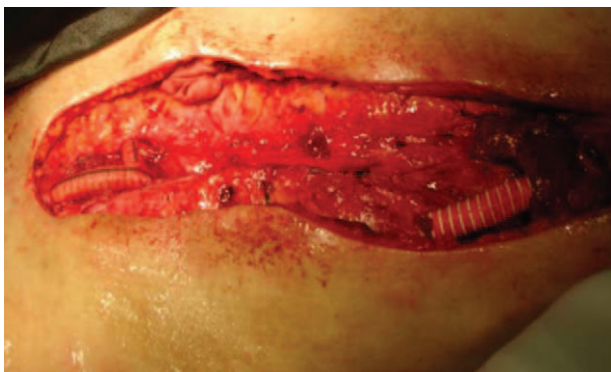	AB only	Irrigation + debridement	Graft explantation + new bypass	Muscle flap	Amputation	Limb salvage
Group 2	3	3	–	–	–	6
Group 3	–	2	–	–	–	2
Group 4	–	1	3	1	1	4
Group 5	–	–	3	2	2	2



**Figure 1.** Completely exteriorized vascular prosthesis at the thigh level of a femoro-popliteal PTFE bypass.



**Figure 2.** Exteriorized segment of axillo-femoral bypass.



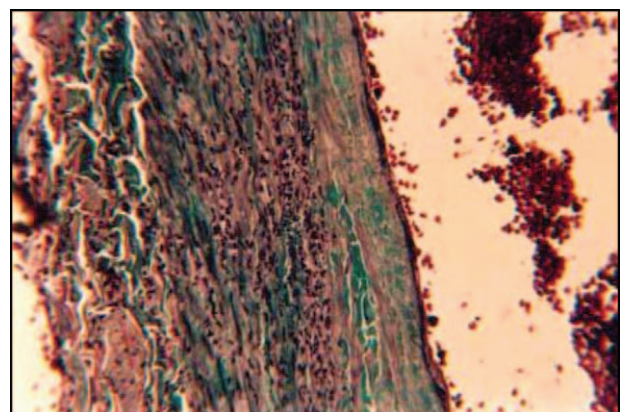
**Figure 3.** Covering the prosthesis with a muscle flap.

shows a purulent process around the vein, associated with a periphlebitis (Fig. 4). In this case, we decided to ligate the common femoral artery and explant the venous graft completely. Due to a good arterial compensation of the limb, we were able to perform a secondary limb revascularization. After the wounds healed, we restored vascularization with a new venous graft, this time covered with a Sartorius muscle flap, in order to prevent a new infection; the outcome was very good.

Case number 4 is a patient with an aorto-bifemoral bypass, who, from a clinical point of view, had a pseudoaneurysm in the right inguinal area. We decided to remove the pseudoaneurysm and to perform a ligation and resection of the right branch of the bypass. This was necessary due to the presence of a purulent and hemorrhagic fluid surrounding the right branch of the prostheses. We harvested a fragment of distal segment of the graft. The histopathological examination of this prosthesis segment taken from the immediate vicinity of the anastomosis showed the presence of the bacteria that caused ruptures of the prosthesis and of the sutures. At the time of the graft removal, the general status of the patient was relatively bad, so we decided not to prolong the operative time. Unfortunately, the outcome was not favorable, and the limb was lost, due to a poor perfusion of the limb.

**3. Discussion**

In vascular surgery, infections are a challenge even to an experienced surgeon. Superficial infections are treated relatively easily, the administration of antibiotics with an associated local debridement being sufficient in most cases.<sup>[17]</sup> But, in many of these conservatively treated cases, a superficial infection can be a risk factor for a deep infection, and the consequences may be catastrophic if the prosthesis is affected (the amputation rate may reach 70% in such cases).<sup>[4]</sup>



**Figure 4.** Purulent peri- and endophlebitis at the level of the venous graft (Trichrome Goldner staining × 200).

The risk factors that may trigger an infection are multiple, but studies have shown that the main cause is the intraoperative contamination of the prosthesis coming into contact with the surrounding tissues.<sup>[18]</sup> But there may be other causes as well: emergency reconstructive surgical interventions, extensive lymphatic dissection, a prolonged operative time (more than 2 hours), and a long hospitalization period.<sup>[19]</sup> In order to achieve effective prevention, our prophylactic option is to administer 1 to 2g Cefazolin before the onset of anaesthesia, which is then repeated every 8 hours for a period of 24 to 48 hours, postoperatively.

Another factor that may be associated with a high risk of infection is the type of prosthesis used. Dacron prostheses are more prone to contamination as compared to PTFE prostheses.<sup>[19,20]</sup> In fact, even according to our case records, Dacron prostheses were more frequently involved in the infectious process (n=8) versus PTFE (n=3), but an infection of a venous graft could happen as well.

Once the infectious process has been triggered, the initiation of the antibiotic treatment as early as possible is the key of success.<sup>[21]</sup> The duration of antibiotic administration after treatment by graft explantation is empirical, but at least 2 weeks of systemic antibiotics is recommended. Patients who received long-term antibiotics (parenteral antibiotics for 6 weeks, followed by oral antibiotics for 6 months) had significantly better results regarding reinfection than patients treated with short-term therapy (2 weeks).<sup>[22]</sup> In the case of a verified infection with MRSA, the therapeutic option is to administer vancomycin, in accordance with the recommendations provided by the literature.<sup>[23]</sup>

Nevertheless, in deep infections the basic treatment is surgical. Depending on the extension and depth of the infection determined via classification into the Samson groups, we have at our disposal different solutions. The optimal method is the one by which the graft is kept intact, but it needs to be associated with a local irrigation and a wide debridement of the tissues, in order to eliminate, as much as possible, all local sources of infection. Vacuum-assisted closure (VAC) or negative pressure wound therapy (NPWT) is an important modality for wound management.<sup>[22,24]</sup> Unfortunately at the time of our study this method was not available in our department in Romania.

Preservation of the graft is possible only in the cases of groups 2, 3, or 4, when no anastomosis is involved.<sup>[25,26]</sup> In fact in group 4 patients, the preferred method is to explant the prosthesis completely as well. Conservative treatment preserving the reconstruction is recommended only in patients who present with a high perioperative risk and severe comorbidities or those in which a complete explantation of the prosthesis is associated with a very high amputation risk and a concomitant reconstruction is not possible. We used this solution in 2 patients, where we decided to perform a partial explantation of the infected prosthesis, restoring the blood flow by interposing a new prosthesis and covering it with a muscle flap from the vicinity (latissimus dorsi for the axillo-femoral bypass and Sartorius for a femoro-popliteal bypass respectively). These procedures allowed us to maintain the perfusion of the limb. This procedure is described in the literature as well.<sup>[14,27]</sup> In the case of extensive infections or in the situation where complications occur at the level of the anastomoses, as happens in the patients of Samson group 5, the only option is to explant the prosthesis completely. Blood flow can be restored either at the same time, usually via an extra-anatomic bypass or in situ graft, or, if the limb is not ischemic, the decision can be made to revascularize the limb in a

**Table 9****Review of recent vascular graft infections.**

	Infection rate	Amputation rate	Mortality
Erb et al <sup>[31]</sup>	20%		30%
Wilson et al <sup>[32]</sup>	20%	18%	18%
Kilic et al <sup>[33]</sup>	10%	25%	18%
Revillas et al <sup>[34]</sup>	0%–2.3%	16%	8%
Batt et al <sup>[35]</sup>	10.5%–16.8%	8.1%–15.4%	10.5%–16.8%

second staged procedure.<sup>[28,29]</sup> Insufficient perfusion leads to an increased rate of major amputations, as happened in 3 patients (20%) in our study. All of the patients with amputation presented with a MRSA infection, which proves once more that this bacteria is responsible for a high rate of amputation in patients with vascular prosthesis infection.

Our results compare very well with the results reported in the literature (Table 9). Ratliff et al<sup>[30]</sup> report an infection rate after vascular reconstructions of 15% in their single center analysis. In the latest studies for extracavitary vascular graft infections the operative mortality ranges from 0% to 30%, amputation from 0% to 25%, and recurrence of infection from 0% to 20%.

#### 4. Conclusion

The optimal treatment of infection is to prevent it. Despite all prophylactic measures, once the infection has occurred, it is a threat for the limb or even for the patient's life. The surgical strategy is based on determining the etiological agent as accurately as possible and verifying the depth of the infection. The optimal result is to save the prosthesis or vein graft, by associating a local debridement treatment to the antibiotic treatment. Nevertheless, the infection needs to be regarded as a dynamic phenomenon, with frequent changes in terms of the local situation. Having studied the literature, we have concluded that in case of infections, no treatment algorithm has yet been clearly established; instead, this is based on the personal experience of each individual vascular surgeon.

All procedures performed in studies involving human participants were in accordance with the ethical standards of the institutional and/or national research committee and with the 1964 Helsinki declaration and its later amendments or comparable ethical standards. For this type of study formal consent is not required.

#### Author contributions

**Conceptualization:** Octavian Andercou, Dorin Marian, Gabriel Olteanu, Bogdan Stancu, Beatrix Cucuruz, Thomas Noppeney.

**Investigation:** Octavian Andercou, Gabriel Olteanu, Bogdan Stancu, Thomas Noppeney.

**Methodology:** Octavian Andercou, Dorin Marian, Gabriel Olteanu, Bogdan Stancu, Beatrix Cucuruz.

**Supervision:** Dorin Marian, Thomas Noppeney.

**Validation:** Octavian Andercou.

**Visualization:** Octavian Andercou, Gabriel Olteanu, Bogdan Stancu, Beatrix Cucuruz, Thomas Noppeney.

**Writing – original draft:** Octavian Andercou, Dorin Marian, Gabriel Olteanu, Bogdan Stancu, Beatrix Cucuruz, Thomas Noppeney.

**Writing – review & editing:** Thomas Noppeney.

## References

- [1] Darouiche RO. Treatment of infections associated with surgical implants. *N Engl J Med* 2004;350:1422–9.
- [2] Saleem BR, Meerwaldt R, Tielliu IF, et al. Conservative treatment of vascular prosthetic graft infection is associated with high mortality. *Am J Surg* 2010;200:47–52.
- [3] Legout L, D'Elia PV, Sarraz-Bournet B. Diagnosis and management of prosthetic vascular graft infections. *Med Mal Infect* 2012;42:102–9.
- [4] Sousa JV, Antunes I, Mendes C, et al. Prosthetic vascular graft infections: a center experience. *Angiol Cir Vasc* 2014;10:52–7.
- [5] O'Hara PJ, Hertzner NR, Beven EG, et al. Surgical management of infected abdominal aortic grafts: review of a 25-year experience. *J Vasc Surg* 1986;3:725–31.
- [6] Valentine RJ. Diagnosis and management of aortic graft infection. *Semin Vasc Surg* 2001;14:292–301.
- [7] Siracuse JJ, Nandivada P, Giles KA, et al. Prosthetic graft infections involving the femoral artery. *J Vasc Surg* 2013;57:700–5.
- [8] Orton DF, LeVeen RF, Saigh JA. Aortic prosthetic graft infections: radiologic manifestations and implications for management. *Radiographics* 2000;20:977–93.
- [9] Thomas P, Forstrom L. In-111 labeled purified granulocytes in the diagnosis of synthetic vascular graft infections. *Clin Nucl Med* 1994;19:1075–8.
- [10] Teixeira G, Loureiro L, Machado R, et al. Groin wound infection in vascular surgery. A one year institutional incidence. *Angiol Cir Vasc* 2015;1:3–10.
- [11] Engin C, Posacioglu H, Ayik F, et al. Management of vascular infection in the groin. *Tex Heart Inst J* 2005;32:529–34.
- [12] Dosluoglu HH, Loghmanee C, Lall P, et al. Management of early (<30 days) vascular groin infections using vacuum-assisted closure alone without muscle flap coverage in a consecutive patient series. *J Vasc Surg* 2010;51:13–7.
- [13] Mohammed S, Pisimisis GT, Daram SP, et al. Impact of intraoperative administration of local vancomycin on inguinal wound complications. *J Vasc Surg* 2013;57:1079–83.
- [14] Calligaro KD, Veith FJ, Schwartz ML, et al. Selective preservation of infected prosthetic arterial grafts. Analysis of a 20-year experience with 120 extracavitary-infected grafts. *Ann Surg* 1994;22:461–71.
- [15] Szilagyi DE, et al. Infection in arterial reconstruction with synthetic grafts. *Ann Surg* 1972;176:321–33.
- [16] Samson RH, et al. A modified classification and approach to the management of infections involving peripheral arterial prosthetic grafts. *J Vasc Surg* 1988;8:147–53.
- [17] FitzGerald F, Kelly C, Humphreys H. Diagnosis and treatment of prosthetic aortic graft infections: confusion and inconsistency in the absence of evidence. *J Antimicrob Chemother* 2005;56:996–9.
- [18] Zetrenne E, McIntosh BC, McRae MH, et al. Prosthetic vascular graft infection: a multi-center review of surgical management. *Yale J Biol Med* 2007;80:113–21.
- [19] Swain TW 3rd, Calligaro KD, Dougherty MD. Management of infected aortic prosthetic grafts. *Vasc Endovascular Surg* 2004;38:75–82.
- [20] Post S, Kraus T, Muller-Reinartz U, et al. Dacron vs polytetrafluoroethylene grafts for femoropopliteal bypass: a prospective randomised multicenter trial. *Eur J Vasc Endovasc Surg* 2001;22:226–31.
- [21] Legout L, Sarraz-Bournet B, D'Elia PV, et al. Characteristics and prognosis in patients with prosthetic vascular graft infection: a prospective observational cohort study. *Clin Microbiol Infect* 2012;18:352–6.
- [22] Young MH, Upchurch GR, Malani PN. Vascular graft infections. *Infect Dis Clin N Am* 2012;26:41–56.
- [23] Venkatesan AM, Kundu S, Sacks D, et al. Society of Interventional Radiology Standards of Practice Committee. Practice guidelines for adult antibiotic prophylaxis during vascular and interventional radiology procedures. Written by the Standards of Practice Committee for the Society of Interventional Radiology and Endorsed by the Cardiovascular Interventional Radiological Society of Europe and Canadian Interventional Radiology Association. *J Vasc Interv Radiol* 2010;21:1611–30.
- [24] Dosluoglu HH, Schimpf DK, Schultz R, et al. Preservation of infected and exposed vascular grafts using vacuum assisted closure without muscle flap coverage. *J Vasc Surg* 2005;42:989–92.
- [25] Yasim A, Gul M, Ciralik H, et al. Gelatin-sealed dacron graft is not more susceptible to MRSA infection than PTFE graft. *Eur J Vasc Endovasc Surg* 2006;32:425–30.
- [26] Chalmers RT, et al. Improved management of infrainguinal bypass graft infection with methicillin-resistant *Staphylococcus aureus*. *Br J Surg* 1999;86:1433–6.
- [27] Meland NB, et al. Muscle-flap coverage for infected peripheral vascular prostheses. *Plast Reconstr Surg* 1994;9:1005–11.
- [28] Nagpal A, Sohail MR. Prosthetic vascular graft infections: a contemporary approach to diagnosis and management. *Curr Infect Dis Rep* 2011;13:317–23.
- [29] Treska V, Houdek K, Vatchova M, et al. Management of the prosthetic vascular graft infections: the incidence of predictive factors on treatment results. *Bartisl Lek Listy* 2008;109:544–50.
- [30] Ratliff CR, Strider D, Flohr T, et al. Vascular graft infection: incidence and potential risk factors. *J Wound Ostomy Continence Nurs* 2018;44:524–7.
- [31] Erb S, Sidler JA, Elzi L, et al. Surgical and antimicrobial treatment of prosthetic vascular graft infections at different surgical sites: a retrospective study of treatment outcomes. *PLoS One* 2014;9:e112947.
- [32] Wilson WR, Bower TC, Creager MA, et al. Vascular graft infections, mycotic aneurysms, and endovascular infections; a scientific statement from the American Heart Association. *Circulation* 2016;134:e412–60.
- [33] Kilic A, Arnaoutakis DJ, Reifsnnyder T, et al. Management of infected vascular grafts. *Vasc Med* 2016;21:53–60.
- [34] Revillas FA, Sampedro MF, Garcia AM, et al. Daptomycin treatment in Gram-positive vascular graft infections. *Int J Infect Dis* 2018;68:69–73.
- [35] Batt M, Camou F, Coffy A, et al. A meta-analysis of outcomes of in situ reconstruction after total or partial removal of infected abdominal aortic grafts. *Angiology* 2018;69:1–7.