

Pseudo-Lyre Sign

Authors: R Nash and R Farrell

Location: Northwick Park Hospital, London, UK

Citation: Nash R, Farrell R. Pseudo-Lyre Sign. JSCR. 2011 2:2

ABSTRACT

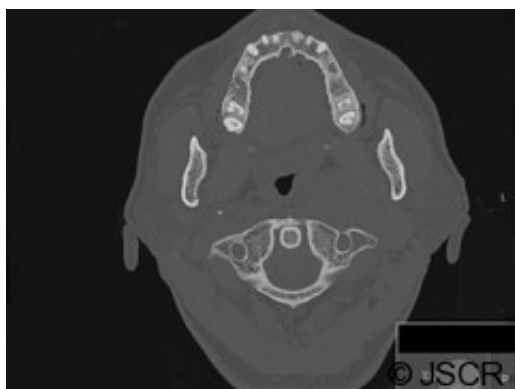
Carotid body tumours cause characteristic splaying of the internal and external carotid arteries, known as 'Lyre Sign'. Vagal paragangliomas are rare tumours that arise from glomus cells along the length of the vagus nerve. We present a case in which a vagal paraganglioma has arisen from the vagus nerve at the carotid bifurcation, and has mimicked the 'Lyre Sign' of a carotid body tumour.

INTRODUCTION

Head and neck paragangliomas, or glomus tumours, are highly vascular tumours arising from paraganglionic tissue. They most commonly arise from characteristic locations including the carotid bifurcation, the jugular fossa, tympanic cavity, and the vagus nerve, but may rarely arise from other locations such as the larynx. (1) The carotid body is the most common site for these tumours to arise, and these carotid body tumours characteristically splay the internal and external carotid arteries. This is known as 'Lyre Sign'. (2) Other tumours in the parapharyngeal space can lead to anterior or posterior dislocation of the carotid arteries. (3) We present a case in which this characteristic finding has been caused by a vagal paraganglioma.

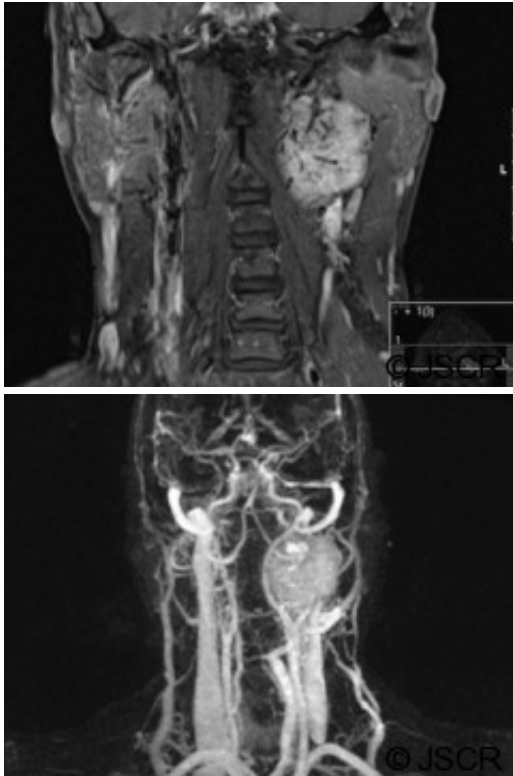
CASE PRESENTATION

A 48 year old woman presented with a six month history of left sided pulsatile tinnitus and fainting episodes. On examination, there was a true pulsatile tinnitus, and the oropharynx was deviated away from the left side into the midline. CT scanning demonstrated a mass at the left carotid bifurcation (Figure 1).



MRI with magnetic resonance angiography demonstrated the characteristic imaging findings of

a carotid body tumour. These include a salt-and-pepper appearance on standard spin echo (Figure 2), and splaying of the internal and external carotid arteries (Figure 3).



At the time of operation, the mass arose from the vagus nerve, and extended superiorly to the skull base. Obliteration of the sigmoid sinus was required to resect the tumour safely. The patient suffered from transient dysphagia and odynophagia post-operatively, but otherwise made a good recovery. Histology revealed a paraganglioma. The patient was well upon review six months post-operatively.

DISCUSSION

There are two previous reports of vagal paragangliomas mimicking a carotid body tumour. (4,5) Furthermore there are reports of a parathyroid carcinoma mimicking a carotid body tumour, and a carotid aneurysm causing splaying of the carotid arteries. (6,7) In this case, a vagal paraganglioma demonstrated the characteristic 'Lyre Sign' of a carotid body tumour. It is expected that these tumours will have the same intrinsic imaging characteristics, as they have the same histological basis, however it is unusual for a vagal paraganglioma to arise within the carotid sheath at the point of the carotid bifurcation.

It is important to consider the differential diagnosis of carotid bifurcation masses prior to surgical resection. Not only may the nature of resection be different, but the pre-operative investigation of these patients also varies. Carotid body tumours, for example, may be associated with phaeochromocytoma, however vagal paragangliomas are more commonly seen in familial syndromes, and are more likely to be multifocal. In this case, the tumour extended superiorly to the skull base, necessitating obliteration of the sigmoid sinus in order to safely gain vascular control of the tumour prior to resection.

This case demonstrates that differential diagnoses should be considered even when distinctive imaging characteristics of carotid body tumour are found.

REFERENCES

1. [Karaman E, Isildak H, Yilmaz M, et al. Management of paragangliomas in otolaryngology practice: review of a 7-year experience. J Craniofac Surg. 2009. 20\(4\):1294-7](#)
2. [Patlola R, Ingraldi A, Walker C, Allie D, Khan IA. Carotid Body Tumour. Int J Cardiol. 2009. 143\(1\):e7-e10](#)
3. [Shirakura S, Tsunoda A, Akita K, et al. Parapharyngeal space tumors: anatomical and image analysis findings. Auris Nasus Larynx. 2010 Oct;37\(5\):621-5](#)
4. [Caldarelli C, Iacconi C, Della Giovampaola C, Iacconi P, Beatrice F. Vagal paragangliomas: two case reports. Acta Otorhinolaryngol Ital. 2007 Jun;27\(3\):139-43](#)
5. [Singh D, Krishna PR. Paraganglioma of the vagus nerve mimicking as a carotid body tumor. J Vasc Surg. 2007 Jul;46\(1\):144](#)
6. [Ahmad W, Kanatas AN, Mitchell DA. Parathyroid carcinoma radiographically mimicking a carotid body tumour. Int J Oral Maxillofac Surg. 2010 Jun;39\(6\):620-2](#)
7. [Venkatanarasimha N, Olubaniyi B, Freeman SJ, Suresh P. Usual and unusual causes of splaying of the carotid artery bifurcation: the lyre sign-a pictorial review. Emerg Radiol. 2010 Sep 23](#)