

# You can use it there too (2): Deployment of the Bridge occlusion balloon during transvenous lead extraction via a persistent left superior vena cava



Gourg Atteya, MD, Laurence M. Epstein, MD, FHRS

From the Department of Cardiology Northwell Health, North Shore University Hospital, Zucker School of Medicine at Hofstra/Northwell, Manhasset, New York.

## Introduction

Superior vena cava (SVC) injuries/tears are the most lethal and feared complication of transvenous lead extractions. Although these injuries are rare (0.46% of all lead extractions performed),<sup>1,2</sup> they account for the majority of mortalities.

The Bridge Occlusion Balloon® (Philips-Spectranetics, Colorado Springs, CO) was developed and approved by the FDA as a rescue tool in the event of an SVC tear. It is a compliant balloon designed to temporarily occlude the site of injury, which in turn allows more time for surgical intervention. Since the inception of the Bridge balloon, there has been mounting evidence of its benefit in reducing mortality in the event of an SVC tear.<sup>3,4</sup> The Bridge balloon was developed and tested and has been used to help manage *right-sided* SVC tears.

A persistent left-sided superior vena cava (PLSVC) is the most common anomaly of systemic venous drainage (present in 0.5% of the general population and about 10% of those with congenital heart disease).<sup>5-7</sup> Cardiac device implantation in patients with PLSVC can be challenging and potentially carries a higher risk of complications.<sup>8-11</sup> It is critical for cardiac electrophysiologists to be familiar with such an uncommon anomaly when it comes to cardiac device management, and lead extraction is not an exception. There are case reports of performing transvenous lead extraction safely in patients with PLSVC.<sup>12,13</sup> We present here the first report of test deploying the Bridge balloon in the left SVC safely during a transvenous lead extraction involving a dual-coil implantable cardioverter-defibrillator (ICD) lead in a PLSVC.

**KEYWORDS** Bridge occlusion balloon; Cardiac implantable electronic devices; Lead extraction; Persistent left superior vena cava; Thoracic venous anomaly  
(Heart Rhythm Case Reports 2022;8:180-182)

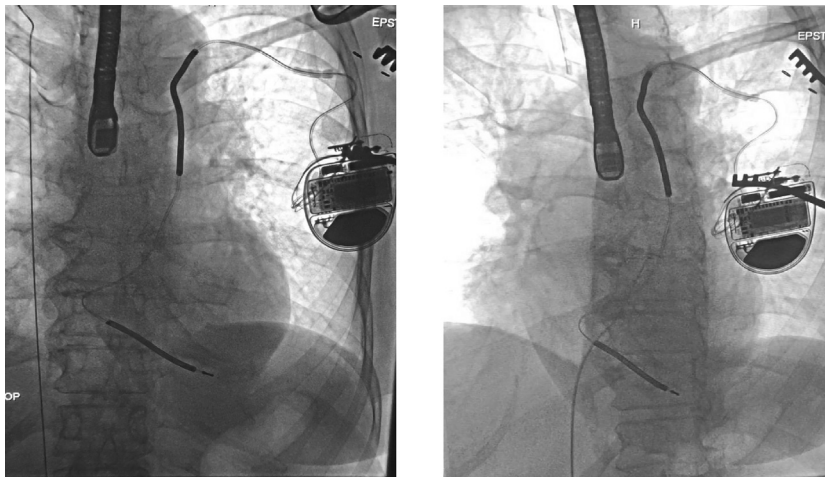
**Funding Sources:** This research did not receive any specific grant from funding agencies in the public, commercial, or not-for-profit sectors. **Disclosures:** The authors have no conflict of interests to disclose. **Address reprint requests and correspondence:** Dr Gourg Atteya, Department of Electrophysiology, Zucker School of Medicine at Hofstra/Northwell, 300 Community Dr, Manhasset, NY 11030. E-mail address: [gatteya@northwell.edu](mailto:gatteya@northwell.edu).

## KEY TEACHING POINTS

- Persistent left-sided superior vena cava (PLSVC) is the most common anomaly of systemic venous drainage. Cardiac device implantation and extraction could be challenging in such cases
- The Bridge Occlusion Balloon (Philips-Spectranetics, Colorado Springs, CO) was developed and approved as a rescue tool in cases of SVC tear. This important tool has been tested and used to manage *right-sided* SVC tears.
- We report the first case of test deploying the Bridge Occlusion Balloon in the *left* SVC safely during transvenous lead extraction of a dual-coil implantable cardioverter-defibrillator lead implanted via a PLSVC.
- The Bridge Occlusion Balloon remains a critical tool in our armamentarium to safely perform transvenous lead extractions, even with cardiac devices implanted via a PLSVC.

## Case report

The patient is a 74-year-old woman with a history of non-ischemic cardiomyopathy (left ventricular ejection fraction 35%) who underwent a single-chamber dual-coil ICD (Medtronic 6942) implant for primary prevention 22 years prior. She was transferred to our institution for transvenous lead extraction, after being diagnosed with endocarditis. A pre-procedure chest radiograph demonstrated that her ICD lead was implanted via a PLSVC. A super-stiff guidewire was advanced via the right femoral vein into the right atrium. It was easily passed into the right-sided SVC (Figure 1, left panel). Utilizing a multipurpose guide catheter, the ostium of the coronary sinus was easily cannulated (Figure 1, right panel). The wire was advanced into the PLSVC, adjacent to the SVC coil of the ICD lead and up into the right internal



**Figure 1** Left panel: Guidewire in right superior vena cava and dual-coil implantable cardioverter-defibrillator lead in place via persistent left-sided superior vena cava (PLSVC). Right panel: Cannulation of coronary sinus and then PLSVC.

jugular vein. The Bridge balloon was successfully deployed and inflated to ensure it could occlude the PLSVC in the unlikely event of a tear (Figure 2). The balloon was deployed safely, the volume for proper inflation noted, and the position on the catheter marked. The balloon was then deflated and withdrawn to the IVC. The guidewire was left in the PLSVC.

The procedure was carried out as previously reported.<sup>14</sup> Briefly, the procedure was performed under invasive blood pressure monitoring, general anesthesia, and transesophageal echocardiogram monitoring. The device pocket was opened, the generator was disconnected from the ICD lead, the anchor

was removed, and the lead was mobilized to the venous entry site. The active-fixation mechanism was retracted and the lead was cut. A locking stylet (EZ®; Phillips, Amsterdam, Netherlands) was inserted distally and a #5 silk tied to the outer insulation. The dual-coil defibrillator lead showed lead-to-vessel binding and required a 16F laser sheath (GlideLite®; Phillips, Amsterdam, Netherlands) for extraction (Figure 3, left panel). Complete procedural success was achieved (Figure 3, right panel).

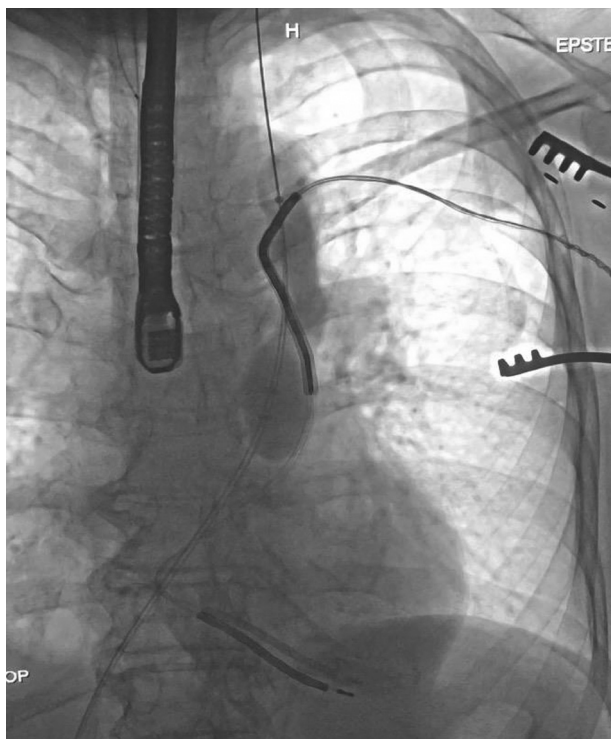
## Discussion

We report a case of transvenous lead extraction in a patient with a dual-coil ICD implanted via a PLSVC. There have been many reports of using the Bridge balloon in the right SVC in cases of tears/injury. We previously published using the Bridge balloon in a case of left subclavian injury.<sup>15</sup> To our knowledge, this is the first report demonstrating the feasibility of deploying and inflating the Bridge balloon in a PLSVC.

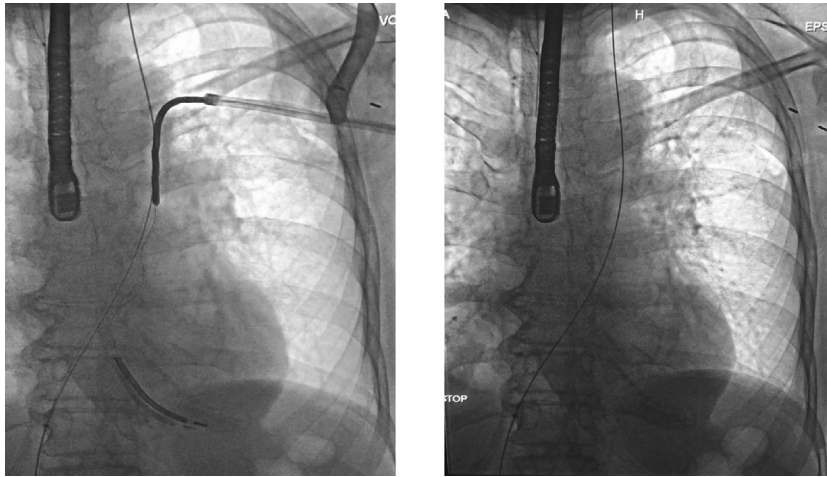
PLSVC is an uncommon thoracic venous anomaly that implanting electrophysiologists may encounter. Unfortunately, just like leads implanted via a right-sided SVC, leads implanted via a PLSVC may require extraction. This case demonstrates that the Bridge occlusion balloon can be safely deployed in the PLSVC. It has become standard practice to place a guidewire via the femoral vein through the SVC to the right internal jugular vein prior to extraction to serve as a guide should the Bridge balloon be required. In some cases, the balloon is staged on the wire. This report demonstrates that the same practice can be employed for extraction from the PLSVC.

## Conclusion

We describe the first report of safely deploying the Bridge Occlusion Balloon to successfully occlude a PLSVC prior to dual-coil ICD lead extraction. This remains a critical tool



**Figure 2** Bridge Occlusion Balloon (Philips-Spectranetics, Colorado Springs, CO) inflated in the persistent left-sided superior vena cava.



**Figure 3** Left panel: Extraction of implantable cardioverter-defibrillator with 16F laser sheath. Right panel: Final result after successful extraction.

in our armamentarium to safely perform transvenous lead extraction procedures.

## References

1. Brunner MP, Cronin EM, Wazni O, et al. Outcomes of patients requiring emergent surgical or endovascular intervention for catastrophic complications during transvenous lead extraction. *Heart Rhythm* 2014;11:419–425.
2. Hauser RG, Katsiyannis WT, Gornick CC, Almquist AK, Kallinen LM. Deaths and cardiovascular injuries due to device-assisted implantable cardioverter-defibrillator and pacemaker lead extraction. *Europace* 2010;12:395–401.
3. Boyle TA, Wilkoff BL, Pace J, Saleem M, Jones S, Carrillo R. Balloon-assisted rescue of four consecutive patients with vascular lacerations inflicted during lead extraction. *Heart Rhythm* 2017;14:757–760.
4. Azarrafiy R, Tsang DC, Boyle TA, Wilkoff BL, Carrillo RG. Compliant endovascular balloon reduces the lethality of superior vena cava tears during transvenous lead extractions. *Heart Rhythm* 2017;14:1400–1404.
5. Perles Z, Nir A, Gavri S, et al. Prevalence of persistent superior vena cava and association with congenital heart anomalies. *Am J Cardiol* 2013;112:1214–1218.
6. Tyrak KW, Holda J, Holda MK, Koziej M, Piatek K, Klimek-Piotrowska W. Persistent left superior vena cava. *Cardiovasc J Afr* 2017;28:e1–e4.
7. Goyal SK, Punnam SR, Verma G, Ruberg FL. Persistent left superior vena cava: a case report and review of literature. *Cardiovasc Ultrasound* 2008;6:50.
8. Cheng Z, Deng H, Cheng K, et al. Implantation of a pacemaker in a patient with persistent left superior vena cava and absence of right superior vena cava. *Int J Cardiol* 2013;30:168.
9. Vijayvergiya R, Shrivastava S, Kumar A, et al. Transvenous defibrillator implantation in a patient with persistent left superior vena cava. *World J Cardiol* 2013; 26:109–110.
10. Seow SC, Agbayani MF, Lim TW, et al. Left ventricular pacing in persistent left superior vena cava: a case series and potential application. *Europace* 2013; 15:845–848.
11. Guenther M, Kolschmann S, Rauwolf TP, et al. Implantable cardioverter defibrillator lead implantation in patients with a persistent left superior vena cava - feasibility, chances, and limitations: Representative cases in adults. *Europace* 2013; 15:273–277.
12. Trenson S, Doering M, Hindricks G, Winnik S, Richter S. Transvenous lead extraction in a patient with persistent left superior vena cava. *HeartRhythm Case Rep* 2021;7:153–156.
13. Green E, Tran VQ, Birgersdotter-Green U, Pretorius V. Percutaneous extraction of ICD lead placed through a persistent left-sided superior vena cava with right superior vena cava atresia. *JSM Cardiothorac Surg* 2017;2:1005.
14. Epstein LM, Maytin M. Strategies for transvenous lead extraction procedures 2017;8:2702–2716.
15. Bhullar A, Alcantara S, Yu P, Epstein L. It works there too! Use of the endovascular occlusion balloon to rescue left subclavian vein injury during lead extraction. *HeartRhythm Case Rep* 2021;7:395–397.