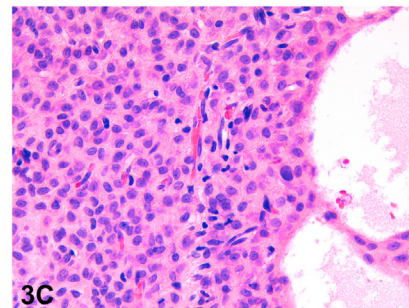
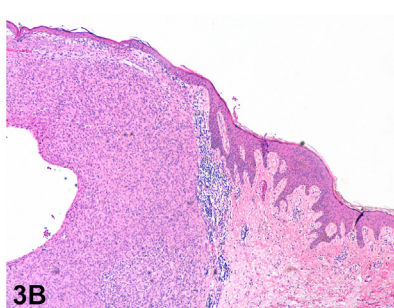
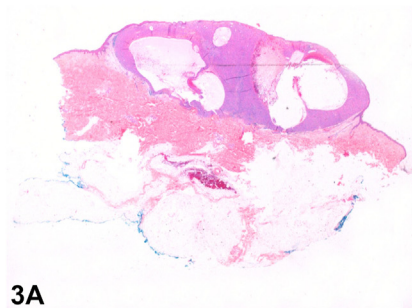
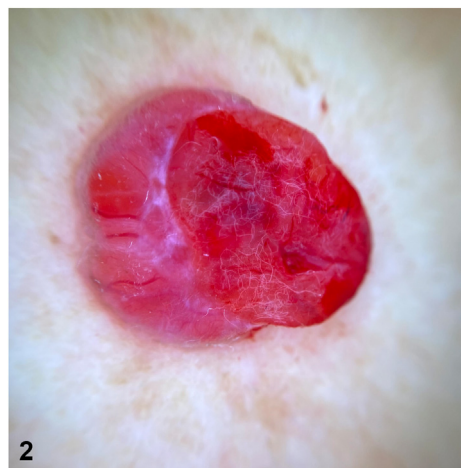
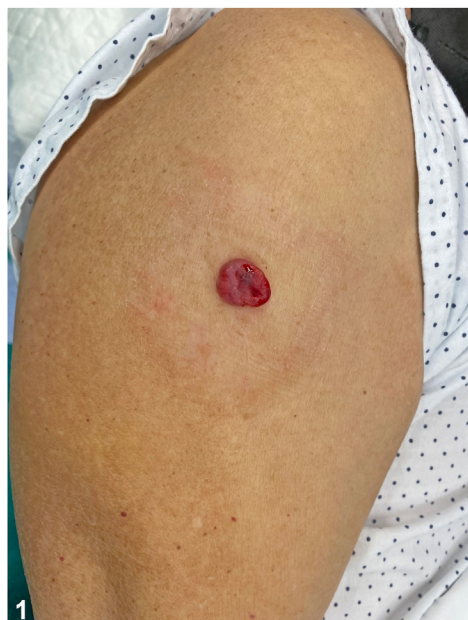
A sessile nodule with vascular appearance



Nicolás Silvestre-Torner, MD,^a Jorge Román-Sainz, MD,^a Fernando Gruber-Velasco, MD,^a
Belén Romero-Jiménez, MD,^a Adrián Imbernón-Moya, PhD,^a María Dorado-Fernández, MD,^a
Adrián Nogales-Moro, MD,^b and Fernando Burgos-Lázaro, MD^b
Leganés, Madrid, Spain

Key words: dermoscopy; epithelioid fibrous histiocytoma.



From the Department of Dermatology^a and the Department of Pathology,^b Hospital Universitario Severo Ochoa.

Funding sources: None.

IRB approval status: Not applicable.

Correspondence to: Nicolás Silvestre-Torner, MD, Plaza General Vara de Rey 11, 4G, Leganés Madrid, Spain 28005. E-mail: nicolassilvestretorner@gmail.com.

JAAD Case Reports 2022;23:171-3.
2352-5126

© 2022 by the American Academy of Dermatology, Inc. Published by Elsevier, Inc. This is an open access article under the CC BY-NC-ND license (<http://creativecommons.org/licenses/by-nc-nd/4.0/>).

<https://doi.org/10.1016/j.jdc.2022.02.042>

CASE

A 78-year-old man presented with a 4-month history of a progressively growing, bleeding, elevated sessile nodule, located in his right upper extremity (Fig 1). Polarized light noncontact dermoscopy revealed that the lesion had a vascular appearance (Fig 2). No previous trauma, arthropod bites, or systemic manifestations were reported. No regional lymphadenopathies were spotted. The histologic examination showed an exophytic proliferation, sharply circumscribed to papillary dermis, and a discrete epidermal collarette. The tumor was composed of nonatypical large epithelioid cells showing low mitotic activity, embedded in a fine collagenous stroma with prominent dilated blood vessels (Fig 3, A–C).

Question 1: Which of the following dermoscopic findings is not seen in this case?

- A. Red homogeneous lacunae
- B. Sticky fibers sign
- C. Arborizing blood vessels
- D. Shiny white streaks
- E. Pale septa

Answers:

A. Red homogeneous lacunae — Incorrect. Lacunae correspond histologically to dilated, thin-walled vessels in the papillary dermis. The red color corresponds to the presence of blood inside the vessels. They represent the main characteristic of vascular anomalies, including vascular tumors and malformations.¹

B. Sticky fibers sign — Incorrect. The sign of sticky fibers corresponds to the presence of textile fibers in the serum or blood in ulcerated tumors. It has been described in melanoma and squamous and basal cell carcinoma.

C. Arborizing blood vessels — Incorrect. Arborizing blood vessels correspond to superficial branching vessels located below the epidermis. They have a positive predictive value for basal cell carcinoma.¹ However; these could also be found in adnexal tumors, cysts, scars, and other malignant cancers, including melanoma and Merkel cell carcinoma.

D. Shiny white streaks — Correct. Shiny white streaks are parallel or perpendicular crystalline structures that correlate histopathologically with fibrosis in the dermis. They can be seen in melanocytic lesions, such as spitz nevi or melanoma, basal cell carcinoma, and benign lesions (eg, scars).

E. Pale septa — Incorrect. Pale septa are whitish structures between lacunae that correlate histologically with the presence of collagenous stroma between dilated blood vessels.

Question 2: Based on the clinical presentation, dermoscopy examination, and histologic features, what is the diagnosis?

- A. Amelanotic melanoma
- B. Pyogenic granuloma
- C. Epithelioid fibrous histiocytoma (EFH)
- D. Cutaneous metastasis
- E. Eccrine poroma

Answers:

A. Amelanotic melanoma — Incorrect. Amelanotic melanoma is characterized by irregular blood vessels without any pigmented structures under polarized dermoscopy. Histologically, nests of pleomorphic melanocytes with epidermal involvement are seen.

B. Pyogenic granuloma — Incorrect. Pyogenic granuloma presents as a rapidly growing vascular papule. Although reddish homogeneous areas can be found on dermoscopy, irregular vessels are infrequent.¹ On histology, it shows a lobular pattern of vascular proliferation with a central branching vessel.

C. EFH — Correct. EFH represents less than 1% of all benign fibrous histiocytomas (dermatofibromas). It commonly presents in the fifth decade, without sex preference, and is usually located in the extremities.² The predominance of epithelioid cells, the prominence of vascularization, and the sharp circumscription help to histologically differentiate EPH from other dermatofibromas.³ Therefore, this lesion can mimic a variety of nonfibrohistiocytic lesions, including vascular and melanocytic neoplasms, as well as cutaneous sarcomas.

D. Cutaneous metastasis — Incorrect. Skin metastases occur in 0.6% to 10.4% of all patients with cancer. Lung and breast carcinoma represent the most frequent visceral malignancies with cutaneous involvement. Although they have variable clinical appearances, most of the cases present as isolated or multiple firm nodules, with or without secondary

ulceration. Polymorphic vascular structures are usually seen on dermoscopic examination. The histologic and immunohistochemical examination of skin metastases may show similar characteristics to the internal malignancy to which they are related.

E. Eccrine poroma – Incorrect. Eccrine poroma is a benign adnexal tumor that originates from the acrosyringium and the terminal eccrine duct. Depending on the localization of the proliferation within the eccrine duct, different clinical, dermoscopic, and histopathologic variants have been described. Nonpigmented eccrine poroma presents as a long-time, pink-reddish, firm nodule with polymorphous vessels and structureless and lacunae-like areas. Histopathologically consists of aggregated small nodules of small cuboidal cells.⁴

Question 3: For what immunohistochemical markers will this lesion positively stain?

- A.** HMB45 and melan-A
- B.** Factor XIIIa and vimentin
- C.** Cytokeratins (CKs)
- D.** Desmin
- E.** CD34

Answers:

A. HMB45 and melan-A – Incorrect. Melanocytic markers, such as HMB45 and melan-A, are systematically negative. S-100 staining is also negative in the majority of the cases. However, S-100 protein can be focally seen due to the presence of reactive dendritic cells.

B. Factor XIIIa and vimentin – Correct. In the majority of the cases, more than 50% of the cells stain positively, with a moderate-to-strong nuclear and cytoplasmic pattern for factor XIIIa and other fibrohistiocytic proliferations.⁵ Vimentin cytoplasmic expression is positive in most of the cases, which confirms its mesenchymal origin and helps to differentiate from epithelial tumors. Moreover,

staining for anaplastic lymphoma kinase protein is also seen in the majority of EFH cases and can also be used as a distinguishing marker from its mimickers.²

C. CKs – Incorrect. CKs, such as CK5/6, CK7, and CK20, are epithelial markers used in the diagnosis of keratinocyte carcinomas and some adnexal tumors.

D. Desmin – Incorrect. Desmin is an immunomarker used to screen for myogenic differentiated proliferations.

E. CD34 – Incorrect. CD34 is a histologic marker used for hematopoietic progenitor cells and endothelial cells. In dermatopathology, it is mainly used to distinguish dermatofibroma from dermatofibrosarcoma protuberans. Although EFH does not typically express CD34, a subpopulation of CD34⁺ EFH has been reported.

Abbreviations used:

CK: cytokeratin

EFH: epithelioid fibrous histiocytoma

Conflicts of interest

None disclosed.

REFERENCES

1. Yélamos O, Braun RP, Liopyris K, et al. Dermoscopy and dermatopathology correlates of cutaneous neoplasms. *J Am Acad Dermatol*. 2019;80(2):341-363. <https://doi.org/10.1016/j.jaad.2018.07.073>
2. Felty CC, Linos K. Epithelioid fibrous histiocytoma: a concise review. *Am J Dermatopathol*. 2019;41(12):879-883. <https://doi.org/10.1097/DAD.0000000000001272>
3. Glusac EJ, McNiff JM. Epithelioid cell histiocytoma: a simulant of vascular and melanocytic neoplasms. *Am J Dermatopathol*. 1999;21(1):1-7. <https://doi.org/10.1097/00000372-199902000-00001>
4. Chessa MA, Patrizi A, Baraldi C, Fanti PA, Barisani A, Vaccari S. Dermoscopic–histopathological correlation of eccrine poroma: an observational study. *Dermatol Pract Concept*. 2019;9(4):283-291. <https://doi.org/10.5826/dpc.0904a07>
5. Singh Gomez C, Calonje E, Fletcher CD. Epithelioid benign fibrous histiocytoma of skin: clinico-pathological analysis of 20 cases of a poorly known variant. *Histopathology*. 1994;24(2):123-129. <https://doi.org/10.1111/j.1365-2559.1994.tb01290.x>