



RESEARCH ARTICLE

**REVISED** Lumboperitoneal shunt insertion without fluoroscopy guidance: Accuracy of placement in a series of 107 procedures [version 2; referees: 3 approved]

Sabah Al-Rashed <sup>1</sup>, Haider Kareem<sup>2</sup>, Neeraj Kalra<sup>2</sup>, Linda D’Antona<sup>1</sup>, Mouness Obeidat<sup>1</sup>, Bhavesh Patel<sup>1</sup>, Ahmed Toma<sup>1</sup>

<sup>1</sup>The National Hospital for Neurology and Neurosurgery, London, WC1N 3BG, UK

<sup>2</sup>Charing Cross Hospital, London, W6 8RF, UK

**v2** First published: 25 Apr 2017, 6:565 (doi: 10.12688/f1000research.11089.1)  
 Latest published: 30 Jun 2017, 6:565 (doi: 10.12688/f1000research.11089.2)

**Abstract**

**Background:** Lumboperitoneal (LP) shunts were the mainstay of cerebrospinal fluid diversion therapy for idiopathic intracranial hypertension (IIH). The traditionally cited advantage of LP shunts over ventriculoperitoneal (VP) shunts is the ease of insertion in IIH. This needs to be placed at the level of L3/4 to be below the level of the spinal cord. The objective of this study was to analyse the position of LP shunts inserted without portable fluoroscopy guidance. **Methods** : A retrospective analysis of radiology was performed for patients who underwent lumboperitoneal shunts between 2006 and 2016 at the National Hospital for Neurology and Neurosurgery. Patients who had insertion of a LP shunt without fluoroscopy guidance were selected. Patients without post-procedural imaging were excluded. A retrospective analysis of the clinical notes was also performed. **Results:** Between 2006 and 2016, 163 lumboperitoneal shunts were inserted in 105 patients. A total of 56 cases were excluded due to lack of post-procedural imaging; therefore, 107 post-procedural x-rays were reviewed. In 17 (15.8%) cases the proximal end of the LP shunt was placed at L1/L2 level or above. **Conclusions:** Insertion of LP shunts without portable fluoroscopy guidance gives a 15.8% risk of incorrect positioning of the proximal end of the catheter. We suggest that x-ray is recommended to avoid incorrect level placement. Further investigation could be carried out with a control group with fluoroscopy against patients without.

**Open Peer Review**

**Referee Status:** ✓✓✓

	Invited Referees		
	1	2	3
<b>REVISED</b>	✓	✓	✓
<b>version 2</b>			report
published			
30 Jun 2017	↑	↑	↑
<b>version 1</b>	?	?	?
published	report	report	report
25 Apr 2017			

---

1 **Uygur Er**, Düzce University, Turkey

2 **Rafid Al-mahfoudh**, Brighton and Sussex University Hospitals NHS Trust, UK

3 **Rossana Romani**, Imperial College London, UK

---

**Discuss this article**

Comments (0)

**Corresponding author:** Sabah Al-Rashed ([sabah.alrashed@gmail.com](mailto:sabah.alrashed@gmail.com))

**Author roles:** **Al-Rashed S:** Conceptualization, Data Curation, Investigation, Methodology; **Kareem H:** Investigation, Methodology, Project Administration; **Kalra N:** Writing – Original Draft Preparation, Writing – Review & Editing; **D’Antona L:** Data Curation, Formal Analysis; **Obeidat M:** Investigation, Methodology; **Patel B:** Data Curation, Investigation, Methodology; **Toma A:** Supervision

**Competing interests:** No competing interests were disclosed.

**How to cite this article:** Al-Rashed S, Kareem H, Kalra N *et al.* **Lumboperitoneal shunt insertion without fluoroscopy guidance: Accuracy of placement in a series of 107 procedures [version 2; referees: 3 approved]** *F1000Research* 2017, **6**:565 (doi: [10.12688/f1000research.11089.2](https://doi.org/10.12688/f1000research.11089.2))

**Copyright:** © 2017 Al-Rashed S *et al.* This is an open access article distributed under the terms of the [Creative Commons Attribution Licence](#), which permits unrestricted use, distribution, and reproduction in any medium, provided the original work is properly cited. Data associated with the article are available under the terms of the [Creative Commons Zero "No rights reserved" data waiver](#) (CC0 1.0 Public domain dedication).

**Grant information:** The author(s) declared that no grants were involved in supporting this work.

**First published:** 25 Apr 2017, **6**:565 (doi: [10.12688/f1000research.11089.1](https://doi.org/10.12688/f1000research.11089.1))

**REVISED Amendments from Version 1**

Following feedback from our referees, changes to the article have been made to clarify the term misplacement with regards to position of the LP shunts and to the outcomes of patients with misplaced shunts. We have also further clarified the indication for LP shunt within our patient population.

**See referee reports**

## Introduction

Historically, lumboperitoneal (LP) shunts were the mainstay of cerebrospinal fluid (CSF) diversion therapy for idiopathic intracranial hypertension (IIH). The traditionally cited advantage of LP shunts over ventriculoperitoneal (VP) shunts is the ease of insertion in IIH patients who usually have small and sometimes difficult to catheterise ventricles<sup>1-4</sup>.

Multiple studies have shown that when functional, LP shunts are effective in alleviating headaches and improving or stabilising visual symptoms in patients with IIH<sup>5-8</sup>. Studies have shown that IIH patients who underwent LP shunting had improvement in both visual acuity and visual fields with patients also reporting an improvement in headache symptoms post LP shunting<sup>6,9</sup>. In these previous studies, and in many others, the most common complication was shunt obstruction, with up to 65% of cases requiring revision in one study<sup>9</sup>. Other less frequent yet significant complications of LP shunts include infection, radiculopathy, shunt migration, syrinx, low pressure headaches, tonsillar herniation, subdural haematomas and potential damage of the distal end of the spinal cord.

The conus medullaris is the tapered, lower end of the spinal cord. Multiple cadaveric studies have demonstrated the level of the conus medullaris to be between T12 and L3<sup>10</sup>. Other studies report that the conus reaches the adult level by two years of age and lies at an average position of L1 to L2<sup>11</sup>. This position was also confirmed by a large radiological study performed in 1998<sup>10</sup>. Due to the proximity of the distal end of the spinal cord, it is best practice to avoid the insertion of LP shunts higher than L2/3 level. The ideal position for this procedure is considered to be at L3/L4 level or below.

The primary advantage of a LP over a VP shunt is the ability to cannulate the CSF space, in this case the thecal sac, as opposed to having to cannulate the very commonly found slit ventricles associated with IIH when considering a VP shunt<sup>1-4</sup>. However, there are also a series of challenges associated with this procedure.

Generally LP shunt patients are positioned in the lateral position to provide simultaneous access to the lumbar spine and flank. Percutaneous cannulation of the thecal sac can be very challenging, often requiring specific long needles. Additionally, it is often difficult to get the flexion (“foetal position”) required in these patients to open the interlaminar space and allow for the needle to access the thecal sac. Once the proximal catheter enters the thecal sac it needs to be threaded cranially into position, which is at times challenging as the catheter often kinks within the significant tissue volume. Following placement of the proximal catheter, the remainder

then needs to be tunneled through the subcutaneous tissue into the flank region. At this point, while in the lateral position and with the significant amount of adipose tissue, the surgeon then needs to identify the peritoneum. This can prove to be quite challenging given the non-anatomic patient’s position as well as the fact that gravity is working against the surgeon. At this point the catheter is then passed into the flank within the peritoneum.

The insertion of the catheter into the lumbar CSF space determines the success or failure of the LP shunt. Since this involves a manual manoeuvre with a “blind” tap, the catheter may be inadvertently placed incorrectly and migration of the shunt catheters is a common experience. The lumbar catheter can migrate relative to the thecal sac (usually into the subcutaneous space), and the peritoneal catheter can likewise come out of the peritoneum. The incidence ranges from 3–20%. Migration complications have been noted to be more common in the paediatric population<sup>4,12,13</sup>. When a catheter migrates out of the thecal sac, a subcutaneous collection of spinal fluid can be observed.

Newly onset radicular pain has been noted to occur with LP shunts. This may result from catheter migration or localised inflammation leading to arachnoiditis. The onset of symptoms may necessitate shunt revision. The incidence of developing newly onset radicular pain ranges from 5–6%<sup>13,14</sup>.

The efficacy of fluoroscopic guidance in the placement of a lumbar catheter in patients treated with an LP shunt has been reported<sup>9</sup>. The method includes using intraoperative portable fluoroscopy with contrast medium. The direction of the inserted catheter can be confirmed, and loop formation or absence thereof can be detected intraoperatively. It is possible to confirm that the catheter has not migrated into the extra-CSF space or the intervertebral foramen containing the spinal nerve roots. Improved visibility of the catheter in the spine, by filling it with contrast medium, is the key to the success of this procedure<sup>15</sup>. Intraoperative fluoroscopic guidance has become widely available in last two decades. Despite its efficacy, it exposes the patients and the staff to radiation. Moreover, there are possible side effects and restrictions related to the use of contrast medium, such as allergy, anaphylactic shock and acute renal failure. For these and other reasons, there is still a significant number of LP shunts operations that are performed without fluoroscopic guidance.

The National Hospital for Neurology and Neurosurgery offers dedicated hydrocephalus services and receives quaternary referrals from centres situated in the UK and abroad. The present study describes the accuracy of LP shunt placement without intraoperative fluoroscopic guidance over a 10-year period.

## Methods

### Patients and procedures

An analysis of the hospital electronic records identified 163 LP shunt procedures performed without fluoroscopic guidance on patients with a diagnosis of idiopathic intracranial hypertension (IIH). They were performed between 2006 and 2016. Cases with no post-procedural imaging were excluded (56), due to the impossibility to identify the level of the proximal catheter.

### Data collection and analysis

Post-procedural imaging was reviewed and reported by two independent operators who were blinded to each other's results and verified using visible anatomical landmarks on the x-ray, the location of the proximal end of the catheter was recorded. In all cases, the imaging used was lumbar x-ray. Clinical notes were also reviewed for those patients who had incorrect positioning of the proximal catheter to identify potentially related signs and symptoms, such as lumbar radiculopathy.

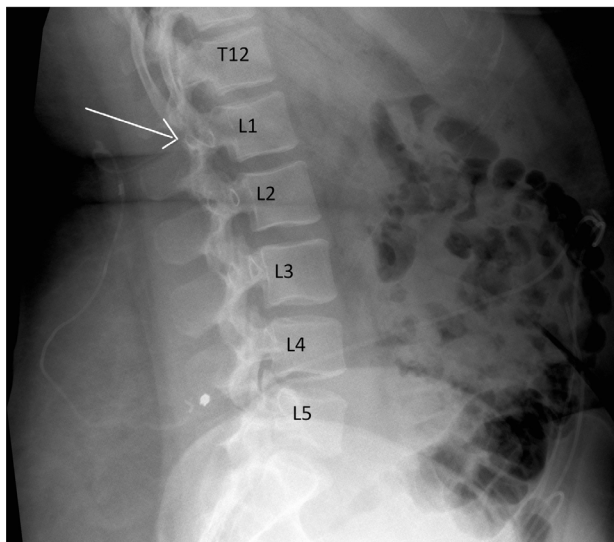
The data collection and analysis was carried out using Microsoft Excel 2010.

### Results

Between 2006 and 2016, 163 LP shunt procedures were performed on patients with IIH without intraoperative fluoroscopic guidance. After exclusion of the cases without post-procedural imaging (56), a total of 107 procedures performed on 73 patients were selected. A total of 57 patients were female and 16 were male (M:F, 1:3.5), the mean age was 41 years ( $\pm$  13 SD) ranging from 16–69 years.

The review of all post-procedural imaging showed that in 17 cases (15.8%) patients had the proximal catheter placed at the level of L1/L2 or above (T12/L1, 1.8%; L1/2, 14.0%) (Figure 1). On the other hand, in 94 cases (84.2%), patients had the proximal tip of the catheter placed at the level of L2/L3 or below (L2/3, 33.0%; L3/4, 37.4%; L4/5, 12.0%; L5/S1, 1.8%) (Table 1).

An analysis of the clinical notes of the patients who had mispositioned LP shunts was carried out for a minimal post-operative period of one year. None of the patients complained of signs or symptoms related to possible distal spinal cord damage.



**Figure 1.** Lateral lumbar x-ray showing incorrect level of lumboperitoneal shunt insertion.

**Table 1.** Number of cases of lumboperitoneal shunt insertion according to the level of insertion.

Level of insertion	Number of cases (%)
T12/L1	2 (1.8)
L1/L2	15 (14.0)
L2/L3	35 (32.7)
L3/L4	40 (37.4)
L4/L5	13 (12.0)
L5/S1	2 (1.8)

**Dataset 1.** X-rays showing the final position of the lumboperitoneal (LP) shunt in patients that underwent LP shunt insertion without fluoroscopic guidance

<http://dx.doi.org/10.5256/f1000research.11089.d154686>

### Discussion

This study demonstrates that, without intraoperative fluoroscopic guidance, an LP shunt insertion procedure can lead to a mispositioned proximal catheter in 15.8% of cases. Despite none of our patients presenting with any signs or symptoms of spinal cord damage, this risk needs to be considered when performing this procedure “blindly”.

One of the biggest challenges in performing LP shunts in IIH patients is often related to their habitus. It is in fact recognised that a strong association between IIH and obesity exists<sup>16</sup>. Approximately 70–80% of IIH patients are obese and over 90% are overweight<sup>16</sup>. In this group of patients finding the anatomical landmarks, maintaining them and inserting the lumbar catheter at the correct level, can represent a technical challenge; this is especially true when the procedure is performed without fluoroscopy guidance.

We suggest that the use of intra-operative imaging guidance should be adopted: this practice could reduce the incidence of mispositioned LP shunts and therefore decrease the risk of significant spinal cord damage, which may have serious, irreversible consequences.

The results of this series must be interpreted considering the limitations of the nature of any retrospective study. It could be argued that results achieved by our unit could vary markedly from those achieved at other units. We also do not take into account for operator experience, which may be partially responsible for the differences in success rate, and again may vary from individual to individual. Ultimately, to prove the efficacy and benefits of

intraoperative imaging for LP shunt insertion, large, prospective, randomised controlled studies should be performed.

## Conclusions

While this series is too small to conclude whether intraoperative imaging should be used to minimize the risk of misplaced proximal LP shunt catheters, it prepares the basis for further prospective studies. Our results suggest that LP shunt insertion without fluoroscopic guidance has a 15.8% risk of misplacement of the end position of the proximal catheter, and for this reason the use of intraoperative image guidance is suggested to reduce the risk of spinal cord damage and its potentially catastrophic consequences, although no spinal cord injury was noted as a result of misplacement in our patient population.

## Ethical statement

Ethical approval and registration was obtained from the National Hospital for Neurology and Neurosurgery.

This study was performed as part of an audit to analyse the current practice against the department policy standards.

## Data availability

**Dataset 1: X-rays showing the final position of the lumboperitoneal (LP) shunt in patients that underwent LP shunt insertion without fluoroscopic guidance.** Each page of the dataset indicates a different procedure. doi, [10.5256/f1000research.11089.d154686](https://doi.org/10.5256/f1000research.11089.d154686)<sup>17</sup>

## Author contributions

Concept and design of study: SA-R, HK; acquisition of data: BP, LD'A; analysis and/or interpretation of data: NK, AT; drafting the manuscript: SA-R, MO, NK.

## Competing interests

No competing interests were disclosed.

## Grant information

The author(s) declared that no grants were involved in supporting this work.

## References

- Ingraham FD, Sears RA, Woods RP, *et al.*: **Further studies on the treatment of experimental hydrocephalus; attempts to drain the cerebrospinal fluid into the pleural cavity and the thoracic duct.** *J Neurosurg.* 1949; **6**(3): 207–15.  
[PubMed Abstract](#) | [Publisher Full Text](#)
- Matson DD: **A new operation for the treatment of communicating hydrocephalus; report of a case secondary to generalized meningitis.** *J Neurosurg.* 1949; **6**(3): 238–47.  
[PubMed Abstract](#) | [Publisher Full Text](#)
- Vander Ark GD, Kempe LG, Smith DR: **Pseudotumor cerebri treated with Lumbar-peritoneal shunt.** *JAMA.* 1971; **217**(13): 1832–1834.  
[PubMed Abstract](#) | [Publisher Full Text](#)
- Spetzler RF, Wilson CB, Grollmus JM: **Percutaneous lumboperitoneal shunt. Technical note.** *J Neurosurg.* 1975; **43**(6): 770–3.  
[PubMed Abstract](#) | [Publisher Full Text](#)
- Burgett RA, Purvin VA, Kawasaki A: **Lumboperitoneal shunting for pseudotumor cerebri.** *Neurology.* 1997; **49**(3): 734–9.  
[PubMed Abstract](#) | [Publisher Full Text](#)
- El-Saadany WF, Farhoud A, Zidan I: **Lumboperitoneal shunt for idiopathic intracranial hypertension: patients' selection and outcome.** *Neurosurg Rev.* 2012; **35**(2): 239–43; discussion 243–4.  
[PubMed Abstract](#) | [Publisher Full Text](#)
- Binder DK, Horton JC, Lawton MT, *et al.*: **Idiopathic intracranial hypertension.** *Neurosurgery.* 2004; **54**(3): 538–51; discussion 551–2.  
[PubMed Abstract](#) | [Publisher Full Text](#)
- Abubaker K, Ali Z, Raza K, *et al.*: **Idiopathic intracranial hypertension: lumboperitoneal shunts versus ventriculoperitoneal shunts—case series and literature review.** *Br J Neurosurg.* 2011; **25**(1): 94–9.  
[PubMed Abstract](#) | [Publisher Full Text](#)
- Burgett RA, Purvin VA, Kawasaki A: **Lumboperitoneal shunting for pseudotumor cerebri.** *Neurology.* 1997; **49**(3): 734–9.  
[PubMed Abstract](#) | [Publisher Full Text](#)
- Saiffudin A, Burnett SJ, White J: **The variation of position of the conus medullaris in an adult population. A magnetic resonance imaging study.** *Spine (Phila Pa 1976).* 1998; **23**(13): 1452–1456.  
[PubMed Abstract](#) | [Publisher Full Text](#)
- Wilson DA, Prince JR: **John Caffey award. MR imaging determination of the location of the normal conus medullaris throughout childhood.** *AJR Am J Roentgenol.* 1989; **152**(5): 1029–32.  
[PubMed Abstract](#) | [Publisher Full Text](#)
- Chumas PD, Kulkarni AV, Drake JM, *et al.*: **Lumboperitoneal shunting: a retrospective study in the pediatric population.** *Neurosurgery.* 1993; **32**(3): 376–83; discussion 383.  
[PubMed Abstract](#) | [Publisher Full Text](#)
- Eisenberg HM, Davidson RI, Shillito J Jr: **Lumboperitoneal shunts. Review of 34 cases.** *J Neurosurg.* 1971; **35**(4): 427–31.  
[PubMed Abstract](#) | [Publisher Full Text](#)
- Aoki N: **Lumboperitoneal shunt: clinical applications, complications, and comparison with ventriculoperitoneal shunt.** *Neurosurgery.* 1990; **26**(6): 998–1003; discussion 1003–4.  
[PubMed Abstract](#) | [Publisher Full Text](#)
- Sato K, Shimizu S, Oka H, *et al.*: **Intraoperative fluoroscopy with contrast medium for correct lumbar catheter placement in lumboperitoneal shunts.** *Kitasato Med J.* 2013; **43**: 155–158.  
[Reference Source](#)
- Subramaniam S, Fletcher WA: **Obesity and Weight Loss in Idiopathic Intracranial Hypertension: A Narrative Review.** *J Neuroophthalmol.* 2016; 1–9.  
[PubMed Abstract](#) | [Publisher Full Text](#)
- Al-Rashed S, Kareem H, Kalra N, *et al.*: **Dataset 1 in: Lumboperitoneal shunt insertion without fluoroscopy guidance: Accuracy of placement in a series of 107 procedures.** *F1000Research.* 2017.  
[Data Source](#)

# Open Peer Review

Current Referee Status:



---

## Version 2

Referee Report 14 August 2017

doi:[10.5256/f1000research.12972.r23922](https://doi.org/10.5256/f1000research.12972.r23922)



**Rafid Al-mahfoudh**

Brighton and Sussex University Hospitals NHS Trust, Brighton, UK

**Competing Interests:** No competing interests were disclosed.

**I have read this submission. I believe that I have an appropriate level of expertise to confirm that it is of an acceptable scientific standard.**

Referee Report 31 July 2017

doi:[10.5256/f1000research.12972.r23923](https://doi.org/10.5256/f1000research.12972.r23923)



**Rossana Romani**

Imperial College London, London, UK

The authors modified the article which is now ready for indexing.

**Competing Interests:** No competing interests were disclosed.

**I have read this submission. I believe that I have an appropriate level of expertise to confirm that it is of an acceptable scientific standard.**

Referee Report 11 July 2017

doi:[10.5256/f1000research.12972.r23924](https://doi.org/10.5256/f1000research.12972.r23924)



**Uygur Er**

Neurosurgery Department, Medical School, Düzce University, Düzce, Turkey

**Competing Interests:** No competing interests were disclosed.

**I have read this submission. I believe that I have an appropriate level of expertise to confirm that it is of an acceptable scientific standard.**

---

**Version 1**

Referee Report 26 May 2017

doi:10.5256/f1000research.11961.r22200

**Rossana Romani**

Imperial College London, London, UK

The article is interesting and it can be indexed after revision. Suggestions for revision as follows:

1. The introduction is too long and it needs to be shortened. The majority of the concepts in the introduction should be in the paragraph of the discussion.
2. A further paragraph regarding the surgical techniques and the insertion of the lumbar catheter should be added in the Results section. Details of the surgical technique are in the Introduction section.
3. 17 patients had post-operative misplacement of the lumbar catheter with no symptoms nevertheless the authors conclude that intraoperative image guidance is suggested in all procedures to avoid misplacement of the lumbar catheter. The authors need to report the literature data regarding the misplacement of the lumbar catheter and clinical symptoms related.
4. I agree that further randomised clinical trial with a large number of patients can clarify the utility of intraoperative image guidance during lumboperitoneal shunt insertion. The conclusions need revision.

**Is the work clearly and accurately presented and does it cite the current literature?**

Partly

**Is the study design appropriate and is the work technically sound?**

Yes

**Are sufficient details of methods and analysis provided to allow replication by others?**

Yes

**If applicable, is the statistical analysis and its interpretation appropriate?**

Not applicable

**Are all the source data underlying the results available to ensure full reproducibility?**

Partly

**Are the conclusions drawn adequately supported by the results?**

Partly

**Competing Interests:** No competing interests were disclosed.



**I have read this submission. I believe that I have an appropriate level of expertise to confirm that it is of an acceptable scientific standard, however I have significant reservations, as outlined above.**

Referee Report 08 May 2017

doi:[10.5256/f1000research.11961.r22202](https://doi.org/10.5256/f1000research.11961.r22202)



**Rafid Al-mahfoudh**

Brighton and Sussex University Hospitals NHS Trust, Brighton, UK

The population studied needs to be accurately defined - do all the LP (Lumboperitoneal) shunt patients in this study have a diagnosis of IIH?

Have the authors used fluoroscopic guidance for LP shunts at their institution? This should be mentioned and if yes, then a comparison of proximal catheter placement could be made with and without fluoroscopy.

Some of the introduction would be best moved to the discussion (probably paragraph 5 onwards) as this mostly elaborates on possible causes which may explain the results of the study.

Result section - clarify the indication for LP shunt (do all patients have a diagnosis of IIH)?

The drive for quality in healthcare in general and a reduction in revision surgery specifically, continues to gain momentum worldwide. The authors discuss the possibility that intraoperative fluoroscopy can improve accurate LP shunt placement and should be praised for providing an honest appraisal of their results / misplaced proximal catheter rates.

**Is the work clearly and accurately presented and does it cite the current literature?**

Yes

**Is the study design appropriate and is the work technically sound?**

Yes

**Are sufficient details of methods and analysis provided to allow replication by others?**

Partly

**If applicable, is the statistical analysis and its interpretation appropriate?**

Not applicable

**Are all the source data underlying the results available to ensure full reproducibility?**

No source data required

**Are the conclusions drawn adequately supported by the results?**

Yes

**Competing Interests:** No competing interests were disclosed.



**I have read this submission. I believe that I have an appropriate level of expertise to confirm that it is of an acceptable scientific standard, however I have significant reservations, as outlined above.**

Referee Report 03 May 2017

doi:[10.5256/f1000research.11961.r22457](https://doi.org/10.5256/f1000research.11961.r22457)



**Uygur Er**

Neurosurgery Department, Medical School, Düzce University, Düzce, Turkey

Authors claimed that using a fluoroscopic system may reduce the risk of misplacement of the proximal catheter. However, they did not see any spinal cord injuries or other complications due to misplacement. In conclusion section this needs clarifying. Misplacement rate was given but this was emphasized as a technical complication, not a harmful cause.

The second vital point is that it is unclear the meaning of misplacement according to this article. It should be clarified "misplacement". Did they use this term as the inserting vertebral level or the end position of the proximal catheter? Figure 1 showed wrong insertion points, but in the introduction section this was defined as "mislaced inside thecal sac due to migration". Besides, position of the patient doesn't change vertebral levels due to anatomical landmarks. For example, in lateral position, superior iliac line passes L-4/5 level like in anatomical position. Authors should give some strictly defined methods using fluoroscopy, positioning and evaluation to allow replication by others.

Following clarifying these points, this article may accepted for indexing after reviewing of the revised version.

**Is the work clearly and accurately presented and does it cite the current literature?**

Partly

**Is the study design appropriate and is the work technically sound?**

Yes

**Are sufficient details of methods and analysis provided to allow replication by others?**

Partly

**If applicable, is the statistical analysis and its interpretation appropriate?**

Yes

**Are all the source data underlying the results available to ensure full reproducibility?**

Yes

**Are the conclusions drawn adequately supported by the results?**

Partly

**Competing Interests:** No competing interests were disclosed.

**Referee Expertise:** Spine surgery

**I have read this submission. I believe that I have an appropriate level of expertise to confirm that it is of an acceptable scientific standard, however I have significant reservations, as outlined above.**

---