

Direct Cerebral Revascularization: Extracranial-intracranial Bypass

Abstract

In 1967, the first extracranial to intracranial (EC-IC) arterial anastomosis was performed. Since that time, EC-IC bypass surgery has become a widely accepted surgical treatment for patients with IC stenotic or occlusive atherosclerotic lesions. This article will discuss the history, indications, types, surgical methods, and complications of the EC-IC bypass.

Keywords: *Anastomosis, middle cerebral artery, posterior circulation, superficial temporal artery*

Introduction

Since the first STA-MCA procedure was described by Yasargil in 1969,³⁵ many variations have been reported. Many of these variations have been developed in dealing with complex cerebral aneurysms and skull base neoplasms in which vessel sacrifice is required. These variations include anastomoses between the bilateral anterior cerebral arteries; occipital artery-to-posterior, inferior cerebral artery (PICA), anterior and inferior cerebral artery (AICA). Others includes PICA to PICA, vertebral artery to PICA, STA to SCA or PCA, subclavian artery to PCA, PCA to SCA, and even a tandem occipital artery to AICA and PICA anastomoses. Essentially any two vessels than can be liberated and approximated can be used to create an anastomosis. In terms of the surgical treatment of intracranial atherosclerosis, the main bypass procedure remains the STA-MCA bypass.

History of Revascularization

German and Taffel^[1] began to experiment with cerebral revascularization in 1939 with the transposition of a vascular muscle flap onto the cortex in dogs and primates; the first documented encephalomyosynangiosis. Kredel^[2] attempted this in humans in 1942 but later abandoned the procedure due to a high incidence of postoperative seizures. Soon after, in 1949, Beck *et al.*^[3] described their revascularization technique of a carotid-jugular fistula. Fisher^[4] had quite astutely stated in 1951, “it is

even conceivable that someday vascular surgery will find a way to bypass the occluded portion of the artery.” In 1961, Pool and Potts^[5] first attempted cerebral revascularization with a synthetic graft using a plastic tube to create a superficial temporal artery (STA) to anterior cerebral artery shunt. Arteriography performed <2 weeks after the operation showed a clotted tube. However, the patient apparently recovered well and was able to return to full-time work. In 1963, Woringer and Kunlin^[6] performed the first extracranial to intracranial (EC-IC) bypass of the common carotid artery CA – intracranial (IC) internal carotid artery (ICA) using a saphenous vein (SV) graft. While overall the patient did not survive, the graft was patent on autopsy.

In 1967, Yaşargil performed the first EC-IC bypass in a patient with the purpose of bypassing an occluded ICA.^[7] Yaşargil performed the first STA-middle cerebral artery (MCA) bypass for moyamoya disease in 1972. Karasawa *et al.*^[8] achieved good clinical results repeating this procedure in 23 patients with moyamoya syndrome. Lougheed performed the first EC-IC bypass using an SV graft in 1971, and Ausman used a radial artery graft in 1978. In the 1970s, Sundt *et al.*^[9] and others introduced posterior circulation revascularization. This was used to treat occlusive disease, vertebrobasilar insufficiency, and unclippable aneurysms.

Indications

To formalize the indications and outcomes of the EC-IC bypass, the international

**Sengottuvel
Thanapal,
Shyam Duvuru¹,
Treepob Sae-Ngow²,
Yoko Kato³,
Katsumi Takizawa⁴**

Department of Neurosurgery, Government Mohan Kumaramangalam Medical College, Salem, ¹Department of Neurosurgery, Gleneagles Global Hospitals, Chennai, Tamil Nadu, India, ²Department of Neurosurgery, Hua Hin Hospital, Hua Hin City, Thailand, ³Department of Neurosurgery, Banbuntane Hotokukai Hospital, Fujita Health University, Nagoya, ⁴Department of Neurosurgery, Asahikawa Red Cross Hospital, Hokkaido, Japan

Address for correspondence:

*Dr. Sengottuvel Thanapal,
Department of Neurosurgery,
Government Mohan
Kumaramangalam Medical
College, Salem - 636 001,
Tamil Nadu, India.
E-mail: drsengottuvelms@
gmail.com*

Access this article online

Website: www.asianjns.org

DOI: 10.4103/ajns.AJNS_76_17

Quick Response Code:



How to cite this article: Thanapal S, Duvuru S, Sae-Ngow T, Kato Y, Takizawa K. Direct cerebral revascularization: Extracranial-intracranial bypass. *Asian J Neurosurg* 2018;13:9-17.

This is an open access article distributed under the terms of the Creative Commons Attribution-NonCommercial-ShareAlike 3.0 License, which allows others to remix, tweak, and build upon the work non-commercially, as long as the author is credited and the new creations are licensed under the identical terms.

For reprints contact: reprints@medknow.com

cooperative study of EC-IC arterial anastomosis (EC-IC bypass study) was conducted from 1977 to 1985.^[10] This was an international, multicenter, prospective, randomized study, which was to test the concept of STA-MCA bypass surgery as a stroke prevention treatment. Specifically, the study evaluated the value of EC-IC bypass as a means to decrease the subsequent stroke rate for the treatment of “symptomatic atherosclerotic lesions of the ICA and/or MCA.” Ultimately, the data of the study suggested that EC-IC anastomosis was not better at preventing stroke in the patients with atherosclerotic arterial disease of the CA and MCA compared with best medical therapy. The study identified two important subgroups that appeared to do particularly poorly: patients with severe MCA stenosis and those with the persistence of ischemic symptoms in known ICA occlusion.

Pathophysiology

IC atherosclerosis leads to an ischemic cerebrovascular event through several differing processes: (1) Hypoperfusion, (2) thrombosis at the site of stenosis, (3) thromboembolism, and (4) direct occlusion of small perforating vessels.^[11]

The clinical presentation may vary from an acute ischemic deficit due to embolic or thrombotic sources to intermittent neurological symptoms from hypoperfusion. The pathophysiologic changes of chronic hypoperfusion due to IC arterial stenosis have been previously categorized into three stages:

- Stage 0: Normal hemodynamics
- Stage 1: Reflex vasodilation in response to inadequate collaterals and a falling perfusion pressure with resultant increases in cerebral blood volume and prolongation of mean transit time, but with preservation of cerebral blood flow (CBF) and normal oxygen extraction fraction (OEF)
- Stage 2: Misery perfusion in response to cerebral perfusion pressure falling below the range of autoregulatory capability exemplified by falling CBF and increasing OEF and maintenance of the cerebral metabolic rate of oxygen (CMRO₂).

Risk Factors and Progression

Progressive MCA stenosis, as evaluated by transcranial Doppler (TCD) studies, appears to be an independent risk factor for increased stroke risk because 32.5% of patients with progressive disease had a stroke by 26 months of follow-up. Severe stenosis (>70% stenosis), female gender, National Institutes of Health Stroke Scale score >1, concurrent diabetes, borderline body mass index values, hyperlipidemia, white ethnicity, and the presence of hemodynamic stenosis increases the risk for stroke.

Radiographic Evaluation

The initial assessment of transient ischemic attack (TIA) or stroke should include noncontrast head computed

tomography (CT) to exclude the possibility of IC hemorrhage and estimate the extent of ischemic change in consideration of thrombolysis. Diffusion-weighted magnetic resonance imaging (MRI) with or without magnetic resonance angiography (MRA), and perfusion studies can be subsequently obtained to better delineate the extent of ischemic injury as well as provide more information for further management decisions.^[11] The principle radiographic evaluations of IC flow related pathology revolve around visualization of the vessels and flow (i.e., TCD, angiography, MRA, and computed tomographic angiography [CTA]) or parenchymal perfusion (CT perfusion, positron emission tomography [PET], single-photon emission computed tomography [SPECT], and magnetic resonance perfusion studies).

MRA and CTA both provide excellent detail regarding the caliber of vessels; although, MRA has been shown to overestimate the degree of stenosis in some cases. In some series, time-of-flight MRA using 1.5-tesla MRI had a sensitivity of 90%–95%, a specificity of 95%, a positive predictive value (PPV) of 84%–86%, and a negative predictive value (NPV) of 97%–98%. The diagnostic accuracy ranged from 93% to 95% compared with digital subtraction angiography. The Stroke Outcomes and Neuroimaging of IC Atherosclerosis trial concluded that TCD had a PPV of 36% and an NPV of 86%, whereas MRA had a PPV of 59% and an NPV of 91%. These noninvasive techniques were sufficiently accurate to exclude more than 50% stenosis, but further confirmatory studies were needed to characterize the stenosis. TCD provides dynamic flow related results, but the gold standard remains digital subtraction angiography.

Perfusion

Perfusion studies^[11] include PET scans, SPECT scans, xenon CT perfusion studies, CT perfusion, and perfusion MRIs. These studies permit the extrapolation of CMRO₂, OEF, and CBF and provide information on the perfusion of the brain. The Japanese EC-IC bypass trial^[11] used SPECT imaging with an acetazolamide challenge to calculate hemodynamic parameters in patients. They used a technique of three-dimensional stereotactic surface projections with stereotactic extraction estimation to objectively quantify hemodynamic instability. The Carotid Occlusion Surgery Study^[12] employs measuring OEF by PET.

Surgical technique

The STA-MCA anastomosis represents the cornerstone of the EC-IC bypass. As a training exercise for more complex bypass procedures, STA-MCA anastomosis allows for the development of proper microsurgical dexterity and teaches the delicate handling of tissues necessary to learn the art of cerebral revascularization.

Patient Positioning

STA-MCA anastomosis can be performed with the patient on a donut or secured in a rigid frame. The patient is typically supine with the head turned more than 60°. Depending on the particular patient, head rotation up to 90° may be beneficial during the exposure and performance of the anastomosis.

Doppler Identification of the Superficial Temporal Artery

At this point, use a handheld Doppler probe to map out the course of the STA. The mapping is carried above the superior temporal line to be sure an adequate length of the STA is exposed. If the frontal branch is to be used, make a gently curving incision that increases vertically above the ear toward the superior temporal line and then curves anteriorly to reach the hairline, between the mid pupillary line and the midline. It is important to differentiate the typical venous signal of the superficial temporal veins from the more classic arterial pulsation of the STA.

Dissection of the Superficial Temporal Artery

The incision is generally started at the level of the zygoma and carried up over a length of several centimeters [Figure 1].

Exposure is conducted from the right above skin incision for STA parietal branch. Since STA is located within the dermis right above galea aponeurosis and provides blood to the muscle, epidermis, and pericranium in the region, many small branches toward those sites exist there. Superficial temporal veins are often located side-by-side around the

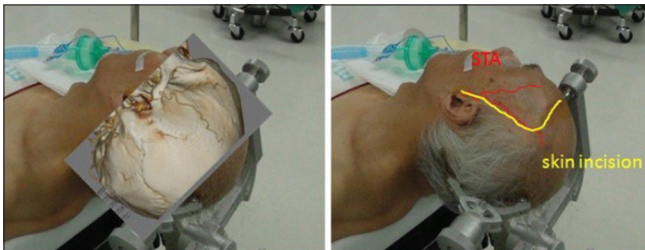

Figure 1: Patient positioning and marking of the skin incision

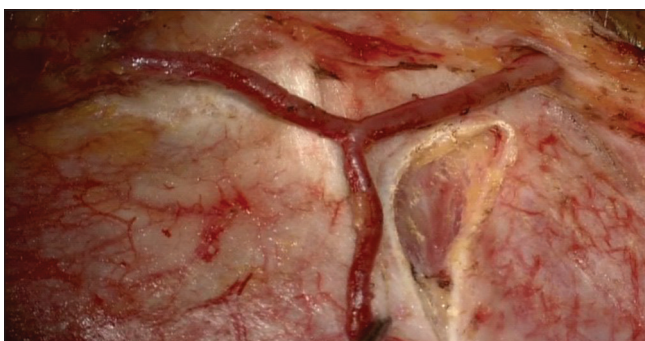

Figure 3: Exposure for superficial temporal artery

trunk. An appropriate tension toward diagonally upward against incised skin is required to conduct the dissection procedure more easily [Figure 2], but it also requires a cautious approach due to being more difficult to control the dissection procedure with excessive traction. When the exposure is conducted with this method, it is required to pay great attention to a treatment of blood vessel protectively (not excessively/directly grasp a blood vessel with tweezers) and avoid thermal damage or avulsion injury for branch [Figure 3].

We have generally placed two burr holes and then completed the craniotomy with a high-speed drill. Obviously, great care must be taken to protect the STA during the drilling. The craniotomy is generally circular with a roughly 2.5 cm diameter centered over the squamosal suture; although, larger or smaller openings can be made. Ideally, the opening should cover the Sylvian fissure to allow for exposure of a cortical MCA branch emerging from the fissure. The dura is opened in stellate fashion to maximize exposure of the cortical surface. Often, opening the arachnoid to allow for cerebrospinal fluid (CSF) to drain will relax the brain and facilitate the identification of a suitable recipient vessel, that is, “hiding” just at the edge of the craniotomy. We typically follow the Sylvian fissure first distally toward the angular gyrus, then proximally. If no vessel is identified, opening the fissure along its superficial aspect may reveal an appropriate MCA branch just below the surface. Care is taken to avoid inadvertent venous injury and to preserve

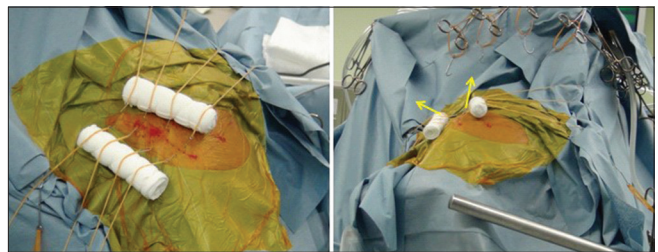


Figure 2: Draping and preparation

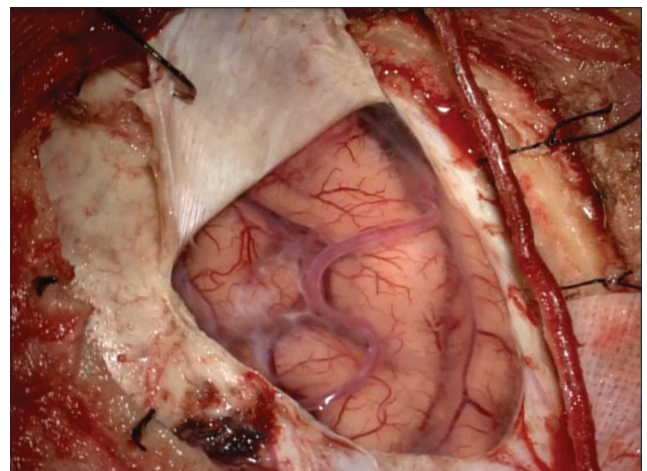


Figure 4: Craniotomy and dural incision

all cortical vessels that may be important in the setting of previous hemodynamic compromise. At times, a white, flattened artery that has been the victim of an old ischemic injury will be encountered. We have generally avoided the use of these vessels as a recipient.

Dural incision

Dural incision will be executed along with a large flap shape, but dura mater on temporal bone side should be incised by the length of 6–7 mm from the bone margin [Figure 4].

Dissection of the Recipient

Under high power magnification, the arachnoid overlying the recipient MCA branch is taken down. This can usually be achieved using jeweler’s forceps and a jeweler’s micro scissors. A small piece of background material slipped beneath the vessel will greatly facilitate the anastomosis as the opened, thin-walled vessel becomes surprisingly translucent when emptied of blood. The cautery should be turned to a very low setting when coagulating these branches to avoid transmission of current to the main vessel. In addition, the liberal application of topical papaverine will often help reverse narrowing created by iatrogenically induced spasm.

Preparation of recipient artery (M2)

When M2 is applied to “recipient a.,” MCA should be widely exposed with separating the Sylvian fissure. Select an appropriate region for anastomosis as carefully examining a blood vessel orientation and arterial sclerosis level. When deciding an anastomotic region, insert a silicon sheet under the blood vessel and then insert appropriate amount of gelform under the silicon sheet. Since MCA is slightly uplifted by this procedure and become a fixed condition with excessive tension, anastomosis can be performed more easily. Blood influx into the operative field during the anastomosis should be avoided by conducting hemostasis more rigorously. Since the anastomosis could be difficult for a wet operative field by CSF, the moist condition should be maintained by consistently suctioning CSF by setting a suction system connected nutrition tube for infant to a lower site of operative field. Conversely, when the operative field becomes an excessive dry condition, a suture thread would cause a trouble as sticking to surrounding tissue; therefore, it should be careful for the operative field to avoid an excessive dry condition. It

should also protect the brain surface around the anastomotic operative field by placing the gelfoam.

Stump forming of donor artery (superficial temporal artery)

STA stump forming will be performed right before anastomosis. Connective tissue around the stump should be thoroughly removed. For enlarging an apertural area of anastomosis, after we incise the stump with the angle of 60°, the wide apertural area on fish mouth can be formed by further incising one side for the same length as the diameter of the trimmed-off distal end [Figure 5]. The stump visibility should be improved by applying picrotanin (violet die) to outer membrane side of stump margin. This method offers a high usability, particularly for narrow and thin blood vessel. 10.0 or 9.0 nylon is used for anastomosis but normally two strings with the length of 5.0 cm should be used. Although zoom in/out for microscope will frequently be repeated during the anastomosis, the thread length up to 5.0 cm can be handled with visualization within the operational field. If the length is too long, it would take more time to check the needle and procedure, then if the length is too short, the anastomosis could not be completed with two strings; therefore, approximately 5 cm would be the appropriate length. After completing STA stump treatment, threading two strings to STA in advance is required for “stay suture.”

Final check before anastomosis

Incision length for MCA is important to be matched with a stump length for STA. The incision marking should be conducted while matching and measuring MCA with a trimmed STA stump. Incision length for thin wall blood vessel should be a little shorter if the wall thickness between STA and MCA has dissociation (normally the wall of STA is often thicker). Since a release of temporary blockage cannot be performed until anastomosis completion if once temporarily blocking and adding arteriotomy to MCA (it means no turning back after the execution), it is important to complete all the preparations before the temporary blockage from a viewpoint of shortening anastomosis time. Before performing the temporary blockage, the final confirmation should be carried out for the setting in the best condition. The anastomosis never be started until the satisfactory setting is carried out without any compromise [Figure 6].

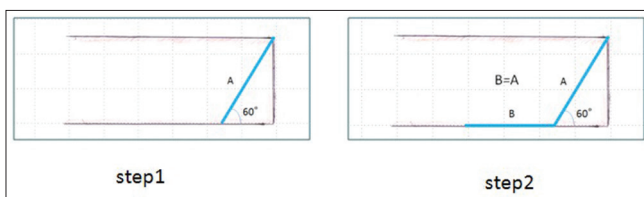


Figure 5: Fish mouth technique

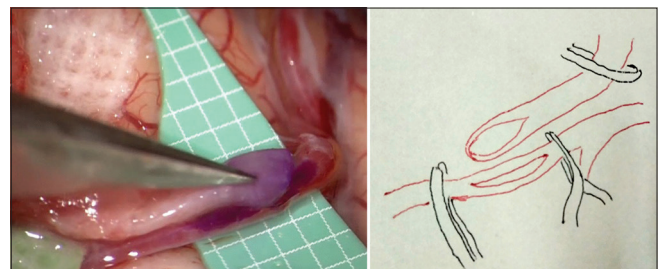


Figure 6: Final exposure before anastomosis (1), Illustration showing the final exposure before anastomosis (2)

Anastomosis

Initially, MCA (recipient a.) is temporarily blocked with appropriate clips but make sure whether the temporary blockage completes before MCA incision. It can be confirmed by the feel provided by grasping the blocked portion of MCA with tweezers. The most important procedure for vascular anastomosis is to precisely match inner membranes of “donor a.” and “recipient a.” (eversion technique) [Figure 7a]. To avoid the inner membrane damage, the inner membranes should not be strongly grasped by the tweezers. For the suture method, the suture insertion distance should be the same as thickness of blood vessel and a suture interval should be twice the blood vessel thickness [Figure 7b]. Make sure to tie up three times by one suture to avoid getting loose the knot. If it is sutured with such needle interval, total twenty stitches would be completed with “stay suture” in an ordinary M2 bypass, but the suture can normally be completed within 20 min. If an appropriate suture is performed, a blood leakage should not occurred from suture site and the site would be recognized as a favorable expansion at the time of releasing a temporary blockage [Figures 8 and 9].

Alternate method of Anastomosis

As an alternative, the suture can be placed in a running fashion, left loose initially, and then tightened at the conclusion. It is extremely difficult to maintain good

tension on the suture line because of the fine nature of the suture, so tightening the suture at the end works well.^[13]

Dural closure/wound closure

When closing a region penetrated by STA with dura mater mutually, a kinking would occur and the circulation would be slower when tightening the blood vessel too tightly, yet conversely a CSF leakage would occur when too loosely. To avoid this risk, we perform a dural closure with the following method. First, a dura mater and temporal muscle will be sutured approximately 3 cm as covering bone margin for a region penetrated by STA [Figure 10a]. Second, construct a caulescent small pedicle using a deep layer on the temporal side of temporal muscle as being reversed and incised in flap shape. Dura mater and temporal muscle with covering the bone margin should be sutured as wrapping STA with a side of this pedicle. Then, the dura mater should be closed after suturing other sides with dura mater [Figure 10b]. By this method, kinking and CSF leakage at the site of dura mater penetrated by STA will be prevented. It should also be careful to avoid an occurrence of kinking for blood vessel at bone margin even at the time of returning a bone flap to the original site and also frequently check to make sure there is no problem for STA blood circulation until the final wound closure by a Doppler ultra sound.

Pearls and Pitfalls Associated with Superficial Temporal Artery-Middle Cerebral Artery Anastomosis

Avoid:

- Tension on anastomosis
- Unnecessarily large craniotomy
- Overaggressive coagulation to achieve hemostasis
- Overaggressive retraction of STA during drilling of craniotomy

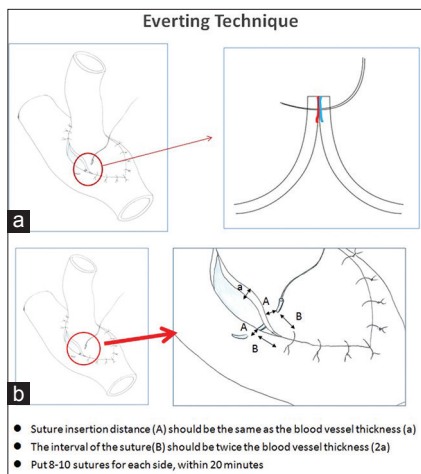


Figure 7: (a) Schematic drawing of eversion technique, (b) schematic drawing of suture method

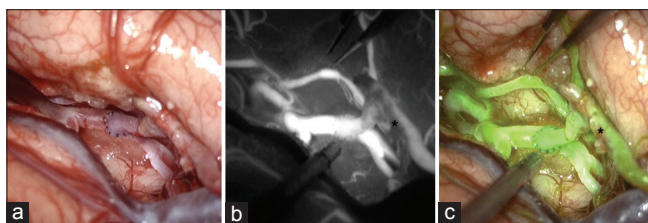


Figure 9: (a) Microscopic view, (b) indocyanine green view, and (c) dual image video angiography view

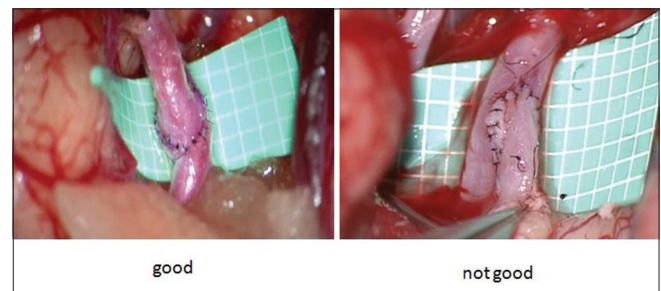


Figure 8: Compare the picture of the suture site

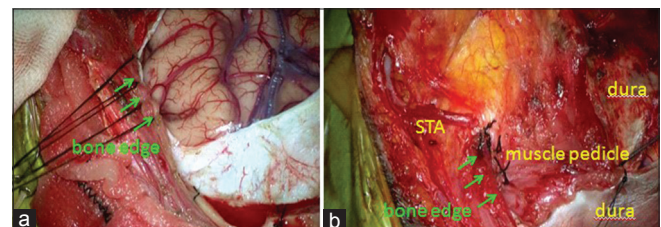


Figure 10: (a) Photographs of dural closure and (b) muscle closure

- Bypassing to white, flattened recipient artery
- Working in “wet” or “bloody” field
- Kinking or injuring STA during closure.

Do’s:

- Practice in microvascular laboratory
- Use high(est) power magnification
- Treat STA and MCA branch gently
- Expose long enough length of STA
- Create elongated, flat anastomosis
- Use interrupted sutures for very small vessels
- Orient STA to assume “comfortable,” natural orientation once bypass completed.

Complications

Complications associated with STA-MCA bypass have been limited, early postoperative TIA, delayed stroke, development of a pseudoaneurysm, and wound dehiscence.

Alternate Options and Special Circumstances

In rare cases, the STA may not be suitable for bypass. This may occur on a congenital basis, due to atherosclerotic disease, or as a result of prior surgery. In such cases, several options are available. A large occipital artery can be used in some instances. If the proximal STA is preserved, we have used short-segment venous grafts or even the contralateral STA, which has been harvested as a free graft at the start of the operation. Rarely, we have encountered a heavily calcified or atherosclerotic STA or MCA necessitating local end arterectomy to allow for anastomosis.^[13]

Postoperative Management

Generally start a full adult aspirin at 325 mg the day of surgery and continue that indefinitely. Patients who cannot tolerate this regimen are switched to 81 mg aspirin per day.^[13]

High-flow Cerebral Revascularization with Radial Artery and Saphenous Vein Grafts

Indications for high-flow bypass

Although most vascular lesions do not require parent artery sacrifice, many lesions require complex clip reconstruction techniques requiring extended temporary artery occlusion times. For example, large or giant aneurysms of the MCA bi-/tri-furcation may have branches originating from the fundus or close to the neck. In addition, the failure of endovascular techniques for complex vascular lesions can require more complex vascular reconstructions and/or endovascular material extraction at retreatment, necessitating longer occlusion times, and possible cerebral revascularization.^[14] The patients with complex vascular lesions are initially evaluated by a multidisciplinary team of neurosurgeons and neuroradiologists. If it is surmised that either long temporary occlusion times or parent artery sacrifice might be necessary, the patient is scheduled to undergo a balloon test occlusion.

Bypass graft selection

For high-flow bypass procedures, the conduits of choice are the radial artery and the SV, both of which can, in most cases, be easily harvested from the patient being treated. The radial artery has a flow rate ranging between 40 and 150 mL/min and a diameter between 2.5 and 3.5 mm.^[15,16] The advantages of the radial artery are that this conduit is normally equipped to handle the arterial blood flow. It has a homogeneous intra-luminal diameter without valves or varicosities. The smooth laminar blood flow is thought to reduce the incidence of thrombosis that occurs during temporary occlusion or a low-flow state. Furthermore, the luminal diameter more closely matches that of the M2 segment of the MCA and the P2 segment of the posterior carotid artery (PCA) than a vein graft. It has a predictable anatomic location that with training is straightforward to harvest. The main disadvantage of the radial artery is the potential for vasospasm, which often occurs following harvest; however, this can be reduced with preimplantation distension and maintenance of the graft in a solution of calcium channel blockers before implantation. There have been reports that the long-term patency of radial artery grafts is threatened by the loss of the vasa vasorum, which is disrupted during dissection.

The SV has a flow rate between 70 and 200 mL/min and an average diameter of 5 mm.^[15,17] The advantages of the SV graft are the ease of harvest, length of graft, absence of atherosclerotic changes, and large caliber. The disadvantages of SV grafts are frequent caliber mismatch, which leads to intra-luminal turbulent flow and thrombosis, the presence of valves, and the potential for kinking at the site of the recipient due to the thick surrounding tissue and vessel wall. Maintenance of the vessel orientation of SV grafts is critical for their functionality and durability as a vascular conduit.

Both vessels require two separate anastomoses and separate incisions for graft harvest, which increases the potential for complications. Long-term patency has not been directly compared between the radial artery and SV.

Intraoperative assessment of bypass patency

Intraoperative assessment of bypass patency and functionality can avoid complications due to premature graft stenosis or occlusion. Although intraoperative catheter angiograms remain the gold standard, this technique requires additional costs and risks to the patient. At our institution, we prefer bypass assessment using indocyanine green videoangiography, which provides a quick assessment of patency with little to no risk to the patient. We can determine the direction of flow and perform multiple assessments throughout the procedure.

Complications

Cerebral revascularization with high-flow bypass grafts is more prone to complications than their low-flow counterparts. Radial artery grafts may suffer vasospasm

or intimal hyperplasia after implantation and eventually occlude. However, SV grafts can undergo proatherogenic changes after implantation eventually leading to their occlusion as well. Thromboembolic complications are the most common after bypass procedures thought mainly due to the change in IC hemodynamics after parent vessel occlusion. Preoperative antiplatelet medications, as well as intraoperative anticoagulation, can reduce these thromboembolic events. In patients without vascular reserve, prolonged temporary occlusion times can lead to territory infarcts without changes in the cerebral monitoring. It is of paramount importance to minimize occlusion times in these patients or complete the revascularization procedure initially to avoid such ischemic risks. If the perfusion defect had been longstanding, reperfusion hemorrhage may be problematic after revascularization. Although the incidence is low and can mostly be predicted on provocative imaging studies, other complications involve the site of graft harvests such as infection, ischemic hand, or hematoma.

Postoperative considerations

The patients are maintained on aspirin therapy indefinitely and depending on mobility, on prophylactic doses of heparin beginning 24–48 h postoperatively. The patients are observed in the Intensive Care Unit for at least 48 h after revascularization. Blood pressure monitoring is strict and maintained at normo pressure (120–140 systolic). Graft patency should be monitored closely postoperatively with Doppler evaluation at the bedside every hour for the first 24 h, then twice a day thereafter. CTA is performed within 48 h to assess patency. At any point during the immediate postoperative period if there is a concern for the patency of the graft, a cerebral angiogram is performed. Follow-up imaging is performed at 3, 6, and 12 months after the procedure.

Other bypass procedures

Several other bypass strategies for high-flow bypass grafts have been developed. Frequently, the length of the harvested bypass graft is not adequate for deeper recipient vessels. However, an interposition graft made from the combination of either a radial artery or SV with the STA allows deep bypass procedures to be possible. Further, for patients that cannot tolerate any length of temporary occlusion, even for the performance of a revascularization procedure, the excimer laser-assisted nonocclusive anastomosis technique^[18] can be used. This technique allows the completion of a high-flow revascularization procedure using an SV graft without any temporary occlusion. Although this technique is being used more frequently, it still requires a tremendous amount of expertise.

Intracranial Posterior Circulation Techniques

The choice of bypass option depends on multiple factors, including the goals of the procedure, the availability and

accessibility of donor and recipient vessel, and the patient's particular pathology and anatomy.

The STA is the artery most commonly used as a donor vessel for PCA and superior cerebellar artery (SCA) revascularization. The STA also may be used for anterior inferior cerebellar artery (AICA) and posterior inferior cerebellar artery (PICA) bypasses. Frequently, the OA rather than the STA is used as the EC vascular conduit for revascularization of the AICA or PICA distributions.

Posterior Cerebral Artery and Superior Cerebellar Artery Revascularization

The patient's head is rotated to the contralateral side until the zygomatic arch is in the horizontal position. To facilitate this position, the ipsilateral shoulder may be elevated with a cushion. Then, the head is laterally flexed to support gravity related self-retraction of the temporal lobe. The skin incision is performed at a right angle to the zygomatic arch, 1 cm anterior to the external auditory meatus. After a subtemporal approach is performed in cases of STA-SCA anastomosis, the tentorial edge is identified, cut, and coagulated to increase exposure. During this maneuver, care must be taken not to damage the fourth cranial nerve, which courses below the edge of the tentorium. The fourth nerve must be visualized before the tentorial edge is cut and coagulated. The SCA is identified in the lateral pontomesencephalic segment.^[19]

A short segment of the SCA is then isolated between temporary clips. After the distal end of the cut STA is stripped from its fascial layer and cut into a shape that is suitable for the anastomotic site, it is tacked to the SCA at two points. A loose running 10-0 suture is placed along one wall. Tightening ensures uniform suture tension and improves hemostasis. Then, the suture on the front wall is placed to complete an end-to-side anastomosis.^[19]

The STA-to-SCA anastomosis is completed [Figure 11].

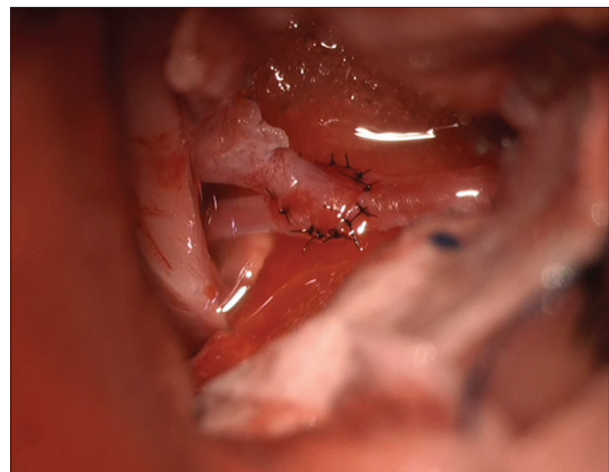


Figure 11: The final appearance showing superficial temporal artery-superior cerebellar artery anastomosis

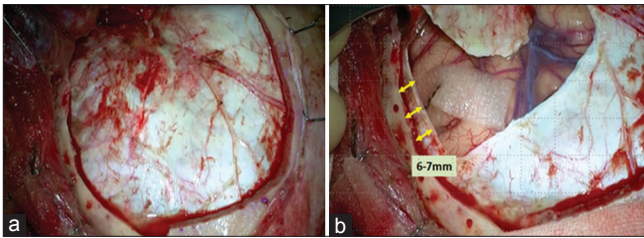


Figure 12: Intraop photographs showing craniotomy, dural incision

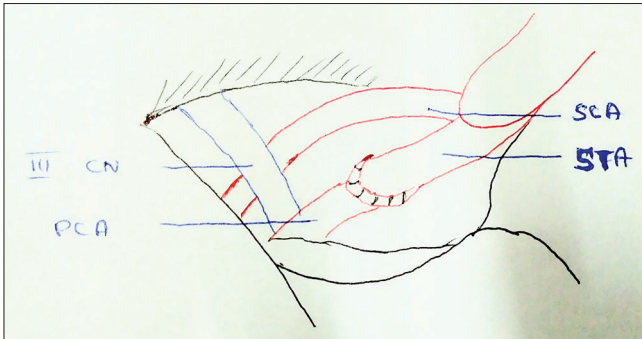


Figure 13: Illustration showing the superficial temporal artery to the posterior cerebral artery bypass respectively

Posterior Inferior Cerebellar Artery and Anterior Inferior Cerebellar Artery Revascularization

Unclippable aneurysms of the PICA and vertebral artery (VA) are typically dissecting or fusiform in nature. Some VA dissecting aneurysms and partially thrombosed aneurysms involve the origin of PICA and may be treated only with aneurysm trapping or parent vessel occlusion. If there is a high probability of disturbing PICA blood flow after surgical or endovascular treatment for a local aneurysm, PICA revascularization should be considered to prevent cerebellar infarction and lateral medullary syndrome. Options include an OA-PICA anastomosis,^[20] VA-PICA anastomosis using an interposition graft (STA or radial artery graft),^[21] an end-to-side or end-to-end reimplantation of the PICA into the VA, or a side-to-side PICA-PICA *in situ* bypass.

Superficial Temporal Artery-Posterior Cerebral Artery Anastomosis

Figure 12 and 13 shows intraop photograph and illustration shows the completed STA to posterior cerebral artery bypass respectively.

Conclusion

The STA-MCA anastomosis represents the most commonly performed EC-IC bypass. The basic microsurgical techniques employed in this operation can be mastered in the laboratory before entering the operating room. Due to the very small size of the vessels being anastomosed, continued practice is required to achieve and maintain the facility with this operation. In particular, the procedure should be performed on a regular basis to optimize bypass patency rates and to limit complications.

In the treatment of complex vascular disease, cerebral revascularization is necessary in the case of necessary extended temporary occlusion, absence of adequate collateral reserve, and requirement of parent artery sacrifice. High-flow cerebral revascularization can be successfully completed using either harvested radial artery or SV vascular grafts. Success is dictated by careful patient selection, meticulous surgical technique, thoughtful planning and perioperative care, and mindful knowledge of the potential pitfalls and complications that can accompany cerebral revascularization procedures.

Declaration of patient consent

The authors certify that they have obtained all appropriate patient consent forms. In the form the patient(s) has/have given his/her/their consent for his/her/their images and other clinical information to be reported in the journal. The patients understand that their names and initials will not be published and due efforts will be made to conceal their identity, but anonymity cannot be guaranteed.

Financial support and sponsorship

Nil.

Conflicts of interest

There are no conflicts of interest.

References

1. German WJ, Taffel W. Surgical production of collateral intracranial circulation: An experimental study. *Proc Soc Exp Biol Med* 1939;42:349-53.
2. Kredel FE. Collateral cerebral circulation by muscle graft: Technique of operation with report of 3 cases. *South Surg* 1942;10:235-44.
3. Beck CS, McKhann CF, Belnap WD. Revascularization of the brain through establishment of a cervical arteriovenous fistula; effects in children with mental retardation and convulsive disorders. *J Pediatr* 1949;35:317-29.
4. Fisher M. Occlusion of the internal carotid artery. *AMA Arch Neurol Psychiatry* 1951;65:346-77.
5. Pool DP, Potts DG. Aneurysms and Arteriovenous Anomalies of the Brain: Diagnosis and Treatment. New York: Harper & Row; 1965.
6. Woringer E, Kunlin J. Anastomosis between the common carotid and the intracranial carotid or the sylvian artery by a graft, using the suspended suture technic. *Neurochirurgie* 1963;9:181-8.
7. Yaşargil MG, editor. Diagnosis and indications for operations in cerebrovascular occlusive disease. In: *Microsurgery Applied to Neurosurgery*. Stuttgart: Georg Thieme Verlag, Academic Press; 1969. p. 95-118.
8. Karasawa J, Kikuchi H, Furuse S, Kawamura J, Sakaki T. Treatment of moyamoya disease with STA-MCA anastomosis. *J Neurosurg* 1978;49:679-88.
9. Sundt TM Jr., Whisnant JP, Piepgras DG, Campbell JK, Holman CB. Intracranial bypass grafts for vertebral-basilar ischemia. *Mayo Clin Proc* 1978;53:12-8.
10. Failure of extracranial-intracranial arterial bypass to reduce the risk of ischemic stroke. Results of an international randomized trial. The EC/IC Bypass Study Group. *N Engl J Med* 1985;313:1191-200.
11. Hwang SW, Lee SK, David CA. Intracranial occlusive disease. *Youmans Neurological Surgery*. 6th ed., Vol. 4, Ch. 355.

- Philadelphia, PA: Saunders, An Imprint of Elsevier Inc.; 2011.
12. Grubb RL Jr, Powers WJ, Clarke WR, Videen TO, Adams HP Jr, Derdeyn CP; Carotid Occlusion Surgery Study Investigators. Surgical results of the Carotid Occlusion Surgery Study. *J Neurosurg* 2013;118:25-33.
 13. Nussbaum ES, Mocco J. Cerebral Revascularization Microsurgical and Endovascular Techniques. Ch. 5. Thieme Medical Publishers, Inc. 2011.
 14. Nussbaum ES, Mocco J. Cerebral Revascularization Microsurgical and Endovascular Techniques. Ch. 6. Thieme Medical Publishers, Inc. 2011.
 15. Surdell DL, Hage ZA, Eddleman CS, Gupta DK, Bendok BR, Batjer HH. Revascularization for complex intracranial aneurysms. *Neurosurg Focus* 2008;24:E21.
 16. Kocaeli H, Andaluz N, Choutka O, Zuccarello M. Use of radial artery grafts in extracranial-intracranial revascularization procedures. *Neurosurg Focus* 2008;24:E5.
 17. Bisson EF, Visioni AJ, Tranmer B, Horgan MA. External carotid artery to middle cerebral artery bypass with the saphenous vein graft. *Neurosurgery* 2008;62 3 Suppl 1:134-8.
 18. Streefkerk HJ, Bremmer JP, Tulleken CA. The ELANA technique: High flow revascularization of the brain. *Acta Neurochir Suppl* 2005;94:143-8.
 19. Nussbaum ES, Mocco J. Cerebral Revascularization Microsurgical and Endovascular Techniques. Ch. 8. Thieme Medical Publishers, Inc. 2011.
 20. Khodadad G. Occipital artery-posterior inferior cerebellar artery anastomosis. *Surg Neurol* 1976;5:225-7.
 21. Hamada J, Todaka T, Yano S, Kai Y, Morioka M, Ushio Y. Vertebral artery-posterior inferior cerebellar artery bypass with a superficial temporal artery graft to treat aneurysms involving the posterior inferior cerebellar artery. *J Neurosurg* 2002;96:867-71.