

Complications and management in Descemet's stripping endothelial keratoplasty: Analysis of consecutive 430 cases

Samar K Basak, Soham Basak¹

Purpose: To analyze the complications and their managements in Descemet's stripping endothelial keratoplasty (DSEK) in consecutive 430 cases by single surgeon in a tertiary eye hospital. **Materials and Methods:** 430 eyes of 366 patients with endothelial dysfunctions scheduled for DSEK, were analyzed retrospectively. In all cases donor dissection was performed manually, and 'Taco' insertion and unfolding technique was used. Intra-operative and postoperative complications with their managements and outcomes were reviewed retrospectively. Periodic endothelial cell density was analyzed for each patient till the last visit. Follow-up period was between 3 to 60 months (mean 18.7 months). **Results:** 13 (3.0%) eyes had operative complications during donor dissection and 16 (3.7%) had during recipient procedure. In 7 (1.6%) eyes, donor lenticule was replaced with a new one during the surgery. In early postoperative period, 21 (4.9%) eyes had donor dislocation and 12 (2.8%) eyes had air-induced pupillary block; and they were managed immediately. 2 cases had primary graft failure and in 1 case had postoperative bacterial endophthalmitis requiring evisceration. In late postoperative period, 48 (11.3%) eyes had secondary glaucoma and 14 (3.3%) eyes had late secondary graft failure. Endothelial rejection occurred in 5 (1.2%) cases. Mean endothelial cell loss was 19.7% after 3 months and 54.2% after 5 years. Total graft failure in this series was 31 (7.2%) and in 17 cases re-DSEK was performed successfully. **Conclusions:** Both operative and postoperative complications do occur in DSEK. Most of these complications can be managed by medical or appropriate surgical means. Some of the complications can be avoided and reduced with experience.

Key words: Descemet's stripping endothelial keratoplasty, complications, donor dislocation, endothelial cell loss, graft failure, management

Descemet's stripping endothelial keratoplasty (DSEK) is now the choice of surgery in corneal endothelial dysfunctions as an alternative to penetrating keratoplasty (PKP). In DSEK, the diseased endothelium and Descemet's membrane (DM) are replaced with a donor posterior lamella, such as healthy endothelium, DM, and a thin portion of posterior corneal stroma.^[1] A comprehensive review on safety and outcomes of DSEK was published by American Academy of Ophthalmology in 2009. It states that DSEK appears similar to PKP in terms of graft clarity, visual acuity, surgical risks, complication rates, and endothelial cell loss (ECL). But, it seems to be superior to PK in terms of early visual recovery, refractive stability, postoperative astigmatism, wound and suture-related complications, and intraoperative and late suprachoroidal hemorrhage risk.^[2]

Some surgeons are using automated microkeratome for the preparation of the donor endothelial graft that is mounted on an artificial anterior chamber. This variant in procedure has been termed Descemet's stripping automated endothelial keratoplasty (DSAEK). At the same time, many surgeons are still using manual dissector for the preparation of the donor tissue mounted on an artificial anterior chamber because of the

cost issue in relation to microkeratome. Most of the surgeons use the term DSEK and DSAEK interchangeably.^[3]

As a relatively new procedure, the operative and postoperative complications associated with DSEK/DSAEK are now appearing in the peer-review journals. Some reported donor tissue complications have included inability to separate newly prepared donor tissue from the anterior portion, excessively thickened donor posterior lenticules, donor tissue perforation, and inadvertent flipping of the tissue inside the eye.^[2-4] Price and Price showed that the most frequent complication in early postoperative period encountered in DSEK is donor lenticular dislocation, which can be resolved with repositioning of the graft, termed 'repositioning', and injection of an air bubble, termed 're-bubbling'. The proposed causes of graft detachment include patient eye rubbing and poor donor tissue dissection technique.^[5] There are reports on air-induced pupillary block, primary graft failure (PGF), and interface infection in early postoperative period.^[6-9] In the late postoperative period, the most important reported complications were – secondary glaucoma and graft rejection by different authors.^[10-13] But most of the current studies in literature are in relation to DSAEK procedure, which is an automated dissection technique rather than manual dissection or DSEK procedure.

The purpose of the present study was to compile and analyze the overall intraoperative and postoperative complications in a large series of DSEK with their management, performed by single surgeon from a tertiary eye-care centre.

Materials and Methods

Surgical outcomes from 430 DSEK cases performed by a single

Access this article online

Website:

www.ijo.in

DOI:

10.4103/0301-4738.116484

Quick Response Code:



Cornea Department, Disha Eye Hospitals & Research Centre, Barrackpore, Kolkata, ¹Ophthalmology Department, Kasturba Medical College, Manipal, Udupi, Karnataka, India

Correspondence to: Dr. Samar K Basak, Disha Eye Hospitals and Research Centre, Barrackpore, North 24 Parganas, Kolkata - 700 120, India. E-mail: basak_sk@hotmail.com

Manuscript received: 28.01.12; **Revision accepted:** 09.09.12

surgeon in a tertiary eye hospital were compiled and analyzed retrospectively to assess the rate and types of complications with their management. DSEK began to be performed at this institution since July 2006. The chief author (Dr. SKB) had undertaken wet-lab and skill transfer courses from accomplished DSEK surgeons abroad before starting the procedure. The informed written consent was obtained from all patients after institutional review board approval and the study was in accordance with the declaration of Helsinki.

Four hundred and thirty eyes of 366 patients underwent DSEK from July 2006 through June 2011. The patients comprised 168 men and 198 women. The median age of these patients was 59.5 years (range: 4-92 years). Table 1 shows the preoperative diagnosis and crystalline lens status of the patients. Most eyes had pseudophakic corneal edema and/or bullous keratopathy (259 eyes) of which 225 (52.3%) eyes had posterior chamber intraocular lens (PCIOL) and 34 (7.9%) eyes had anterior chamber intraocular lens (ACIOL). Fuchs' dystrophy with different grades of cataract was present in 98 (22.8%) eyes and post-PKP failed graft in 32 (7.4%) eyes.

All the DSEK procedures were performed using the similar technique. The preoperative donor endothelial cell density (ECD) was ≥ 2200 cell/mm² (range 2214-3305 cell/mm²; median: 2441 cells/mm²). The donor dissection was performed manually after mounting the donor tissue on Barron's artificial anterior chamber (Katena, USA) and 60:40 'Taco' forceps technique was used for donor insertion. The unfolding of the donor tissue was performed by injection of balanced salt solution (BSS) and air from the sideports. In 98 cases, where the patients presented with moderate to severe Fuchs' dystrophy with some degree of cataract, the DSEK procedure was combined with phacoemulsification (PE) or manual small incision cataract surgery (MSICS) with PCIOL implantation. The detailed description of the surgical technique used by the author was published earlier.^[14] The intraocular lens (IOL) exchange and secondary PCIOL implantation were performed in seven eyes. Additional triamcinolone-assisted vitrectomy was performed in selected cases where it was indicated. Intraoperative complications were those that happened during the surgery in relation to DSEK procedure. Early postoperative complications were defined as those complications that happened within 2 months of surgery and late complications were those, which occurred after 2 months. The corneal graft that had not cleared even after 2 months of surgery was classified as PGF.^[2] The periodic ECD was analyzed postoperatively for each patient until the last follow-up visit. The follow-up period was between 3 and 60 months (mean 18.7 months).

Any complication either intraoperative or postoperative, which happened, was managed either medically, or by appropriate surgical means. These data were retrospectively reviewed from the case sheets. An Excel (Microsoft, Redmond, WA, USA) spreadsheet was used to compile the complications and calculate the results. A $P < 0.05$ is considered significant.

Results

Operative complications

Table 2 shows the operative complications in relation to the donor dissection. In three (0.7%) cases, the donor button was changed with a new one because of poor donor preparation. In 10 (2.3%) cases, additional donor tissue preparation

Table 1: Preoperative diagnosis (no. of eyes=430)

Indications	No. of cases	Percentage
Pseudophakic edema/PBK	259	60.2
PCIOL	225	52.3
ACIOL	34	7.9
Fuchs' dystrophy with different grades of cataract	98	22.8
Post-PKP-failed graft	32	7.4
ABK	15	3.5
CHED	4	1
ICE syndrome	4	1
PPMD	2	0.5
Repeat DSEK	16	3.7
Primary failure	2	0.5
Donor dislocation	4	1.0
Late donor failure	10	2.4
Total	430	100
Recipient's lens status		
Pseudophakic	309	65.2
Phakic	106	31.1
Aphakic	15	3.7

PCIOL: Posterior chamber intraocular lens, ACIOL: Anterior chamber intraocular lens, PBK: Pseudophakic bullous keratopathy, PKP: Penetrating keratoplasty, ABK: Aphakic bullous keratopathy, ICE: Iridocorneo-endothelial syndrome, CHED: Congenital hereditary endothelial dystrophy, PPMD: Posterior polymorphous dystrophy, DSEK: Descemet's stripping endothelial keratoplasty

Table 2: Intraoperative complications during donor dissection (n=13)

Complications	No.	Percentage
Descemet's perforation of the donor cornea*	1	0.2
Excessive thick donor preparation*	2	0.5
Button-holing of the donor cornea [#]	2	0.2
Too thin donor preparation [^]	8	1.9
Total	13	3.0

*Change with a new donor button in 3 cases (0.7%), [#]New area was selected and donor dissection completed, [^]Handled the lamellar tissue delicately and used

Table 3: Operative complications during recipient procedure (n=20)

Complications	No.	Percentage
Incomplete stripping of DM	7	1.6
Scoring and DM stripping not possible	4	0.9
Air bubble-related problem	6	1.3
Reverse unfolding of the donor*	2	0.5
Donor button came out of the anterior chamber*	1	0.2
Total	20	4.6

*Donor button was replaced with a new donor button, DM: Descemet's membrane

complications such as button-holes or thin donor posterior lenticule did not result in need to use additional donor tissue.

Table 3 shows operative complications during recipient procedure. In two (0.5%) cases, donor button was replaced with a new one because of reverse donor unfolding; and one donor button came out during forcible injection of air while giving air tamponed. So, during operation the overall donor button damage was in six (1.4%) cases, and in all cases the button was replaced with a new button immediately.

Early postoperative complications

Table 4 enumerates the important early postoperative complications. The two most common complications in early postoperative period were air-induced pupillary block glaucoma in 12 (2.8%) eyes [Fig. 1a and b] and donor dislocation in 21 (4.9%) cases. Two eyes had PGF [Fig. 2a and b], one case had interface fungal infection [Fig. 3a and b], and one case had postoperative bacterial endophthalmitis.

Air-induced pupillary block glaucoma cases were initially treated with intravenous injection of mannitol and pupillary dilatation. In eight (66.7%) eyes, pupil dilated and air bubble moved anteriorly with relief of pupillary block. But in four (33.3%) cases, under topical or peribulbar anesthesia, air bubble was brought anteriorly by tapping the iris with a Sinsky's hook from the sideports.

Donor dislocation is one of the most important complications of DSEK [Fig. 4a-c]. Table 5 shows the details of 21 donor dislocations in this series. It is more with aphakic bullous keratopathy cases, ACIOL cases, and post-PKP-failed graft cases. It is also interesting to note that the incidence is highest in the initial 100 cases and reduced with time. In 18 (85.7%) eyes, donor dislocation occurred within 24 h of surgery, but in three cases, it happened after 7 days after the first follow-up visit. Once the donor dislocation was detected, it was immediately treated by repositioning of the donor tissue and rebubbling. In all dislocation cases, 'repositioning and rebubbling' were tried and successful reattachment occurred in 16 cases [Fig. 4d], but it failed in five eyes. Table 6 shows the details of donor dislocation management, its success and failures, and repeat procedures. In three eyes, finally they were converted into PKP. In partial non-attachment cases, they were completely attached with time. In all three cases, the graft was attached in more than two-third area.

Excluding the pupillary block glaucoma, seven eyes had glaucoma in early postoperative period due to other factors such as previous toxic anterior segment syndrome (TASS) in three cases, past history of glaucoma surgery in three cases, and iridocorneal endothelial syndrome in one case. They were initially treated with oral and topical antiglaucoma medications, but ultimately, in two cases, trabeculectomy with mitomycin-C and in one eye cyclocryopexy was required. The TASS occurred in two eyes where DSEK was combined with PE and foldable hydrophobic acrylic IOL implantation [Fig. 5a and b]. In both the cases, they were treated with systemic and frequent topical steroids, cycloplegic, and intraocular pressure-lowering agents. Both of them responded well with medical therapy within 3 months.

In PGF cases, Re-DSEK was performed with a fresh healthy donor tissue as early as possible. In case of interface infection, a therapeutic PKP with very good optical quality tissue was immediately performed. The culture report was *Fusarium* spp. and the patient was further treated with antifungal agents. Finally, this patient recovered with clear graft and good visual

outcome. The fulminant bacterial endophthalmitis happened in a case of DSEK with PE and PCIOL. The bacterial culture was positive for *Bacillus cereus*. In spite of urgent therapeutic PKP and vitrectomy, the eye could not be saved and eventually it was eviscerated on the 5th day.^[15] Table 7 shows the overall causes of graft failure in 11 cases in early postoperative period, that is, within first 2 months after the surgery.

Late postoperative complications

Table 8 shows the details of overall complications in the late postoperative period. In this period, the most common complication was secondary glaucoma in 41 (9.6%) eyes. The other important complications were late interface opacification in 13 (3.1%) eyes, endothelial graft rejection occurred in five (1.2%) eyes, epithelial ingrowth in two eyes, and late infectious keratitis in two eyes. There were also some uncommon complications. Fourteen (3.3%) patients had late secondary graft failure between 6 and 54 months.

Secondary glaucoma

The most common cause of secondary glaucoma in late postoperative period was steroid-induced glaucoma in 35 (8.3%) eyes. The other causes are enumerated in Table 9. Initially, all the secondary glaucoma cases were treated

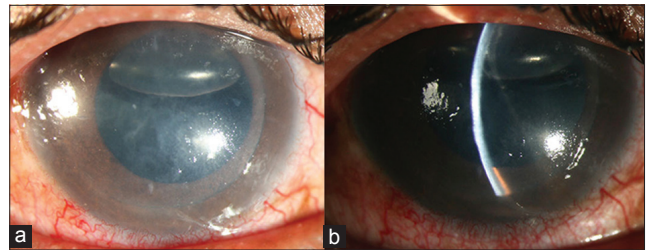


Figure 1: (a) Air-induced pupillary block; (b) air-induced pupillary block in slit section

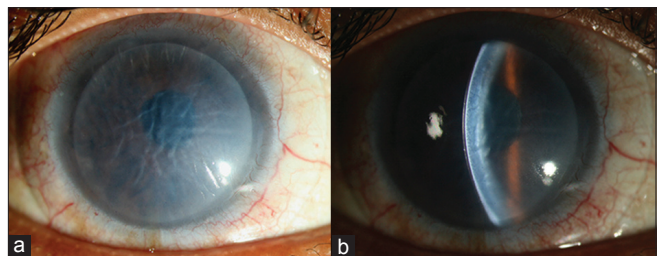


Figure 2: (a) Primary graft failure; (b) primary graft failure in slit section

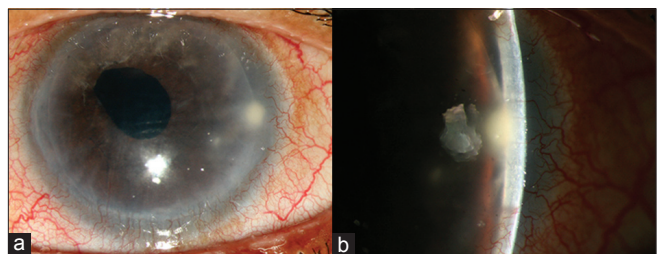


Figure 3: (a) Interface infection – 7th day postoperative; (b) interface infection – in slit section

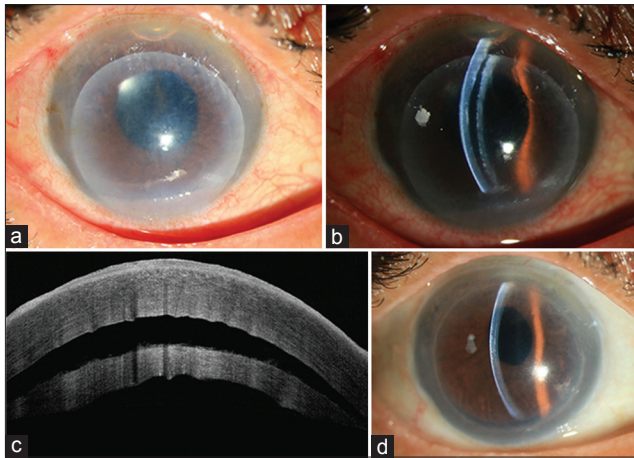


Figure 4: (a) Donor dislocation on 2nd day; (b) donor dislocation on 2nd day in slit section; (c) donor dislocation on 2nd day – anterior segment OCT picture; (d) donor reattachment after repositioning and rebubbling

Table 4: Early postoperative complications (n=50)

Complications	No.	Percentage	P value
Donor dislocation	21	4.9	<0.001
Air-induced pupillary block glaucoma	12	2.8	0.024
Secondary glaucoma (other causes)	7	1.6	0.095
Partial donor non-attachment	3	0.7	NS
Primary graft failure	2	0.5	NS
Toxic anterior segment syndrome	2	0.5	NS
Blood in interface	2	0.5	NS
Interface infection	1	0.2	NS
Bacterial endophthalmitis	1	0.2	NS
Total	50	11.6	

NS: Not significant

Table 6: Donor dislocation management: Success and failures and repeat procedures (n=21)

	No.	Percentage
Total dislocation	21	100
Donor repositioning and rebubbed	21	100
Reattachments after rebubbling	16	76.2
Cornea cleared after reattachment	15	71.4
Edema persisted after reattachment	1	4.8
Detachment after rebubbling	5	23.8
ABK cases*	3	14.3
ACIOL cases	1	4.8
Failed post-PK cases	1	4.8
Repeat DSEK		
Attempted	4	19.0
Successful repeat DSEK	3	14.3
PKP after DSEK	3	14.3

*In 2 ABK cases, repeat DSEK was not attempted, DSEK: Descemet's stripping endothelial keratoplasty, PKP: Penetrating keratoplasty, ABK: Aphakic bullous keratopathy, ACIOL: Anterior chamber intraocular lens

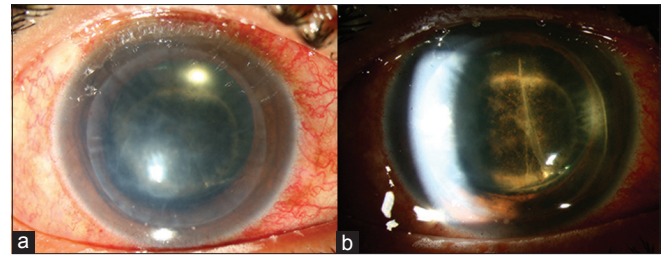


Figure 5: (a) Toxic anterior segment syndrome at 7th day; (b) toxic anterior segment syndrome – note the anterior uveitis

Table 5: Donor dislocation: Overview (n=21)

Incidence	No.	Percentage	P value
Number of surgery wise			
First 100 cases	9	9.0	
Second 100 cases	6	6.0	NS
Third 100 cases	4	4.0	0.07
Next 130 cases	2	1.5	0.0205
Total	21	4.9	
Indication wise			
ABK cases	7	46.7	<0.001
ACIOL cases	5	14.7	0.048
Failed post-PKP cases	4	12.5	0.041
Other cases	5	1.4	NS
Postoperative day wise			
Within 24 h	18	85.7	<0.001
After 7 days	3	14.3	0.1687

ABK: Aphakic bullous keratopathy, ACIOL: Anterior chamber intraocular lens, PKP: Penetrating keratoplasty, NS: Not significant

Table 7: Early graft failure (within first 2 months) and final management (n=11)

Causes	No.	Percentage	Management	No.
Edema and non-attachment after rebubbling in donor dislocation	6	1.4	Re-DSEK	3
			PKP	3
Primary graft failure	2	0.5	Re-DSEK	2
Graft interface infection	1	0.2	Th-PKP	1
Bacterial endophthalmitis	1	0.2	Evisceration	1
Absolute glaucoma	1	0.2	Cyclocryopexy	1
Total	11	2.6		11

DSEK: Descemet's stripping endothelial keratoplasty, PKP: Penetrating keratoplasty, Th-PKP: Therapeutic penetrating keratoplasty

with antiglaucoma medications, and topical steroids were reduced, changed, or withdrawn in selected cases. In one eye, developed total glaucomatous optic atrophy inspite of crystal clear graft [Fig. 6a-c]. The intervened surgical methods were trabeculectomy with mitomycin-C in five cases and Ahmed glaucoma valve (AGV) in two cases. Eventually, cyclocryopexy was required in two cases for absolute glaucoma – one was with iridocorneo endothelial (ICE) syndrome and the other case was with congenital hereditary endothelial dystrophy (CHED). Among the five cases of late secondary angle closure

glaucoma (ACG), 360° adhesion was noticed between the iris and the donor lenticular edge [Fig. 7a and b]. In three of these eyes, simple breaking of adhesion cured the secondary glaucoma; but in two eyes, as the graft health was not good, repeat DSEK procedure was performed after breaking the adhesion. All of these cases are doing fine with clear graft until their last follow-up.

Graft rejection

Five (1.2%) eyes had endothelial graft rejection that occurred between 11 and 36 months after the DSEK procedure [Fig. 8a and b]. Three patients with graft rejection presented with sudden dimness of vision and photophobia; but in two cases, the rejection episodes were diagnosed during routine examination. All eyes had keratic precipitates and anterior chamber cells, with diffuse corneal edema in three cases. But none of the eyes developed endothelial rejection line. Graft rejection cases were treated immediately by intravenous methyl prednisolone injection and frequent topical prednisolone acetate eye drop. In three cases, the rejection episode was reversed with medication and the grafts were cleared [Fig. 8c]. But, in two eyes graft edema persisted even after maximum medication and re-DSEK was eventually required.

Interface opacification was another complication noticed in 13 eyes (3.1%), and in all cases, it occurred 6 months after the surgery [Fig. 9a and b]. This was mostly [10 eyes (2.4%)] with the TASS-related PBK cases. These patients are still maintaining reasonable amount of vision.

Table 8: Late postoperative complications (of 424 patients)

Complications	No.	Percentage	P value
Late secondary glaucoma	48	11.3	<0.05
Interface opacification	13	3.1	0.181
Endothelial graft rejection	6	1.4	0.368
Epithelial ingrowth	2	0.5	NS
Late infectious keratitis	2	0.5	NS
Late graft failure	14	3.3	0.13
Other complications			NS
Cystoid macular edema	7	1.7	
Retinal detachment	2	0.5	
Cataract*	1	0.2	
Total	95	22.4	<0.01

NS: Not significant, *DSEK performed alone in 5 phakic eyes

Secondary graft failure occurred in 14 (3.3%) cases between 6 and 54 months after the DSEK procedure [Fig. 10a-c]. Of these, eight (2.4%) eyes were with PCIOL, four (11.7%) eyes had previous ACIOL, and two (13.3%) eyes were aphakic. In nine eyes, the DSEK graft failed 3 years after the surgery. Among 14 cases, 10 eyes were treated with repeat DSEK procedure [Fig. 10d]. Three cases (two with aphakia and one eye with ACIOL) were treated with PKP and one case was lost to follow-up.

Epithelial ingrowth was seen in two cases, and in both cases, venting incisions were given during surgery. Late infectious keratitis occurred in two cases – one after 8 months and the other after 18 months of the surgery [Figs. 11 and 12]. In both the cases, there was history of foreign body entry in the eye – one was aspergillus keratitis and the other one was streptococcal keratitis. Both cases responded well with appropriate antimicrobial therapy. One case developed cataract (of 5 phakic cases where DSEK was performed alone without lens extraction) after 18 months of surgery and treated with PE with PC IOL implantation. There was no further problem with donor tissue after the cataract surgery.

Endothelial cell loss

The overall median ECL after 3 months was 19.7%. It was 32.5%, 38.9%, 42.2%, 47.1%, and 54.2% after 1 year, 2 years, 3 years,

Table 9: Causes and number of patients developed late secondary glaucoma (n=48)

Causes*	No. of eyes	Percentage	P value
Steroid-induced glaucoma	35	8.3	<0.01
Known POAG patient using medication	6	1.4	NS
Late secondary angle closure glaucoma	5	1.2	NS
Operated glaucoma patients	4	1.2	NS
Known PACG with YAG PI done	4	0.9	NS
Vitreous disturbances (ACIOL/ABK/IOL exchange)	4	0.9	NS
Known iridocorneo endothelial (ICE) syndrome	2	0.5	NS

*The causes may be multiple in many cases, NS: Not significant, ACIOL: Anterior chamber intraocular lens, ABK: Aphakic bullous keratopathy, IOL: Intraocular lens

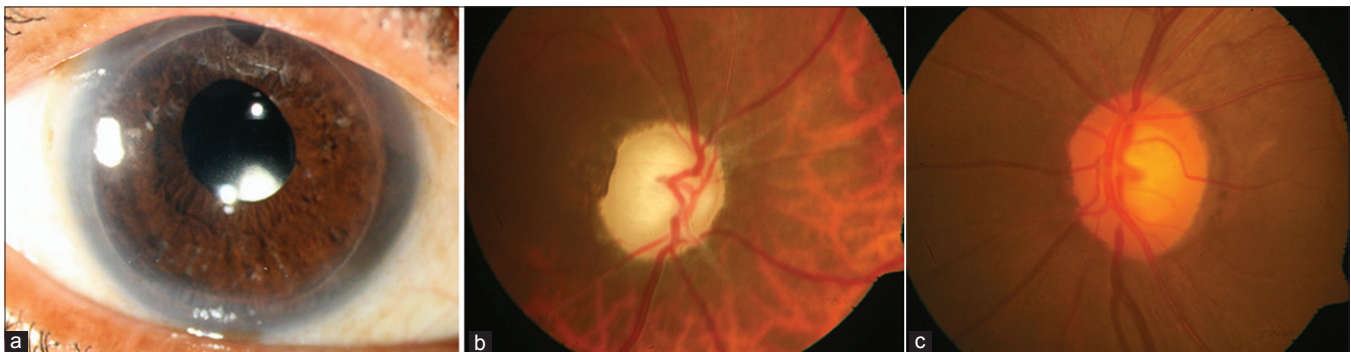


Figure 6: (a) Clear graft in DSEK after 3 years – secondary glaucoma; (b) glaucomatous optic atrophy – total cupping; (c) normal optic nerve of the other eye

4 years, and 5 years, respectively [Table 10]. However, the ECL had not been analyzed independently with different group of patients and with or without complications, such as donor dislocation and rebubbling, secondary glaucoma, rejection episode, etc.

Seven (1.6%) eyes developed cystoid macular edema, between 4 and 11 months after surgery and they were treated with sub-Tenon's injection of triamcinolone acetonide, and nepafenac eye drop-q.i.d. for 3 months. In all cases, macular edema resolved with improvement of vision. Two cases of retinal detachment were managed surgically by the vitreoretinal surgeon.

The total number of graft failure in this series was 31 (7.2%) cases that occurred between day 1 and 5 years after the surgery [Table 11]. Eleven (2.6%) of them happened within 2 months of DSEK procedures and in 20 eyes graft failed (4.7%) after that. Table 12 shows the overall surgical management of these failed grafts.

Discussion

The DSEK offers an effective and efficient alternative to traditional PKP for the treatment of corneal endothelial

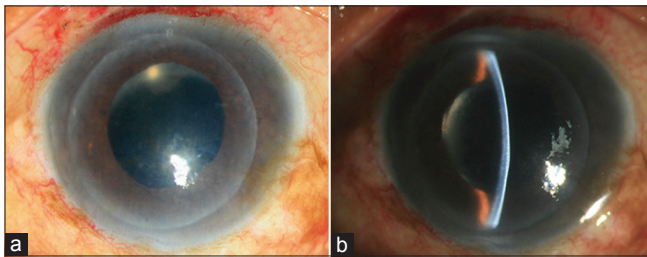


Figure 7: (a) 360° peripheral anterior synechia; (b) 360° peripheral anterior synechia – iris bombe

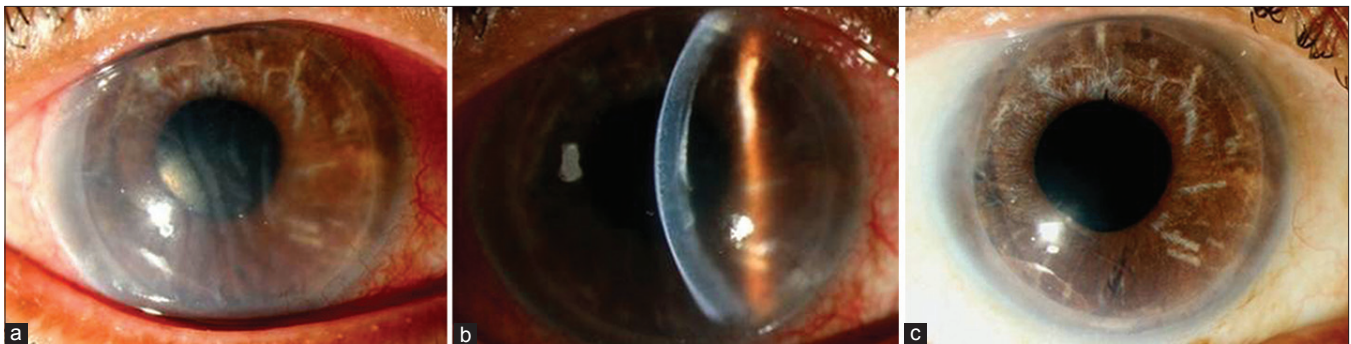


Figure 8: (a) Endothelial graft rejection in DSEK; (b) endothelial graft rejection in DSEK – note corneal edema with Descemet's folds; (c) same eye after two doses of intravenous methyl prednisolone

dysfunctions. As a relatively new procedure, the different complications of DSEK are now being described in the literature. As previously reported, such complications include pupillary block by air, donor dislocation, graft failure secondary glaucoma, and graft rejection. The potential causes of donor dislocation include the presence of interface viscous fluid or air, patient squeezing, and eye rubbing.^[2-13] There are complications with the preparation, handling, and insertion of donor lamellar tissue into the anterior chamber of the recipient.^[2,3] But most of the reported complications are with automated dissection of the donor tissue, that is, with DSAEK and most of the reports did not cover the management of each complication.

There are only few reports on intraoperative donor complications. One with microkeratome-related dissection where four tissues were discarded because of imperfect cut and one with manual dissection where the incidence of donor Descemet's perforation was 4.4%.^[4,15] In this series, the donor Descemet's perforation was only 0.2%. There were other problems that have not been reported earlier, such as excessive donor thickness for which the donor tissue was discarded. Two other important intraoperative complications happened where the donor tissue were discarded and replaced with a new one. One was reverse unfolding in two eyes during injecting air from the side port, and in another case, the donor tissue came out of the A/C during unfolding.

As previously described, pupillary block by air is an important complication of DSEK procedure. In fact, the reported incidence of pupillary block varies between 0.5% and 13% in different series.^[5,16-19] This is due to the displacement of an excessively large air bubble. In this series, the overall incidence is 2.8%. But in last 130 cases, it happened only in one (0.8%) eye. The incidence could be prevented drastically by placing a freely mobile air bubble and put a drop of cycloplegic at the end of the surgery as recommended by Terry *et al.*^[13]

Table 10: Periodic endothelial cell loss following manual DSEK

	Preoperative donor ECD	Postoperative					
		3 months	1 year	2 years	3 years	4 years	5 years
ECD cells/mm ²	2214-3305	987-2810	614-2432	686-2176	540-1720	468-1746	411-1702
Median ECD	2441	1959	1603	1491	1411	1291	1118
% of ECL		19.7	34.3	38.9	42.2	47.1	54.2
Patient (n)	430	424	298	203	134	57	27

ECD: Endothelial cell density, ECL: Endothelial cell loss, DSEK: Descemet's stripping endothelial keratoplasty

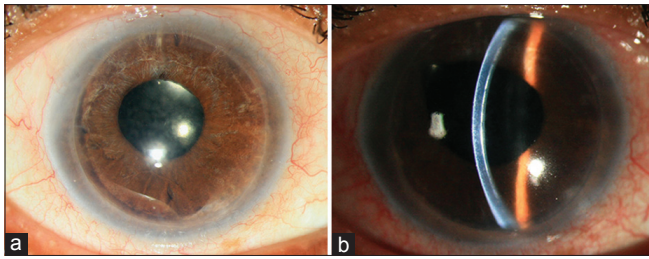


Figure 9: (a) Late interface opacification in the pupillary area; (b) late interface opacification in slit section

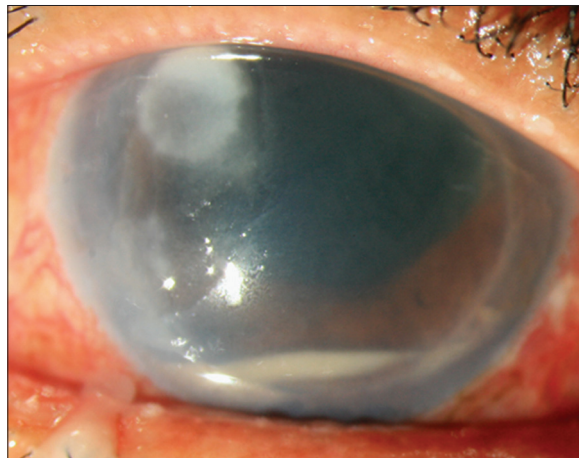


Figure 11: Late infective keratitis with interface hypopyon

Table 11: Total graft failure following manual DSEK procedure (n=31)

Causes	No.	Percentage
Early graft failure	11	2.5
Due to nonattachment and edema	6	
Primary graft failure	2	
Interface infection	1	
Endophthalmitis	1	
Absolute glaucoma	1	
Late graft failure	20	4.7
Late graft failure	14	
Secondary ACG	2	
Absolute glaucoma	2	
Graft rejection	2	
Total	31	7.2

ACG: Angle closure glaucoma, DSEK: Descemet's stripping endothelial keratoplasty

Donor dislocation is one of the most important complication and the rates varied from 0% to 82%, with an average dislocation rate of 14.5%.^[2] The graft dislocation may represent either fluid in the interface of an otherwise well-positioned graft or complete dislocation into the anterior chamber. In this series, the overall donor dislocation rate was 4.8%. It is interesting to note that the incidence of this unique complication is reduced with experience, and the same author had reported 8% dislocation rate in 2008.^[14] Price and Price reported a dislocation

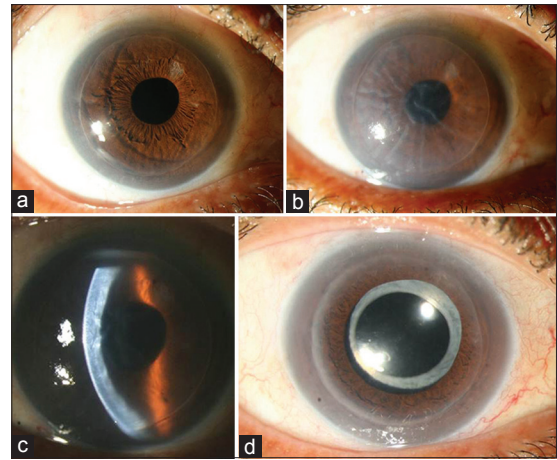


Figure 10: (a) Clear graft 2.5 years after DSEK; (b) late graft failure – same eye after 3.5 years; (c) Late graft failure in slit section – same eye after 3.5 years; (d) re-DSEK-same eye – postoperative 3 months

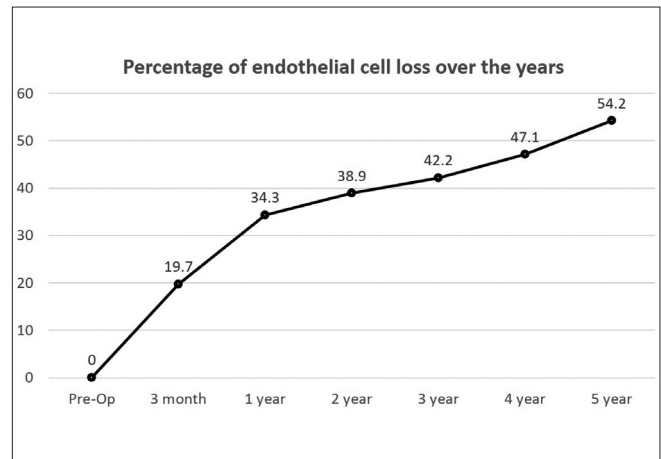


Figure 12: Percentage of periodic endothelial cell loss over last 5 years

Table 12: Summary of repeat surgery in failed-DSEK cases (n=31)

Procedures	No. of cases	Percentage
Successful repeat DSEK	16	51.6
PKP after DSEK	8	25.8
Cyclocryopexy	3	9.6
Therapeutic PKP	1	3.2
Evisceration	1	3.2
Lost to follow-up	2	6.4
Total	31	100

PKP: Penetrating keratoplasty, DSEK: Descemet's stripping endothelial keratoplasty

rate of 50% in the first 10 eyes undergoing DSAEK, which was reduced to 13% in the next 126 cases after changing the procedure to include face-up positioning after surgery and smoothing of the corneal surface.^[5] Several other authors have shown the similar results that, with experience and time, the dislocation rate is reduced.^[10,12,13] The results of dislocation management are also satisfactory with a success rate of 72.3%

that is comparable with other published series.^[20] In this study, the donor dislocation was highest in aphakic, ACIOL, and post-PKP cases compared with uncomplicated PBK and Fuchs' dystrophy cases. So case selection is an important criteria and special precautions are to be taken in this kind of complicated cases. Re-dislocation of donor lenticule, even after rebubbling, is also higher in these cases.

The published studies showed rates of PGF from 0% to 29%, with an average PGF rate of 5%.^[2,19,21-23] Poor surgical technique has been linked to PGF in DSEK, with surgeon inexperience and related excessive of iatrogenic intraoperative manipulation donor endothelial as the main factor. In fact, some studies refer to this entity as iatrogenic PGF.^[10,13] In this series, the PGF happened in only three (0.7%) eyes and one of them after donor dislocation and subsequent rebubbling.

Published reports on secondary glaucoma after DSEK was between 0% and 15%, with an average of 3%.^[2] In this series, the incidence of secondary glaucoma was 11.8% and the commonest cause of this late secondary glaucoma was topical corticosteroids-induced (8.3%). Most of the patients showed rise in IOP after 3 months of surgery. Some of the patients had previous history of open-angle glaucoma and also it was more with ABK and post-PKP-failed graft cases. As previously reported, patients with a preoperative diagnosis of Fuchs' endothelial dystrophy did not show a statistically significant increase in IOP compared with other group.^[24] In this study, two the four eyes with ICE syndrome initially remained good, but later failed due to progressive peripheral anterior synechia formation. So, ICE syndrome may not be a good indication of DSEK, because of continuous nature of the disease.

The DSEK in CHED is often difficult and corneal edema takes long time to clear. In some cases, it is not possible to score and strip the DM, and to work under shallow AC and poor visualization due to thickened edematous cornea.^[25,26] There is also a case report on abandoning the procedure and converting to a PK on operation table due to these technical difficulties.^[27] Of the four eyes in this series, DM stripping was not possible in two eyes, in one eye it was partial, and only in one eye it was easy. In two eyes, corneal edema cleared after 6 months, and in one eye, there was residual diffuse stromal opacity. One eye developed secondary glaucoma and ultimately the graft failed.

Among reviewed studies, the endothelial rejection rates varied from 0% to 45.5%, with an average rejection rate of 10% with the follow-up ranging from 3 to 24 months.^[12,28-30] In this series, the rejection happened with five (1.2%) cases that is low compared with most of the study, although some studies reported the incidence as 0%. Allan *et al.* reported that 15 (7.5%) of 199 eyes had a graft rejection episode within the first 2 years after DSEK or deep lamellar endothelial keratoplasty, a rate less frequent than in their series of patients who underwent PKP.^[31,32] In this series, the clinical presentations of endothelial rejection were similar with previous study; however, no rejection line was noticed in any of the five cases.^[33,34] Three cases were reversed with intravenous injection of methyl prednisolone and topical steroids, with two cases progressing to graft failure requiring redo procedure.

Epithelial ingrowth, interface opacification, and interface hemorrhages are less common complications in this series

and these are comparable with reported studies.^[3,35,36] Among these, interface opacity is one of the important reasons for repeat endothelial keratoplasty (REK) as reported by Letko *et al.* following 1050 consecutive DSAEK cases in 5 years.^[37] Interface fibrosis was also described histo-pathologically in failed DSAEK cases where PKP procedure was performed later on.^[38]

The incomplete removal of DM as a cause of partial graft detachment in DSAEK has been reported.^[39] In this series, partial donor detachment happened in three cases and with time they attached completely. In all three cases, the graft was initially attached in more than two-third area.

Postoperative cystoid macular edema developed in seven (1.7%) eyes, which resolved with topical nonsteroidal anti-inflammatory agent and sub-Tenon triamcinolone acetamide injections. This is again comparable with the previous reports.^[3] Two cases of retinal detachment may not be directly related to the DSEK procedure: In one case, it was ACIOL-related PBK, and in the other case, the patient was highly myopic. The corneal surgeon should consult a retinal specialist whenever the patient complains of suboptimal or sudden drop of vision in spite of a clear graft.

In this series, the median ECL in manual DSEK in different postoperative periods is almost similar to the automated procedure or DSAEK of other series using similar donor insertion technique.^[40] The DSEK grafts experienced more initial cell loss until 1 year, and then a slow and steady cell loss over next 4 years. This is consistent with an earlier finding that cell loss in DSEK patients plateaus more quickly.^[41] Furthermore, the 5-year ECL after manual DSEK compared favorably with that measured after PKP in the Cornea Donor Study (54.7% versus 70%).^[42]

Late secondary donor failure due to chronic ECL is a question in DSEK procedure. The reported late graft failure varies between 0 and 45% after 1 year with an average of 6% in the 1st year.^[2] In this series, late secondary donor failure occurred in 14 (3.3%) eyes, which is comparable with other series and it happened between 10 months and 5 years. Late graft failure was more in DSEK in pseudophakic eyes with ACIOLs than with PCIOLs (11.7% versus 2.4%). Previous studies have also showed that ECL in DSAEK in pseudophakic eyes with ACIOLs is higher and the graft failure was 16% up to 30 months follow-up.^[43] Although DSEK surgery in patients with an ACIOL remains controversial, considering the outcomes from different studies, this is a good surgical option in selected cases.^[44]

As the published report of DSEK beyond 5 years are few in number, so long-term graft clarity with DSEK is yet to be determined.^[36,39,40] Ratanasit *et al.* showed that only four (7.8%) eyes had late donor failure among 51 cases in their longest follow-up of more than 5 years.^[45] The author stated that long-term results of DSAEK were excellent. The grafts were clear despite lower than normal endothelial cell counts. The total graft failure in this large series was 31 (7.2%) eyes. The failed DSEK cases, early or late can be managed by redo procedure in majority (54.8%) of the cases.

The infection following DSEK procedure, either in the form of interface keratitis and endophthalmitis in early postoperative period, or delayed keratitis after 3 months is always serious and has already been reported in literature.^[22,46-51] They were managed either medically or by PKP. In this series, in early

period, one interface fungal keratitis with *Candida*, and one fulminant endophthalmitis occurred with *B. cereus* for which evisceration was required on the 5th day. This is probably the first reported endophthalmitis with *B. cereus* infection.^[52] The two cases with delayed keratitis had positive cultures for *Candida*. Of these cases, one responded to medical treatment with resolution of the infection and the second case required a therapeutic PKP.

As a fairly new procedure, the relative inexperience of surgeons in earlier cases may account for more graft manipulation and ECL during surgery.^[7] In addition, the DSEK in certain indications have more complications than clean case of PCIOL-related PBK or Fuchs' endothelial dystrophy. These eyes are aphakic eyes, ACIOL-related PBK, post-PKP-failed graft, CHED, and ICE syndrome. In aphakic cases, there are reports of posterior dislocation of the donor disc into the vitreous cavity with or without retinal detachment.^[53,54] Other difficult cases are – vitreous in the anterior chamber, previous large peripheral iridectomy, large YAG capsulotomy even in presence of PCIOL, and a large filtration bleb.^[55] An experienced surgeon can perform these difficult cases, but with extra precautions and care, and these cases may require additional procedures.

There are inherent limitations of this kind of retrospective study. All the surgeries were performed by single surgeon with a maximum follow-up period of 5 years. For late complications, the author considered follow-up of 2 months or more. So the long-term delayed complications may not be reflected properly in this series. However, to the best of my knowledge after Medline search, this is a compilation of complications of the largest series of manual dissection of DSEK performed by single surgeon with the same technique for a period of more than 5 years.

In conclusion, the DSEK/DSAEK is an exciting and promising alternative procedure to the traditional PKP. Like other corneal transplantation surgeries, the learning curve is steep and the potential for complications is significant during first few cases. Both operative and postoperative complications do occur in DSEK and increases with the longer postoperative follow-up, but all very much within acceptable limit. The Re-DSEK procedure can be easily performed in most of the failed cases with satisfactory results.

References

- Patel SV. Keratoplasty for endothelial dysfunction. *Ophthalmology* 2007;114:627-8.
- Lee WB, Jacobs DS, Musch DC, Kaufman SC, Reinhart WJ, Shtein RM. Descemet's stripping endothelial keratoplasty: Safety and outcomes: A report by the American Academy of Ophthalmology. *Ophthalmology* 2009;116:1818-30.
- Suh LH, Yoo SH, Deobhakta A, Donaldson KE, Alfonso EC, Culbertson WW, *et al.* Complications of Descemet's stripping with automated endothelial keratoplasty: Survey of 118 eyes at one institute. *Ophthalmology* 2008;115:1517-24.
- Glasser DB. Tissue complications during endothelial keratoplasty. *Cornea* 2010;29:1428-9.
- Price FW Jr, Price MO. Descemet's stripping with endothelial keratoplasty in 200 eyes: Early challenges and techniques to enhance donor adherence. *J Cataract Refract Surg* 2006;32:411-8.
- Terry MA, Shamie N, Chen ES, Phillips PM, Shah AK, Hoar KL, *et al.* Endothelial keratoplasty for Fuchs' dystrophy with cataract: Complications and clinical results with the new triple procedure. *Ophthalmology* 2009;116:631-9.
- Gorovoy MS. Descemet-stripping automated endothelial keratoplasty. *Cornea* 2006;25:886-9.
- Price MO, Price FW Jr. Descemet's stripping with endothelial keratoplasty: Comparative outcomes with microkeratome-dissected and manually dissected donor tissue. *Ophthalmology* 2006;113:1936-42.
- Chen ES, Terry MA, Shamie N, Hoar KL, Phillips PM, Friend DJ. Endothelial keratoplasty: Vision, endothelial survival, and complications in a comparative case series of fellows vs attending surgeons. *Am J Ophthalmol* 2009;148:26-31.
- Terry MA, Hoar KL, Wall J, Ousley P. Histology of dislocations in endothelial keratoplasty (DSEK and DLEK): A laboratory-based, surgical solution to dislocation in 100 consecutive DSEK cases. *Cornea* 2006;25:926-32.
- O'Brien PD, Lake DB, Saw VP, Rostron CK, Dart JK, Allan BD. Endothelial keratoplasty: Case selection in the learning curve. *Cornea* 2008;27:1114-8.
- Mearza AA, Qureshi MA, Rostron CK. Experience and 12-month results of Descemet-stripping endothelial keratoplasty (DSEK) with a small-incision technique. *Cornea* 2007;26:279-83.
- Terry MA, Shamie N, Chen ES, Hoar KL, Friend DJ. Endothelial keratoplasty a simplified technique to minimize graft dislocation, iatrogenic graft failure, and pupillary block. *Ophthalmology* 2008;115:1179-86.
- Basak SK. Descemet stripping and endothelial keratoplasty in endothelial dysfunctions: Three-month results in 75 eyes. *Indian J Ophthalmol* 2008;56:291-6.
- Price MO, Price FW Jr. Descemet's stripping with endothelial keratoplasty: Comparative outcomes with microkeratome-dissected and manually dissected donor tissue. *Ophthalmology* 2006;113:1936-42.
- Koenig SB, Covert DJ. Early results of small-incision Descemet's stripping and automated endothelial keratoplasty. *Ophthalmology* 2007;114:221-6.
- Covert DJ, Koenig SB. New triple procedure: Descemet's stripping and automated endothelial keratoplasty combined with phacoemulsification and intraocular lens implantation. *Ophthalmology* 2007;114:1272-7.
- Cheng YY, Hendrikse F, Pels E, Wijdh RJ, van Cleynenbreugel H, Eggink CA, *et al.* Preliminary results of femtosecond laser-assisted Descemet stripping endothelial keratoplasty. *Arch Ophthalmol* 2008;126:1351-6.
- Lee JS, Desai NR, Schmidt GW, Jun AS, Schein OD, Stark WJ, *et al.* Secondary angle closure caused by air migrating behind the pupil in Descemet stripping endothelial keratoplasty. *Cornea* 2009;28:652-6.
- Chaurasia S, Vaddavalli PK, Ramappa M, Garg P, Sangwan VS. Clinical profile of graft detachment and outcomes of rebubbling after Descemet stripping endothelial keratoplasty. *Br J Ophthalmol* 2011;95:1509-12.
- O'Brien PD, Lake DB, Saw VP, Rostron CK, Dart JK, Allan BD. Endothelial keratoplasty: Case selection in the learning curve. *Cornea* 2008;27:1114-8.
- Oster SF, Ebrahimi KB, Eberhart CG, Schein OD, Stark WJ, Jun AS. A clinicopathologic series of primary graft failure after Descemet's stripping and automated endothelial keratoplasty. *Ophthalmology* 2009;116:609-14.
- Shih CY, Ritterband DC, Rubino S, Palmiero PM, Jangi A, Liebmann J, *et al.* Visually significant and nonsignificant complications arising from Descemet stripping automated endothelial keratoplasty. *Am J Ophthalmol* 2009;148:837-43.
- Espana EM, Robertson ZM, Huang B. Intraocular pressure changes following Descemet's stripping with endothelial keratoplasty. *Graefes Arch Clin Exp Ophthalmol* 2010;248:237-42.
- Ashar JN, Madhavi Latha K, Vaddavalli PK. Descemet's stripping

- endothelial keratoplasty (DSEK) for children with congenital hereditary endothelial dystrophy: Surgical challenges and 1-year outcomes. *Graefes Arch Clin Exp Ophthalmol* 2012;250:1341-5.
26. Busin M, Beltz J, Scorcia V. Descemet-stripping automated endothelial keratoplasty for congenital hereditary endothelial dystrophy. *Arch Ophthalmol* 2011;129:1140-6.
 27. Pineda R 2nd, Jain V, Shome D, Hunter DC, Natarajan S. Descemet's stripping endothelial keratoplasty: Is it an option for congenital hereditary endothelial dystrophy? *Int Ophthalmol* 2010;30:307-10.
 28. Bahar I, Kaiserman I, McAllum P, Slomovic A, Rootman D. Comparison of posterior lamellar keratoplasty techniques to penetrating keratoplasty. *Ophthalmology* 2008;115:1525-33.
 29. Price MO, Price FW Jr. Endothelial cell loss after Descemet stripping with endothelial keratoplasty influencing factors and 2-year trend. *Ophthalmology* 2008;115:857-65.
 30. Terry MA, Chen ES, Shamie N, Hoar KL, Friend DJ. Endothelial cell loss after Descemet's stripping endothelial keratoplasty in a large prospective series. *Ophthalmology* 2008;115:488-96.
 31. Allan BD, Terry MA, Price FW Jr, Price MO, Griffin NB, Claesson M. Corneal transplant rejection rate and severity after endothelial keratoplasty. *Cornea* 2007;26:1039-42.
 32. Li JY, Terry MA, Goshe J, Shamie N, Davis-Boozer D. Graft rejection after Descemet's stripping automated endothelial keratoplasty: Graft survival and endothelial cell loss. *Ophthalmology* 2012;119:90-4.
 33. Jordan CS, Price MO, Trespalacios R, Price FW Jr. Graft rejection episodes after Descemet stripping with endothelial keratoplasty: Part one: Clinical signs and symptoms. *Br J Ophthalmol* 2009;93:387-90.
 34. Wu EI, Ritterband DC, Yu G, Shields RA, Seedor JA. Graft rejection following Descemet stripping automated endothelial keratoplasty: Features, risk factors, and outcomes. *Am J Ophthalmol* 2012;153:949-57.
 35. Ebrahimi KB, Oster SF, Green WR, Grebe R, Schein OD, Jun AS. Calcareous degeneration of host-donor interface after Descemet membrane stripping with automated endothelial keratoplasty. *Cornea* 2009;28:342-4.
 36. Schmitt AJ, Feilmeier MR, Piccoli FV, Ide T, Yoo SH. Interface blood after Descemet stripping automated endothelial keratoplasty. *Cornea* 2011;30:815-7.
 37. Letko E, Price DA, Lindoso EM, Price MO, Price FW Jr. Secondary graft failure and repeat endothelial keratoplasty after Descemet's stripping automated endothelial keratoplasty. *Ophthalmology* 2011;118:310-4.
 38. Shulman J, Kropinak M, Ritterband DC, Perry HD, Seedor JA, McCormick SA, *et al.* Failed Descemet-stripping automated endothelial keratoplasty grafts: A clinicopathologic analysis. *Am J Ophthalmol* 2009;148:752-9.
 39. Kymionis GD, Suh LH, Dubovy SR, Yoo SH. Diagnosis of residual Descemet's membrane after Descemet's stripping endothelial keratoplasty with anterior segment optical coherence tomography. *J Cataract Refract Surg* 2007;33:1322-4.
 40. Price MO, Fairchild KM, Price DA, Price FW Jr. Descemet's stripping endothelial keratoplasty five-year graft survival and endothelial cell loss. *Ophthalmology* 2011;118:725-9.
 41. Price MO, Gorovoy M, Benetz BA, Price FW Jr, Menegay HJ, Debanne SM, *et al.* Descemet's stripping automated endothelial keratoplasty outcomes compared with penetrating keratoplasty from the Cornea Donor Study. *Ophthalmology* 2010;117:438-44.
 42. Cornea Donor Study Investigator Group, Lass JH, Gal RL, Dontchev M, Beck RW, Kollman C, Dunn SP *et al.* Donor age and corneal endothelial cell loss 5 years after successful corneal transplantation. Specular microscopy ancillary study results. *Ophthalmology* 2008;115:627-32.
 43. Gupta PK, Bordelon A, Vroman DT, Afshari NA, Kim T. Early outcomes of Descemet stripping automated endothelial keratoplasty in pseudophakic eyes with anterior chamber intraocular lenses. *Am J Ophthalmol* 2011;151:24-8.
 44. Esquenazi S, Schechter BA, Esquenazi K. Endothelial survival after Descemet-stripping automated endothelial keratoplasty in eyes with retained anterior chamber intraocular lenses: Two-year follow-up. *J Cataract Refract Surg* 2011;37:714-9.
 45. Ratanasit A, Gorovoy MS. Long-term results of Descemet stripping automated endothelial keratoplasty. *Cornea* 2011;30:1414-8.
 46. Kaiura TL, Ritterband DC, Koplin RS, Shih C, Palmiero PM, Seedor JA. Endophthalmitis Following Descemet's Stripping Endothelial Keratoplasty With Concave Oriented Dislocation on Slit Lamp Optical Coherence Topography. *Cornea*. 2009 Dec 17. [Epub ahead of print]
 47. Koenig SB, Wirostko WJ, Fish RI, Covert DJ. Candida keratitis after Descemet stripping and automated endothelial keratoplasty. *Cornea* 2009;28:471-3.
 48. Sengupta J, Khetan A, Saha S, Ganguly A, Pal D. Bacterial keratitis after manual Descemet stripping endothelial keratoplasty—a different pathophysiology? *Eye Contact Lens* 2010;36:62-5.
 49. Lee WB, Foster JB, Kozarsky AM, Zhang Q, Grossniklaus HE. Interface fungal keratitis after endothelial keratoplasty: A clinicopathological report. *Ophthalmic Surg Lasers Imaging*. 2011 Apr 14;42 Online: e44-8. doi: 10.3928/15428877-20110407-01.
 50. Ortiz-Gomariz A, Higuera-Esteban A, Gutiérrez-Ortega ÁR, González-Méjome JM, Arance-Gil A, Villa-Collar C. Late-onset candida keratitis after Descemet stripping automated endothelial keratoplasty: Clinical and confocal microscopic report. *Eur J Ophthalmol* 2011;21:498-502.
 51. Chew AC, Mehta JS, Li L, Busmanis I, Tan DT. Fungal endophthalmitis after Descemet stripping automated endothelial keratoplasty—a case report. *Cornea* 2010;29:346-9.
 52. Basak SK, Deolekar SS, Mohanta A, Banerjee S, Saha S. *Bacillus cereus* infection after Descemet stripping endothelial keratoplasty. *Cornea* 2012;31:1068-70.
 53. Singh A, Gupta A, Stewart JM. Posterior dislocation of Descemet stripping automated endothelial keratoplasty graft can lead to retinal detachment. *Cornea* 2010;29:1284-6.
 54. Afshari NA, Gorovoy MS, Yoo SH, Kim T, Carlson AN, Rosenwasser GO, *et al.* Dislocation of the donor graft to the posterior segment in Descemet stripping automated endothelial keratoplasty. *Am J Ophthalmol* 2012;153:638-42.
 55. Phillips PM, Terry MA, Shamie N, Chen ES, Hoar K, Dhoot D, *et al.* Descemet stripping automated endothelial keratoplasty in eyes with previous trabeculectomy and tube shunt procedures: Intraoperative and early postoperative complications. *Cornea* 2010;29:534-40.

Cite this article as: Basak SK, Basak S. Complications and management in Descemet's stripping endothelial keratoplasty: Analysis of consecutive 430 cases. *Indian J Ophthalmol* 2014;62:209-18.

Source of Support: Nil. **Conflict of Interest:** None declared.