


Entecavir-associated thrombocytopenia

Yi Yu¹  and Hao Feng^{1,2} 

International Journal of
Immunopathology and Pharmacology
Volume 35: 1–4
© The Author(s) 2021
Article reuse guidelines:
sagepub.com/journals-permissions
DOI: 10.1177/20587384211059676
journals.sagepub.com/home/iji


Abstract

Entecavir (ETV) is widely used in the treatment of hepatitis B, but there are only a few reports about entecavir-associated thrombocytopenia, and it is considered as an immediate response and inappropriate to continue the treatment with other nucleoside analogues. Now, we report the third case, and this case was delayed response and we switched to treatment with tenofovir (TDF). There was a 66-year-old female who was infected with hepatitis B virus (HBV). Her platelet count decreased from $111 \times 10^9/L$ to $3 \times 10^9/L$ and was prone to gum bleeding and skin ecchymosis after she received ETV treatment for 88 days. As a treatment option, ETV was replaced by TDF immediately, frequent platelets transfusions and thrombopoietin were applied for several days, daily prednisone of 50 mg was concomitantly taken, and then platelet count improved after 10 days. She was diagnosed with entecavir-associated thrombocytopenia after analysis of the temporal relationship and exclusion of other causes of thrombocytopenia by blood and bone marrow examinations. Our case suggested that the platelet count should be monitored regularly in patients during ETV treatment, and it may be a feasible option to choose TDF to maintain antiviral treatment when entecavir-associated thrombocytopenia occurs.

Keywords

entecavir, entecavir-associated thrombocytopenia, hepatitis B, tenofovir

Date received: 20 July 2021; accepted: 26 October 2021

Introduction

Many people infected with hepatitis B virus (HBV) and for the development of chronic hepatitis B (CHB), hepatitis B associated liver cirrhosis (HBV-LC) or hepatocellular carcinoma (HBV-HCC) in China.¹ The only effective method to block the progression is antiviral therapy, and entecavir (ETV) is a first-line drug for the treatment of chronic HBV infection, which has been used for decades and proven to have slight side effects and good tolerance. In rare cases, ETV would be associated with severe thrombocytopenia, there are two case reports of entecavir-associated thrombocytopenia, and it is considered as an immediate response and inappropriate to continue the treatment with nucleoside analogues.^{2,3} Here, we report the third case of a female who developed severe thrombocytopenia with bleeding after she had received entecavir for 88 days, and switched to treatment with tenofovir.

Case presentation

A 66-year-old female was diagnosed with CHB in Nanjing Jiangbei Hospital on 17 September 2019. Diagnosis results on hepatitis B surface antigen (HBsAg), hepatitis B e antigen (HBeAg), and hepatitis B core antibody (anti-HBc) were positive, while antibodies to hepatitis A, hepatitis C, hepatitis D, and hepatitis E were negative. There was no evidence of infection with cytomegalovirus, HIV virus, herpes simplex

¹Infectious Diseases Section, Nanjing Jiangbei Hospital, Nanjing, China

²Infectious Diseases Section, Nanjing Pukou Central Hospital, Jiangsu Provincial People's Hospital Pukou Branch, Nanjing, China

Corresponding author:

Hao Feng, Infectious Diseases Section, Nanjing Jiangbei Hospital, No.552, Geguan Road, Nanjing, 210048, China; Infectious Diseases Section, Jiangsu Provincial People's Hospital Pukou Branch, 211800, China. Email: drill2004@sina.com



Creative Commons Non Commercial CC BY-NC: This article is distributed under the terms of the Creative Commons Attribution-NonCommercial 4.0 License (<https://creativecommons.org/licenses/by-nc/4.0/>) which permits non-commercial use, reproduction and distribution of the work without further permission provided the original work is attributed as specified on the SAGE and Open Access pages (<https://us.sagepub.com/en-us/nam/open-access-at-sage>).

virus, or Epstein–Barr virus. In addition, the results were also negative for serologic markers of autoimmune diseases (antinuclear antibody (ANA), antinuclear ribonucleoprotein (anti-nRNP), anti-Smith antibody (anti-Sm), anti-Sjogren's syndrome antigen A antibody (anti-SSA), anti-Ro-52 antibody (RO-52), anti-Sjogren's syndrome antigen B antibody (anti-SSB), anti-scleroderma-70 antibody (anti-ScL-70), anti-histidyl-transfer RNA synthetase antibody (anti-JO-1), centromere protein B (CB), antidouble-stranded DNA antibody (anti-dsDNA), nucleosome (NUC), histone (HI), anti-ribosomal P-protein antibody (RIB), anti-PM/Scl antibody (PM-Scl), proliferating cell nuclear antigen (PCNA), anti-mitochondrial antibody (AMA), anti-liver and kidney microsomal antibody (LKM), anti-liver cytosol antigen type 1 antibody (LC-1), and soluble liver antigen (SLA) were all negative). Meanwhile, alanine aminotransferase (ALT): 41 IU/L and aspartate aminotransferase (AST): 41 IU/L. HBV-DNA in serum was 6.14×10^6 IU/ml, and the platelet count was 111×10^9 /L. An abdominal magnetic resonance imaging (MRI) scan showed signs of fatty liver. The patient started taking ETV 0.5 mg/day after being diagnosed with CHB. She did not experience any discomfort during the treatment.

Till December 13, she found herself prone to gum bleeding and skin ecchymosis without nasal hemorrhage or sclera bleeding, She denied epistaxis, melena, hematochezia, hematuria, or other bleeding manifestations, and without other chronic or neoplastic disease. Results of blood examination showed that platelet count dropped to 3×10^9 /L, while white blood cell (WBC) and hemoglobin (HGB) remained normal. HBV-DNA in serum was raised to 4.42×10^2 IU/ml with ALT: 52 U/L, AST: 54 U/L, IgA: 2.15 g/L, IgG: 17.90 g/L, and IgM 1.54 g/L. On physical examination, her temperature was 36.9°C ; blood pressure, 116/77 mmHg; pulse, 67 beats/min; and respiratory rate, 18 beats/min. She looked tired but had no pallor, icterus, or generalized lymphadenopathy. The anterior nares were clear without epistaxis. The

mucous membrane was moist, and the oral mucosa of the oropharynx has many scabs and dried blood. Auscultation of chest revealed that S1 and S2 were normal, without fricative, murmur, gallop, or blister, and the patient had normal breath sounds. Her abdomen was soft without tenderness, hepatosplenomegaly, or ascites. The skin was warm and dry, with several ecchymoses on the chest and back.

She immediately underwent bone marrow aspiration. The bone marrow examination revealed that the hyperplasia was significantly active, granulocytic and erythroid hyperplasia were active, megakaryocytes were common, and platelets were rare. Immunotype lymphocytes occupy about 12% of nucleus cells, and the proportion is reduced. Among them, precursor B-lymphocytes account for 0.5% of lymphocytes, which increases, but there is no obvious light-chain restriction. The cells in the primitive area occupy about 1% of the nucleus cells and are scattered. Monocytes occupy about 4% of the nucleus cells and have a mature phenotype. Granulocytes accounted for about 68% of nuclear cells, and no significant abnormalities were observed (Figure 1(a)). Peripheral blood flow cytometry showed a significant increase in B-lymphocytes (29.20%) (Figure 1(b)). All performance was in accordance with thrombocytopenia.

Platelet count may be decreased by the factor of aplastic anemia, leukemia, cancer, severe infections, immune abnormalities, drugs, vaccines, and so on.^{4,5} Since the patient had no history of other medications or infections while taking ETV, and no other causes of thrombocytopenia were identified. The patient was diagnosed with entecavir-associated thrombocytopenia.

ETV medication was replaced by tenofovir (TDF) immediately. Since the patient was in urgent condition, frequent platelets transfusions and thrombopoietin were applied for several days, and daily prednisone of 50 mg was concomitantly taken. Platelet count increased after 10 days, and her symptoms of bleeding faded away gradually. The platelet count reached 297×10^9 /L after 18 days (Figure 2).

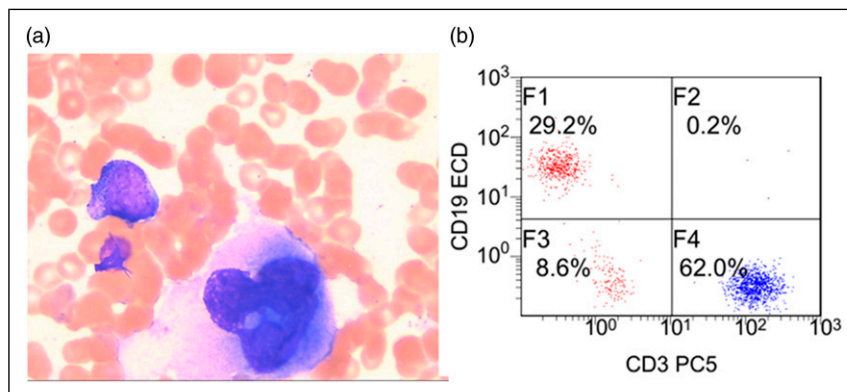


Figure 1. Megakaryocyte mature hindrance in bone marrow and the changes of B-lymphocytes in peripheral blood. (A) Megakaryocyte mature hindrance in bone marrow and (B) peripheral blood flow cytometry showed a significant increase in B-lymphocytes.

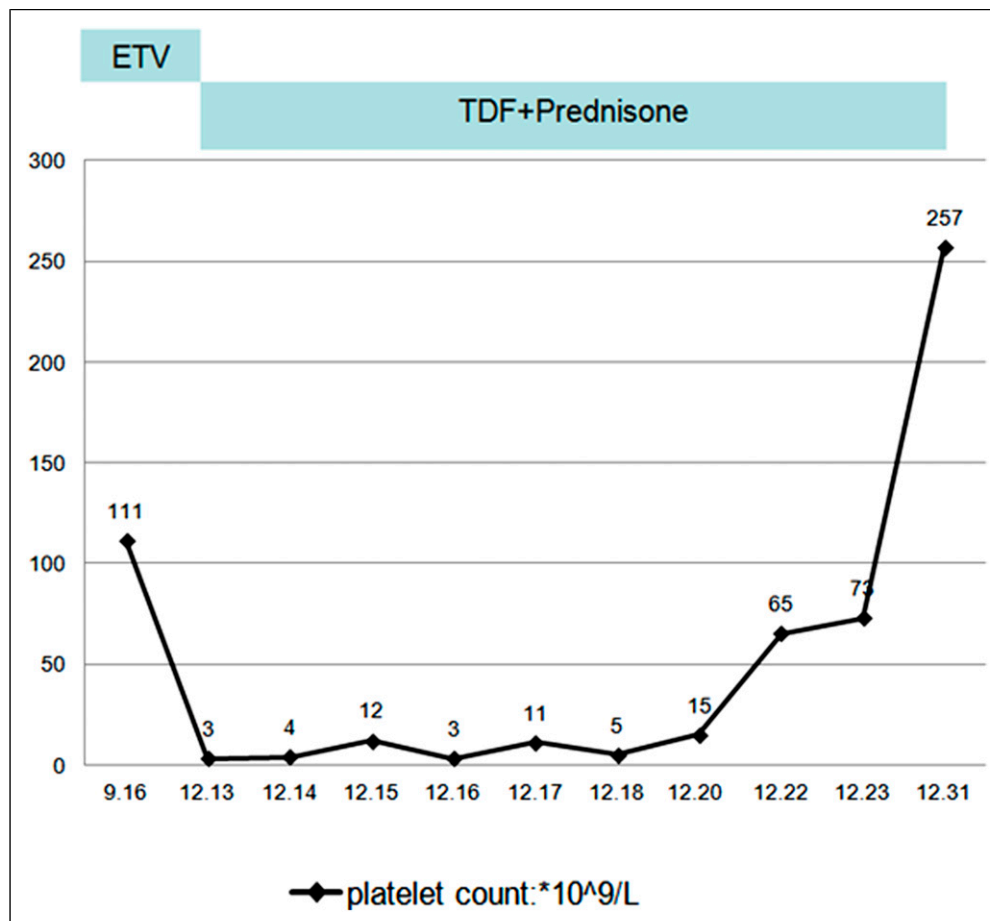


Figure 2. The changes of platelet count after using prednisone of 50 mg daily. The level of platelet count was raised after 10 days with prednisone of 50 mg daily.

Discussion

Thrombocytopenia, characterized by low platelet count and mucocutaneous bleeding, is defined as decreased platelet numbers along with the absence of decreased megakaryocytes in the bone marrow. There are some cases of thrombocytopenia caused by drugs, called drug-induced thrombocytopenia (DITP). The specific mechanism is not recognized, and the etiology is partly due to the direct destruction of platelets by the drugs. The second is that the drug activates autoimmunity and induces the production of drug-dependent antiplatelet antibodies which can bind on glycoprotein Ib-IX, glycoprotein IIb-IIIa, and platelet-endothelial cell adhesion molecule-1; all of the above causes eventually lead to thrombocytopenia.^{5,6}

There are five case reports of nucleoside analogue (NA)-associated thrombocytopenia, and only two with entecavir-associated thrombocytopenia—one had rheumatoid arthritis with decompensated liver cirrhosis, and thrombocytopenia appeared after 4 days of using ETV, and the other was a myeloma patient who had received

rituximab, and thrombocytopenia occurred after 5 days of using ETV; both patients were successfully treated by discontinuation of ETV and intravenous immunoglobulin. Summarizing all three patient data, we found that they were all over 60 years old, which prompted the conclusion that this complication may occur more frequently in elderly women. In consideration of the onset time of entecavir-associated thrombocytopenia, we found that two cases had abnormal changes in immune function that happened in 1 week and the last one was significantly delayed—the patient had no underlying disease other than CHB, and therefore, entecavir-related thrombocytopenia was not only an immediate response, but also a delayed response. It was speculated that the occurrence time of entecavir-associated thrombocytopenia may be related to the degree of immune environment imbalance of patients.

Through bone marrow and peripheral blood examination, we found that the patient had a significant increase in B-lymphocytes. Its main functions include improving secretion of autoantibodies, presenting autoantigens and ensuing reciprocal interactions with T cells, secreting inflammatory

cytokines, and promoting the production of ectopic germinal centers. It has been confirmed that T-lymphocytes may induce HBV clearance under the action of B-lymphocytes⁷; therefore, the increase of B-lymphocyte and HBV-DNA during the patient's treatment may be related to the failure of ETV. At the same time, thrombocytopenia is often related to the high expression of B-lymphocytes, which means better steroid response⁸; that may be the one of the reasons why we succeeded in treating this patient with prednisone alone instead of combined with intravenous immunoglobulin.

Clinicians should consider drug-induced thrombocytopenia in the differential diagnosis of a patient on ETV therapy presenting with unexplained isolated thrombocytopenia. Entecavir-associated thrombocytopenia can mimic primary immune thrombocytopenia (ITP); however, distinguishing these syndromes is important to avoid unnecessary immunosuppressive treatments and to avoid future exposure to the sensitizing drug. Hence, it is important for clinicians to be aware of this adverse drug event and have a general understanding of the common drugs associated with thrombocytopenia.

Conclusions

Since entecavir-associated thrombocytopenia is a reversible cause of thrombocytopenia, which would present with severe thrombocytopenia after starting ETV and resolution after discontinuing the drug, so clinicians should monitor the platelet count during treatment. In the event of a severe decrease in the platelet count, the possibility of the entecavir-associated thrombocytopenia should be considered and the drug should be stopped as soon as possible. Based on this case, platelets count should be checked regularly throughout treatment and detection of B-lymphocytes' level during early administration of ETV may have certain predictability for entecavir-associated thrombocytopenia. Since we replaced ETV with TDF, and the platelet count did not continue to decline, it may be a feasible option to choose TDF to maintain antiviral treatment when entecavir-associated thrombocytopenia occurs.

Author's contributions

Yi Yu analyzed and interpreted the patient data. Hao Feng was a major contributor in writing the manuscript. All authors read and approved the final manuscript.

Declaration of conflicting interests

The authors declared no potential conflicts of interest with respect to the research, authorship, and/or publication of this article.

Funding

The authors disclosed receipt of the following financial support for the research, authorship, and/or publication of this article: The project was supported by the Medical Technology Development of Nanjing (YKK18243); Nanjing Medical Science and Technique Development Foundation (QRX17098).

ORCID iDs

Yi Yu  <https://orcid.org/0000-0002-8052-2030>

Hao Feng  <https://orcid.org/0000-0002-2066-2496>

Ethical approval

The study protocol was approved and monitored by the ethics committee of Nanjing Jiangbei Hospital(Code 20180040), and written informed consent was obtained from the patients

References

1. Liaw YF and Chu CM (2009) Hepatitis B virus infection. *Lancet* 373: 582–592.
2. Fan X, Chen L, Yang J, et al. (2016) Entecavir-associated thrombocytopenia in a decompensated cirrhotic patient: a case report and literature review. *Medicine (Baltimore)* 95(12): e3103.
3. Yohannan B, Luu DCN and Feldman M (2019) Entecavir-associated thrombocytopenia: a case report and review of the pathophysiology, diagnosis, and treatment of a rare but reversible cause of thrombocytopenia. *Case Reports in Hematology* 2019: 4319148.
4. Reese JA, Nguyen LP, Buchanan GR, et al. (2013) Drug-induced thrombocytopenia in children. *Pediatric Blood Cancer* 60(12): 1975–1981.
5. Rizvi MA, Shah SR, Raskob GE, et al. (1999) Drug-induced thrombocytopenia. *Current Opinion in Hematology* 6(5): 349–353.
6. Wu YF, Huang WH, Gu MH, et al. (2019) Higher CD56+ or CD2+ lymphocyte percentage predicts poor steroid response in patients with immune thrombocytopenia. *Thrombosis Research* 183: 63–68.
7. Wang FS and Zhang Z (2009) Host immunity influences disease progression and antiviral efficacy in humans infected with hepatitis B virus. *Expert Review of Gastroenterology & Hepatology* 3: 499–512.
8. Durani U, Go RS and Kay NE (2018) Immune-mediated hemolytic anemia and thrombocytopenia in clonal B-cell disorders: a review. *Clinical Advances in Hematology & Oncology* 16(10): 670–676.