

Available online at www.sciencedirect.com

ScienceDirect

journal homepage: www.e-jds.com

Correspondence

Artificial intelligence measurement of multi-layer tooth structures using semantic segmentation and computer vision

KEYWORDS

Artificial intelligence;
Semantic segmentation
model;
Tooth structure;
Cone-beam computed
tomography;
Dentistry

Recently, the development of artificial intelligence (AI) in dentistry has been extensively reported. These studies encompass the development of the AI-driven language,¹ the application of the AI imaging for diagnostics,² and the generation of the AI-designed dental crowns.³ These findings indicate that computational assistance tools are progressively being adopted in medicine and dentistry. Thus, the application of the AI has become an important development trend of the dental technology. Given the complexities of assessing the dental caries-related depth and parameters, this article introduced a novel evaluation guidance (Fig. 1A), grounding in clinical definitions and integrated with the AI algorithms to assist clinicians in assessing the dental caries risk. This study employed the cone-beam computed tomography (CBCT, ProMax 3D Plus, Planmeca, Finland) to acquire a series of cross-sectional images of an individual tooth, capturing slices from the buccal to the lingual aspects. An analysis was conducted on the spatial tissue architecture of the tooth across various cross-sectional layers.

The method begun with a semantic segmentation algorithm to isolate regions of interest in the tooth radiographs, specifically the enamel, the dentin, and the pulp chamber (Fig. 1B). The key parameters were then calculated for the dental caries assessment, focusing on two primary measures:

(1) the enamel thickness and (2) the distance from the enamel to the pulp chamber (Fig. 1C). The enamel thickness was calculated across the majority of the enamel region. Given that the enamel near the gingival area is typically thinner, a peak-finding algorithm was used to detect the corner point of the lower surface of the enamel, establishing a cutoff at this point to prevent measurement inaccuracies. For calculating the enamel-to-pulp chamber distance, the vertical distance from the enamel's lower surface to the pulp chamber was measured. Because the pulp chamber is relatively small, certain regions of the enamel's lower surface do not align vertically with it. To address this, an edge-finding algorithm identified the left and right boundaries on the segmented contour, and the distance calculation was restricted to the area within these boundaries. Through the automatic computer-based assessment, each parameter was evaluated at 10-pixel increments, generating a detailed measurement curve (Fig. 1D and E).

This novel method enabled a comprehensive evaluation of the enamel thickness and the dentin-to-pulp chamber distance, allowing for statistical analysis of parameters such as the average, maximum, and minimum values to enhance precision in the dental caries assessment. Moreover, this computational evaluation method facilitated the assessment of the dental caries risk at various depths within

<https://doi.org/10.1016/j.jds.2024.11.007>

1991-7902/© 2025 Association for Dental Sciences of the Republic of China. Publishing services by Elsevier B.V. This is an open access article under the CC BY-NC-ND license (<http://creativecommons.org/licenses/by-nc-nd/4.0/>).

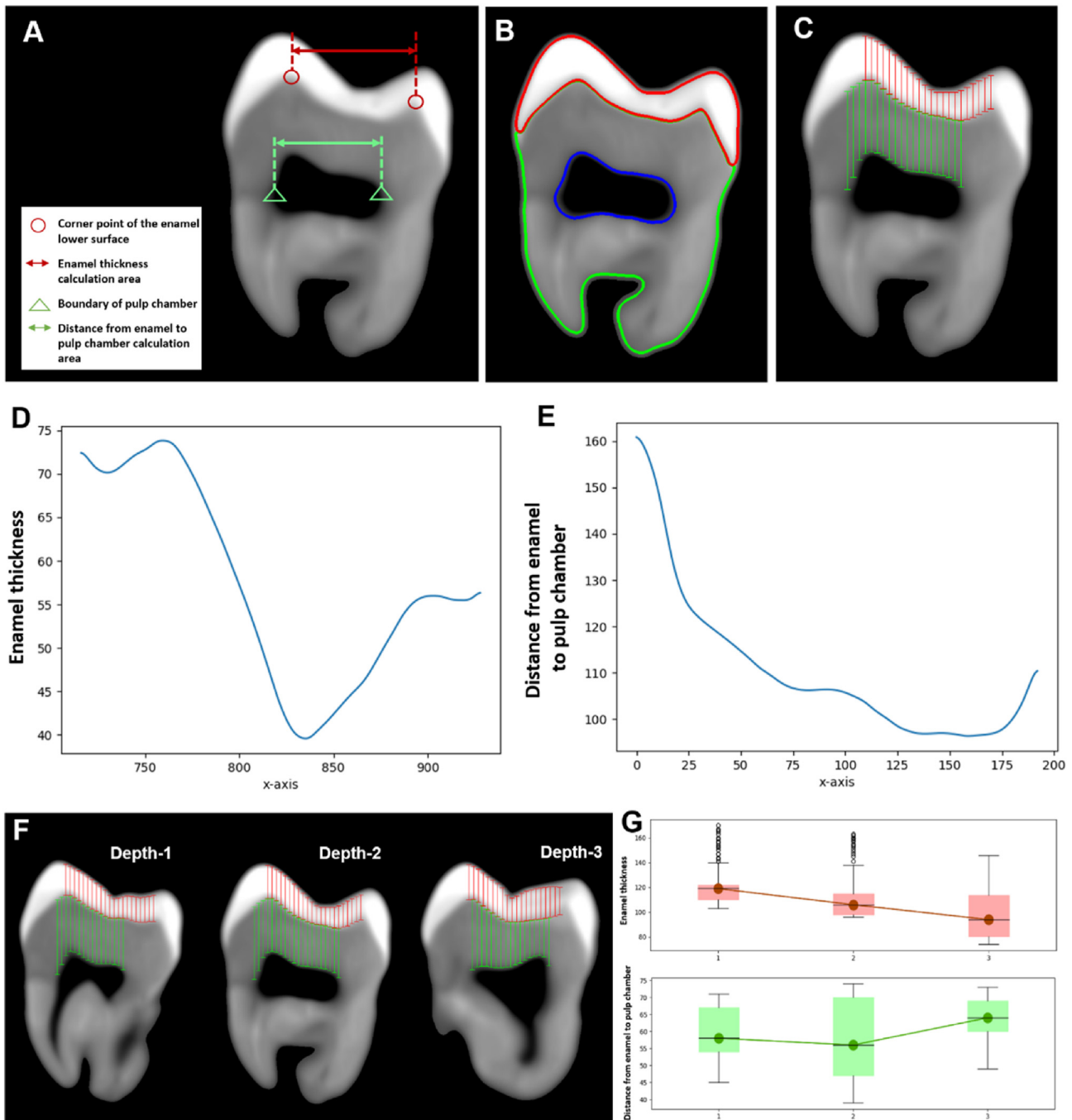


Figure 1 Overview of a novel evaluation method for the dental caries assessment. (A) The schematic of the evaluation concept and the cutoff determination. (B) The semantic segmentation of the enamel, the dentin, and the pulp chamber regions. (C) The automatic computer-based assessment of parameters at 10-pixel increments. (D) The enamel thickness curve corresponding to Fig. 1C. (E) The curve of the distance from the enamel to the pulp chamber corresponding to Fig. 1C. (F) The CBCT images of a tooth at varying depths. (G) The landscape visualization of the two parameters along with the depth.

the CBCT images (Fig. 1F). By leveraging automatic calculation, parameters across the different layers could be determined, generating a landscape that depicted variation through the depths in the three-dimensional (3D) space (Fig. 1G).

Due to the intricate anatomy of the natural teeth, utilizing the 3D spatial imaging enables more precise diagnostics.⁴ This study proposed a technology that combined

the image recognition, the language processing, and the spatial computation. The calculation of the distances between different tooth structures was built upon the AI image learning technology. This tool thus served as a pre-screening aid, enabling clinicians to rapidly identify the critical layers and diagnose the dental caries with greater accuracy. Moreover, the analysis of these 3D images aided in the digital teaching and learning of dentistry.⁵ However,

the accuracy, precision, and clinical applicability still require evaluation through the relevant studies. It is expected that this study may serve as a reference for the future applications of the AI in the measurement of the complex structures.

Declaration of competing interest

The authors have no conflicts of interest relevant to this article.

Acknowledgments

The authors extend their gratitude to Shao-Yu Chang, an AI scientist at ST Medical Technology, for his invaluable advice on the AI models and related calculations. The authors thank Dr. Chi-Yu Lin for his important contribution to the labeling of the dental images.

References

1. Shan T, Tay FR, Gu L. Application of artificial intelligence in dentistry. *J Dent Res* 2021;100:232–44.
2. Kao CT, Tseng CJ, Tsai MC, Huang CN. Determination of periodontal bone loss in panoramic radiographs through artificial intelligence analysis. *J Dent Sci* 2025;20:698–700.
3. Liu CM, Lin WC, Lee SY. Evaluation of the efficiency, trueness, and clinical application of novel artificial intelligence design for dental crown prostheses. *Dent Mater* 2024;40:19–24.
4. Cen Y, Huang X, Liu J, et al. Application of three-dimensional reconstruction technology in dentistry: a narrative review. *BMC Oral Health* 2023;23:630.
5. Kato A, Ziegler A, Utsumi M, Ohno K, Takeichi T. Three-dimensional imaging of internal tooth structures: applications in dental education. *J Oral Biosci* 2016;58:100–11.

Yu-Chieh Lin[†]

Digital Medicine Center, Translational Health Research
Institute, Vilnius University, Vilnius, Lithuania

Institute of Research, Development and Innovation, IMU
University, Kuala Lumpur, Malaysia

Feng-Chou Cheng[†]

Chia-Te Dental Clinic, New Taipei City, Taiwan
School of Life Science, College of Science, National Taiwan
Normal University, Taipei, Taiwan
Science Education Center, National Taiwan Normal
University, Taipei, Taiwan

Wei-Chun Lin^{**}

School of Dental Technology, College of Oral Medicine,
Taipei Medical University, Taipei, Taiwan
Department of Dentistry, Wan-Fang Hospital, Taipei
Medical University, Taipei, Taiwan

Chun-Pin Chiang^{*}

Department of Dentistry, National Taiwan University
Hospital, College of Medicine, National Taiwan University,
Taipei, Taiwan
Graduate Institute of Oral Biology, School of Dentistry,
National Taiwan University, Taipei, Taiwan
Department of Dentistry, Hualien Tzu Chi Hospital,
Buddhist Tzu Chi Medical Foundation, Hualien, Taiwan
Institute of Dental Medicine and Materials, College of
Medicine, Tzu Chi University, Hualien, Taiwan

^{**}Corresponding author. School of Dental Technology, College of Oral Medicine, Taipei Medical University, No. 250, Wu-Xing Street, Taipei, 11031, Taiwan.
E-mail address: weichun1253@tmu.edu.tw (W.-C. Lin)

^{*}Corresponding author. Department of Dentistry, Hualien Tzu Chi Hospital, Buddhist Tzu Chi Medical Foundation, and Institute of Dental Medicine and Materials, College of Medicine, Tzu Chi University, No. 707, Section 3, Chung-Yang Road, Hualien 970, Taiwan.
E-mail address: cpchiang@ntu.edu.tw (C.-P. Chiang)

Received 2 November 2024
Available online 14 November 2024

[†] These two authors contributed equally to this work.