

# Renal cell carcinoma metastatic to the scalp

Mounir Errami,<sup>1</sup> Vitali Margulis,<sup>1</sup>  
Sergio Huerta<sup>1,2</sup>

<sup>1</sup>The University of Texas Southwestern Medical School, Dallas; <sup>2</sup>Veterans' Affairs Hospital, Dallas, TX, USA

## Abstract

Because of the asymptomatic natural history of renal cell carcinoma (RCC), by the time a diagnosis is made, metastatic disease is present in about one third of the cases. Thus, the overall survival of patients with RCC remains poor. Ultimately up to 50% of patients with RCC will develop metastases. Metastatic lesions from RCC are usually observed in the lungs, liver or bone. Metastases to the brain or the skin from RCC are rare. Here we present a patient diagnosed with RCC, found to have no evidence of metastases at the time of nephrectomy, who presented two years later with metastases to the scalp. We review the literature of patients with this rare site of metastasis and outline the overall prognosis of this lesion compared to other site of metastases from RCC.

## Introduction

Renal cell carcinoma (RCC) is a cancer that originates in the proximal tubule epithelium of the kidney. It is responsible for over 95% of kidney cancers and represents about 3% of malignant tumors in adults. RCC is twice more frequent in man than women and typically presents in the 7<sup>th</sup> decade of life.<sup>1</sup> Hematuria, flank pain and abdominal mass are the symptoms called the *classic triad* for the presentation of RCC despite the fact this triad is quite infrequent as it is found only in about 10% of patients diagnosed with RCC.<sup>2,3</sup> RCC also presents with other insidious non-specific symptoms such as weight loss, fever, and hypertension, as well as left sided varicocele in males. It might also present with anemia as a result of erythropoietin suppression. In rare instances (less than 5%) paraneoplastic syndromes associated with the disease are present resulting in hypercalcemia or erythrocytosis. The heterogeneity of the presentation of the disease compounded by the lack of warning signs makes the detection of RCC challenging. By the time of diagnosis, metastasis had occurred in about one third of the cases.<sup>4</sup> While RCC is known to primarily metastasize

to the lungs and the liver (Figure 1), virtually any organ can be involved including skin, muscle, thyroid or pancreas.<sup>3</sup> Here we report a case of RCC metastatic to the scalp two years post nephrectomy following an R0 operation.

## Case Report

The patient is a 64-year-old African American man who presented with back pain in the fall 2012. Diagnostic work up for the back pain included a computed tomography scan, which showed a 7 cm incidental mass on the right kidney. He then underwent right nephrectomy and pathology studies of the mass were consistent with a 5.3 cm RCC Furham grade 3, identified grossly as a golden yellow tumor with a hemorrhagic surface showing several white and gray areas that occupied the inferior pole. The excision margins were found to be negative and it was concluded that the tumor was confined to the kidney with no involvement of the vein, the renal sinus and the local lymphovascular structures. Later in August 2014, the patient noted a left tonsillar mass with cervical lymphadenopathy and underwent bilateral tonsillectomy after an inconclusive biopsy. The surgical pathology report concluded that the mass was a 1.0×0.4×0.4 cm carcinoma metastasis, with similar histologic features to the previous RCC. The right tonsil was normal. The excision margins were again free of carcinoma. Subsequent repeat positron emission tomography scans through spring 2015 demonstrated constantly progressing and increased osteoblastic activity with associated active soft tissue in multiple sites including left clavicle (medial third), left sixth rib, left T012 hemivertebra, right acetabulum and ischium, and right mid femur. These foci of activity were compatible with malignant and metastatic etiology. In the summer of 2015, the patient presented with bleeding lesions of the scalp grossly visible as three heterogeneously ulcerated masses, the largest of which was on the forehead measuring 4.4×3.3 cm (Figure 2).

Pathology and immunochemical analyses revealed atypical cells, positive for CAM 5.2 and negative for CK7 and CD68 consistent with metastasis from a primary RCC. Late in 2015, the patient presented with fever and altered mental status due to a bacterial infection. An incidental new pulmonary mass was found in the left lower lobe, presumably another metastatic mass of his previous RCC.

During 2015, the patient was treated with everolimus. Everolimus is a mammalian target of rapamycin (mTOR) inhibitor which had previously been shown to prolong progression-free survival relative to placebo in patients with metastatic renal cell carcinoma whose

Correspondence: Sergio Huerta, Veterans' Affairs Hospital, 4500 S Lancaster Rd. 140, Dallas, TX 75216, USA.

Tel.: +1.214.857.0971.

E-mail: sergio.huerta@utsouthwestern.edu

Key words: Renal cell carcinoma; skin; scalp; metastasis, carcinogenesis.

Contributions: ME, analysis of the case, primary drafting of the first version of the manuscript with subsequent revisions; VM, draft revision; SH, conceived the idea, analysis of the case, drafting and revising the manuscript, assistance with funding.

Conflict of interest: the authors declare no potential conflict of interest.

Received for publication: 14 January 2016.

Revision received: 11 June 2016.

Accepted for publication: 15 June 2016.

This work is licensed under a Creative Commons Attribution NonCommercial 4.0 License (CC BY-NC 4.0).

©Copyright M. Errami et al., 2016  
Licensee PAGEPress, Italy  
Rare Tumors 2016; 8:6400  
doi:10.4081/rt.2016.6400

disease had progressed while on vascular endothelial growth factor-targeted therapy with (with tyrosine kinase inhibitors such as sunitinib or soratinib).<sup>5</sup> However, the patient decided to discontinue treatment late in 2015 due to relentless clinical progression of his disease as evidenced by the appearance of bleeding metastasis on the scalp and worsening symptoms such as chest pain and left leg pain. The patient declined pursuing further chemotherapy or radiation therapy and opted for hospice care.

## Discussion

The estimated incidence of RCC in 2015 is slightly above 61,000 cases, resulting in a mortality of about 14,000 individuals. There are about 400,000 people living with kidney cancer in the United States. While the number of cases has slowly increased over the past two decades, the number of deaths has remained constant. The 5-year overall survival following diagnosis of RCC is 80% for stage I and plummets to 8% with distant metastases.<sup>1</sup> The median overall survival of stage IV RCC is 11.1 months in patients in which the primary tumor is surgically removed.<sup>6</sup>

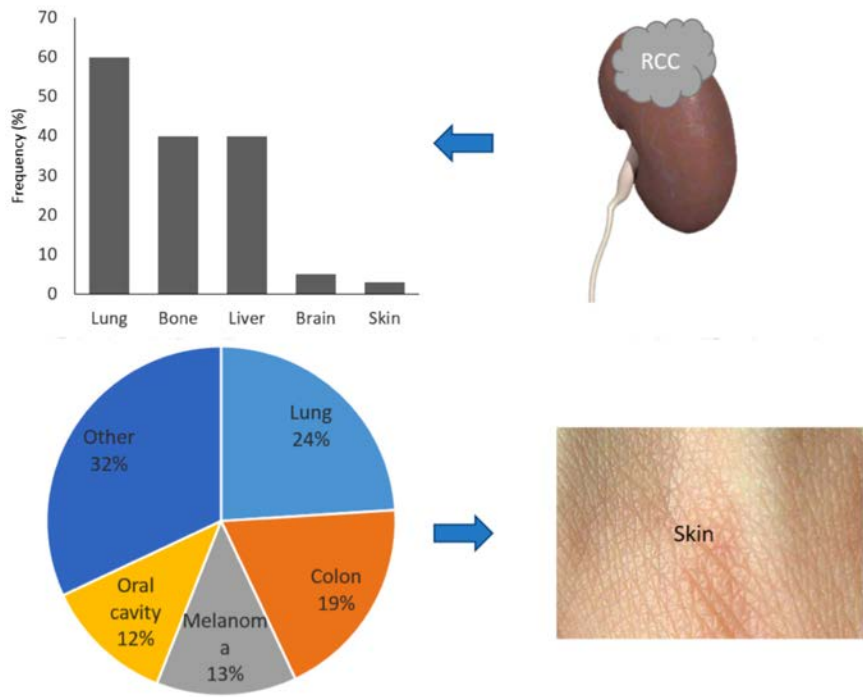
Metastasis to the scalp from RCC is a rare

occurrence. To date, there have been less than 50 reports of RCC with metastasis to the skin and six reported metastases to the scalp (Table 1).<sup>7-11</sup> RCC is one of the carcinomas known to spread hematogenously along with follicular carcinomas of the thyroid, choriocarcinoma, and hepatocellular carcinoma. RCC spreads via three routes,<sup>12</sup> the most important being via the renal vein and vena cava to the right atrium and lung. However there is a lack of data supporting the hematogenous spread from the kidney (or pelvic organs) to the scalp, although theoretically possible via the renal veins to the plexus of Batson (with low pressure and flow inversion) to vertebral veins to emissary scalp veins. While the path of spread of RCC to the head, neck and skin is still conjecture, the fact remains that skin metastases are found in 1 to 3% of cases and the preferred sites are the scalp and the face.<sup>13,14</sup>

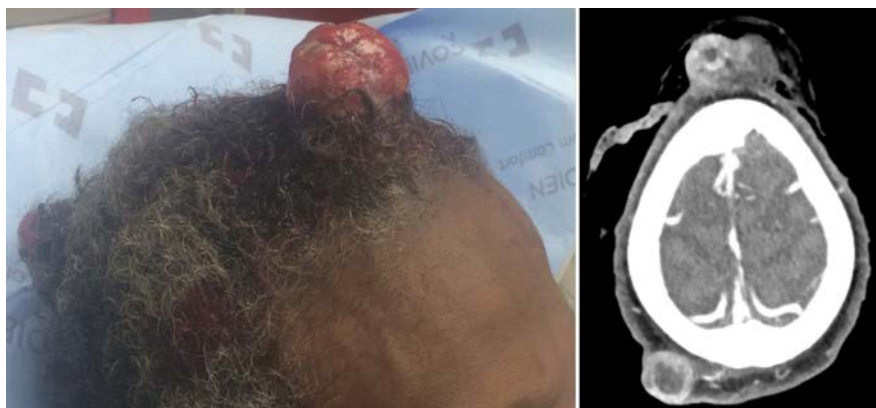In the absence of metastasis, nephrectomy is the mainstay of treatment and offers 5-year survival rates of above 90% in patients with stage I RCC. Patients with stage II and III see a relapse rate of about 40%, usually within 3 years post-surgical excision.<sup>15</sup> Adjuvant therapy has thus far failed to demonstrate any benefit in disease free survival (DFS), with clinical studies still being undertaken and results yet to be reported.

In the presence of metastasis, targeted therapy is often the first option. Targeted agents usually administered are tyrosine kinase inhibitor (such as sunitinib),<sup>16</sup> vascular endothelial growth factor inhibitor (such as bevacizumab),<sup>17</sup> or mTOR inhibitor (such as everolimus).<sup>5</sup> The expanding portfolio of targeted agents, albeit with numerous side effects leads to complicated management of the disease, and the prognosis remains dismal with only an extra few months of DFS (*i.e.* sorafenib showed a DFS of 5.5 *vs.* 2.8 months for placebo with no difference in overall survival).<sup>18</sup> Targeted therapies have provided a new window in which to explore potential therapeutic pathways for treatment improvement. However, with one third of patients being diagnosed at the metastatic stage, new diagnostic modalities need to be implemented.

Considerable effort is geared toward the identification of biomarkers for early diagno-



**Figure 1.** Frequency of organs affected in patients with metastasis (top) and frequency by cancer types of cancers that metastasize to the skin (bottom).<sup>1,3</sup>



**Figure 2.** Gross and computed tomography scan presentations of scalp metastases.

**Table 1.** Information regarding reported cases of renal cell carcinoma with metastasis to the scalp.

Author	Age	Gender	Race	Time to diagnosis	Treatment	Overall survival
Livingston <i>et al.</i> <sup>7</sup>	45	Male		1 year		
Snow <i>et al.</i> <sup>8</sup>	69	Female	White	6 years 4 months	Excision with 4 mm margin	
Eke <i>et al.</i> <sup>9</sup>	42	Female				Lost to follow up
Pan <i>et al.</i> <sup>10</sup>	63	Male		6 week		
Barry Delongchamps <i>et al.</i> <sup>11</sup>	74	Male				
Current patient	64	Male	African American	2 years	Nephrectomy, everolimus, hospice	

sis with more accurate prognostic value.<sup>19</sup> However, to date, there is no biomarker that can be used clinically to help with early identification of RCC, or to offer insight regarding the aggressiveness of a tumor in a particular patient. As evidenced by this case, and despite the absence of metastasis at the time of nephrectomy, within less than two years, multiple metastases appeared including metastases on the scalp. It has been shown that metastases to the skin can appear anywhere between 6 months to 6 years in patients in newly diagnosed with RCC.<sup>14,20,21</sup>

There is a lack of data regarding the prognosis value of scalp metastases and how to best manage a patient with metastases to the scalp. A retrospective study of 278 patients shows that resection of solitary metastases from RCC is associated with a 5-year survival rate of 35 to 50% arguing in favor of metastectomy when reasonable.<sup>22</sup> The management of patients with RCC continues to be a challenge from early diagnosis to treatment of complicated metastases. The present report illustrates a patient who was diagnosed incidentally, but still escaped treatment and developed metastatic disease. The metastatic lesions presented a treatment dilemma, but at the end he elected for hospice care.

## Conclusions

Here we present a case of renal cell carcinoma with metastasis to the scalp, two years after nephrectomy. This is quite unusual as metastases to the skin, in the case of RCC, are quite rare. Given the mortality associated with RCC (particularly stage IV), the elusive diagnosis of the condition, the presence of metastasis in one third of cases and the poor response to chemotherapy, the management of patients presenting with RCC must include frequent and timely follow-ups.<sup>23</sup> The absence of metastases, even years after surgery, doesn't preclude the appearance of metastases in the evolution of the disease, emphasizing the need for continued close monitoring of patients diagnosed with RCC. It is therefore critical particularly in the setting of primary care prevention, to stress the importance of

timely and regular follow-ups in patients with RCC after nephrectomy as the median time to recurrence varies from a few months to a couple of years.

## References

1. Howlader N. SEER Research Data 1973-2012. National Cancer Institute, 2014. Available from: <http://seer.cancer.gov/data/seerstat/nov2014/>
2. Cohen HT, McGovern FJ. Renal-cell carcinoma. *N Engl J Med* 2005;353:2477-90.
3. Ritchie AW, Chisholm GD. The natural history of renal carcinoma. *Semin Oncol* 1983;10:390-400.
4. Flanigan RC, Campbell SC, Clark JI, Picken MM. Metastatic renal cell carcinoma. *Curr Treat Options Oncol* 2003;4:385-90.
5. Motzer RJ, Escudier B, Oudard S, et al. Efficacy of everolimus in advanced renal cell carcinoma: a double-blind, randomised, placebo-controlled phase III trial. *Lancet* 2008;372:449-56.
6. PDQ Adult Treatment Editorial Board. National Cancer Institute (US), 2002. Available from: <http://www.cancer.gov/publications/pdq/editorial-boards/adult-treatment>
7. Livingston WD, Becker DW, Lentz CW. Solitary scalp metastasis as the presenting feature of a renal carcinoma. *Br J Plast Surg* 1977;30:319-20.
8. Snow S, Madjar D, Reizner G, et al. Renal cell carcinoma metastatic to the scalp: case report and review of the literature. *Dermatol Surg* 2001;27:192-4.
9. Eke N, Eghwudjakpor P, Echem RC. Renal cell carcinoma presenting as a scalp swelling. *Niger J Med* 2003;12:154-6.
10. Pan D, Niall O, Sharma H, Gya D. Isolated scalp nodule in patient with undiagnosed RCC. *Sci World J* 2006;6:2430-2.
11. Barry Delongchamps N, Peyromaure M, Debre B, Zerbib M. [Renal cancer presenting as an isolated cutaneous metastasis]. *Prog Urol* 2004;14:538-9. [Article in French]
12. Wahner-Roedler DL, Sebo TJ. Renal cell carcinoma: diagnosis based on metastatic manifestations. *Mayo Clin Proc* 1997;72:935-41.
13. Dorairajan LN, Hemal AK, Aron M, et al. Cutaneous metastases in renal cell carcinoma. *Urol Int* 1999;63:164-7.
14. Barbagelata López A, Ruibal Moldes M, Blanco Díez A, et al. [Cutaneous metastasis of a renal carcinoma: case report and review]. *Arch Esp Urol* 2005;58:247-50. [Article in Spanish]
15. Escudier B, Eisen T, Porta C, et al. Renal cell carcinoma: ESMO Clinical Practice Guidelines for diagnosis, treatment and follow-up. *Ann Oncol* 2012;23:vii65-71.
16. Motzer RJ, Hutson TE, Tomczak P, et al. Sunitinib versus interferon alfa in metastatic renal-cell carcinoma. *N Engl J Med* 2007;356:115-24.
17. Rini BI. Vascular endothelial growth factor-targeted therapy in renal cell carcinoma: current status and future directions. *Clin Cancer Res* 2007;13:1098-106.
18. Escudier B, Eisen T, Stadler WM, et al. Sorafenib for treatment of renal cell carcinoma: Final efficacy and safety results of the phase III treatment approaches in renal cancer global evaluation trial. *J Clin Oncol* 2009;27:3312-8.
19. Mickley A, Kovaleva O, Kzhyshkowska J, Gratchev A. Molecular and immunologic markers of kidney cancer-potential applications in predictive, preventive and personalized medicine. *EPMA J* 2015;6:20.
20. Williams JC, Heaney JA. Metastatic renal cell carcinoma presenting as a skin nodule: case report and review of the literature. *J Urol* 1994;152:2094-5.
21. Bujons A, Pascual X, Martínez R, et al. Cutaneous metastases in renal cell carcinoma. *Urol Int* 2008;80:111-2.
22. Kavolius JP, Mastorakos DP, Pavlovich C, et al. Resection of metastatic renal cell carcinoma. *J Clin Oncol* 1998;16:2261-6.
23. Kassouf W, Siemens R, Morash C, et al. Follow-up guidelines after radical or partial nephrectomy for localized and locally advanced renal cell carcinoma. *Can Urol Assoc J* 2009;3:73-6.