

HIGH-DOSE HIGH-FREQUENCY AFLIBERCEPT FOR RECALCITRANT NEOVASCULAR AGE-RELATED MACULAR DEGENERATION

QI SHENG YOU, MD,*† RAOUF GABER, MD,* AMIT MESHI, MD,* HEMA L. RAMKUMAR, MD,* MOSTAFA ALAM, MD,*‡ ILKAY KILIC MUFTUOGLU, MD,* WILLIAM R. FREEMAN, MD*

Purpose: To determine the efficacy of monthly (0.1 mL/4 mg) aflibercept for refractory neovascular age-related macular degeneration (wet age-related macular degeneration).

Methods: This was a retrospective interventional case series in which patients with wet age-related macular degeneration were treated with stepwise dose escalation. Non-vitreotomized patients resistant to monthly (Q4W) ranibizumab/bevacizumab were switched to 2 mg aflibercept every 8 weeks. With resistance, they were escalated to Q4W 2 mg aflibercept, then Q4W 4 mg (high dose high frequency, 4Q4W) aflibercept. Resistance was defined as ≥ 2 recurrences after being dry following ≥ 3 injections or persistent exudation on treatment of ≥ 5 injections.

Results: Thirty-three eyes of 28 patients were treated with 4Q4W aflibercept and followed for a mean of 16 months. A dry retina (no intraretinal or subretinal fluid) was achieved after initiating 4Q4W aflibercept treatment at a mean of 3.8 months. Central foveal thickness, maximum foveal thickness, intraretinal fluid, subretinal fluid, and retinal pigment detachment height decreased significantly at 1 month after initiating the 4Q4W aflibercept, and the morphologic therapeutic effect was sustained until the last visit. Forty-five percent of eyes had one or more lines of vision improvement. New geographic atrophy developed in 9% of eyes during follow-up. No ocular or systemic adverse events occurred after initiating 4Q4W aflibercept.

Conclusion: Intravitreal high-dose high-frequency aflibercept is an effective treatment for patients with refractory wet age-related macular degeneration.

RETINA 38:1156–1165, 2018

Age-related macular degeneration (AMD) is a leading cause of visual impairment and blindness in economically developed countries.^{1,2} The introduction of intravitreal anti-vascular endothelial growth factor (VEGF) agents greatly improved the visual prognosis for patients with neovascular AMD. The pivotal ANCHOR and MARINA clinical trials demonstrated superior visual acuity results with monthly ranibizumab injections compared with photodynamic therapy or observation.^{3,4} The Comparison of Age-Related Macular Degeneration Treatment Trials (CATTs) indicated that bevacizumab had a similar treatment effect and safety profile compared with ranibizumab.⁵ The VIEW 1 and VIEW 2 studies revealed that subjects exhibited similar visual outcomes when treated with aflibercept 2 mg dosed every 2 months (2Q8W)

after a 3 monthly loading dose compared with monthly ranibizumab 0.5 mg.⁶

Although most patients respond well to standardized fixed dosing anti-VEGF treatment, there are some patients resistant to standard treatment intervals and doses and some who initially respond to treatment but keep recurring later. Even in strict clinical trials such as the CATT study, 53% to 79% of patients had macular fluid and 13% to 17% lost more than 5 letters of vision at the 1-year visit.⁵ These recalcitrant patients are very difficult to manage in daily practice. In our practice, patients with wet AMD were treated according to a stepwise algorithm. Patients initially treated with monthly (Q4W) ranibizumab or bevacizumab were switched to 2 mg aflibercept every 8 weeks (2Q8W) when resistance occurred, then escalated to Q4W 2 mg (2Q4W) aflibercept when resistant to

2Q8W aflibercept, then escalated to double dose at Q4W 4 mg (4Q4W) aflibercept when resistance to 2Q4W aflibercept developed. We previously reported 60% of eyes with resistant AMD while on Q4W ranibizumab or bevacizumab respond well to 2Q8W aflibercept,⁷ and the macula was dry for up to 2 years after switching to 2Q8W aflibercept.⁸ We also found that approximately 45% of eyes needed to be escalated from 2Q8W to 2Q4W aflibercept because of persistent fluid, and some of these patients still did not respond very well to monthly 2 mg aflibercept.⁸ In these cases, we initiated a double-dose 4Q4W aflibercept treatment regimen. In the current study, we retrospectively evaluate the efficacy of 4Q4W (high dose high frequency) aflibercept intravitreal injections in patients with wet AMD resistant to other anti-VEGF treatments.

Methods

This retrospective chart review study was conducted according to the principles of the Helsinki Declaration. Written informed consent was obtained for each patient before evaluation and treatment for each intravitreal injection. Institutional Review Board (IRB) approval was acquired from the University of California San Diego for the review and analysis of patients' data. The study complied with the Health Insurance Portability and Accountability Act of 1996.

All the patients were diagnosed with wet AMD and treated by an experienced retinal specialist (W.R.F.) based on clinical characteristics and multimodal imaging including spectral domain optical coherence tomography (OCT) and fluorescein angiography (FA). The

treatment regimen was as needed after an initial loading dose of three monthly injections with monthly evaluation and reinjection until the eye became completely dry, after which we give 1 to 2 bonus injections before going to an observation or holiday phase. Treatment indications included intraretinal fluid (IRF) or subretinal fluid (SRF) on OCT, new or persistent hemorrhage on color fundus photography or ophthalmoscopy, decreased visual acuity as compared to the previous examination, or leakage on FA. Retinal pigment epithelial detachment (RPED) was not an indication for treatment. Patients were treated in a stepwise pattern. Patients initially treated with monthly (Q4W) ranibizumab or bevacizumab were switched to 2Q8W without monthly loading phase when resistance occurred, escalated to 2Q4W aflibercept when resistant to 2Q8W aflibercept, and finally escalated to double-dose 4Q4W aflibercept when resistant to 2Q4W aflibercept. Resistance was defined as having multiple recurrences (a minimum of two recurrences after the eye was completely dry following a series of at least three monthly injections per treatment cycle) or persistence of IRF or SRF (poor response to monthly 2 mg aflibercept for at least 5 months) as evident on clinical examination and on imaging studies (leakage on FA, or fibrovascular RPED with IRF or SRF on spectral domain OCT). Poor compliance was not considered resistance. Recurrence was diagnosed as new or increased IRF or SRF with or without vision changes or symptoms. Considering the pharmacokinetic changes in vitrectomized eyes, with protein molecules having a shorter half-life in vitrectomized eyes, a dose of monthly 4 mg/0.1 mL aflibercept was applied universally without stepwise dose escalation.

ETDRS charts were used for standardized vision testing to determine visual acuity. Vision was recorded at baseline and at each follow-up visit. For the current study, baseline was defined as the visit initiating the monthly 4 mg/0.1 mL aflibercept injection. The ETDRS letter scores were used for statistical analysis for visual acuity. The intraocular pressure (IOP) was measured with Goldmann applanation tonometry and recorded for every visit. The recorded highest IOP during the follow-up and the IOP at the last visit were compared with the IOP at the baseline visit to assess for a potential effect of high-dose high-frequency aflibercept injections on IOP. Detailed slit-lamp examination and dilated fundus ophthalmoscopy were performed at every visit. Severe postinjection complications, including intraocular inflammation, infection, or systemic arteriothrombotic events such as stroke or myocardial infarction were recorded.

Furthermore, to assess the safety of the high-dose high-frequency injections of aflibercept, the

From the *Jacobs Retina Center, Shiley Eye Institute, University of California San Diego, La Jolla, California; †Beijing Institute of Ophthalmology, Beijing Tongren Hospital, Capital Medical University, Beijing, China; and ‡Department of Ophthalmology, Tanta University, Tanta, Egypt.

Supported in part by UCSD Vision Research Center Core Grant P30EY022589, an unrestricted grant from Research to Prevent Blindness, NY (W.R.F.), ICO-Retina Research Foundation Helmerich Fellowship, Beijing Talents Fund (2015000021223ZK22), and National Natural Science Foundation of China (No. 81400422) (Q.S.Y.).

None of the authors has any financial/conflicting interests to disclose.

The funding organizations had no role in the design or conduct of this research.

This is an open-access article distributed under the terms of the Creative Commons Attribution-Non Commercial-No Derivatives License 4.0 (CCBY-NC-ND), where it is permissible to download and share the work provided it is properly cited. The work cannot be changed in any way or used commercially without permission from the journal.

Reprint requests: William R. Freeman, MD, Jacobs Retina Center, Shiley Eye Institute, University of California San Diego, 9415 Campus Point Drive 0946, La Jolla, CA 92093; e-mail: wrfreeman@ucsd.edu

development of geographic atrophy (GA) was proactively assessed. Geographic atrophy was diagnosed based on dilated fundus examinations, autofluorescence, FA, and OCT images. A macular area of hypoautofluorescence with sharp (well-demarcated) edges on autofluorescence images combined with RPE and choriocapillaris atrophy on OCT images confirmed the clinical diagnosis of GA. The autofluorescence images at baseline and final visits were compared side by side to assess for the development and/or progression of GA.

The detailed methodology for image acquisition has been reported by our group in previous reports.^{7,8} In short, spectral domain OCT, fundus autofluorescence images, and FA were performed in all patients at baseline and at monthly visits in concert with aflibercept injections using the Heidelberg Spectralis (Spectralis HRA-OCT; Heidelberg Engineering, Carlsbad, CA). Horizontal and vertical scans cutting through the fovea were acquired. Raster scans were performed based on the judgment of the retinal fellow who did the imaging to acquire the image in the clinical areas of interest where choroidal neovascularization and leakage were most prominent. A retina specialist masked to clinical information (including visual acuity, treatment history, and treatment dose) evaluated all images. All measurements were performed manually using built-in Heidelberg eye explorer software. On spectral domain OCT, central foveal thickness (CFT) was defined as the distance between internal limiting membrane and Bruch membrane in the central foveola. Maximum foveal thickness (MFT) was defined as the maximum vertical distance between the internal limiting membrane and Bruch membrane within an area of 2,000 μm from the fovea where choroidal neovascularization activity was most prominent and/or corresponding to the fibrovascular RPEd with the greatest amount of IRF or SRF.

The maximum height of RPEd was measured as the distance between the outer border of the RPE and the inner border of Bruch membrane in the area of choroidal neovascularization. For the analysis of fluid, the maximum height of the IRF or SRF was measured.

Statistical analyses were performed using R statistical software (Revolution Analytics, Redmond, WA). Descriptive statistics including mean, SD, median, range, and percentages were presented where appropriate. The Shapiro–Wilk test was used to test normality of the data. The paired Student’s *t*-test was used to compare vision at baseline and follow-up visits. Considering the legal requirement for a driver’s license and the definition of blindness in the United States, eyes were grouped by their baseline visions for subgroup analysis as follows: good vision—visual acuity ≥20/40; moderate vision—visual acuity <20/40 but ≥20/200; and poor vision—visual acuity <20/200. The chi-square test was used to compare the proportion of patients with good vision, moderate vision, and poor vision at baseline and at the final visit. Kaplan–Meier analysis was used for survival analysis. *P* values represent results for 2-sided tests with values less than 0.05 considered statistically significant.

Results

Thirty-three eyes of 28 patients with wet AMD were included in the study with a mean age of 82 years. Twelve patients (36%) were men. The eyes received a mean number of 15 injections of bevacizumab/ranibizumab, 4 injections of 2Q8W aflibercept, and 7 injections of 2Q4W aflibercept before treatment with 4Q4W aflibercept. The mean baseline visual acuity and IOP before starting 4Q4W aflibercept treatment were 55.3 ETDRS letters (Snellen

Table 1. Baseline Characteristics of Patients With Wet AMD Treated With Aflibercept 4 mg Every 4 Weeks

	Nonvitrectomized (n = 17)	Vitrectomized (n = 16)	Combined (n = 33)
Age, years, mean ± SD (range)	81 ± 7 (67–89)	83 ± 7 (66–93)	82 ± 7 (66–93)
Sex (male/female)	6/11	6/10	12/21
Previous bevacizumab, mean ± SD (range)	12 ± 8 (3–29)	18 ± 11 (7–42)	15 ± 10 (3–42)
Previous aflibercept 2Q8W, mean (range)	4 ± 2 (2–8)	4 ± 3 (1–11)	4 ± 2 (1–11)
Previous aflibercept 2Q4W, mean (range)	8 ± 4 (2–13)	6 ± 2 (3–8)	7 ± 3 (2–13)
Baseline vision logMAR/SE, mean ± SD (range)	0.39 ± 0.21 (0.1–0.9)/0.44 ± 0.1 (0.1–0.8)	1.16 ± 0.59 (0.1–2.0)/0.16 ± 0.22 (0.01–0.8)	0.76 ± 0.58 (0.1–2.0)/0.34 ± 0.24 (0.01–0.8)
Baseline IOP, mmHg	14.8 ± 3.6 (8–24)	15.8 ± 8.1 (5–40)	15.2 ± 6.2 (5–40)
No. of eyes with high IOP (≥21 mmHg) or diagnosed as glaucoma at baseline, n (%)	1 (6)	7 (43.8)	8 (24)

logMAR, logarithm of the minimum angle of resolution; SE, Snellen equivalent.

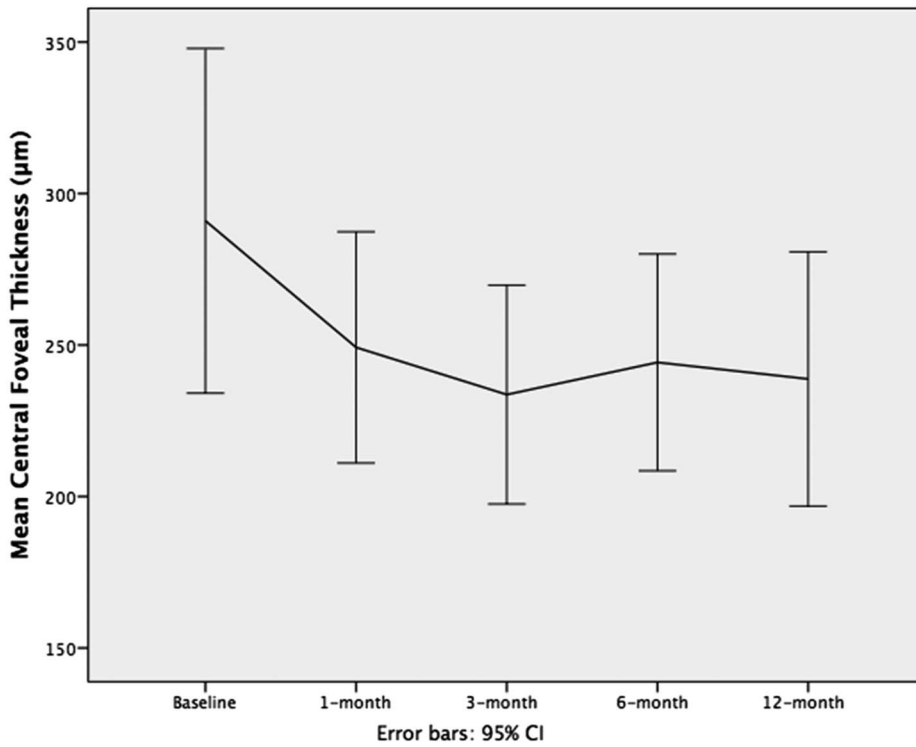


Fig. 1. Central foveal thicknesses before and after initiating aflibercept 4 mg every 4-week treatment. CI, confidence interval.

equivalent, SE 20/80) and 15 mmHg, respectively. Baseline vision was $\leq 20/40$ in 85% of the eyes, and 24% of the eyes had a history of elevated IOP at some point before entry into the study. Sixteen of the 33

eyes underwent vitrectomy before initiating the 4Q4W aflibercept treatment for wet AMD. The baseline characteristics of the study patients are summarized in Table 1.

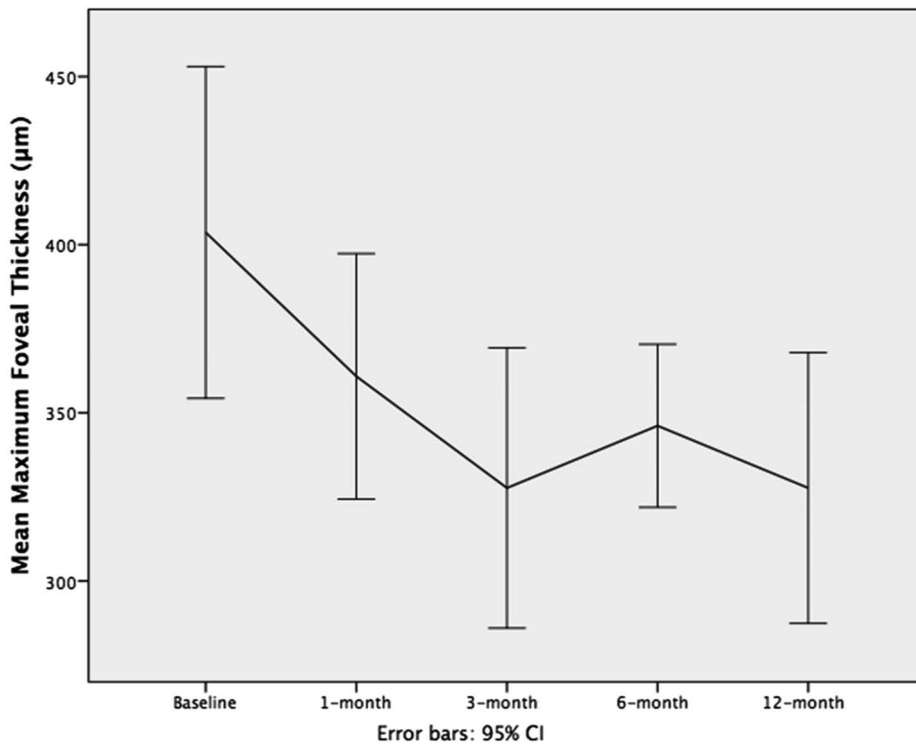


Fig. 2. Maximum foveal thicknesses before and after initiating aflibercept 4 mg every 4 weeks. CI, confidence interval.

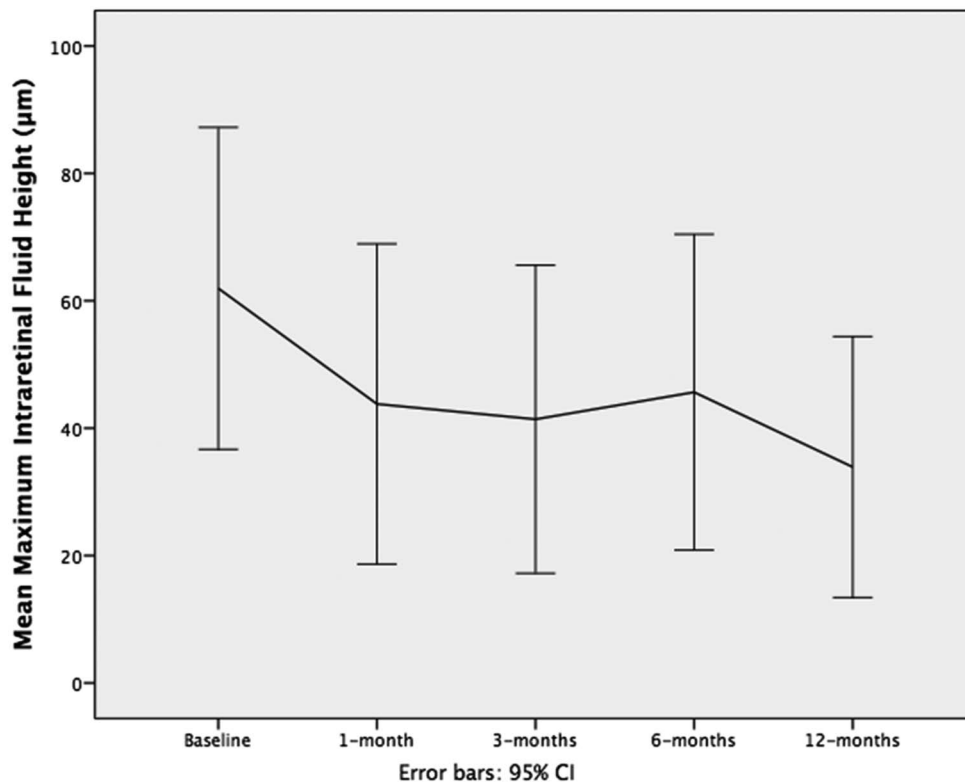


Fig. 3. Maximum IRF height before and after initiating aflibercept 4 mg every 4 weeks. CI, confidence interval.

Patients were followed on average 16 (range 4–37) months after starting 4Q4W aflibercept treatment. The mean number of injections of 4Q4W aflibercept was 7.9 (range 3–26). The mean CFT decreased significantly after initiating 4Q4W aflibercept injections: from 292.4 µm at baseline to 241.9 µm at 1 month ($P = 0.02$), and this therapeutic effect remained significant at 12 months (302.7 µm vs. 251.3 µm, $n = 22$, $P = 0.008$) (Figure 1). Similarly, the MFT decreased significantly from 399.2 µm at baseline to 360.5 µm ($P = 0.01$) at 1 month and 334.7 µm ($P = 0.001$) at 12 months (Figure 2). Both IRF and SRF significantly decreased at 1 month and at 12 months (all $P < 0.05$, Figures 3 and 4). Interestingly, sub-RPE fluid also decreased but responded more slowly than IRF and SRF. The

RPED height decreased from 134.6 µm at baseline to 120.6 µm ($P = 0.11$) at 1 month after injection, 126.3 µm at 3 months ($P = 0.39$), 114.4 µm at 6 months ($P = 0.047$), and 107.3 µm at 12 months ($P = 0.037$) (Figure 5).

The mean time for the retina to become dry after initiating 4Q4W aflibercept treatment was 3.8 months (SD 2.7, range 1–11 months). Figure 6 shows the Kaplan–Meier curve for time to get dry after initiating 4Q4W aflibercept treatment. The proportion of eyes getting completely dry at 1 month, 3 months, 6 months, and 12 months was 33%, 36%, 27%, and 33%, respectively. At the final visit, 39% of eyes were completely dry, and the mean CFT was 260.4 µm, significantly thinner than the baseline visit ($P = 0.05$).

Table 2. Anatomical Parameters and Visual Acuity (VA) at Baseline and at the Last Visit of Wet AMD Eyes Treated With 4 mg Aflibercept Every 4 Weeks

Parameter	Baseline, Mean ± SD	Last Visit, Mean ± SD	<i>P</i>
CFT, µm	292.4 ± 121.9	260.4 ± 126.1	0.05
MFT, µm	399.2 ± 105.4	355.5 ± 115.2	0.02
Retinal pigment detachment height, µm	134.6 ± 70.2	109.8 ± 62.5	0.02
IRF height, µm	69.6 ± 55.8	54.8 ± 61.7	0.18
SRF height, µm	36.7 ± 79.2	7.2 ± 23.3	0.048
VA logMAR (SE)	0.76 ± 0.58 (0.31 ± 0.25)	0.77 ± 0.71 (0.36 ± 0.31)	0.88

logMAR, logarithm of the minimum angle of resolution.

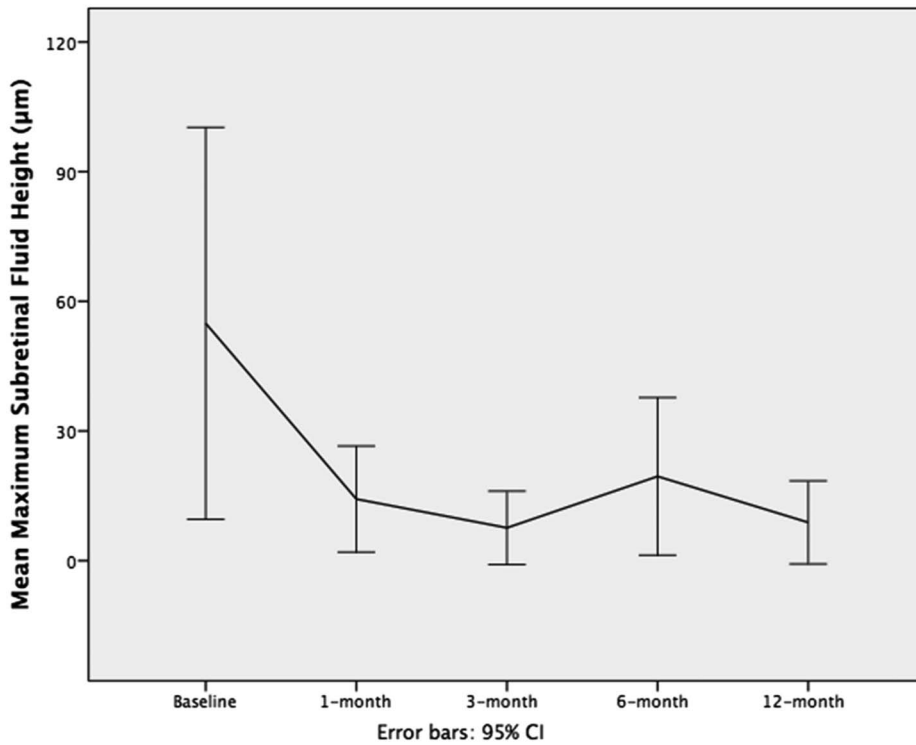


Fig. 4. Maximum SRF height before and after initiating aflibercept 4 mg every 4 weeks. CI, confidence interval.

The mean MFT decreased to 355.5 µm ($P = 0.02$), and RPED height decreased to 109.8 µm ($P = 0.02$). Mean IRF height was 54.8 µm ($P = 0.18$), and the mean SRF height decreased to 7.2 µm ($P = 0.048$) (Table 2).

Although macular morphologic results improved significantly after initiating 4Q4W aflibercept treatment and were maintained until the last visit, mean visual acuity did not show improvement. The mean

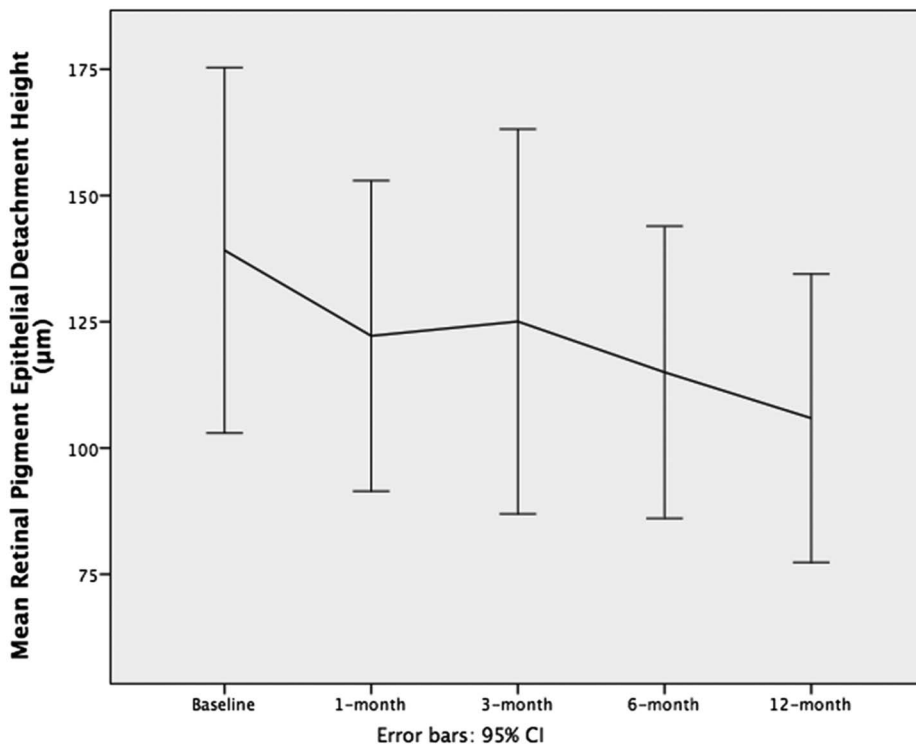


Fig. 5. Retinal pigment epithelial detachment height before and after initiating aflibercept 4 mg every 4 weeks. CI, confidence interval.

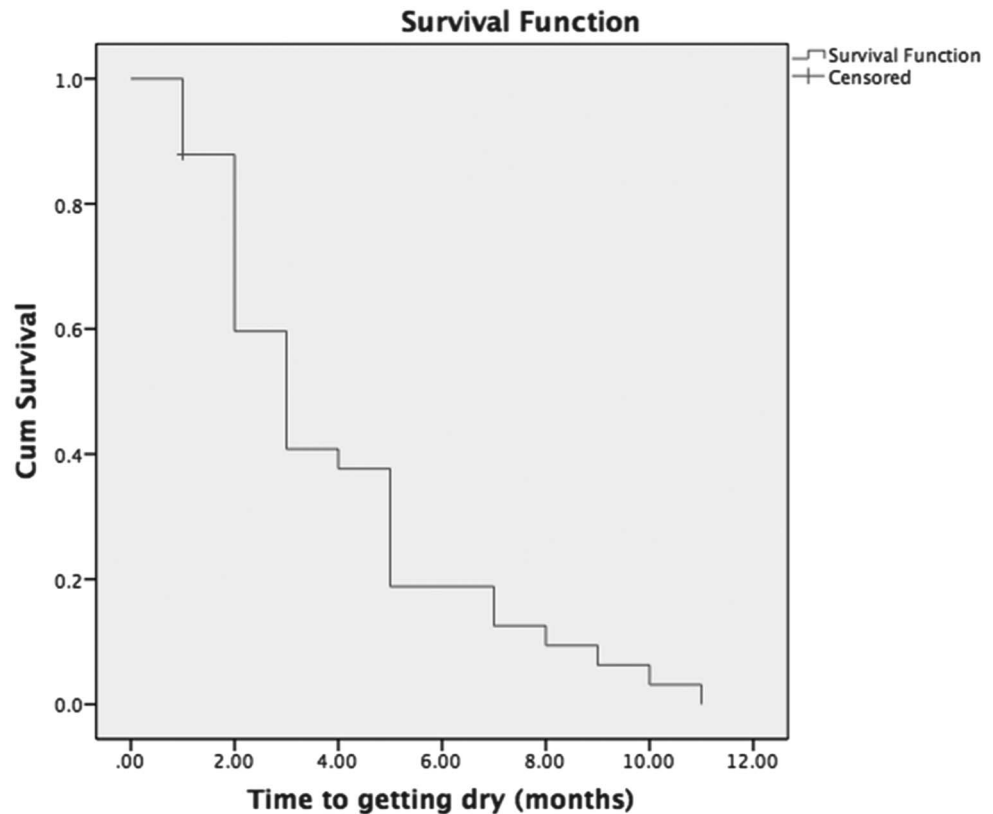


Fig. 6. Kaplan–Meier curve of the survival time to get dry after initiating monthly 4 mg aflibercept intravitreal injections.

visual acuity at baseline and at the final visit was 55.3 ETDRS letters (SE 20/80) and 57.8 ETDRS letters (SE 20/70), respectively. Figure 7 showed the dynamic change of mean vision after initiating the 4Q4W aflibercept treatment. The proportion of eyes with poor vision ($\leq 20/200$), moderate vision ($\leq 20/40$ but $>20/200$), and good vision ($>20/40$) was 30.3%, 54.5%, and 15.2% at baseline and 36.4%, 30.3%, and 33.3% at the last visit, respectively ($P < 0.001$). Fifteen eyes (45%) showed vision improvement of one line or more, and four eyes (12%) improved three or more lines at the last visit.

The mean IOP at baseline, highest IOP during the follow-up period, and mean IOP at the last visit were 15.2, 18.2, and 13.9 mmHg, respectively ($P = 0.28$). There were no cases of new onset elevated IOP (≥ 21 mmHg) or glaucoma that developed after initiating 4Q4W aflibercept treatment. No cases of postinjection intraocular inflammation or endophthalmitis were noted during the follow-up period.

To further address the safety of high-dose high-frequency aflibercept, GA was evaluated. Geographic atrophy was present in 10/33 (30.3%) eyes before initiating the 4Q4W aflibercept treatment. And at the final visit, GA was detected in 13/33 (39.4%) eyes, and newly developed GA occurred in 3 eyes (incidence rate 9.1%) during the mean follow-up of

16 months. In the 10 eyes with GA at baseline, 3 eyes (30%) showed enlargement and 7 eyes (70%) showed no progression of the GA lesion. No RPE tears occurred. No systemic arteriothrombotic events or deaths were recorded during the follow-up period.

A subgroup analysis for nonvitrectomized and vitrectomized eyes was performed. In the nonvitrectomized eyes ($n = 17$), the mean vision at the last visit and the baseline was not significantly different (logarithm of the minimum angle of resolution 0.33 [SE 20/36] vs. logarithm of the minimum angle of resolution 0.39 [SE 20/45], $P = 0.26$). The mean CFT was significantly thinner at 12 months after initiating 4Q4W aflibercept treatment compared with the baseline (220.8 vs. 286.7 μm , $P = 0.03$). The MFT was significantly thinner at 1 month (333.5 vs. 380.6 μm , $P = 0.02$) and 12 months (303.2 vs. 280.6 μm , $P = 0.02$). Subretinal fluid decreased significantly at the last visit (60.9 vs. 6.06, $P = 0.04$).

In nonvitrectomized eyes, only 4 cases were switched to high-dose high-frequency treatment because of multiple recurrences. Because multiple recurrent cases might be different from those who never respond to low-dose high-frequency cases, we performed a subgroup analysis after excluding these four cases. The results are similar, which showed that the eyes treated with high-dose high-frequency

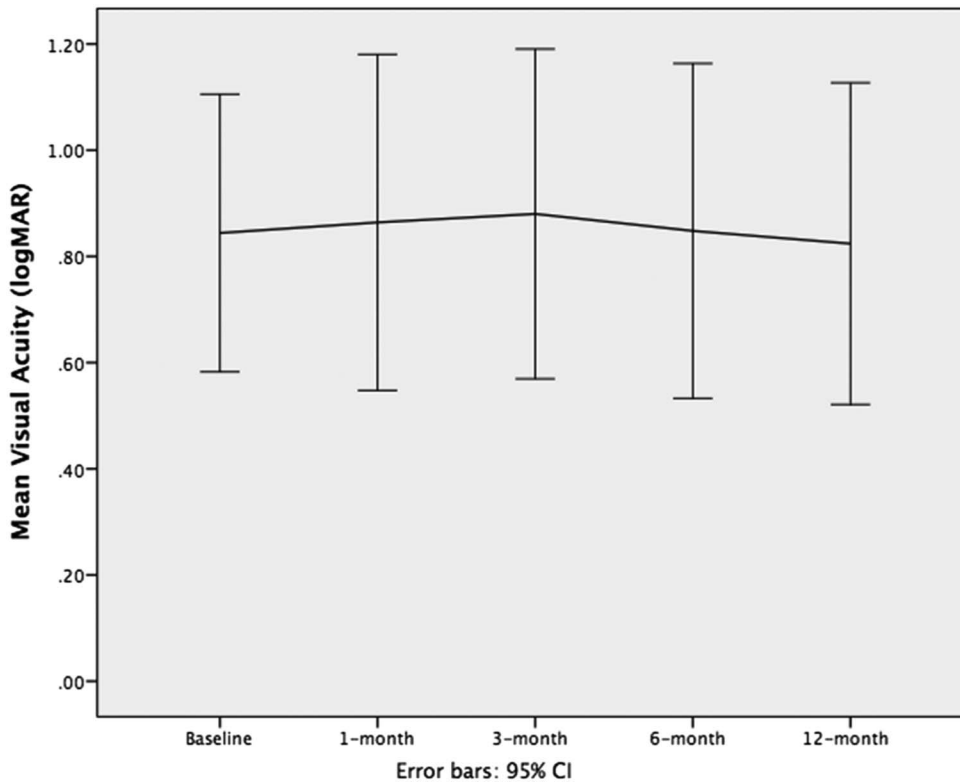


Fig. 7. Mean visual acuity before and after initiating aflibercept 4 mg every 4 weeks. CI, confidence interval; logMAR, logarithm of the minimum angle of resolution.

aflibercept anatomically improved significantly (CFT decreased significantly starting from Month 1 [$P = 0.05$] and maintained until Month 12 [$P = 0.03$]), but the visual acuity remained similar during the whole follow-up period ($P = 0.33$ – 0.69).

In the vitrectomized eyes, mean vision at the last visit and baseline was logarithm of the minimum angle of resolution 1.24 (SE 20/135) and logarithm of the minimum angle of resolution 1.15 (SE 20/125), respectively ($P = 0.47$). The MFT was significantly thinner at 12 months compared with baseline (432.1 vs. 363.5 μm , $P = 0.04$). Intraretinal fluid decreased significantly at 1 month compared with baseline (76.5 vs. 41.7 μm , $P = 0.03$).

Discussion

Our results showed that the 4Q4W aflibercept is effective in treating recalcitrant wet AMD cases. These highly resistant difficult cases did not respond well to multiple monthly ranibizumab or bevacizumab, 2Q8W aflibercept (routine dose and frequency), and 2Q4W aflibercept (routine dose high frequency), but achieved significant anatomical improvement and maintained visual acuity when treated with 4Q4W aflibercept (high dose high frequency). The mean CFT, the MFT, the retinal epithelial detachment height, IRF, and SRF

decreased significantly 1 month after initiating the 4Q4W aflibercept treatment and were maintained until the last visit with a mean follow-up of 16 months. Despite anatomical improvement, mean visual acuity did not show improvement but remained stable. However, 45% of the treated eyes showed vision improvement of 1 line or more, and 12% showed improvement of 3 or more lines at the last visit, suggesting that some patients might benefit from the high-dose high-frequency treatment for anatomical improvement and have improved visual function. No ocular safety issues were identified during the follow-up period.

It is unclear why some patients with wet AMD respond completely to anti-VEGF treatments while others do not. Although some pharmacogenetic studies suggested that certain genotypes might be related to treatment response,^{9–11} other studies such as the CATT study and IVAN trials do not support pharmacogenetic associations between genotypes and response to anti-VEGF therapy in patients with neovascular AMD.^{12,13} Some patients initially respond well to anti-VEGF treatments but become refractory or recurrent with ongoing treatments, probably because of tachyphylaxis or tolerance to VEGF inhibitors.^{14,15} Switching from bevacizumab or ranibizumab to aflibercept has been reported as an effective choice when resistance occurs.^{7,8,16–18} Aflibercept is officially recommended to be injected

every other month after three monthly loading doses.⁶ We previously reported that 60% of eyes with resistant AMD while on Q4W ranibizumab or bevacizumab respond well to 2Q8W aflibercept without needing monthly loading.⁷ Approximately 45% of eyes needed to be escalated from 2Q8W to 2Q4W aflibercept because of persistence of fluid, and some of them still did not respond very well to monthly 2 mg aflibercept.⁸ In these cases, we doubled the dose and initiated the 4Q4W aflibercept regimen. Our results showed that 4Q4W aflibercept is effective in treating the most recalcitrant cases. Significant anatomical improvements were achieved for these recalcitrant eyes on high-dose high-frequency aflibercept injections. Visual improvement was achieved in a significant subgroup of eyes.

There are no systemic or ocular safety issues noted in this cohort of patients treated with high-dose high-frequency aflibercept. Ocular inflammation and increased IOP after intravitreal injection are the most frequently reported serious ocular adverse events in the literature.¹⁹ No cases of intraocular inflammation or increased IOP were noted in the group of patients treated with 4Q4W aflibercept treatment. The high prevalence (24%) of high IOP (>21 mmHg) or glaucoma at baseline in the current case series might be related to the history of triamcinolone use in previous vitrectomy surgeries in vitrectomized eyes. No new high IOP or glaucoma cases developed after initiating 4Q4W aflibercept treatment, and IOPs in all the eyes were controlled at less than 21 mmHg at the last visit. Geographic atrophy development has been a concern in anti-VEGF therapy for patients with wet AMD.^{20,21} The prevalence of GA at baseline (at the visit initiating 4Q4W aflibercept treatment) in the current cohort was 30.3%, markedly higher than the CATT (82/1185, 6.9%) study cohort,²¹ which is understandable, because our patients were chronic AMD patients with a long history of anti-VEGF treatments, whereas CATT study patients were treatment-naïve newly onset patients with wet AMD. However, the incidence of GA development during the 16-month follow-up in the current study was 9.1%, lower than the 12-month incidence (10.6%) and 24-month incidence (18.3%) of GA development in the CATT study,²¹ suggesting that the high-dose high-frequency aflibercept may not lead to extra GA development compared with standardized anti-VEGF therapy. Retinal pigment epithelium tears, another reported complication associated with anti-VEGF injections,^{22,23} were not noted in this cohort. No systemic arteriothrombotic events or deaths were recorded during the follow-up period.

The relatively small sample size of 33 eyes limits the ability of the study to detect potentially rare but severe associated complications of anti-VEGF therapy

such as systemic arteriothrombotic events or RPE tears. However, considering that the study is addressing the relative rare highly resistant wet AMD cases, a group of 33 recalcitrant eyes is a reasonable size. Lack of a control group does not permit definitive conclusions that this high-dose high-frequency injection of aflibercept will not increase the risk of GA. Although the 16-month incidence of GA in the current study is lower than the 12-month incidence of GA in the large sample randomized CATT study,²¹ further study with a larger sample size and a control group is warranted to determine the effect of this double-dose double-frequency treatment regimen on GA development. Using this systematic dose escalation algorithm with aflibercept in patients with recalcitrant wet AMD can improve vision in some patients and provide better anatomical outcomes.

Key words: age-related macular degeneration, vascular endothelial growth factor, pro re nata, optical coherence tomography, aflibercept.

References

1. Lim LS, Mitchell P, Seddon JM, et al. Age-related macular degeneration. *Lancet* 2012;379:1728–1738.
2. Bourne RR, Jonas JB, Flaxman SR, et al. Prevalence and causes of vision loss in high-income countries and in Eastern and Central Europe: 1990–2010. *Br J Ophthalmol* 2014;98:629–638.
3. Brown DM, Kaiser PK, Michels M, et al. Ranibizumab versus verteporfin for neovascular age-related macular degeneration. *N Engl J Med* 2006;355:1432–1444.
4. Rosenfeld PJ, Brown DM, Heier JS, et al. Ranibizumab for neovascular age-related macular degeneration. *N Engl J Med* 2006;355:1419–1431.
5. CATT Research Group, Martin DF, Maguire MG, et al. Ranibizumab and bevacizumab for neovascular age-related macular degeneration. *N Engl J Med* 2011;364:1897–1908.
6. Heier JS, Brown DM, Chong V, et al. Intravitreal aflibercept (VEGF trap-eye) in wet age-related macular degeneration. *Ophthalmology* 2012;119:2537–2548.
7. Arcinue CA, Ma F, Barteselli G, et al. One-year outcomes of aflibercept in recurrent or persistent neovascular age-related macular degeneration. *Am J Ophthalmol* 2015;159:426–436.
8. Muftuoglu IK, Arcinue CA, Tsai FF, et al. Long-term results of pro re nata regimen of aflibercept treatment in persistent neovascular age-related macular degeneration. *Am J Ophthalmol* 2016;167:1–9.
9. Smailhodzic D, Muether PS, Chen J, et al. Cumulative effect of risk alleles in CFH, ARMS2, and VEGFA on the response to ranibizumab treatment in age-related macular degeneration. *Ophthalmology* 2012;119:2304–2311.
10. Zhao L, Grob S, Avery R, et al. Common variant in VEGFA and response to anti-VEGF therapy for neovascular age-related macular degeneration. *Curr Mol Med* 2013;13:929–934.
11. Hautamäki A, Kivioja J, Vavuli S, et al. Interleukin 8 promoter polymorphism predicts the initial response to bevacizumab treatment for exudative age-related macular degeneration. *Retina* 2013;33:1815–1827.

12. Hagstrom SA, Ying GS, Pauer GJ, et al; Comparison of AMD Treatments Trials Research Group. Pharmacogenetics for genes associated with age-related macular degeneration in the Comparison of AMD Treatments Trials (CATT). *Ophthalmology* 2013;120:593–599.
13. Hagstrom SA, Ying GS, Maguire MG, et al; CATT Research Group; IVAN Study Investigators. VEGFR2 gene polymorphisms and response to anti-vascular endothelial growth factor therapy in age-related macular degeneration. *Ophthalmology* 2015;122:1563–1568.
14. Binder S. Loss of reactivity in intravitreal anti-VEGF therapy: tachyphylaxis or tolerance? *Br J Ophthalmol* 2012;96:1–2.
15. Schachat AP. Switching anti-vascular endothelial growth factor therapy for neovascular age-related macular degeneration. *Am J Ophthalmol* 2013;156:1–2.
16. Bakall B, Folk JC, Boldt HC, et al. Aflibercept therapy for exudative age-related macular degeneration resistant to bevacizumab and ranibizumab. *Am J Ophthalmol* 2013;156:15–22.
17. Yonekawa Y, Andreoli C, Miller JB, et al. Conversion to aflibercept for chronic refractory or recurrent neovascular age-related macular degeneration. *Am J Ophthalmol* 2013;156:29–35.
18. Ho VY, Yeh S, Olsen TW, et al. Short-term outcomes of aflibercept for neovascular age-related macular degeneration in eyes previously treated with other vascular endothelial growth factor inhibitors. *Am J Ophthalmol* 2013;156:23–28.
19. Solomon SD, Lindsley KB, Krzystolik MG, et al. Intravitreal bevacizumab versus ranibizumab for treatment of neovascular age-related macular degeneration: findings from a cochrane systematic review. *Ophthalmology* 2016;123:70–77.
20. Rosenfeld PJ, Shapiro H, Tuomi L, et al; MARINA and ANCHOR Study Groups. Characteristics of patients losing vision after 2 years of monthly dosing in the phase III ranibizumab clinical trials. *Ophthalmology* 2011;118:523–530.
21. Grunwald JE, Daniel E, Huang J, et al; CATT Research Group. Risk of geographic atrophy in the comparison of age-related macular degeneration treatments trials. *Ophthalmology* 2014;121:150–161.
22. Bakri SJ, Kitzmann AS. Retinal pigment epithelial tear after intravitreal ranibizumab. *Am J Ophthalmol* 2007;143:505–507.
23. Durkin SR, Farmer LD, Kulasekara S, Gilhotra J. Change in vision after retinal pigment epithelium tear following the use of anti-VEGF therapy for age-related macular degeneration. *Graefes Arch Clin Exp Ophthalmol* 2016;254:1–6.