

## Raising the bar for appropriateness in the care of patients with peripheral artery disease

Cassius Iyad Ochoa Chaar, MD, MS,<sup>a</sup> Arash Fereydooni, MS,<sup>b</sup> Peter F. Lawrence, MD,<sup>c</sup> and Alan Dardik, MD, PhD,<sup>a</sup> *New Haven, Conn; and Los Angeles, Calif*

### ABSTRACT

Advances in endovascular therapy have exponentially increased the number of procedures performed for peripheral artery disease, but public concerns of overuse have placed the vascular community under scrutiny. The appropriateness of care has thus become a focus of discussion within several professional societies, but literature on the topic is limited. This report presents two cases of patients with peripheral artery disease, one patient who did not need revascularization and underwent an intervention and the other who required additional intervention that was not recognized owing to an incomplete diagnostic workup. (*J Vasc Surg Cases and Innovative Techniques* 2019;5:345-9.)

**Keywords:** Appropriateness of care; Peripheral arterial disease; National guidelines

In the past decade, the prevalence of peripheral arterial disease (PAD) has increase by more than 10% and its incidence is expected to continue to increase.<sup>1</sup> Endovascular therapy has evolved as the preferred modality for lower extremity revascularization, especially in the elderly, because it is better tolerated than open surgery.<sup>2,3</sup> However, the advances in technology has opened the field to specialists with endovascular skills, who have little formal training in the appropriate care of patients with PAD. Notably, the vascular community came under public scrutiny after *The New York Times* reported the abuse of PAD stenting in Medicare patients.<sup>4</sup> The leadership of the Society for Vascular Surgery responded publicly and formed a committee to develop “appropriateness guidelines” for common vascular procedures to offer “the right treatment for the right patient.”<sup>5,6</sup> Unfortunately, inappropriate care of patients with PAD still seems ubiquitous, with variable scrutiny from governing bodies. Given the paucity of literature on this topic, we

present two cases that emphasize the importance of vigilance and scrupulousness in PAD management to highlight opportunities for improvement.

Both patients consented to the publication of this report.

### CASE REPORTS

**Patient 1.** A 57-year-old man with a history of smoking, hypertension, hyperlipidemia, depression, PAD, and left foot rest pain was treated with left femoral endarterectomy and kissing iliac stents 3 years prior, with complete resolution of rest pain. The patient complained on follow-up of right knee pain limiting his ambulation to 10 to 15 steps. The ankle-brachial indices (ABI) were 0.94 and 0.76 on the left and right, respectively. No intervention was offered because his history was not consistent with vascular claudication; the patient was counseled on smoking cessation, asked to continue antiplatelet and statin therapy, and sent to see the orthopedic surgeons for evaluation.

He subsequently sought a second opinion from a different provider, who performed angiography demonstrating moderate right superficial femoral artery (SFA) disease with a focal occlusion. The right SFA was recanalized with drug-coated balloon angioplasty. On follow-up, duplex ultrasound examination demonstrated a patent SFA. His symptoms did not improve, and he returned frustrated to our service. He was again counseled on smoking cessation and referred to orthopedic surgery.

**Patient 2.** An 84-year-old woman with end-stage renal disease on hemodialysis, with hypertension, heart failure, atrial fibrillation, diabetes, and hyperlipidemia, presented with right foot rest pain and nonhealing small ulcers of the right heel and great toe. She was diagnosed with PAD based on duplex ultrasound examination demonstrating occlusion of the right SFA and 50% to 75% stenosis in the left SFA.

She underwent angiography showing bilateral common iliac artery stenosis. The right SFA was occluded and there was

---

From the Section of Vascular Surgery, Department of Surgery, Yale University School of Medicine,<sup>a</sup> and the Yale University School of Medicine,<sup>b</sup> New Haven; and the Section of Vascular Surgery, Department of Surgery, University of California, Los Angeles.<sup>c</sup>

Author conflict of interest: none.

Presented at the Forth-seventh Annual Symposium of Society for Clinical Vascular Surgery, Boca Raton, Fla, March 16-20, 2019.

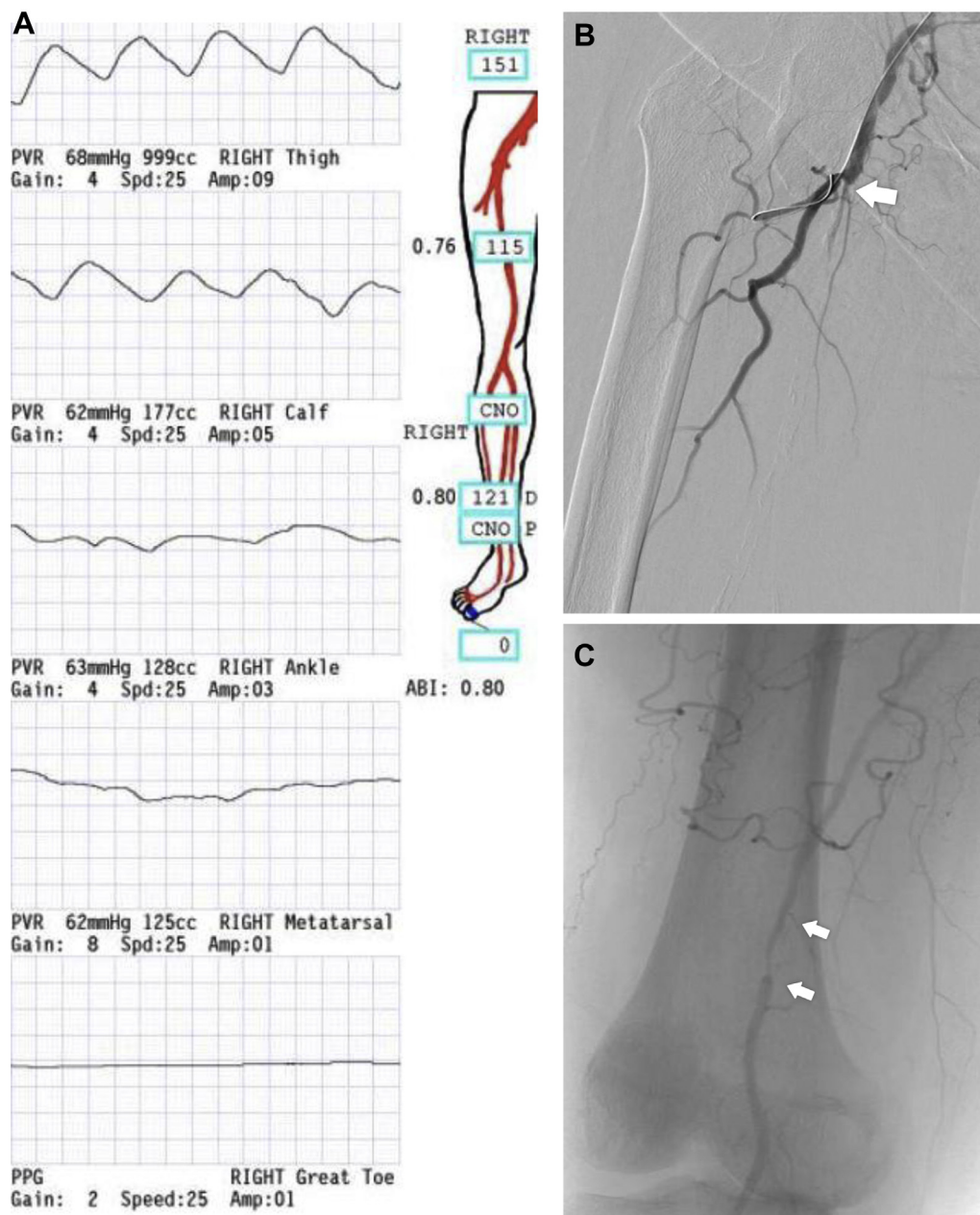
Correspondence: Cassius Iyad Ochoa Chaar, MD, MS, Associate Professor of Surgery, Division of Vascular Surgery, Department of Surgery, Yale University School of Medicine, 333 Cedar St, Boardman 204, PO Box 208062, New Haven, CT 06520-8039 (e-mail: [cassius.chaar@yale.edu](mailto:cassius.chaar@yale.edu)).

The editors and reviewers of this article have no relevant financial relationships to disclose per the Journal policy that requires reviewers to decline review of any manuscript for which they may have a conflict of interest.

2468-4287

© 2019 The Author(s). Published by Elsevier Inc. on behalf of Society for Vascular Surgery. This is an open access article under the CC BY-NC-ND license (<http://creativecommons.org/licenses/by-nc-nd/4.0/>).

<https://doi.org/10.1016/j.jvscit.2019.03.009>



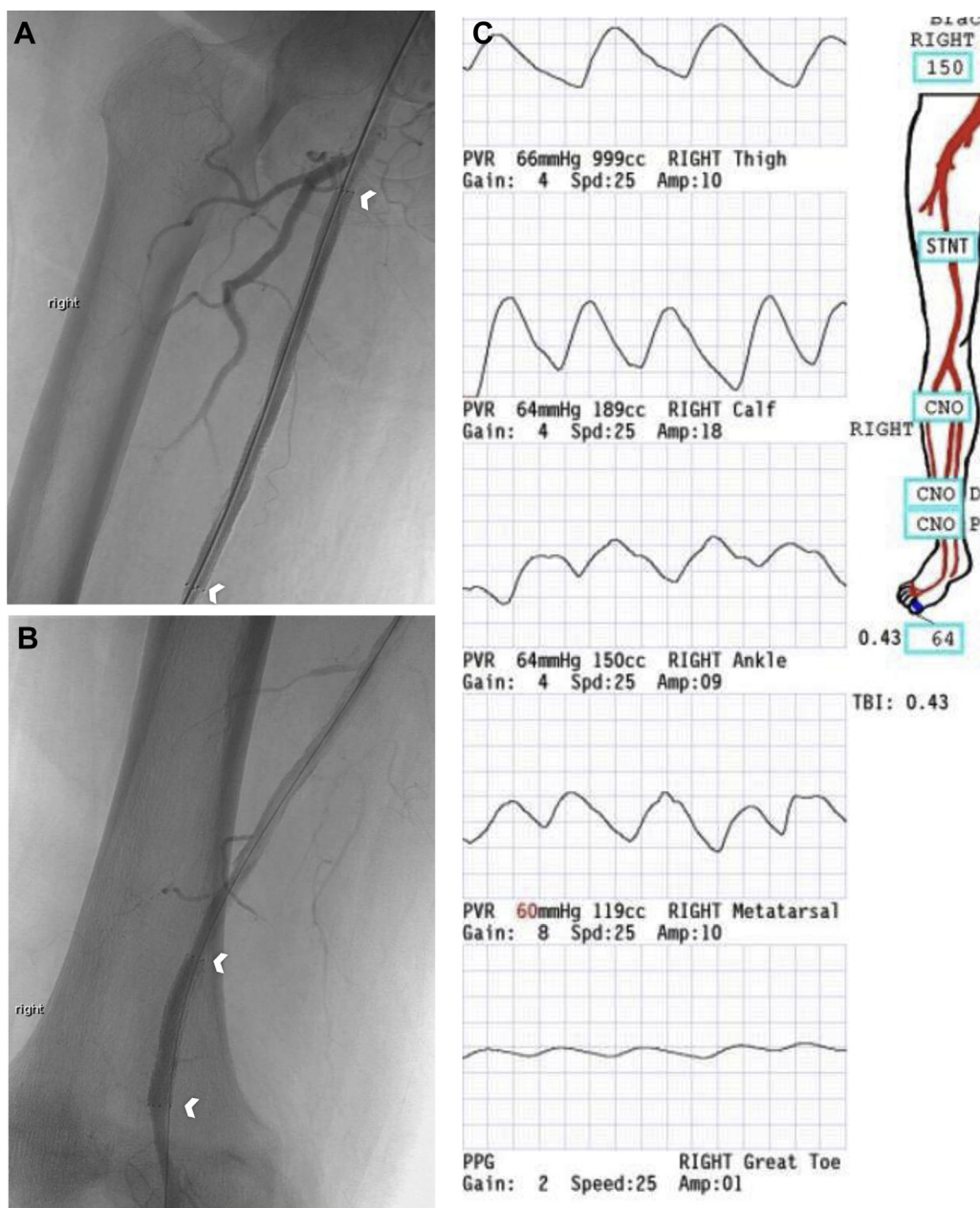
**Fig 1. A,** Preoperative ankle-brachial index (ABI) demonstrating a TP of 0 mm Hg on the right. Lower extremity angiography performed via a left brachial approach showing **(B)** an occluded right superficial femoral artery (SFA) **(C)** and a focal severe stenosis of the above-knee popliteal artery.

reconstitution of the popliteal artery and two-vessel run-off bilaterally. Bilateral kissing iliac stents were placed. After 1 month, she continued to have stable ulcers and persistent foot pain. A repeat angiogram was reported as “adequate tibial run-off” despite occlusion of the right SFA, and her leg pain was attributed to a longitudinal superficial ulcer.

The patient then sought second opinion from our vascular surgery practice. An ABI was obtained for the first time in her care and showed a right toe pressure of 0 mm Hg (Fig 1, A). Computed tomography angiography demonstrated adequate inflow and patent iliac stents with no evidence of significant

inflow disease. The right SFA had a long segment occlusion with reconstitution of a diseased proximal popliteal artery.

After a discussion of open and endovascular options, the patient agreed to proceed with endovascular revascularization and absolutely refused open surgery. Via left brachial access, angiography was performed and demonstrated total occlusion of the right SFA (Fig 1, B) and a 60% stenosis of the popliteal artery (Fig 1, C). Despite extensive calcification and remote access, subintimal angioplasty with stenting of the SFA (Fig 2, A) and proximal popliteal artery (Fig 2, B) was performed successfully. On follow-up, rest pain resolved and the ulcers healed.



**Fig 2.** Completion angiography showing (A) patent right superficial femoral artery (SFA) (B) and above the knee popliteal artery after stenting. C, Postoperative ankle-brachial index (ABI) demonstrating TP of 64 mm Hg on the right.

The right toe pressure was 64 mm Hg (Fig 2, C). A small brachial artery pseudoaneurysm was noted, which was managed conservatively and thrombosed spontaneously. She has had no recurrence of symptoms at 8 months of follow-up.

## DISCUSSION

This reports presents two patients with PAD: one patient who did not need an intervention and underwent revascularization and the other who required additional intervention that was not offered. When caring for patients with PAD, physicians should recognize that a

failure to appropriately evaluate the patient might result in unnecessary interventions and risks to the patient. The ability to offer minimally invasive interventions should not justify performing procedures with no benefit to patients. It is crucial to recognize that nonarterial etiologies represent a majority of patients being evaluated for claudication,<sup>7,8</sup> including spinal stenosis, arthritis, and other conditions.<sup>9</sup> Physiological testing with ABI is the recommended test to establish the diagnosis and to monitor response to treatment for patients with PAD.<sup>10,11</sup> However, as evidenced in the care of patient 1,

the presence of PAD is not synonymous to having vascular claudication and does not exclude the possibility of nonvascular etiologies for leg pain.<sup>12</sup> Careful correlation of symptoms with clinical evaluation is necessary, and sometimes additional imaging or evaluation by musculoskeletal experts may be indicated. Correlating abnormal findings on imaging with symptoms is challenging and requires good clinical judgment. Such a judicious approach is not unique to PAD, but is also necessary in a variety of vascular conditions, such as iliac vein compression, median arcuate ligament syndrome, and renal artery stenosis before offering intervention.

Poor runoff is an independent predictor for adverse outcome after percutaneous intervention on the iliac arteries.<sup>13-15</sup> Moreover, iliac occlusive disease is a common contributing factor to critical limb ischemia (CLI) and rarely exists as an isolated lesion. Therefore, noninvasive evaluations are essential to reliably assess pedal perfusion.<sup>16</sup> Unfortunately, patient 2 did not receive the appropriate noninvasive imaging and only arterial duplex ultrasound examination and angiography were used to define the anatomic lesions. Angiography alone provides an inconsistent correlation between the functional effects and morphology of the arterial disease, and it is more useful when combined with noninvasive hemodynamic tests.<sup>17</sup> Nonetheless, the ABI has been shown to underestimate the presence of medial calcification<sup>18</sup> and toe pressure is more sensitive to diagnose CLI.<sup>19,20</sup> Toe vessels are less susceptible to calcification, and toe pressures are particularly useful in patients with diabetes, chronic kidney disease, or advanced age, such as patient 2.

Appropriateness criteria have become increasingly important in the United States, with cardiology and radiology leading the way to introduce appropriateness guidelines. The "Appropriate Use Criteria for Coronary Revascularization"<sup>21</sup> and the "American College of Radiology Appropriateness Criteria for Vascular Claudication"<sup>12</sup> are examples of guidelines that have shaped practice and improved patient care. In fact, the introduction of percutaneous coronary intervention (PCI) guidelines in 2009 lead to a significant decrease from 26.2% to 13.3% in interventions classified as inappropriate over the subsequent 5-year period.<sup>22</sup> The introduction of the PCI guidelines were accompanied by other simultaneous initiatives to ensure their integration into clinical practice. The National Cardiovascular Data Registry began providing hospitals information about their performance on appropriateness, which were benchmarked against other hospitals; insurers incorporated measures of PCI appropriateness into pay-for-performance programs and some payers declined reimbursement for certain PCIs deemed inappropriate.<sup>22</sup>

In 2007, the Trans-Atlantic Inter-Society Consensus Document (TASC) II was published in collaboration with the major specialties across the trans-Atlantic

region and provided anatomical based treatment recommendations.<sup>23</sup> In 2011, the TASC group embarked on drafting a new version to be called TASC III. However, there were concerns for a lack of scientific evidence or expert opinion and the fact that certain parties within the TASC group had strong ties to the industry. Consequently, the Society for Vascular Surgery, European Society for Vascular Surgery, and the World Federation of Vascular Societies withdrew from the TASC III process, but still recognized the need to define and promote the highest international standards for vascular care.<sup>24</sup> They have recently generated and published internationally agreed standards and Global Vascular Guidelines, which are evidence based, free from industry influence, and patient centered.<sup>25</sup> Consistent with the 2016 American Heart Association guidelines,<sup>10</sup> the Global Vascular Guidelines recommend all patients presenting with CLI have a full history and physical examination and noninvasive hemodynamic testing with ABIs. To enhance patient care, it is essential that all vascular specialty societies work closely together to address the variation in the practice guidelines and care of common vascular diseases in different specialties. Particularly the members of all vascular specialty societies, clinicians who are directly involved in the management of PAD, referring providers and researchers should be invited to review and comment on the draft of Global Vascular Guidelines and subsequent appropriateness criteria.

## CONCLUSIONS

Vascular surgeons have traditionally cared for patients with PAD and should lead international efforts to establish appropriateness guidelines to delineate the thresholds where variation in care exists. Appropriateness criteria would improve patient care, optimize resource use, and help to guide physicians in the management of patients with PAD.

## REFERENCES

1. Criqui MH, Aboyans V. Epidemiology of peripheral artery disease. *Circ Res* 2015;116:1509-26.
2. Brosi P, Dick F, Do DD, Schmidli J, Baumgartner I, Diehm N. Revascularization for chronic critical lower limb ischemia in octogenarians is worthwhile. *J Vasc Surg* 2007;46:1198-207.
3. Arvela E, Venermo M, Söderström M, Korhonen M, Halmesmäki K, Albäck A, et al. Infrainguinal percutaneous transluminal angioplasty or bypass surgery in patients aged 80 years and older with critical leg ischaemia. *Br J Surg* 2011;98:518-26.
4. Abelson Creswell J. R. Medicare payment surge for stents to unblock blood vessels in limbs. *New York Times*; 2015. Available at: <https://www.mdedge.com/vascularspecialistonline/article/97668/letters-editor>. Accessed August 3, 2018.
5. Vascular Community. Letters to the editor. *Vascular Specialist* [serial on the Internet]. 2015. Available at: <https://www.mdedge.com/vascularspecialistonline/article/97668/letters-editor>. Accessed August 3, 2018.
6. Lawrence PF. "Better" (sometimes) in vascular disease management. *J Vasc Surg* 2016;63:260-9.

7. Cafagna D, Ponte E. Non-vascular claudication or "painful leg syndrome". *Minerva Cardioangiol* 1996;44:229-35.
8. Conte MS, Pomposelli FB, Clair DG, Geraghty PJ, McKinsey JF, Mills JL, et al. Society for Vascular Surgery practice guidelines for atherosclerotic occlusive disease of the lower extremities: management of asymptomatic disease and claudication. *J Vasc Surg* 2015;61(Suppl):2S-41S.e1.
9. Goodreau JJ, Creasy JK, Flanigan DP, Burnham SJ, Kudrna JC, Schafer MF, et al. Rational approach to the differentiation of vascular and neurogenic claudication. *Surgery* 1978;84:749-57.
10. Gerhard-Herman MD, Gornik HL, Barrett C, Barsnes NR, Corriere MA, Drachman DE, et al. 2016 AHA/ACC guideline on the management of patients with lower extremity peripheral artery disease: executive summary: a report of the American College of Cardiology/American Heart Association Task Force on Clinical Practice Guidelines. *Circulation* 2017;135:e686-725.
11. Stoner MC, Calligaro KD, Chaar RA, Dietzek AM, Farber A, Guzman RJ, et al. Reporting standards of the Society for Vascular Surgery for endovascular treatment of chronic lower extremity peripheral artery disease. *J Vasc Surg* 2016;64:e1-21.
12. Ahmed O, Hanley M, Bennett SJ, Chandra A, Desjardins B, Gage KL, et al. ACR Appropriateness criteria, vascular claudication—assessment for revascularization. *J Am Coll Radiol* 2017;14(Suppl):S372-9.
13. Kudo T, Rigberg DA, Reil TD, Chandra FA, Ahn SS. The influence of the ipsilateral superficial femoral artery on iliac angioplasty. *Ann Vasc Surg* 2006;20:502-11.
14. Kudo T, Chandra FA, Ahn SS. Long-term outcomes and predictors of iliac angioplasty with selective stenting. *J Vasc Surg* 2005;42:466-75.
15. Timaran CH, Prault TL, Stevens SL, Freeman MB, Goldman MH. Iliac artery stenting versus surgical reconstruction for TASC (TransAtlantic Inter-Society Consensus) type B and type C iliac lesions. *J Vasc Surg* 2003;38:272-8.
16. Copelan AZ, Kapoor BS, AbuRahma AF, Cain TR, Caplin DM, Farsad K, et al. ACR appropriateness criteria for iliac artery occlusive disease. *J Am Coll Radiol* 2017;14(Suppl):S530-9.
17. Thiele BL, Strandness DE Jr. Accuracy of angiographic quantification of peripheral atherosclerosis. *Prog Cardiovasc Dis* 1983;26:223-36.
18. Ix JH, Miller RG, Criqui MH, Orchard TJ. Test characteristics of the ankle-brachial index and ankle-brachial difference for medial arterial calcification on x-ray in type 1 diabetes. *J Vasc Surg* 2012;56:721-7.
19. Dachun X, Jue L, Liling Z, Yawei X, Dayi H, Pagoto SL, et al. Sensitivity and specificity of the ankle-brachial index to diagnose peripheral artery disease: a structured review. *Vasc Med* 2010;15:361-9.
20. Aboyans V, Ho E, Denenberg JO, Ho LA, Natarajan L, Criqui MH. The association between elevated ankle systolic pressures and peripheral occlusive arterial disease in diabetic and nondiabetic subjects. *J Vasc Surg* 2008;48:1197-203.
21. Patel MR, Dehmer GJ, Hirshfeld JW, Smith PK, Spertus JA. ACCF/SCAI/STS/AATS/AHA/ASNC 2009 appropriateness criteria for coronary revascularization: a report by the American College of Cardiology Foundation Appropriateness Criteria Task Force, Society for Cardiovascular Angiography and Interventions, Society of Thoracic Surgeons, American Association for Thoracic Surgery, American Heart Association, and the American Society of Nuclear Cardiology Endorsed by the American Society of Echocardiography, the Heart Failure Society of America, and the Society of Cardiovascular Computed Tomography. *J Am Coll Cardiol* 2009;53:530-53.
22. Desai NR, Bradley SM, Parzynski CS, Nallamothu BK, Chan PS, Spertus JA, et al. Appropriate use criteria for coronary revascularization and trends in utilization, patient selection, and appropriateness of percutaneous coronary intervention. *JAMA* 2015;314:2045-53.
23. Norgren L, Hiatt WR, Dormandy JA, Nehler MR, Harris KA, Fowkes FGR. Inter-Society Consensus for the Management of Peripheral Arterial Disease (TASC II). *J Vasc Surg* 2007;45: S5-67.
24. Ricco JB, Parvin S, Veller M, Brunkwall J, Wolfe J, Sillesen H, et al. Statement from the European Society of Vascular Surgery and the World Federation of Vascular Surgery Societies: Transatlantic Inter-Society Consensus Document (TASC) III and International Standards for Vascular Care (ISVaC). *Eur J Vasc Endovasc Surg* 2014;47:118.
25. Conte MS, Kolh P, White JV, et al; the GVG Writing Group. Global vascular guideline on the management of chronic limb threatening ischemia. *J Vasc Surg* 2019;69(Suppl): S33-125.

Submitted Jan 9, 2019; accepted Mar 14, 2019.