

# The Accessory Medial Portal for Anterior Cruciate Ligament Reconstruction

## A Safe Zone to Avoid Neurovascular Complications

Kevin D. Plancher,<sup>\*†‡</sup> MD, MPH, Jeffrey T. Alwine,<sup>§</sup> DO, Jimmy J. Chan,<sup>§</sup> MD, and Stephanie C. Petterson,<sup>§</sup> MPT, PhD

*Investigation performed at the Orthopaedic Foundation, Stamford, Connecticut, USA*

**Background:** The accessory medial portal (AMP) used for anatomic anterior cruciate ligament reconstruction (ACLR) is gaining popularity. This portal is routinely created at 60° of knee flexion, placing the infrapatellar branch of the saphenous nerve (IBSN) and, less commonly, the descending and superior medial genicular arteries at risk.

**Purpose/Hypothesis:** The purpose of this study was to identify a safe zone for AMP placement in ACLR to minimize the risk of injury to the IBSN. We hypothesized that increased knee flexion angles would decrease the risk to neurovascular structures when creating an AMP.

**Study Design:** Descriptive laboratory study.

**Methods:** A total of 20 cadaveric (10 matched pairs) knees were used for dissection to identify the IBSN and other neurovascular structures. A 30° arthroscope was used to make the central medial portal and AMP at 3 knee flexion angles (60°, 90°, and 110°). Distances were measured from the AMP to branches of the IBSN. Safety of AMP placement was analyzed by assessing the frequency at which spinal needles pierced a neurovascular structure or violated a safe zone.

**Results:** The superior IBSN was significantly closer to the AMP than inferior IBSN. The AMP was significantly farther from the superior IBSN at 110° (8.56 ± 5.28 mm) compared with 60° (5.63 ± 5.00 mm;  $P = .015$ ) and 90° (6.69 ± 5.03 mm;  $P = .006$ ). A triangular safe zone was identified at 110° of knee flexion. No neurovascular structures were pierced, and the IBSN was not present in the safe zone. At 90°, the IBSN was not pierced; however, the IBSN did violate the safe zone at 90° of knee flexion.

**Conclusion:** The superior IBSN is at risk for iatrogenic injury with an AMP placed at 60° of knee flexion. The nerve moved distally with knee flexion. While no neurovascular structures were compromised at 90° of knee flexion, the nerve was found to course through the safe zone. A safe zone at 110° of knee flexion decreases the risk of neurovascular injury and makes the AMP safe for ACLR.

**Clinical Relevance:** The AMP at 60° of knee flexion for ACLR poses risk to the IBSN. The IBSN did violate the safe zone at 90° of flexion. We recommend creating an AMP with increased knee flexion to 110° to decrease the risk of iatrogenic injury. When establishing an AMP, one should aim for the center of the defined safe zone, given that the spinal needle used in this study has a smaller diameter than a stab incision.

**Keywords:** accessory medial portal; infrapatellar branch of the saphenous nerve; ACL reconstruction; superior medial genicular artery

Anatomic anterior cruciate ligament reconstruction (ACLR) through a 3-portal technique has been previously described by Cohen and Fu.<sup>6</sup> The technique utilizes an accessory medial portal (AMP) to drill the femoral tunnel while viewing through a central medial portal (CMP).<sup>6</sup> The AMP enables surgeons to reach the native insertion site of the ACL. This technique is increasingly utilized because it

gives the surgeon an advantage to create a more anatomic femoral tunnel or tunnels for single- or double-bundle ACLR.<sup>1,2,3,4,6,9</sup> While Cohen and Fu originally described the AMP to be 2 cm medial to the medial edge of the patellar tendon in a horizontal plane immediately above the meniscus to improve visualization, it may also reduce injury to the infrapatellar branch of the saphenous nerve (IBSN).

The IBSN is a sensory branch of the saphenous nerve that has a variable pattern over the anteromedial portion of the knee.<sup>10,11</sup> Two distinct branches of the IBSN, the superior branch and the inferior branch, were described

The Orthopaedic Journal of Sports Medicine, 8(9), 2325967120952674  
DOI: 10.1177/2325967120952674  
© The Author(s) 2020

This open-access article is published and distributed under the Creative Commons Attribution - NonCommercial - No Derivatives License (<https://creativecommons.org/licenses/by-nc-nd/4.0/>), which permits the noncommercial use, distribution, and reproduction of the article in any medium, provided the original author and source are credited. You may not alter, transform, or build upon this article without the permission of the Author(s). For article reuse guidelines, please visit SAGE's website at <http://www.sagepub.com/journals-permissions>.

by Tifford et al.<sup>20</sup> These branches cross the joint line 2 cm medial to the patellar tendon and are noted to move distally with knee flexion.<sup>19</sup> The location of the branches makes the nerve susceptible to injury during placement of the AMP during ACLR. Specifically, the superior branch of the IBSN is at a high risk for injury.<sup>20</sup> Injury to the nerve results in numbness to the anterolateral knee with possible painful neuromas and in some severe cases with reflex sympathetic dystrophy.<sup>16,17,19</sup>

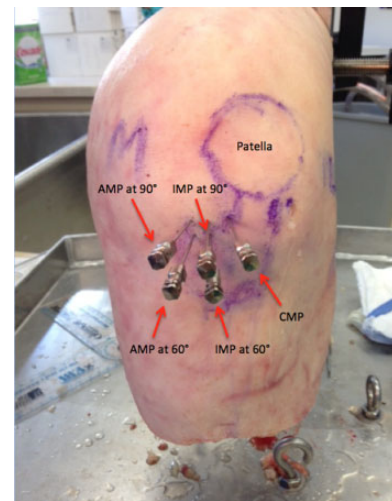
The purpose of this study was to identify a safe zone for AMP placement in ACLR to minimize the risk of injury to the IBSN. We hypothesized that increased knee flexion angles would decrease the risk to neurovascular structures when creating an AMP.

## METHODS

Twenty cadaveric, fresh-frozen knees (10 matched pairs; 6 male and 4 female) were used for dissection. Cadaveric specimens used in this study were purchased by our institution from a tissue bank. The average age of the specimens was  $62 \pm 5.82$  years (range, 49-90 years), and the average weight was  $86.2 \pm 25.6$  kg (range, 52.2-127.0 kg). To investigate the differences at increasing knee flexion angles between the superior and inferior branches of the IBSN and the AMP, 3 portals were created with fluid in the knee in each specimen at 3 knee flexion angles. All portals were marked with an 18-gauge spinal needle. A traditional CMP was placed at 60° of flexion, <1 cm from the medial border of the patellar tendon.<sup>4,6</sup>

Three AMPs were created at 2 cm medial from the medial edge of the patellar tendon just above the meniscus at 60°, 90°, and 110° of flexion (Figure 1).<sup>4,6</sup> All the portals were placed by a sports medicine fellowship-trained orthopaedic surgeon.

A 30° arthroscope (Conmed-Linvatec HD 3CCD) was used to visualize the correct intra-articular placement of each spinal needle. CMP needles were placed to allow access to the intercondylar notch. AMP needles were placed immediately above the meniscus, allowing access to the ACL footprint viewed from a central lateral portal.<sup>6</sup> The superior and inferior IBSN were then meticulously dissected with the knee in 90° of flexion after needle placement, with care taken to avoid mobilization of the nerve. A skin and subcutaneous flap was raised from the lower anteromedial thigh distally and laterally to the tibial tubercle. The IBSN and its divisions were identified emerging from the posterior border of the sartorius approximately at the level of the medial



**Figure 1.** Anterior view of a left knee showing the CMP close to the patellar tendon and the difference of medial portals placed at 60° and 90° of flexion. AMP, accessory medial portal; CMP, central medial portal; IMP, intermediate medial portal.

femoral condyle and were followed distally and laterally until the nerve crossed the patellar tendon (Figure 2).<sup>7</sup>

Calipers calibrated to the nearest 0.01 mm (Ultratech General) were used to measure the vertical distance from the spinal needles to each branch of the IBSN. If the spinal needle pierced any neurovascular structure, it was recorded as 0 mm.

Zones were then created to identify a safe zone for the AMP. These zones were defined by the spinal needles that represented the medial portals and 2 other lateral reference points in a triangular fashion. There was 1 medial reference point defined by a spinal needle at the AMP. The lateral reference points consisted of 2 points alongside the medial patellar tendon: 1 at the joint line and the other where the tendon inserts into the inferior pole of the patella. Measurements of the borders of these zones were recorded. Once the zones were identified, it was recorded whether a branch of the IBSN or any vascular structure pierced these safe zones.

Means and standard deviations were calculated for recorded distances from the spinal needles to the superior and inferior branches of the IBSN. Statistical Package for the Social Sciences Version 21 (SPSS; IBM) was used for statistical analysis. A repeated-measures analysis of variance was used to assess the differences in distances from the spinal needles to both the superior and inferior

\*Address correspondence to Kevin D. Plancher, MD, MPH, 1160 Park Avenue, New York, NY 10128, USA (email: kplancher@plancherortho.com).

†Department of Orthopaedics, Albert Einstein College of Medicine, New York, New York, USA.

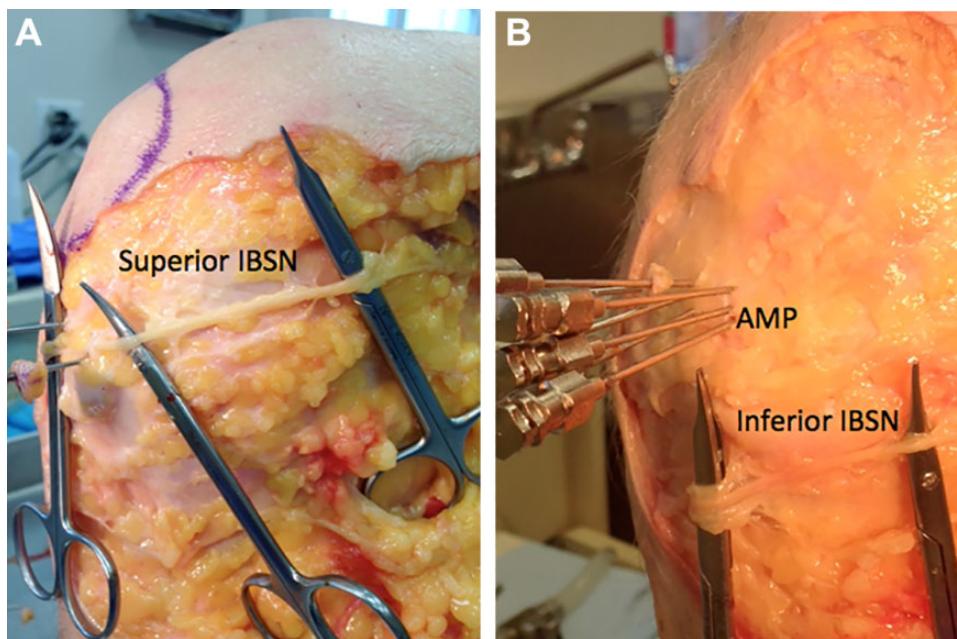
‡Department of Orthopaedic Surgery, Weill Cornell Medical College, New York, New York, USA.

§Orthopaedic Foundation, Stamford, Connecticut, USA.

Final revision submitted March 26, 2020; accepted April 9, 2020.

One or more of the authors has declared the following potential conflict of interest or source of funding: J.T.A. has received educational support from Arthrex and hospitality payments from Prodigy Surgical Distribution. K.D.P. has received consulting fees from Rotation Medical, Smith & Nephew, and Heron Therapeutics; nonconsulting fees from Pacira Pharmaceuticals; teaching/speaking fees from Linvatec; and hospitality payments from Tenex Health and Bioventus. AOSSM checks author disclosures against the Open Payments Database (OPD). AOSSM has not conducted an independent investigation on the OPD and disclaims any liability or responsibility relating thereto.

Ethical approval was not sought for the present study.



**Figure 2.** (A) Medial side of a right knee showing the course of the superior infrapatellar branch of the saphenous nerve (IBSN). (B) Medial side of a right knee showing the course of the inferior IBSN and the accessory medial portal (AMP) shown proximal.

**TABLE 1**  
Distance From the Inferior IBSN to the Medial Portal Sites at Different Knee Flexion Angles<sup>a</sup>

Portal	Knee Flexion Angle		
	60°	90°	110°
AMP, mm	18.53 ± 10.74	21.18 ± 11.09 ( <i>P</i> = .001)**	24.46 ± 12.60 ( <i>P</i> < .001)** ( <i>P</i> < .001)***
CMP, mm	28.9 ± 11.15 ( <i>P</i> = .002)*		

<sup>a</sup>Values are expressed at mean ± SD. AMP, accessory medial portal; CMP, central medial portal; IBSN, infrapatellar branch of the saphenous nerve.

\**P* value for comparison between AMP and CMP; \*\**P* value for comparison with 60° of flexion; \*\*\**P* value for comparison between 90° and 110°.

branches of the IBSN by knee flexion angle. Paired-samples *t* tests were used for post hoc comparisons. The Bonferroni correction was used for multiple comparisons. Chi-square analyses were used to determine the differences in frequency with which the spinal needle pierced the nerve and the identified zones. Significance was defined as *P* < .05.

**RESULTS**

The superior and inferior branches of the IBSN were identified in all specimens. The distances from these structures to the medial portal sites are shown in Tables 1 and 2.

**TABLE 2**  
Distance From the Superior IBSN to the Medial Portal Sites at Different Knee Flexion Angles<sup>a</sup>

Portal	Knee Flexion Angle		
	60°	90°	110°
AMP, mm	5.63 ± 5.0	6.69 ± 5.03 ( <i>P</i> = .238)**	8.56 ± 5.28 ( <i>P</i> = .015)** ( <i>P</i> = .009)***
CMP, mm	11.40 ± 5.57 ( <i>P</i> = .001)*		

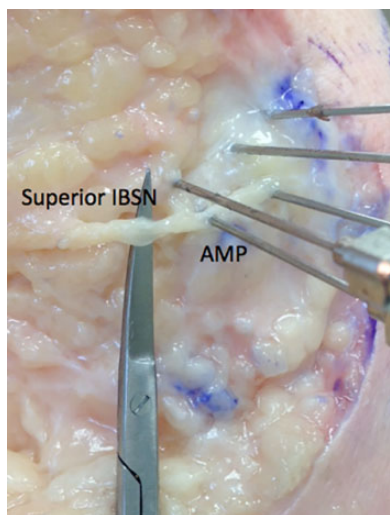
<sup>a</sup>Values are expressed at mean ± SD. AMP, accessory medial portal; CMP, central medial portal; IBSN, infrapatellar branch of the saphenous nerve.

\**P* value for comparison between AMP and CMP; \*\**P* value for comparison with 60° of flexion; \*\*\**P* value for comparison between 90° and 110°.

**Inferior Branch of the IBSN**

The CMP was significantly farther from the inferior branch of the IBSN than the AMP at 60° of knee flexion (*P* = .002). There was a significant main effect for knee flexion angle (*P* = .002) for the inferior IBSN when creating an AMP. The spinal needle was significantly closer to the inferior IBSN at 60° compared with 90° (*P* = .001) and 110° (*P* < .001). The inferior IBSN was also significantly farther at 90° compared with 110° (*P* < .001). The spinal needle only pierced the inferior IBSN and the safe zone in 1 specimen at the AMP in 60° of flexion.





**Figure 3.** The superior infrapatellar branch of the saphenous nerve (IBSN) being pierced by the spinal needle at the accessory medial portal (AMP).

**TABLE 3**  
Frequency (%) that IBSN Was Pierced by a Spinal Needle at 60°, 90°, and 110° of Knee Flexion<sup>a</sup>

Portal	IBSN Nerve Branch	Knee Flexion Angle		
		60°	90°	110°
AMP	Superior	25%	0%	0%
	Inferior	5%	0%	0%
CMP	Superior	0%	0%	0%
	Inferior	0%	0%	0%

*P* = .016\*\*    *P* = .016\*\*

<sup>a</sup>AMP, accessory medial portal; CMP, central medial portal; IBSN, infrapatellar branch of the saphenous nerve.

\**P* value for comparison between AMP and CMP; \*\**P* value for comparison with 60° of flexion.

### Superior Branch of the IBSN

The superior branch of the IBSN was significantly farther from the CMP than the AMP at 60° of knee flexion (*P* = .001). There was a significant main effect for angle (*P* = .007) for the superior branch of the IBSN. The distance between the superior IBSN and the spinal needle was not statistically significant at 60° compared with 90° of knee flexion (*P* = .238); however, the nerve was significantly farther from the portals at 110° compared with 60° of knee flexion (*P* = .015) and at 110° compared with 90° of knee flexion (*P* = .009).

Angle influenced the frequency with which the needle pierced the superior branch of the IBSN (Figure 3) when using an AMP (Table 3) (*P* = .004). The superior branch was more frequently pierced at AMP 60° (25%) versus AMP 90° (0%) (*P* = .016) and AMP 110° (0%) (*P* = .016). No nerves were pierced at the AMP at either 90° or 110° of knee

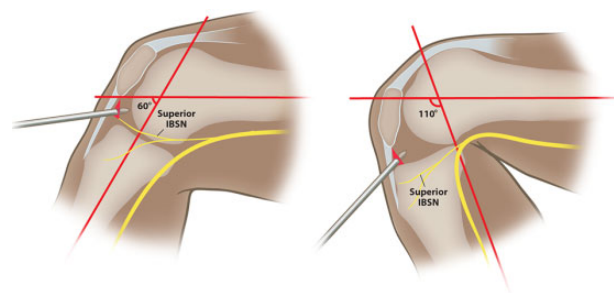
**TABLE 4**  
Frequency (%) that the Safety Zone Triangles were Violated by the IBSN at 60°, 90°, and 110° of Knee Flexion<sup>a</sup>

Triangle Zones	IBSN Nerve Branch	Knee Flexion Angle		
		60°	90°	110°
AMP	Superior	55%	28%	0%
	Inferior	6%	0%	0%

*P* = .091\*    *P* < .001\*  
*P* = .016\*\*

<sup>a</sup>AMP, accessory medial portal; IBSN, infrapatellar branch of the saphenous nerve.

\**P* value for comparison with 60° of flexion; \*\**P* value for comparison between 90° and 110°.



**Figure 4.** Knee shown at 60° of flexion piercing the superior infrapatellar branch of the saphenous nerve (IBSN). Knee then shown at 110° of flexion with the superior IBSN distal to the portal site.

flexion. At 60° of knee flexion, the superior IBSN was more frequently pierced by the spinal needle at the AMP compared with the CMP (*P* = .016).

There was a significant difference in the frequency at which a branch of the superior IBSN violated the safety zones defined by reference points (*P* = .001) (Table 4). The zones were more frequently violated at the AMP at 60° versus the AMP 90° (*P* = .091), the AMP 60° versus the AMP 110° (*P* < .001) and the AMP 90° versus AMP 110° (*P* = .016).

When creating an AMP at 110° of knee flexion, distances from the portals to the superior IBSN significantly increased (Figure 4).

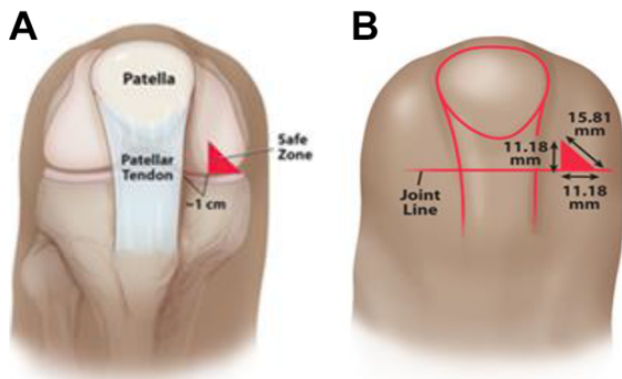
The safe zone is a triangular zone that exists at 110° of knee flexion beginning 1 cm medial to the patellar tendon at the joint line. From this point, it extends 11.2 mm medial and proximal with the superior medial border measuring 15.8 mm connecting these 2 points (Figure 5).

### Medial Genicular Arteries

The genicular arteries were not pierced at any portal site or at any knee flexion angle and also did not violate any zone.

### DISCUSSION

The superior IBSN was at the greatest risk for injury when utilizing an AMP at 60° of knee flexion. Knee flexion angle



**Figure 5.** (A) Safe zone depicted 1 cm medial to the patellar tendon. (B) Measurements of the safe zone at 110° of flexion over the anteromedial portion of the knee.

influenced the distance relationship between the nerve and the portal; the superior IBSN moves distally as the knee is flexed, moving it out of the region of the AMP. Piercing the superior IBSN was significantly decreased with knee flexion, and a safe zone was able to be described at a flexion angle of 110° for creation of the AMP.

The superior IBSN moves distally with increasing knee flexion angle, away from the zone of surgery.<sup>15,20</sup> While previously reported by Tifford et al,<sup>20</sup> their measurements did not illustrate the relationship between the nerve and the AMP, commonly used in ACLR. Furthermore, reference points were made and did not exceed a flexion angle of 90° in the previous study. Recently, 3 low-risk zones for the IBSN have been described but the authors of that study<sup>16</sup> did not vary the flexion angles or relate it to portal sites, which limits its comparison with this study. Both our study and the study by Tifford et al show the superior IBSN to be 5 to 6 mm from a corresponding reference point 2 cm medial to the patellar tendon at the joint line— $6.7 \pm 5$  mm in our study compared with  $5.1 \pm 8.8$  mm in the Tifford et al study.

In the present study, 110° of knee flexion consistently allowed for safe AMP placement. The distance between the superior IBSN and the AMP increased approximately 3 mm inferior as the knee was flexed from 60° to 110° and the nerve moved from  $5.63 \pm 5.00$  mm to  $8.56 \pm 5.28$  mm at the AMP. A previous study<sup>20</sup> also showed that the superior IBSN is at a high risk for being pierced at the area 2 cm medial to the tendon when the knee is in extension—40% (8 of 20 specimens). The superior IBSN was violated in 25% of the specimens at 60° compared with 0% at 110°. In conjunction with data from Tifford et al,<sup>20</sup> in which 40% of specimens were pierced with the knee in extension, these data strongly support creating the AMP in higher knee flexion angles.

The traditional CMP, <1 cm from the patellar tendon, was the safest portal at an average of  $11.4 \pm 5.6$  mm to the closest nerve and did not pierce any neurovascular structure.<sup>3,4,6,9</sup> The close proximity of the CMP to the patellar tendon and the location not immediately at the joint line allows for safe placement and poses little to no risk to neurovascular structures at 60° of knee flexion.<sup>4,6</sup>

These data serve as a guide for surgeons who perform a 3-portal technique utilizing an AMP for ACLR. We advise the surgeon to flex the knee to 110° to avoid complications associated with injury to the IBSN or any other vascular structure. We also recognize that autograft harvest in ACLR also poses risk to the IBSN, which is also performed at similar high knee flexion angles. Iatrogenic injury to the IBSN during autograft harvesting has been reported to be as high as 27.4%.<sup>16</sup> Injury to the branches of the IBSN exist when a graft is harvested either from the central third of the patellar tendon or from the hamstring via an antero-medial approach.<sup>6,10</sup> We still recommend utilization of this safe zone described at higher flexion angles in patellar tendon or hamstring autograft ACLR to reduce the risk of complications in conjunction with either a vertical or oblique incision, as has been described by others.<sup>13</sup> While clinical evidence for the AMP is limited,<sup>5,8,14,21</sup> a systematic review<sup>5</sup> showed mostly mixed results when comparing an ACLR using an AMP versus a transtibial technique. However, the findings did suggest that the AMP technique was more likely to produce improved clinical and biomechanical outcomes.<sup>5</sup>

Pseudoaneurysms, although very rare, have been reported in arthroscopic knee surgery.<sup>18</sup> No branches of the genicular arteries were located in the safe zone described. The superior medial genicular artery was located proximal to the AMP in all specimens. Because of the potential risk of a pseudoaneurysm, we advise surgeons to establish the AMP within the described safe zone.

### Limitations

Limitations of this study include the use of a needle instead of a cannula to establish the portals. The use of a spinal needle allowed for a better control of the positioning while the specimens were dissected. In addition, the needle would pierce and hold its position at the actual state and not allow the nerve to mobilize while the knee was dissected. The use of a cannula would not have held the tissue in place to allow for accurate identification of pierced neurovascular structures. Based on a <5-mm stab using as previously described,<sup>12</sup> the identified safe zone for AMP placement would still provide distance between the portal and neurovascular structures. Anatomy may vary between patients; therefore, care should be taken to avoid neurovascular structures. A total of 10 matched pairs of knees were used in this study, potentially limiting the observed variation in the anatomic locations of nerve branches and arteries that may have otherwise been seen if 20 individual specimens were used. Another limitation is the limited age range of the specimens. Most ACLRs are performed in younger patients. While it would be interesting to determine if these measurements were different in a young knee, the availability of young specimens makes this difficult.

### CONCLUSION

The superior IBSN is at risk for iatrogenic injury with a traditional AMP at 60° of knee flexion. The nerve moves

distally with knee flexion. At 90° of flexion, the nerve was found to course through the safe zone. A safe zone at 110° decreases the risk of neurovascular injury and makes AMP safe for ACLR.

## REFERENCES

1. Abdelkafy A. Protection of the medial femoral condyle articular cartilage during drilling of the femoral tunnel through the accessory medial portal in anatomic anterior cruciate ligament reconstruction. *Arthroscopy Tech*. 2012;1(2):e149-e154.
2. Araujo PH, van Eck CF, Macalena JA, Fu FH. Advances in the three-portal technique for anatomical single- or double-bundle ACL reconstruction. *Knee Surg Sports Traumatol Arthrosc*. 2011;19(8):1239-1242.
3. Bedi A, Musahl V, Steuber V, et al. Transtibial versus anteromedial portal reaming in anterior cruciate ligament reconstruction: an anatomic and biomechanical evaluation of surgical technique. *Arthroscopy*. 2011;27(3):380-390.
4. Brown CH Jr, Spalding T, Robb C. Medial portal technique for single-bundle anatomical anterior cruciate ligament (ACL) reconstruction. *Int Orthop*. 2013;37(2):253-269.
5. Chalmers PN, Mall NA, Cole BJ, Verma NN, Bush-Joseph CA, Bach BR Jr. Anteromedial versus transtibial tunnel drilling in anterior cruciate ligament reconstructions: a systematic review. *Arthroscopy*. 2013;29(7):1235-1242.
6. Cohen SB, Fu FH. Three-portal technique for anterior cruciate ligament reconstruction: use of a central medial portal. *Arthroscopy*. 2007;23(3):325.
7. Ebraheim NA, Mekhail AO. The infrapatellar branch of the saphenous nerve: an anatomic study. *J Orthop Trauma*. 1997;11(3):195-199.
8. Geng Y, Gai P. Comparison of 2 femoral tunnel drilling techniques in anterior cruciate ligament reconstruction. A prospective randomized comparative study. *BMC Musculoskelet Disord*. 2018;19(1):454.
9. Karlsson J, Irrgang JJ, van Eck CF, Samuelsson K, Mejia HA, Fu FH. Anatomic single- and double-bundle anterior cruciate ligament reconstruction, part 2: clinical application of surgical technique. *Am J Sports Med*. 2011;39(9):2016-2026.
10. Kartus J, Ejerhed L, Eriksson BI, Karlsson J. The localization of the infrapatellar nerves in the anterior knee region with special emphasis on central third patellar tendon harvest: a dissection study on cadaver and amputated specimens. *Arthroscopy*. 1999;15(6):577-586.
11. Kerver AL, Leliveld MS, den Hartog D, Verhofstad MH, Kleinrensink GJ. The surgical anatomy of the infrapatellar branch of the saphenous nerve in relation to incisions for anteromedial knee surgery. *J Bone Joint Surg Am*. 2013;95(23):2119-2125.
12. Lubowitz JH1, Ahmad CS, Anderson K. All-inside anterior cruciate ligament graft-link technique: second-generation, no-incision anterior cruciate ligament reconstruction. *Arthroscopy*. 2011;27(5):717-727.
13. Mousavi H, Mohammadi M, Aghdam HA. Injury to the infrapatellar branch of the saphenous nerve during ACL reconstruction with hamstring tendon autograft: a comparison between oblique and vertical incisions. *Arch Bone Jt Surg*. 2018;6(1):52-56.
14. Nakamura T, Koga H, Otabe K, et al. Comparison of three approaches for femoral tunnel during double-bundle anterior cruciate ligament reconstruction: a case controlled study. *J Orthop Sci*. 2019;24(1):147-152.
15. Osaki K, Okazaki K, Tashiro Y, Matsubara H, Iwamoto Y. Influences of knee flexion angle and portal position on the location of femoral tunnel outlet in anterior cruciate ligament reconstruction with anteromedial portal technique. *Knee Surg Sports Traumatol Arthrosc*. 2015;23(3):777-784.
16. Papastergiou SG, Voulgaropoulos H, Mikalef P, Ziogas E, Pappis G, Giannakopoulos I. Injuries to the infrapatellar branch(es) of the saphenous nerve in anterior cruciate ligament reconstruction with four-strand hamstring tendon autograft: vertical versus horizontal incision for harvest. *Knee Surg Sports Traumatol Arthrosc*. 2006;14(8):789-793.
17. Poehling GG, Pollock FE Jr, Koman LA. Reflex sympathetic dystrophy of the knee after sensory nerve injury. *Arthroscopy*. 1988;4(1):31-35.
18. Sherman OH, Fox JM, Snyder SJ, et al. Arthroscopy—"no-problem surgery." An analysis of complications in two thousand six hundred and forty cases. *J Bone Joint Surg Am*. 1986;68(2):256-265.
19. Spicer DD, Blagg SE, Unwin AJ, Allum RL. Anterior knee symptoms after four-strand hamstring tendon anterior cruciate ligament reconstruction. *Knee Surg Sports Traumatol Arthrosc*. 2000;8(5):286-289.
20. Tifford CD, Spero L, Luke T, Plancher KD. The relationship of the infrapatellar branches of the saphenous nerve to arthroscopy portals and incisions for anterior cruciate ligament surgery. An anatomic study. *Am J Sports Med*. 2000;28(4):562-567.
21. Youm YS, Cho SD, Lee SH, Youn CH. Modified transtibial versus anteromedial portal technique in anatomic single-bundle anterior cruciate ligament reconstruction: comparison of femoral tunnel position and clinical results. *Am J Sports Med*. 2014;42(12):2941-2947.