

[CASE REPORT]

Airway Obstruction Caused by Mucinous Material Adherent to the Epiglottis in a Patient with a Progressive Neurological Disorder: An Unusual Case of a Condition Mimicking Acquired Laryngomalacia

Sho Yamada^{1,2}, Daisuke Kawakami¹, Junichiro Ohira³ and Hiroshi Ueta¹

Abstract:

We herein report the successful management of a condition mimicking acquired laryngomalacia using conservative methods in an elderly man with a progressive neurological disorder. The patient developed stridor and was transferred to the intensive-care unit. Flexible laryngoscopy revealed a collapsed epiglottis during inspiration, as seen in acquired laryngomalacia, with mucinous material firmly adhered to the epiglottis. The stridor resolved after the removal of this material. Pathology revealed keratinized material, suggesting a collection of sputum or epithelial tissue. Thus, flexible laryngoscopy can differentiate the cause of airway obstruction and avoid unnecessary endotracheal intubation in patients with neurological disorders.

Key words: spinocerebellar ataxia, acquired laryngomalacia, airway emergency, neurological disorder, conservative treatment

(Intern Med 58: 2711-2714, 2019)

(DOI: 10.2169/internalmedicine.2268-18)

Introduction

Several neurological disorders cause airway instability. Bulbar muscle weakness and bilateral vocal paralysis are well-known causes (1, 2). Although rare, acquired laryngomalacia can also occur in patients with neurological disorders (3-5).

Most cases of acquired laryngomalacia are diagnosed by flexible laryngoscopy and treated by laryngeal surgery (6, 7). Although acquired laryngomalacia may be resolved after neurological recovery in some cases (8), resolution without surgical management has not been reported in patients with progressive neurological disorders.

We herein report a case of an elderly man with a progressive neurological disorder who developed an obstructive airway disorder mimicking acquired laryngomalacia that was diagnosed by flexible laryngoscopy and was reversible by

conservative treatment.

Case Report

A 73-year-old man with a 27-year history of suspected spinocerebellar ataxia (SCA) was admitted for hypernatremia (187 mmol/L) and an altered mental status. He manifested dysarthria, dysphagia and gait disturbance at 46 years of age. The following year, he consulted a neurologist and was suspected of having SCA, an inherited disorder, because cranial computed tomography (CT) revealed cerebellar atrophy without any other abnormal findings. There was no significant family history of neurological disorders. The patient refused genetic testing, which was necessary for a definitive diagnosis. His symptoms had slowly progressed over time. A neurological examination performed before the current admission revealed a conscious state, mild cognitive impairment, and saccadic eye movements. He exhibited orolingual

¹Department of Anesthesia and Critical Care, Kobe City Medical Center General Hospital, Japan, ²Respiratory Disease Center, Kitano Hospital, Tazuke Kofukai Medical Research Institute, Japan and ³Department of Neurology, Kobe City Medical Center General Hospital, Japan
Received: October 15, 2018; Accepted: March 25, 2019; Advance Publication by J-STAGE: June 7, 2019
Correspondence to Dr. Sho Yamada, sho.yjp@gmail.com

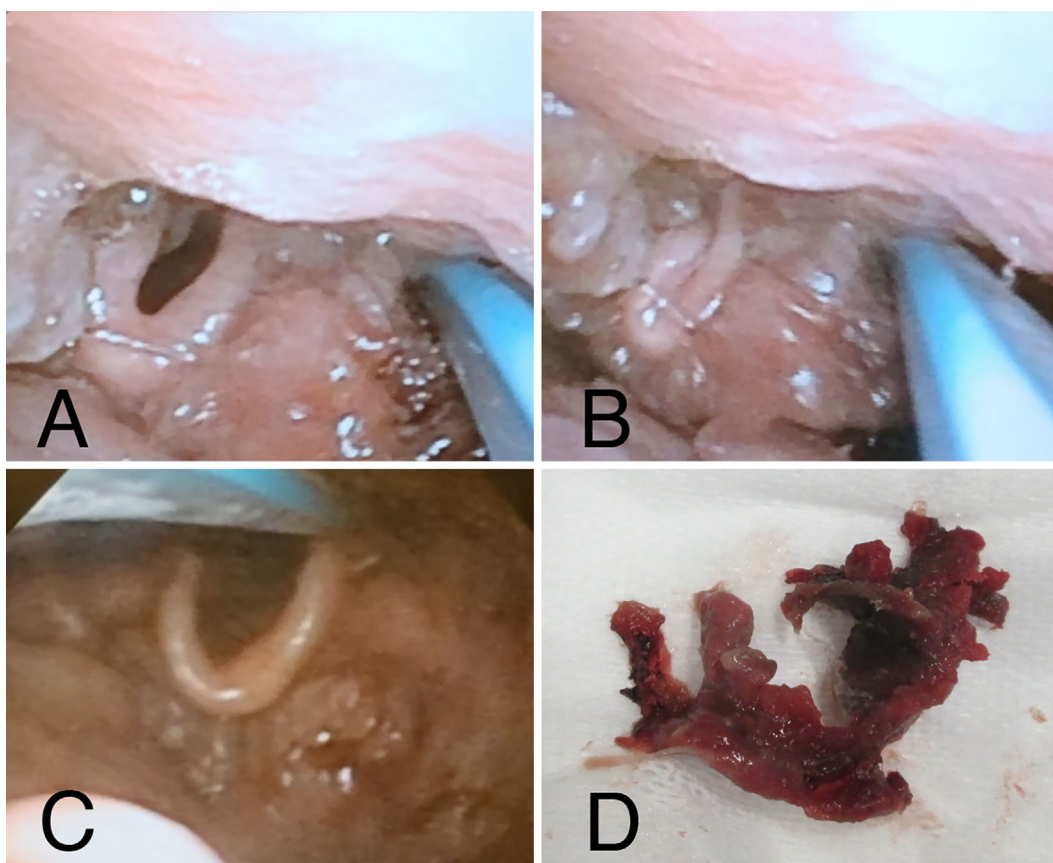


Figure 1. Findings of flexible videolaryngoscopy for an elderly patient with a progressive neurological disorder who developed a condition mimicking acquired laryngomalacia; (A) Normal epiglottis during expiration, (B) Collapsed epiglottis during inspiration, (C) Epiglottis after removal of the obstructive material via laryngoscopy, (D) Removal of stiff material (5 cm in length).

dyskinesia as well as dysphagia. Although he could consume soft foods by himself, he had lost his appetite for the past month. He also exhibited severe dysarthria, and his voice was barely audible. Deep tendon reflexes and motor, sensory, and autonomic functions were normal. Ataxia predominantly affected the trunk and not the limbs. He required assistance to sit up in bed and maintain a seated position. However, he could crawl indoors and walk with the assistance of a walker, although he found it difficult. On admission, he could not obey commands.

Following hydration in the hospital, the patient's mental status improved with a decrease in the serum sodium, which was corrected at a rate of <10 mmol/L per day. Decreased oral ingestion due to dysphagia appeared to have caused the hypernatremia. On day 5, however, he was transferred to the intensive-care unit (ICU) from the general ward because of airway emergency. His serum sodium level was 144 mmol/L in the morning. On arrival in the ICU, his respiratory rate was 30/min, with an oxygen saturation of 100% on room air. He presented with stridor and intercostal retraction. The jaw-thrust maneuver was unsuccessful, and CT did not reveal any airway obstruction. Airway obstruction due to vocal cord paralysis or a foreign body was suspected based on his history and physical examination findings. We performed flexible videolaryngoscopy before endotracheal intubation.

Flexible videolaryngoscopy revealed the collapse of his epiglottis during inspiration (Fig. 1A and B, Supplementary material). The vocal folds were not fixed in the paramedian position. The characteristic movement of the epiglottis was suggestive of acquired laryngomalacia. However, additional careful observation showed mucinous material surrounding and firmly adhered to the epiglottis. This material could not be removed by suctioning and was manually removed with forceps. After removal, the epiglottis was no longer collapsed, and the stridor resolved (Fig. 1C and D). He was discharged from the ICU on the same day. A histopathological examination of the specimen revealed keratinized material, suggesting the collection of sputum or epithelial tissue.

After ICU discharge, the patient's mental status was normal; however, his swallowing function was worse than that before hospital admission. Brain magnetic resonance imaging (MRI) was performed on day 10. Fluid attenuated inversion recovery (FLAIR) revealed cerebellar atrophy, consistent with the previous findings (Fig. 2A and B). On diffusion-weighted imaging (DWI), there were no abnormal signals suggestive of osmotic demyelination syndrome (ODS) (Fig. 2C). In order to prevent future problems related to dysphagia, we performed percutaneous endoscopic gastrostomy. However, he was able to recover his oral ingestion ability after swallowing rehabilitation and did not require

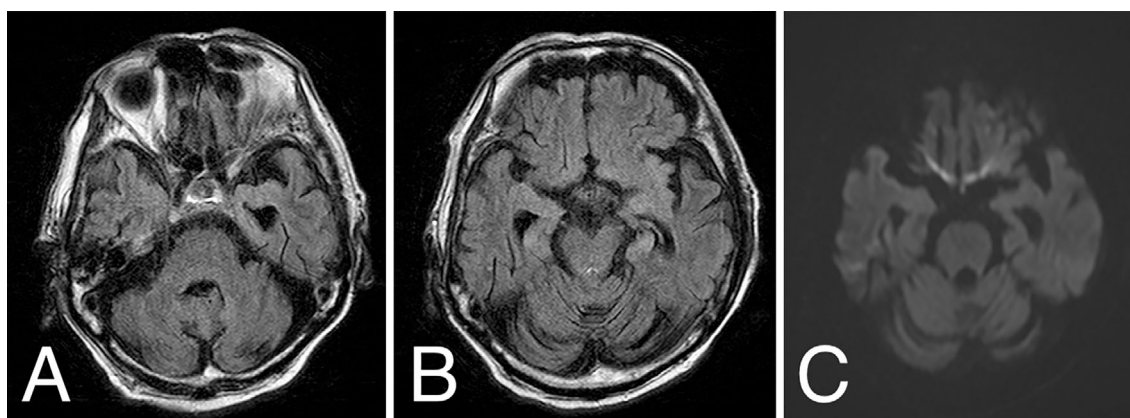


Figure 2. Brain magnetic resonance imaging findings for an elderly patient with a progressive neurological disorder who developed a condition mimicking acquired laryngomalacia; (A, B) Cerebellar atrophy on FLAIR, (C) No abnormal signals on DWI.

gastric fistula formation at the time of discharge.

Discussion

Laryngomalacia is a common congenital anomaly of the larynx, with stridor being the most common manifestation. It is caused by the collapse of supraglottic structures during inspiration (9). Acquired laryngomalacia is an unusual cause of upper airway obstruction and is mainly described in case reports or case series (3-8, 10-14). It is associated with neurological disorders, surgery, trauma, and general anesthesia (6, 10). The pathogenesis of acquired laryngomalacia can be explained by two theories (7). First, loss of neurological control of supraglottic structures may play a role. Alternatively, increased negative inspiratory pressure can cause edema in the mucosal and submucosal tissue.

Originally, laryngomalacia in infants was classified into three types according to the type of obstruction (9). Type 1 is caused by prolapse of the mucosa overlying the arytenoid cartilages. Type 2 is caused by foreshortened aryepiglottic folds. Type 3 is caused by posterior prolapse of the epiglottis. Laryngomalacia tends to show spontaneous resolution, but some cases require surgery based on the type (15). For acquired laryngomalacia, there is no classification or guideline for determining the treatment modality, although most cases seem to be treated by tracheostomy or other otolaryngologic surgeries (6). In some cases, the condition resolves after the resolution of the neurological disorder (8). However, acquired laryngomalacia associated with neurological disorders is typically observed in patients with progressive neurological disorders, such as multiple system atrophy and amyotrophic lateral sclerosis, and resolution without surgical management has not been reported in such patients. In these disorders, the epiglottis is sucked into the glottis and prolapses posteriorly. This type of acquired laryngomalacia is called floppy epiglottis (3-5). In this report, we described an unusual case involving an elderly man with a progressive neurological disorder who developed an obstructive airway disorder mimicking acquired laryngomalacia. On close ob-

servaion using flexible laryngoscopy, it was found that the epiglottis collapsed during inspiration because of the presence of firmly adherent mucinous material. Manual removal of this material led to resolution of the stridor. Thus, the condition was reversible, and unnecessary endotracheal intubation was avoided.

Airway management is a critical aspect of the treatment of critically ill patients (16). In an analysis at a tertiary referral center, airway emergency accounted for 6.3% of unexpected ICU admissions (17). Bulbar muscle weakness and bilateral vocal cord fold paresis are the two best known causes of airway obstruction in patients with neurological disorders (1, 2). Indeed, neurological disorders account for approximately 22% of adult cases of bilateral vocal cord paralysis (18). Although rare, acquired laryngomalacia has been reported as a cause of airway emergency after general anesthesia (10). Therefore, it should be considered when evaluating patients with airway emergency.

Although endotracheal intubation is important, it is associated with major complications, such as severe hypoxemia and hemodynamic instability (19). Therefore, avoiding endotracheal intubation whenever possible may be extremely beneficial, even for patients with airway emergency. Most adult cases of laryngomalacia are diagnosed by flexible laryngoscopy (6). Observation of dynamic airway obstruction confirms the diagnosis. In the present case, flexible laryngoscopy showed that the airway itself was not obstructed by any material; instead, structural changes around the epiglottis were causing the symptoms. Flexible laryngoscopy also enables the diagnosis of bilateral vocal fold paralysis, a more common cause of airway obstruction. Thus, it can be very useful for determining the actual cause of airway obstruction in patients with progressive neurological disorders. The present case is also unique because flexible laryngoscopy revealed a condition mimicking acquired laryngomalacia that was not due to the neurological disorder itself. We ruled out ODS for several reasons. First, the rate of sodium level correction was slow. Second, brain MRI did not show any findings that suggested ODS. Third, the patient's symp-

toms, aside from his dysphagia, remained stable. Finally, although his dysphagia initially worsened, his oral ingestion ability recovered after swallowing rehabilitation, a finding that is generally not observed in patients with ODS.

Pathological findings showed that the mucinous material around the epiglottis was not a foreign body but keratinized material. This suggests that the material was produced within the body. We believe that an impaired swallowing function due to the patient's neurological disorder and his hypovolemic state due to hypernatremia may have been responsible for the formation of redundant material around the epiglottis. In addition, an abnormality in the laryngeal tone, as seen in patients with acquired laryngomalacia (5), may have played a role. Orolingual dyskinesia has been reported in association with SCA, with possible causes being basal ganglia degeneration and consequent loss of muscle tone (20). Accordingly, the presence of orolingual dyskinesia in our patient suggest tone abnormality. These obstructive factors likely amplified the negative inspiratory pressure according to Bernoulli's principle (5, 6). However, this hypothesis needs to be validated using physiological methods.

In conclusion, we described an unusual condition mimicking acquired laryngomalacia caused by mucinous material adherent to the epiglottis and easily reversed by conservative treatment in a patient with a progressive neurological disorder. Even when a dynamic abnormality in the epiglottis resembles acquired laryngomalacia at first glance, other reversible causes should be considered. Patients with neurological disorders should be evaluated using flexible laryngoscopy to determine the actual cause of airway obstruction and avoid unnecessary endotracheal intubation.

The authors state that they have no Conflict of Interest (COI).

References

1. Benditt JO, Boitano LJ. Pulmonary issues in patients with chronic neuromuscular disease. *Am J Respir Crit Care Med* **187**: 1046-1055, 2013.
2. Rubin AD, Sataloff RT. Vocal fold paresis and paralysis. *Otolaryngol Clin North Am* **40**: 1109-1131, 2007.
3. Shimohata T, Shinoda H, Nakayama H, et al. Daytime hypoxemia, sleep-disordered breathing, and laryngopharyngeal findings in multiple system atrophy. *Arch Neurol* **64**: 856-861, 2007.
4. Ito K, Chitose H, Kobayashi A. Upper airway obstruction caused by a floppy epiglottis-report of two cases of amyotrophic lateral sclerosis (ALS). *Nihon Jibiinkoka Gakkai Kaiho* **112**: 660-664, 2009 (in Japanese, Abstract in English).
5. Shimohata T, Tomita M, Nakayama H, Aizawa N, Ozawa T, Nishizawa M. Floppy epiglottis as a contraindication of CPAP in patients with multiple system atrophy. *Neurology* **76**: 1841-1842, 2011.
6. Hey SY, Oozeer NB, Robertson S, MacKenzie K. Adult-onset laryngomalacia: case reports and review of management. *Eur Arch Otorhinolaryngol* **271**: 3127-3132, 2014.
7. Gazzaz MJ, El-Hakim H. A case of acquired laryngomalacia in an infant, with endoscopy before and after establishing the diagnosis for the first time. *BMJ Case Rep* 2015.
8. Wiggs WJ, DiNardo LJ. Acquired laryngomalacia: resolution after neurologic recovery. *Otolaryngol Head Neck Surg* **112**: 773-776, 1995.
9. Olney DR, Greinwald JH, Smith RJ, Bauman NM. Laryngomalacia and its treatment. *Laryngoscope* **109**: 1770-1775, 1999.
10. Takeshita J, Nishiyama K, Fujii M, et al. Repetitive postoperative extubation failure and cardiac arrest due to laryngomalacia after general anesthesia in an elderly patient: a case report. *J Anesth* **31**: 779-781, 2017.
11. Rowe-Jones J, Moore-Gillon V, Hamilton P. Acquired laryngomalacia: epiglottis prolapse as a cause of airway obstruction. *Ann Otol Rhinol Laryngol* **102**: 485-486, 1993.
12. Mima H, Ishida H, Yamazaki K. Acquired laryngomalacia as a cause of airway obstruction immediately after unilateral mouth floor surgery. *Anaesthesia* **51**: 1152-1154, 1996.
13. Echtermach M, Arndt S, Markl M, Richter B, Breyer T. Acquired laryngomalacia of the epiglottis: case report and review of the literature. *HNO* **56**: 1233-1238, 2008 (in German, Abstract in English).
14. Nonomura N, Seki S, Kawana M, Okura T, Nakano Y. Acquired airway obstruction caused by hypertrophic mucosa of the arytenoids and aryepiglottic folds. *Am J Otolaryngol* **17**: 71-74, 1996.
15. Richter GT, Thompson DM. The surgical management of laryngomalacia. *Otolaryngol Clin North Am* **41**: 837-864, 2008.
16. Higgs A, Cook TM, McGrath BA. Airway management in the critically ill: the same, but different. *Br J Anaesth* **117** (Suppl): i5-i9, 2016.
17. Gresoiu M, Singer M. Admissions with airway emergencies in the ICU at a tertiary referral centre. *Crit Care* **19** (Suppl 1): P205, 2015.
18. Holinger LD, Holinger PC, Holinger PH. Etiology of bilateral abductor vocal cord paralysis: a review of 389 cases. *Ann Otol Rhinol Laryngol* **85**: 428-436, 1976.
19. Jaber S, Jung B, Corne P, et al. An intervention to decrease complications related to endotracheal intubation in the intensive care unit: a prospective, multiple-center study. *Intensive Care Med* **36**: 248-255, 2010.
20. Pedroso JL, Carvalho AA, Luiz M, et al. Unusual movement disorders in spinocerebellar ataxias. *Parkinsonism Relat Disord* **19**: 834-835, 2013.

The Internal Medicine is an Open Access journal distributed under the Creative Commons Attribution-NonCommercial-NoDerivatives 4.0 International License. To view the details of this license, please visit (<https://creativecommons.org/licenses/by-nc-nd/4.0/>).