

# The Use of Local Perforator Flaps in Delayed or Secondary Breast Reconstruction

Edel Marie Quinn, MBBCh, MD,  
FRCS  
Siobhan O'Ceallaigh, MD,  
FRCS(Plast)  
Lyndsey Highton, BMBCh, MA,  
FEBS(Breast), FRCS(Plast)  
John Murphy, MBChB, PhD,  
FRCS

**Summary:** Local perforator flaps are used as immediate volume replacement techniques in breast conserving surgery. Here, we describe a case series of local perforator flaps used in the delayed setting to correct defects following previous breast surgery, including previous breast conservation surgery or mastectomy with reconstruction. All cases were performed in a tertiary referral breast unit between 2014 and 2020. Cases were identified using a prospectively maintained database. Indications, type of perforator flap used, immediate post-operative complications, and longer term outcomes were recorded. Fifteen cases were identified: 8 following previous breast conserving surgery and radiotherapy, 6 following mastectomy and reconstruction, and 1 for developmental breast asymmetry following childhood radiotherapy. Indications included volume deficit, contour defect, asymmetry, and capsular contracture. One patient a major complication requiring return to theater due to implant-related infection. There were no flap losses. Longer term, 2 patients underwent lipomodelling to further augment breast volume as part of a planned, staged revision. One patient subsequently elected to have bilateral breast implant exchange to increase volume. Our series shows the versatility of local perforator flaps in the correction of complex breast defects that can occur following previous breast surgery. Delayed local perforator flaps are associated with low morbidity, and further revision surgery is not commonly required. (*Plast Reconstr Surg Glob Open* 2020;8:e3263; doi: [10.1097/GOX.0000000000003263](https://doi.org/10.1097/GOX.0000000000003263); Published online 17 December 2020.)

## INTRODUCTION

Local perforator flaps, utilized as volume replacement to replace defects occurring during breast conserving surgery (BCS),<sup>1-4</sup> are primarily described in the setting of immediate partial breast reconstruction.<sup>3,5</sup> However, their use has been described in a small series in the delayed setting, where patients require corrective surgery following BCS and radiotherapy,<sup>6</sup> and as a means of providing soft tissue coverage over implant-based breast reconstruction or as post-mastectomy reconstruction for smaller volume breasts.<sup>7</sup>

In this short report, we describe our experience using local perforator flaps in an expanded role to correct complex defects following previous BCS, mastectomy,

and reconstruction, and to address developmental breast asymmetry following childhood radiotherapy.

## METHODS

The Nightingale Breast Centre treats over 1200 new breast cancer patients per year, provides the largest risk-reducing mastectomy service in Europe, and is a tertiary referral center for corrective breast surgery.<sup>8</sup> We interrogated our prospectively maintained database to identify patients who underwent delayed local perforator flap reconstruction between August 2014 and February 2020. Patient demographics, indication for procedure, previous surgery performed, local flap used, perioperative complications, and long-term outcomes were analyzed.

Patients are considered for this procedure if they have a suitable local perforator flap donor site available. Indications include volume/contour deficit following BCS, mastectomy and reconstruction, and developmental breast asymmetry. Patients who have had prior radiotherapy have surgery delayed until at least 1 year post radiotherapy.

*From the Department of Oncoplastic Breast Surgery, Nightingale Breast Centre, Wythenshawe Hospital, Manchester University NHS Foundation Trust, Manchester, UK.*

*Received for publication July 28, 2020; accepted September 29, 2020.*

*Copyright © 2020 The Authors. Published by Wolters Kluwer Health, Inc. on behalf of The American Society of Plastic Surgeons. This is an open-access article distributed under the terms of the [Creative Commons Attribution-Non Commercial-No Derivatives License 4.0 \(CCBY-NC-ND\)](https://creativecommons.org/licenses/by-nc-nd/4.0/), where it is permissible to download and share the work provided it is properly cited. The work cannot be changed in any way or used commercially without permission from the journal.*

DOI: [10.1097/GOX.0000000000003263](https://doi.org/10.1097/GOX.0000000000003263)

**Disclosure:** The authors declare no conflicts of interest. This study did not receive any funding.

Related Digital Media are available in the full-text version of the article on [www.PRSGlobalOpen.com](http://www.PRSGlobalOpen.com).

The presence of an appropriate perforator vessel on which to base the flap is confirmed in clinic using a handheld Doppler. The size of the flap harvested is dependent on the amount of tissue available at the donor site. The flap outline is drawn preoperatively (lazy S or elliptical) using the pinch test to ensure the closure is tension-free. When a larger defect needs to be reconstructed, the thoracodorsal artery perforator (TDAP) flap is chosen because a greater volume of tissue can be mobilized. The lateral intercostal artery perforator (LICAP) flap or lateral thoracic artery perforator (LTAP) flap can be chosen for lateral defects. The LTAP flap has the advantage of greater mobility, allowing it to be used also for more medial defects. Lower pole defects are reconstructed using the medial intercostal artery perforator (MICAP) flap or anterior intercostal artery perforator (AICAP) flap (Fig. 1).

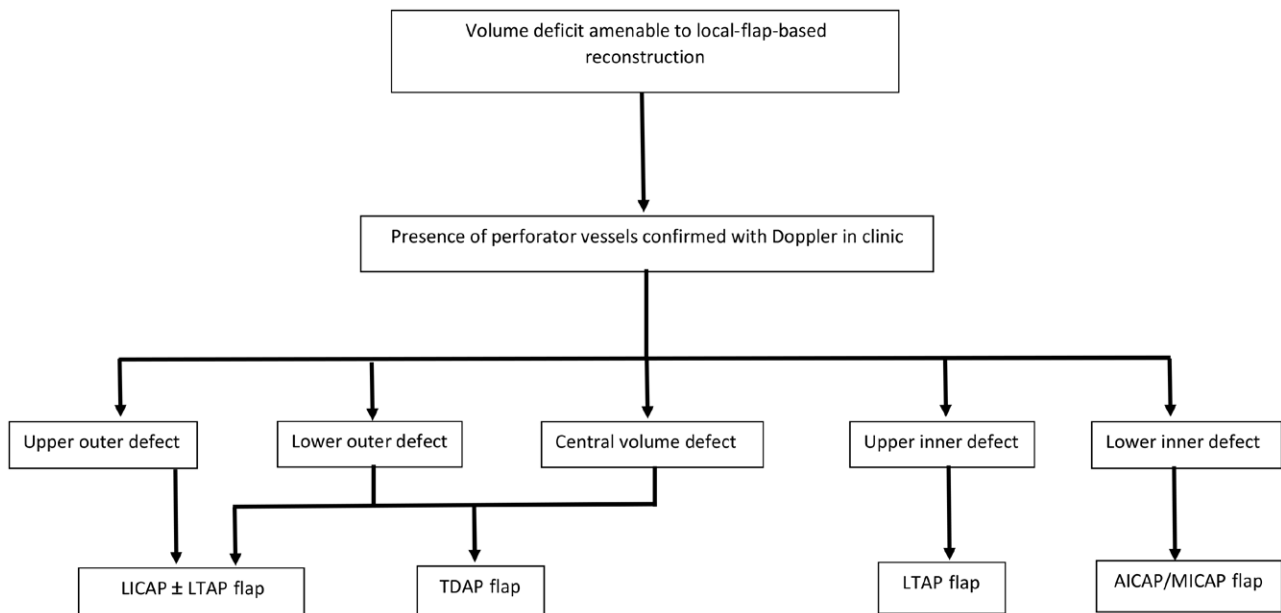
Intra-operatively, the recipient site for the flap is prepared by release of existing scar tissue to delineate the cavity to be filled by the flap. In the case of capsular contracture, the capsule and implant are removed. The donor flap is elevated on perforator vessels, aided by intra-operative Doppler. Once dissection is complete, the flap is de-epithelialized and pivoted as a “turnover flap” or “propellered” into the defect. The donor wound site is closed with absorbable sutures, and drains are not usually required. Patients are routinely discharged within 23 hours of surgery. Patients are reviewed in the dressing clinic at 1 week, in the outpatient follow-up clinic at 2 weeks and 3 months post-operatively.

## RESULTS

Between August 2014 and February 2020, 15 delayed local perforator flap reconstructions were performed in 14

patients: 8 (53%) following BCS, 6 (40%) following mastectomy and implant reconstruction, and 1 for a patient with asymmetry following childhood flank radiotherapy to treat a Wilms’ tumor. The median age was 53.5 years (range 27–72) and 14% (n = 2) were smokers. Patient and procedure details are shown in Table 1. Seven patients (50%) had had more than 1 breast procedure before undergoing local flap reconstruction. Pre- and post-operative appearance is demonstrated in Figure 2. (See figure, Supplemental Digital Content 1, which displays (a) pre- and (b) post-operative pictures showing a right delayed AICAP flap to correct a bird’s beak deformity following a previous wide local excision and radiotherapy. Left capsulectomy and breast implant exchange was also performed to improve the outcome following previous left mastectomy and latissimus dorsi/implant reconstruction. <http://links.lww.com/PRSGO/B522>; See figure, Supplemental Digital Content 2, which displays (a) pre- and (b) post-operative pictures of a patient who underwent right LICAP flap, lipomodeling, and nipple re-positioning along with left mastopexy and lipofilling to correct developmental asymmetry following childhood radiotherapy for a Wilms’ tumor. <http://links.lww.com/PRSGO/B523>.)

Median post-operative stay was 1 night (range 0–4). Complications were recorded after 5 procedures (33%), of which 4 were minor (3 superficial surgical site infections and 1 delayed superficial wound healing), treated as outpatients with antibiotics, and/or negative pressure dressings. One patient (BMI 45) required return to theater due to infection requiring removal of pre-existing breast implant and delayed wound healing requiring a skin graft. During a median of 23 months follow-up (range 1–67 months), 3 patients underwent further surgery, as documented in Table 1.

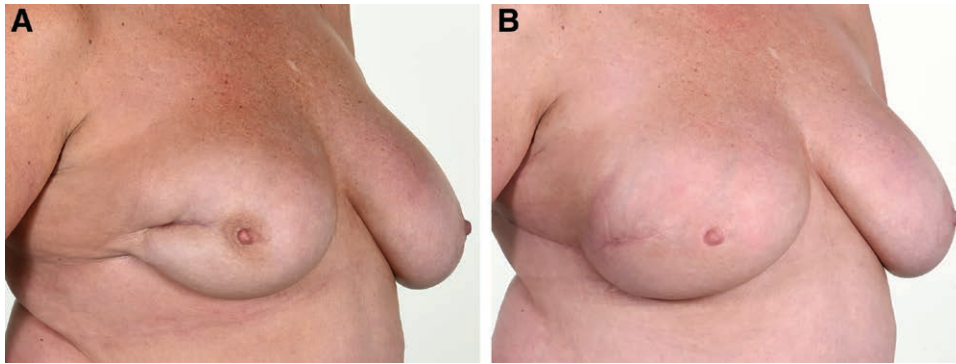


**Fig. 1.** Decision-making algorithm used to choose the appropriate local perforator flap in our unit. LICAP, lateral intercostal artery perforator; LTAP, lateral thoracic artery perforator; TDAP, thoracodorsal artery perforator; AICAP, anterior intercostal artery perforator; MICAP, medial intercostal artery perforator.

**Table 1. Description of Patients Undergoing Delayed Partial Breast Reconstruction with Local Perforator Flaps**

Age (y)	Date of First Surgery	Previous Breast Surgeries	Prior RT	Indication for Flap Surgery	Site of Defect	Date of Flap Surgery	Flap Surgery Performed	Revision Required	Revision Performed
1	49	WLE	Yes	Defect post WLE	Lower outer	2015	AICAP	No	
2	60	WLE	Yes	Bird's beak deformity post WLE	Lower central	2018	AICAP	No	
3	50	Lipomodelling of defect Therapeutic mammoplasty Excision of seroma cavity	Yes	Tethered scar after seroma cavity excision	Lower central	2018	LICAP	No	
4	54	WLE	Yes	Defect post WLE	Lower outer	2018	LICAP + LTAP	No	
5	53	WLE	Yes	Defect post WLE	Lower outer	2018	LICAP	No	
6	72	WLE	Yes	Non-healing wound following reduction mammoplasty.	Lower outer	2019	LICAP + LTAP	No	
		Bilateral breast reduction for asymmetry							
7	58	WLE	Yes	on side with previous RT	Lower outer	2019	LTAP	No	
8	54	WLE	Yes	Defect post WLE	NA	2019	LICAP	No	
9*	52	Risk-reducing mastectomy + implant reconstruction	No	Revision of implant reconstruction with use of flap for additional volume	Central	2014	TDAP	Yes	Upsizing of implants to achieve further volume
10*	53	Risk-reducing mastectomy + implant reconstruction	No	Revision of implant reconstruction with use of flap for additional volume	Central	2015	TDAP	Yes	Upsizing of implants to achieve further volume
11	59	Mastectomy + implant reconstruction Implant conversion to DIEP	Yes	Partial DIEP flap necrosis requiring volume replacement	Lower central	2015	TDAP	Yes	Lipomodelling to improve symmetry with contralateral breast x 2
12	65	Mastectomy + implant/LD reconstruction Capsulectomy + implant removal	Yes	Lack of volume from LD reconstruction following removal of implant	Central	2018	LICAP	No	
13	44	Mastectomy + implant/LD reconstruction Implant removal Lipofilling	No	Lack of volume from LD reconstruction	Central	2020	LICAP	No	
14	62	Mastectomy + implant/LD reconstruction Capsulectomy + implant exchange	Yes	Recurrent capsular contracture within 12 months	Central	2020	LICAP	No	
15	27	Nil – acquired asymmetry	Yes	Lack of lower pole breast development following childhood flank radiotherapy for a Wilms' tumor	Lower central	2015	LICAP	Yes	Planned contralateral mastopexy and lipofilling, ipsilateral lipofilling and nipple re-positioning

\*Procedures 9 and 10 were performed on the same patient who had staged bilateral surgery, right side performed in 2014, left in 2015. Volume defects are described as lower outer for lower outer quadrant, lower central for defects at the 6 o'clock position, and central for overall volume defects requiring positioning of the flap centrally in the breast to create volume and projection. AICAP, anterior intercostal artery perforator; DIEP, deep inferior epigastric perforator flap; LD, latissimus dorsi flap; LICAP, lateral intercostal artery perforator; NA, not available; RT, radiotherapy; TDAP, thoracodorsal artery perforator; WLE, wide local excision.



**Fig. 2.** Right delayed LICAP flap reconstruction to correct deformity following previous wide local excision and radiotherapy: Preoperative (A) and postoperative (B) photographs.

## DISCUSSION

Our case series shows the versatility of local perforator flaps in managing complex defects that can occur following breast surgery. Local perforator flaps offer a robust option where patients have a significant volume or contour deficit after BCS.<sup>6</sup> The benefits of introducing well-vascularized healthy flaps into prior radiotherapy fields have previously been recognized in total breast reconstruction<sup>9</sup> as well as head and neck reconstruction.<sup>10</sup> Lipofilling is an alternative option to correct defects post BCS. However, many patients require multiple attempts at lipofilling, to achieve any improvement in cosmetic outcome.<sup>11</sup> This may be related to ischemia of the recipient area due to scarring and radiotherapy, resulting in poor fat transfer uptake. In contrast, all BCS patients in our series required a single local flap procedure.

Furthermore, local perforator flaps offer a salvage alternative to mastectomy and reconstruction, especially where options may be limited due to a lack of donor tissue, comorbidities, or prior radiotherapy. Implant-based breast reconstruction carries a high rate of revision surgical procedures,<sup>12</sup> particularly following radiotherapy, where capsular contracture can be a significant problem.<sup>13,14</sup> This is also seen even where implant reconstruction has been combined with an autologous flap.<sup>15</sup> Our series demonstrates how local perforator flaps can be used to augment the volume of autologous flaps such as the Latissimus Dorsi flap, without a need for implant placement, thus avoiding further revision procedures, especially in the presence of radiotherapy.

Local flap reconstruction is associated with low donor site morbidity.<sup>3-5</sup> Even in our cohort where 80% had had prior radiotherapy, the vast majority of complications were minor requiring outpatient treatment with antibiotics and/or negative pressure dressings. The 1 patient who required return to theatre had a peri-implant infection rather than a direct complication of the local flap. This complication rate is lower than that seen with other forms of delayed breast reconstruction.<sup>16</sup>

In the longer term, further correctional surgery is unusual. At a median follow-up of 23 months, just 3 patients required further surgery, of which 1 patient underwent lipofilling to further volume match the contralateral breast as a predicted and planned component

of the patient's treatment pathway. In both other cases, further surgery was not directly related to the flap. One patient required lipofilling to the upper pole of their autologous breast reconstruction (DIEP flap) for volume asymmetry, having had local flap reconstruction of the lower pole. The third patient chose to have bilateral larger implants placed to increase the overall volume bilaterally. Our series demonstrates the robustness of the local perforator flap as a single-stage option for corrective partial breast reconstruction, in the majority of cases.

## CONCLUSIONS

In this article, we highlight the versatility of delayed local perforator flaps to correct breast defects following previous surgery. Local perforator flaps perform well when inset into previously irradiated fields, and morbidity rates associated with the procedure are low. Local perforator flaps can be adapted as a novel delayed reconstruction option when faced with potentially complex revisional breast surgery.

*Edel Marie Quinn*

Nightingale Breast Centre  
Wythenshawe Hospital  
Southmoor Road  
Manchester M23 9LT  
United Kingdom  
E-mail: [edelquinn@rcsi.ie](mailto:edelquinn@rcsi.ie)

## REFERENCES

1. Macmillan RD, McCulley SJ. Oncoplastic breast surgery: what, when and for whom? *Curr Breast Cancer Rep.* 2016;8:112-117.
2. Hamdi M, Van Landuyt K, de Frene B, et al. The versatility of the inter-costal artery perforator (ICAP) flaps. *J Plast Reconstr Aesthet Surg.* 2006;59:644-652.
3. Munhoz AM, Montag E, Arruda E, et al. Immediate conservative breast surgery reconstruction with perforator flaps: new challenges in the era of partial mastectomy reconstruction? *Breast.* 2011;20:233-240.
4. Martellani L, Manara M, Renzi N, et al. Use of licap and Itap flaps for breast reconstruction. *Acta Chir Plast.* 2019;60:4-8.
5. Wang X, He YJ, Li JF, et al. Breast conserving surgery with immediate partial breast reconstruction using pedicled thoracodorsal artery perforator flap: a clinical analysis of 33 patients. *Zhonghua Wai Ke Za Zhi.* 2017;55:120-125.

6. Youssif S, Hassan Y, Tohamy A, et al. Pedicled local flaps: a reliable reconstructive tool for partial breast defects. *Gland Surg.* 2019;8:527–536.
7. Hakakian CS, Lockhart RA, Kulber DA, et al. Lateral intercostal artery perforator flap in breast reconstruction: a simplified pedicle permits an expanded role. *Ann Plast Surg.* 2016;76(suppl 3):S184–S190.
8. *National Audit of UK Breast Units. Getting it Right First Time (GIRFT).* In press.
9. Rozen WM, Ashton MW. Radiotherapy and breast reconstruction: oncology, cosmesis and complications. *Gland Surg.* 2012;1:119–127.
10. Ragbir M, Brown JS, Mehanna H. Reconstructive considerations in head and neck surgical oncology: United Kingdom National Multidisciplinary Guidelines. *J Laryngol Otol.* 2016;130(S2):S191–S197.
11. van Turnhout AA, Fuchs S, Lisabeth-Broné K, et al. Surgical outcome and cosmetic results of autologous fat grafting after breast conserving surgery and radiotherapy for breast cancer: a retrospective cohort study of 222 fat grafting sessions in 109 patients. *Aesthetic Plast Surg.* 2017;41:1334–1341.
12. Handel N, Cordray T, Gutierrez J, et al. A long-term study of outcomes, complications and patient satisfaction with breast implants. *Plast Reconstr Surg.* 2007;117:757–767.
13. Whitfield GA, Horan G, Irwin MS, et al. Incidence of severe capsular contracture following implant-based immediate breast reconstruction with or without postoperative chest wall radiotherapy using 40 Gray in 15 fractions. *Radiother Oncol.* 2009;90:141–147.
14. Momoh AO, Ahmed R, Kelley BP, et al. A systematic review of complications of implant-based breast reconstruction with pre-reconstruction and post-reconstruction radiotherapy. *Reconstr Oncol.* 2014;21:118–124.
15. Venus MR, Prinsloo DJ. Immediate breast reconstruction with latissimus dorsi flap and implant: audit of outcomes and patient satisfaction survey. *J Plast Reconstr Aesthet Surg.* 2010;63:101–105.
16. Thorarinsson A, Fröjd V, Kólby L, et al. A retrospective review of the incidence of various complications in different delayed breast reconstruction methods. *J Plast Surg Hand Surg.* 2016;50:25–34.