

# Differentiating between Traumatic Pathology and Congenital Variant: A Case Report of Butterfly Vertebra

Orestis Karargyris, MD, Kalliopi Lampropoulou-Adamidou, MD, Lampros-Guiseppe Morassi, MD, Ioannis P. Stathopoulos, MD, Sofia N. Chatziioannou, MD\*, Spyros G. Pneumaticos, MD

*Third Orthopaedic Department, Faculty of Medicine, University of Athens, KAT General Hospital, Athens,*

*\*Second Department of Radiology, Nuclear Medicine Section, University General Hospital Attikon,*

*National and Kapodistrian University of Athens, Chaidari, Greece*

Butterfly vertebra is a rare congenital malformation of the spine, which is usually reported in the literature as an isolated finding. We describe a 40-year-old woman that presented to our emergency department with back pain and sciatica. Initial radiological evaluation revealed an incidental finding of a L4 butterfly vertebra in the anteroposterior and lateral view radiographs. The patient presented with no neurological deficit. This rare congenital anomaly is usually asymptomatic, and awareness of its non-traumatic nature is critical in order to establish a correct diagnosis. Further evaluation of the patient is necessary to exclude pathologic fracture, infection, or associated vertebral anomalies and syndromes, such as Alagille, Jarcho-Levin, Crouzon, and Pfeiffer syndromes. Furthermore, in the emergency setting, awareness of this entity is needed so that a correct diagnosis can be established.

**Keywords:** *Butterfly vertebra, Vertebral anomalies, Congenital defect, Congenital anomalies, Congenital malformation*

Butterfly vertebra is a rare congenital defect of vertebral body formation characterized by anterior and median aplasia.<sup>1)</sup> The vertebra has a cleft through its body and a funnel shape at the ends that gives the appearance of a butterfly on the anteroposterior (AP) view of a plain radiograph. It may be associated with other congenital syndromes<sup>2-6)</sup> and vertebral anomalies;<sup>7)</sup> however, there are few cases reporting the presence of butterfly vertebra as an incidental finding.<sup>8)</sup> The butterfly vertebra often causes spinal deformities including kyphosis,<sup>9)</sup> but rarely causes neurological symptoms. The orthopedic surgeon has to identify this benign spinal anomaly, which may be confused with a pathologic fracture, infection, or associated vertebral anomalies and syndromes.

In the present report, we describe a 40-year-old

woman that presented to our emergency department after a simple fall with low back pain, left sciatica, and a L4 butterfly vertebra.

## CASE REPORT

A 40-year-old female patient presented to our emergency department after a simple fall. She reported pain upon palpation of the lower lumbar spine and radiating pain to her left buttock and lower leg. The patient reported a history of low back pain and left sciatica, with exacerbation of the symptoms after the fall. Clinically, no neurologic deficit was present. The straight leg raising test was positive on the left side. Simple radiological control of the lumbar spine revealed a sagittal cleft of the body of L4 vertebra on the AP view (Fig. 1A) and a wedge-shaped deformity of the same vertebra on the lateral radiograph (Fig. 1B). Additional hematologic evaluation that included total leukocyte count, erythrocyte sedimentation rate, serum calcium, serum alkaline phosphatase, and serum protein electrophoresis was performed, in order to rule out a pathologic

Received March 10, 2014; Accepted March 31, 2014

Correspondence to: Kalliopi Lampropoulou-Adamidou, MD

Third Orthopaedic Department, KAT General Hospital, Faculty of Medicine, University of Athens, 2 Nikis Str., 14561, Kifissia, Athens, Greece

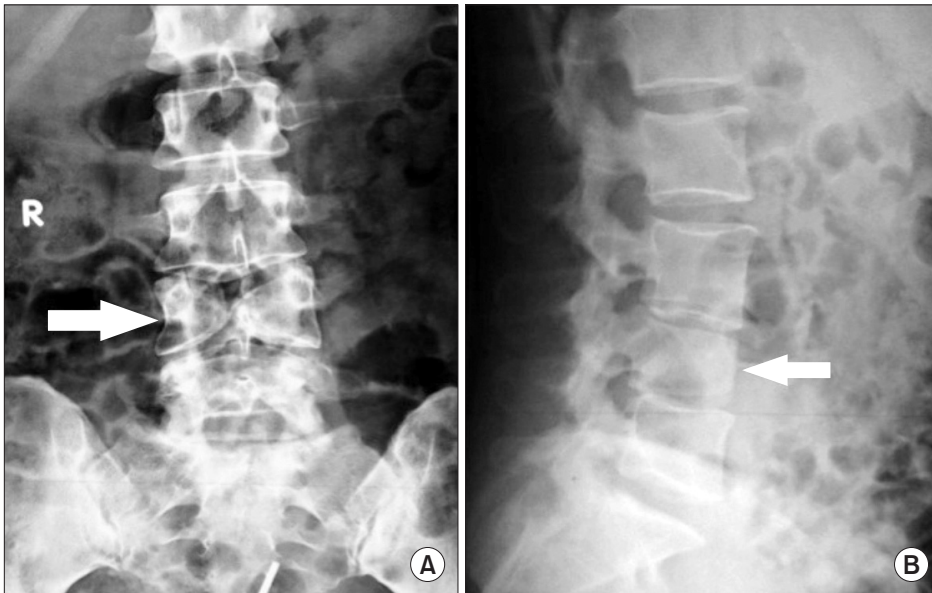Tel: +30-698-42-29-202, Fax: +30-213-20-86-765

E-mail: kilampropoulou@gmail.com

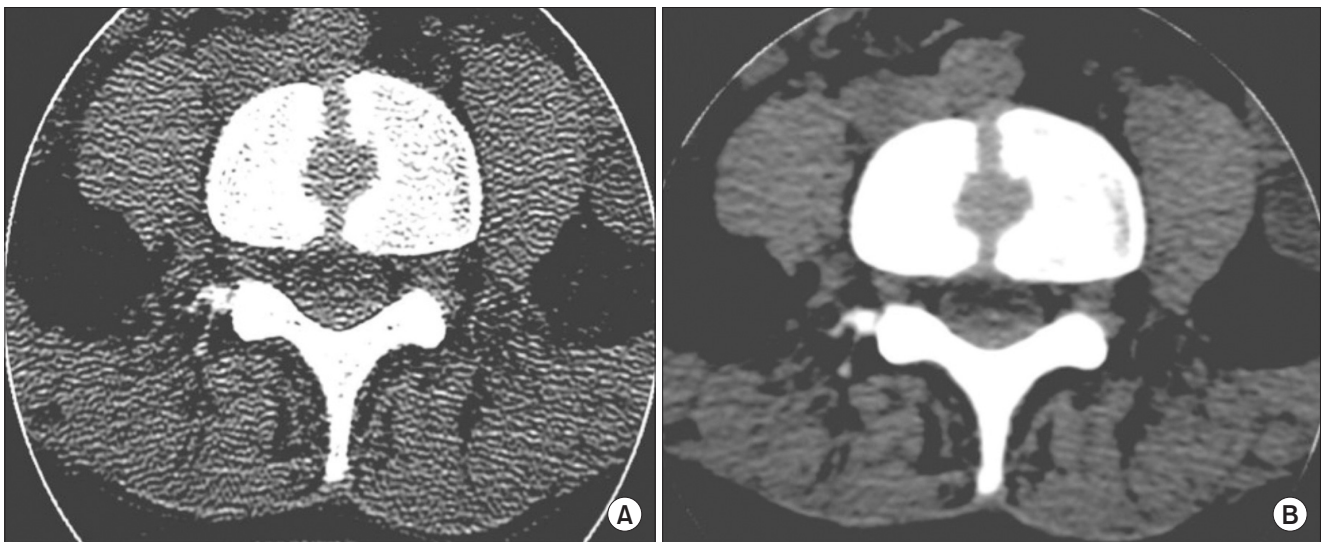
Copyright © 2015 by The Korean Orthopaedic Association

This is an Open Access article distributed under the terms of the Creative Commons Attribution Non-Commercial License (<http://creativecommons.org/licenses/by-nc/4.0>) which permits unrestricted non-commercial use, distribution, and reproduction in any medium, provided the original work is properly cited.

Clinics in Orthopedic Surgery • pISSN 2005-291X eISSN 2005-4408



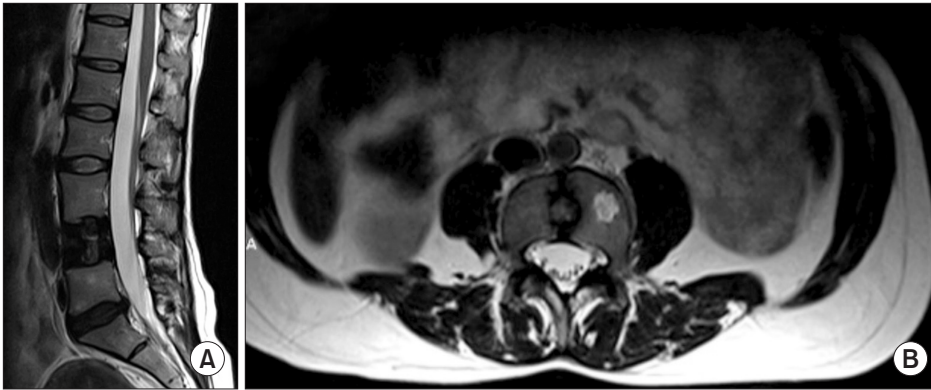
**Fig. 1.** X-ray of the lumbar spine. (A) Anteroposterior view showing L4 butterfly vertebra (arrow). (B) Lateral X-ray of the lumbar spine, demonstrating anterior wedging of the L4 vertebra (arrow), which can be confused with a compression fracture.



**Fig. 2.** (A) Axial computed tomography (CT) scan of the L4 butterfly vertebra (osseous window). A symmetric cleft-like defect of the L4 body is evident. (B) CT scan, axial view of the L4 butterfly vertebra (soft tissue window).

fracture or infection. All values were within normal limits. Computed tomography (CT) imaging of the lumbar spine showed a large, symmetrical cleft-like defect involving the entire vertebral body of L4 with no evidence of canal compression (Fig. 2A). The spinal arch of L4 was intact and no paravertebral soft tissue swelling was evident (Fig. 2B). A posterolateral prolapse of the L5–S1 intervertebral disc was evident, which correlated with the patient's symptoms. The diagnosis of L4 butterfly vertebra was then established. A thorough clinical examination of the patient, the patient's medical history, and her family's medical history did not

reveal any information associated with the incidental finding of the butterfly vertebra. Subsequently, a simple radiological evaluation of the entire spine was performed, in addition to ultrasonography of the heart, urogenital, and hepatobiliary systems, so as to exclude associated congenital abnormalities. A magnetic resonance imaging (MRI) of the lumbar spine reconfirmed the sagittal defect of the L4 vertebral body, occupied by intervertebral disc tissue that included nucleus pulposus material (Fig. 3A). The intervertebral discs L3–L4 and L4–L5 communicated with a bar of disc material which prolapsed in the cleft of the L4



**Fig. 3.** (A) T2-weighted sagittal magnetic resonance imaging (MRI) of the lumbar spine, clearly showing a central defect in the L4 body, occupied by disc material. (B) Axial T2-weighted MRI of the same L4 butterfly vertebra confirming a symmetrical defect of the vertebral body occupied by disc material. Incidentally, a hemangioma on the left part of the L4 body was noted.

body. Incidentally, a hemangioma was found to be present in the body of L4 vertebra (Fig. 3B).

The patient was treated for her low back pain with analgesics and physiotherapy. The benign nature of the butterfly vertebra was explained to her and she was informed that no further treatment was required. Treatment of the L5–S1 disc prolapse was deferred for a later stage.

## DISCUSSION

Butterfly vertebra is usually an asymptomatic and isolated finding. However, it may be associated with other congenital anomalies such as Mullerian hypoplasia/aplasia,<sup>2)</sup> Alagille syndrome,<sup>3)</sup> Jarcho-Levin syndrome,<sup>4)</sup> Crouzon syndrome,<sup>5)</sup> and Pfeiffer syndrome.<sup>6)</sup>

This defect is thought to occur between the third and sixth week of embryonic development. The vertebral body is formed by the fusion of two lateral sclerotomes that derive from the somites. Failure of the fusion of the two sclerotomes results in the formation of butterfly vertebra.<sup>1)</sup> Butterfly vertebrae is seen predominantly in the lumbar spine.<sup>1)</sup>

In this case, the patient did not present with features of any known associated syndromes. Further evaluation with CT and MRI for other vertebral anomalies such as supernumerary lumbar vertebrae, spina bifida, diastematomyelia, and kyphoscoliosis, which could be associated with butterfly vertebra<sup>7)</sup> were all negative.

In simple AP radiographs, the butterfly shape of the body of the vertebra is easily identifiable, while the pedicles may look divergent. In the lateral X-ray view, the butterfly vertebra usually presents with as a wedge-shaped

deformity, which may be confused for a compression fracture. That is the reason why the AP radiographic view is particularly useful in establishing the diagnosis. In case of doubt, or in the setting of previous trauma, a CT scan is indicated.<sup>10)</sup> An MRI may show possible degenerative changes of the overlying and underlying intervertebral discs, as well as the presence of disc material in the body defect of the butterfly vertebra. This can be explained by the ectopic development of disc tissue caused by the deficiency of sclerotomic substance during gestation.<sup>1)</sup> The degenerative changes of the intervertebral discs above and below the butterfly vertebra are suggestive of possible altered biomechanics in the spine. To our knowledge, there are no data regarding the long-term effects of this condition on the stability of the spinal elements.

The congenital malformation of the butterfly vertebra is usually isolated. However, a thorough clinical examination of the patient, a detailed family history and, if necessary, additional imaging and laboratory evaluation may be needed in order to exclude pathologic fracture, infection, and congenital anomalies which are associated with this malformation. Furthermore, in the emergency setting, awareness of this entity is needed so that a correct diagnosis can be established efficiently.

## CONFLICT OF INTEREST

No potential conflict of interest relevant to this article was reported.

## REFERENCES

1. Muller F, O'Rahilly R, Benson DR. The early origin of vertebral anomalies, as illustrated by a 'butterfly vertebra'. *J Anat.* 1986;149:157-69.
2. Mahajan P, Kher A, Khungar A, Bhat M, Sanklecha M, Bharucha BA. MURCS association: a review of 7 cases. *J Postgrad Med.* 1992;38(3):109-11.
3. Alagille D, Estrada A, Hadchouel M, Gautier M, Odievre M, Dommergues JP. Syndromic paucity of interlobular bile ducts (Alagille syndrome or arteriohepatic dysplasia): review of 80 cases. *J Pediatr.* 1987;110(2):195-200.
4. McCall CP, Hudgins L, Cloutier M, Greenstein RM, Cassidy SB. Jarcho-Levin syndrome: unusual survival in a classical case. *Am J Med Genet.* 1994;49(3):328-32.
5. Anderson PJ, Hall C, Evans RD, Harkness WJ, Hayward RD, Jones BM. The cervical spine in Crouzon syndrome. *Spine (Phila Pa 1976).* 1997;22(4):402-5.
6. Anderson PJ, Hall CM, Evans RD, Jones BM, Harkness W, Hayward RD. Cervical spine in Pfeiffer's syndrome. *J Craniofac Surg.* 1996;7(4):275-9.
7. Sepulveda W, Kyle PM, Hassan J, Weiner E. Prenatal diagnosis of diastematomyelia: case reports and review of the literature. *Prenat Diagn.* 1997;17(2):161-5.
8. Cho HL, Kim JS, Paeng SS, Lee SH. Butterfly vertebra with lumbar intervertebral disc herniation. *J Neurosurg Spine.* 2011;15(5):567-70.
9. McMaster MJ, Singh H. Natural history of congenital kyphosis and kyphoscoliosis: a study of one hundred and twelve patients. *J Bone Joint Surg Am.* 1999;81(10):1367-83.
10. Garcia F, Florez MT, Conejero JA. A butterfly vertebra or a wedge fracture? *Int Orthop.* 1993;17(1):7-10.