

# Early Cleft Lip Repair Revisited: A Safe and Effective Approach Utilizing a Multidisciplinary Protocol

Jeff A. Hammoudeh, MD, DDS\*†  
 Thomas A. Imahiyerobo, MD†  
 Fan Liang, MD†  
 Artur Fahradyan, MD\*  
 Leo Urbinelli, MD\*  
 Jennifer Lau, MD§  
 Marla Matar, MD§  
 William Magee, III, MD, DDS\*†  
 Mark Urata, MD, DDS, FACS,  
 FAAP\*†

**Background:** The optimal timing for cleft lip repair has yet to be established. Advances in neonatal anesthesia, along with a growing body of literature, suggesting benefits of earlier cleft lip and nasal repair, have set the stage for a reexamination of current practices.

**Methods:** In this prospective study, cleft lip and nasal repair occurred on average at 34.8 days (13–69 days). Nasal correction was achieved primarily through molding the nasal cartilage without the placement of nasal sutures at the time of repair. A standardized anesthetic protocol aimed at limiting neurotoxicity was utilized in all cases. Anesthetic and postoperative complications were assessed. A 3-dimensional nasal analysis compared pre- and postoperative nasal symmetry for unilateral clefts. Surveys assessed familial response to repair.

**Results:** Thirty-two patients were included (27 unilateral and 5 bilateral clefts). In this study, the overall complication rate was 3.1%. Anthropometric measurements taken from 3-dimensional-image models showed statistically significant improvement in ratios of nostril height (preoperative mean, 0.59; postoperative mean, 0.80), nasal base width (preoperative mean, 1.96; postoperative mean, 1.12), columella length (preoperative mean, 0.62; postoperative mean, 0.89; and columella angle (preoperative mean, 30.73; postoperative mean, 9.1). Survey data indicated that families uniformly preferred earlier repair.

**Conclusions:** We present evidence that early cleft lip and nasal repair can be performed safely and is effective at improving nasal symmetry without the placement of any nasal sutures. Utilization of this protocol has the potential to be a paradigm shift in the treatment of cleft lip and nasal deformity. (*Plast Reconstr Surg Glob Open* 2017;5:e1340; doi: 10.1097/GOX.0000000000001340; Published online 26 June 2017.)

## INTRODUCTION

The optimal timing for cleft lip and nasal repair has yet to be established.<sup>1,2</sup> Although support in the literature for primary repair ranges from 2 days of life to as late as 1 year, the majority of cleft centers in the United

States recommend the “traditional timeline” with repair performed between 3 and 6 months of age.<sup>1–3</sup> Though this is a time-honored approach, there is an overall lack of objective validation and indeed, some of the supporting evidence for this timing may be dated. Historically, these recommendations are often attributed to the “Rule of 10’s,” which derive primarily from publications by Millard, as well as Wilhelmsen and Musgrave<sup>4</sup>, on complications following primary cleft surgery.<sup>2–4</sup> In their 1966 retrospective study, William and Musgrave<sup>4</sup> described a postoperative complication rate that was 5 times higher in patients who did not meet the “Rule of 10’s”: that is they weighed less than 10 pounds, had a hemoglobin of less than 10g/dl, or a white blood cell count of less than 10.<sup>2</sup> Limitations in preoperative screening, available techniques for anesthesia, and technical considerations were implicated as contributing factors.<sup>2,4</sup> As the majority of patients will not reach the proposed parameters until 3–6 months of age, the pervasive doctrine has thus been to delay repair until this time. However, over the last 50 years, advances have been made in techniques for prena-

From the \*Division of Plastic Surgery, Children’s Hospital Los Angeles, Calif.; †Division of Plastic and Reconstructive Surgery, Keck School of Medicine at USC, Calif.; ‡Division of Plastic Surgery, New York Presbyterian Hospital—Columbia University Medical Center, N.Y.; and §Department of Anesthesiology, Children’s Hospital Los Angeles, Calif.

Received for publication January 3, 2017; accepted March 31, 2017.

Presented in part at the 73rd Annual Meeting of the American Cleft Palate-Craniofacial Association.

This study was approved by the Institutional Review Board (IRB) at Children’s Hospital Los Angeles (Protocol #: CCF-14-00001).

Copyright © 2017 The Authors. Published by Wolters Kluwer Health, Inc. on behalf of The American Society of Plastic Surgeons. This is an open-access article distributed under the terms of the Creative Commons Attribution-Non Commercial-No Derivatives License 4.0 (CCBY-NC-ND), where it is permissible to download and share the work provided it is properly cited. The work cannot be changed in any way or used commercially without permission from the journal.

DOI: 10.1097/GOX.0000000000001340

**Disclosure:** The authors have no financial interest to declare in relation to the content of this article. The Article Processing Charge was paid for by the authors.

tal screening of cleft lip and associated anomalies.<sup>5,6</sup> Similarly, anesthetic delivery during the neonatal period has also grown more sophisticated.<sup>7,8</sup> Multiple studies have also demonstrated the feasibility of performing cleft lip surgery at an earlier time.<sup>9–12</sup> Given these developments, we question whether a delay in repair until 3–6 months of age is still necessary.

Early cleft lip repair may provide additional benefits such as improved appearance of surgical scars, accelerated weight gain from ease of feeding, and heightened maternal-infant socialization.<sup>13–17</sup> Less well described, but an equally significant advantage, is the potential greater capacity for correction of the cleft nasal deformity. Repair within the neonatal period takes advantage of the high degree of plasticity within the cleft nasal cartilage and may allow for recapitulation of a more normal nasal morphology. Ear molding, for example, has illustrated that neonatal cartilage is malleable within the first 6 weeks of life.<sup>18–24</sup> This had been attributed to elevated levels of circulating maternal estrogen, stimulating an overproduction of hyaluronic acid, as well as elevated gradients of transforming growth factor-beta.<sup>25,26</sup> This neonatal milieu allows for molding of cleft nasal cartilage in an analogous fashion. Indeed, attempts at total nonsurgical correction of the cleft nasal deformity by means of presurgical nasal molding have been described with some success.<sup>27,28</sup> It serves to reason then that early intervention on the nose may also lead to improved nasal conformation by arresting the progressive nasal deformity, which has been noted to occur in the neonatal period.<sup>28</sup>

The value of early intervention to improve the results of cleft nasal repair is demonstrated by the growing number of reports, which detail persistent nasal asymmetry following traditional cleft lip repair.<sup>29–32</sup> Although secondary rhinoplasty has been shown to be an effective means of improving persistent stigmata of the cleft nasal deformity, efforts to improve primary outcomes might obviate the need for such measures.<sup>33–35</sup> To date, nasoalveolar molding (NAM) and other types of presurgical nasal molding represent our best attempts at optimizing cleft nasal outcomes.<sup>36–38</sup> Long-term follow-up using these techniques has shown a decrease in secondary rhinoplasty and cleft lip revision rates, with resultant decreases in overall healthcare costs.<sup>39</sup> These findings again underscore the potential value of improving results during primary cleft lip and nasal repair.

Currently, what is lacking is a consensus protocol for safe and effective early cleft lip and nasal repair. Ideally, such a protocol should be prospectively designed with objective outcome measurements and take into account safety parameters for mitigating both anesthesia and surgical complications. Given this, we herein present our initial results from a prospective study of a multidisciplinary protocol for safe and effective early cleft lip and nasal repair.

## PATIENTS AND METHODS

### Demographics

This prospective study was approved by the Institutional Review Board at Children's Hospital Los Angeles and included infants who presented to the Division of Plastic and Maxillofacial Surgery between February 2015 and March 2016. Families were offered the option of early surgical repair and traditional repair done after 3 months of age with full disclosure of the potential anesthetic and surgical risks associated with earlier repair. All study subjects underwent screening for associated major congenital anomalies and a preoperative anesthesia evaluation. Inclusion criteria were as follows: infants without major comorbidities (American Society of Anesthesiologist class I or class II designation), diagnosis of nonsyndromic cleft lip or cleft lip and palate and caregivers electing to have early repair. Patients who had received presurgical NAM were excluded from the study.

Thirty-four children were initially enrolled in the study. Two subjects were removed from the study because of late diagnosis of immunodeficiency and surgical postponement due to an upper respiratory tract infection. The mean age at the time of surgery for the remaining 32 children was 34.8 days (range, 13–69 days). There were 20 female and 12 male subjects with a mean body weight of 4.06 kg at the time of surgery. Ten patients were diagnosed with right unilateral cleft lip/unilateral cleft lip and palate, 17 with left unilateral cleft lip/unilateral cleft lip and palate, and 5 with bilateral cleft lip/bilateral cleft lip and palate. The average follow-up time was 47 weeks (range, 6–95 weeks). Infants were eligible for cleft repair after 2 weeks of life, which corresponded to the end of the transient catabolic state characteristic to the early neonatal period.

### Study Design

3D images were obtained (3dMD LLC, Atlanta, Ga.) to document pre- and postoperative anatomy. Images were taken at defined intervals, which included preoperative imaging at the time of recruitment, postoperative imaging 2 weeks after stent removal, 6 weeks after stent removal, 6 months postoperative, and 1 year postoperative.

### Anesthetic Protocol

All patients for this study underwent repair under general anesthesia under the supervision of 2 members of the Anesthesia Department at Children's Hospital Los Angeles. The anesthetic approach was modified to limit exposure to agents, which have been indicated to cause cell apoptosis (i.e., volatiles agents, ketamine, propofol, etomidate, barbituates, and benzodiazepines). The exception was a very short course of inhaled sevoflurane, a volatile agent, for induction and IV placement.

### Anthropometric Measurements

A 3D nasal analysis was performed to assess the improvement in nasal symmetry before and after surgery. Standardized anthropometric points were obtained for all patients with unilateral cleft lip and nasal deformity. Four measures were tracked pre- and postoperatively: nasal

base width, nostril height, columella length, and columella angle. The anthropometrics points were determined according to the following guidelines (Fig. 1):

- Nasal base width—distance between the subalare (midpoint of lateral nasal base) and the ipsilateral lateral aspect of the columella base;
- Nostril height—distance between subalare and the most caudal aspect of the mid-point of the soft triangle;
- Columella length—distance between the lateral aspect of the columella base, where it meets the lip, and the junction of the middle crus and the columella on the ipsilateral side;
- Columella angle—the angle between the columella and the sagittal plane.

### Analysis

3D images were analyzed by 2 independent blinded surgeon investigators using 3dMD vultus software (3dMD LLC, Atlanta, Ga.). To standardize results, the absolute measurements were converted to ratios. Cleft to noncleft side ratios were calculated for nasal base width, nostril height, and columella length, with the ideal ratio being 1 in a perfectly symmetric nose. For columella angle, cleft to normal columella angle ratio was calculated. Note that normal columella angle with sagittal plane in a perfectly symmetric nose should be 0 degree, but for mathematical purposes it was considered to be 1 degree.

Statistical analysis was done using SPSS 17.0 (SPSS Inc., Chicago, Ill.). The measurements were analyzed for interinvestigator correlation using the Interclass Correlation Coefficient (ICC). The ICC was above 0.7 across all 8 measurements indicating good correlation. Therefore, the average of the 2 investigator's measurements was utilized for the final statistics and analyzed with paired *t* test to compare the pre- and postoperative results.

Complications related to anesthesia and surgery were recorded. Anesthesia-related complications were categorized as major or minor. Intraoperative and postoperative complications were also tracked. Surveys were sent to families at 6 months postoperatively to evaluate their response to repair.

### Surgical Technique

A modified subunit repair was utilized in all cases of unilateral cleft lip (Fig. 2). Under loupe magnification, points for the height, depth, and height of Cupid's bow are defined. The opening incision of the medial lip element is chosen to mimic the slope of the noncleft side philtral column. The total lip length as defined by the distance from the noncleft side peak of Cupid's bow to the lip-columellar junction is approximated on the lateral lip element by the distance from Noordhoff's point to the point of closure along the nostril sill. A laterally based triangle flap can be utilized to augment the cleft side philtral length and further balance Cupid's bow.<sup>40</sup> The approach to the cleft nasal deformity relied exclusively on primary molding of the cleft nasal cartilage to affect the desired change. To prevent confounding, we elected not to place any sutures in the nose, including McComb sutures, elevating sutures or quilting sutures, or interdomal sutures. For manipulation of the nasal cartilage, a marginal incision was made on the cleft side to identify the lower lateral cartilage. The cartilage was then mobilized, and overlying fibrofatty tissue was removed to facilitate cartilage elevation as previously described by Patel and Mulliken<sup>41</sup> (Fig. 3). The marginal incision also provided access for disruption of the aberrant attachments to the cleft side alae cartilage. After completion of the cleft lip and nasal repair, a semi-rigid stent was secured in place and left for a period of 4–6 weeks (Fig. 4).

### RESULTS

Improvement of nasal asymmetry was seen in all 4 measurements. All changes were statistically significant with  $P < 0.0001$  (Figs. 5–8). The mean columella angle ratio improved from 30.83 degree to 9.1 and nasal base width ratio improved from 1.96 to 1.12. These data indicated that on average the preoperative cleft side nasal base were nearly twice as wide as the noncleft side but nearly identical postoperatively. The preoperative mean columella length ratio was 0.62, which improved to 0.89, suggesting better nasal symmetry. Similar improvement was observed in the nostril height ratio, which improved from 0.59 to

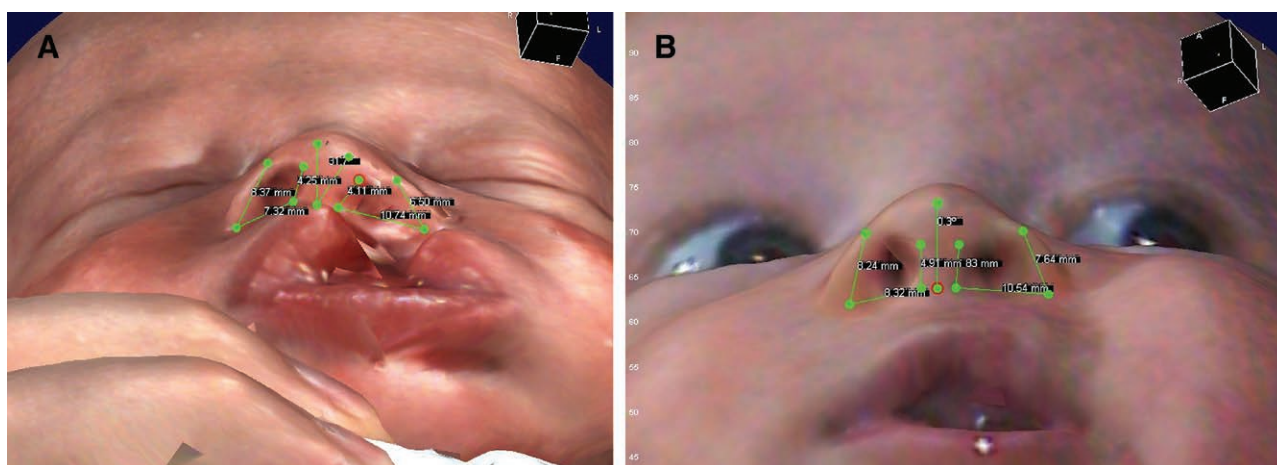
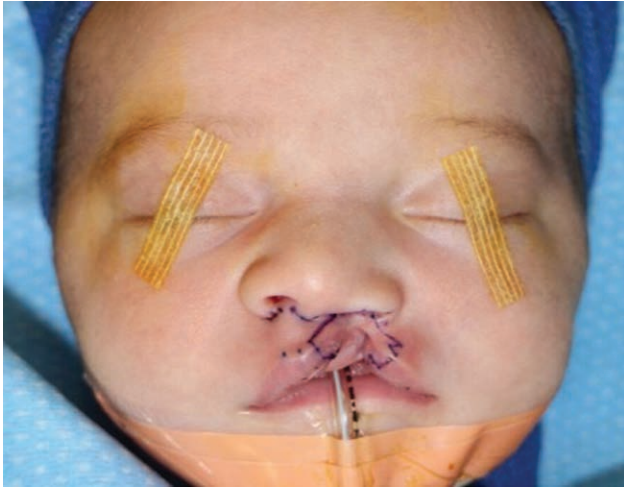
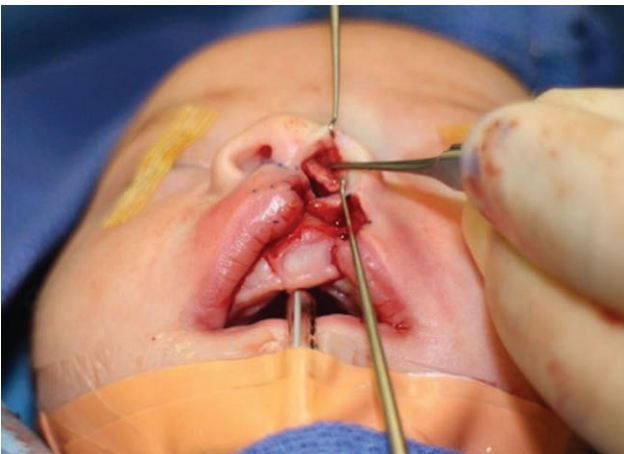
Fig. 1. Preoperative (A) and postoperative (B) anthropometric points demonstrated on 3D images.

0.8. A smaller degree of improvement was noted in columella length and nostril height symmetry compared with columella angle and nasal base width. It should be noted



**Fig. 2.** Preoperative markings.



**Fig. 3.** Nasal cartilage exposure and mobilization.

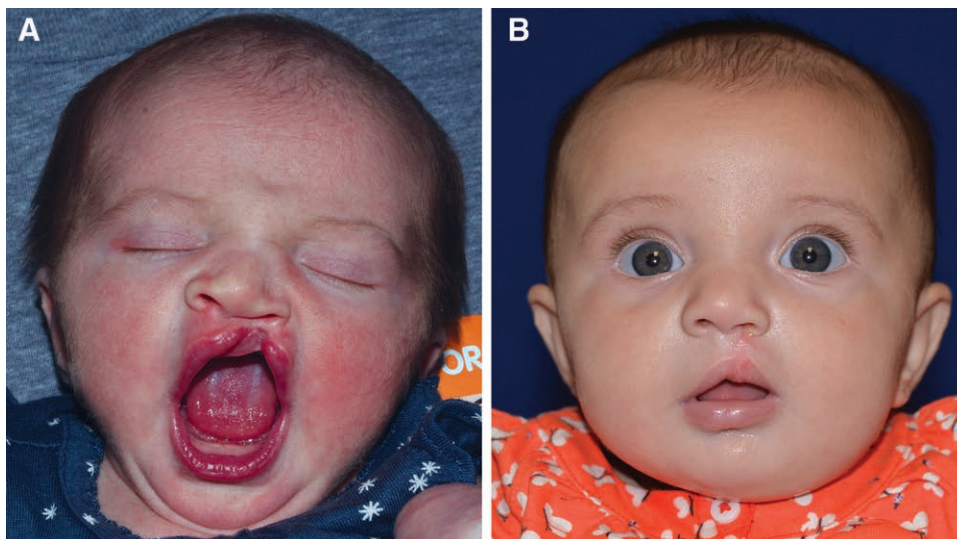that our sample consisted of a broad range of clefts including mild microform to severe wide clefts (Figs. 9, 10). Although good symmetry was achieved in all types of clefts, the milder clefts were characterized with less asymmetry in columella length and nostril height, preoperatively. Therefore, the absolute degree of changes were smaller, whereas the preoperative asymmetry was more prominent in wide clefts, hence the greater degree of postoperative changes achieving similar results.

The overall anesthetic-related complication rate was 3.1% and resulted from 1 patient who sustained prolonged emergence from anesthesia (> 30 minutes off Precedex) that resolved without further intervention. We considered this a minor anesthetic-related complication. There were no major anesthetic-related complications. Specifically, there were no difficult intubations, inability to intubate with standard techniques, prolonged intraoperative desaturation (< 85% SPO<sub>2</sub>), evidence of fetal circulation, sustained laryngospasm, or reintubations. The surgery-related complications rate was also 3.1% and involved 1 patient who had dehiscence of a wide bilateral cleft repair. After this incident, we largely excluded wide bilateral cleft patients from consideration for this technique. Thereafter, no other surgical complications were observed.

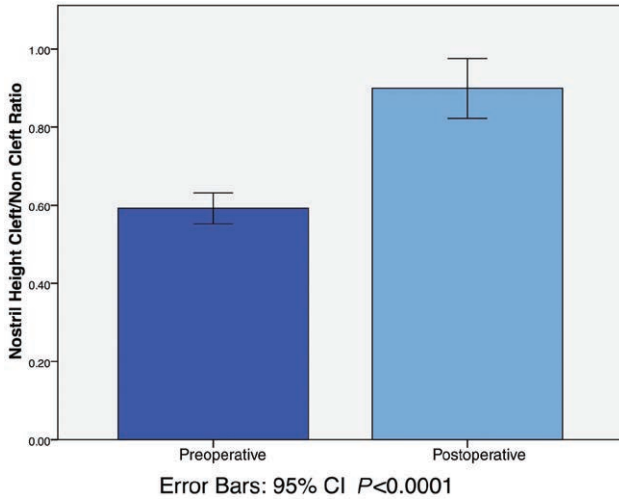
Postoperative survey results were completed by 60% of the caregivers at approximately 6 months postoperatively. In total, 94.7% of survey respondents were either very or mostly satisfied with results, 5.3% of families were somewhat satisfied with the results, and there were no families who were dissatisfied. When questioned regarding the ideal timing of the cleft lip and nasal repair, parents uniformly reported their preference to be before the age of 2 months, consistent with an early repair.

## DISCUSSION

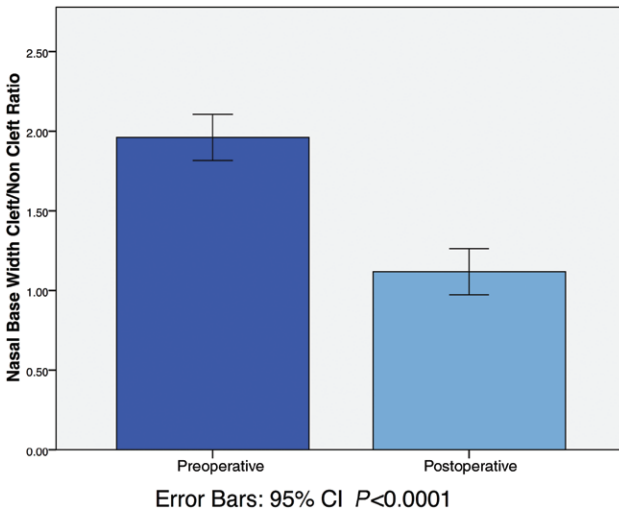
For many years the “Rule of 10’s” was viewed as the most appropriate timing directive for elective cleft lip surgery.<sup>2,4</sup> Until recently, we have followed this tradition without exploring the possibility of whether earlier cleft



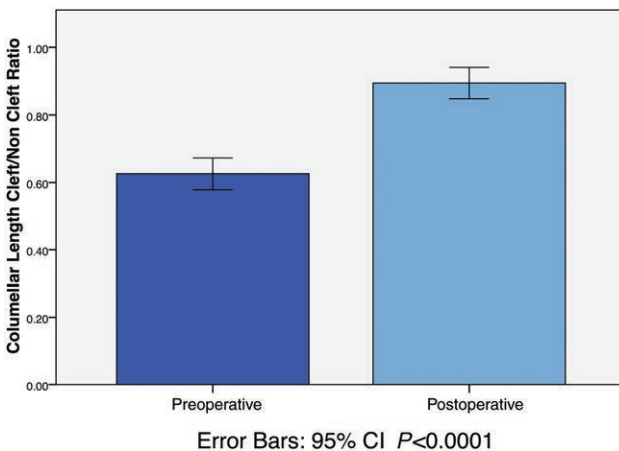
**Fig. 4.** Preoperative (A) and 3-month postoperative (B) photographs; repair performed at 4 weeks.



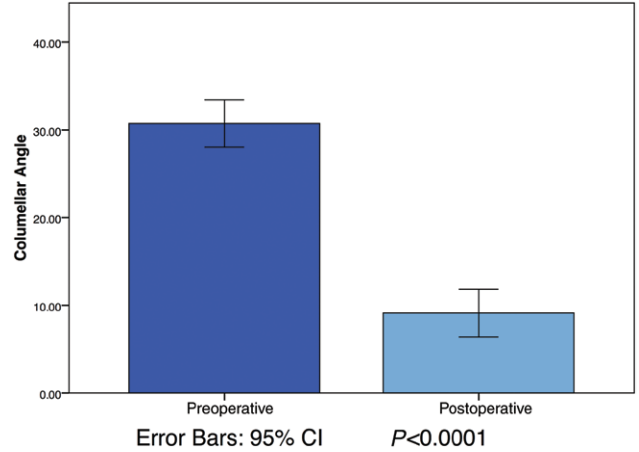
**Fig. 5.** Nostril height ratio: preoperative to postoperative improvement.



**Fig. 6.** Nostril base width ratio: preoperative to postoperative improvement.



**Fig. 7.** Columellar length ratio: preoperative to postoperative improvement.

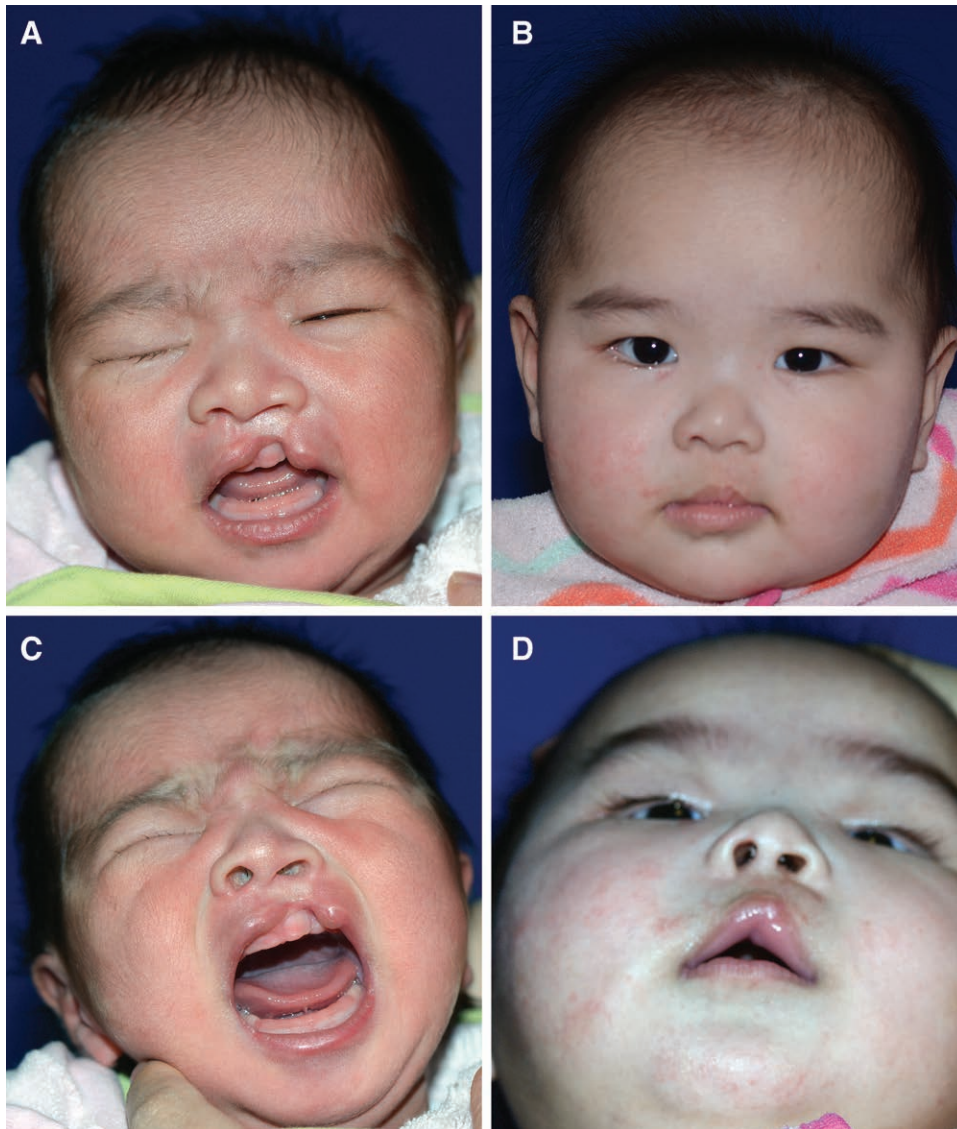

**Fig. 8.** Columellar angle: preoperative to postoperative improvement.

surgery could be safe and more effective. Here, we present evidence to counter the Rule of 10's, based on results of a prospective study of more than 30 consecutive early cleft lip and nasal repairs. We have shown that operating early, even within the neonatal period, can be both safe and effective. Our study challenges the current treatment paradigm, which delays cleft lip and nasal repair until 3–6 months.

The motivation for this study is born from our and others' observations with NAM and ear molding.<sup>18,19,36,42</sup> NAM has shown us that targeted forces applied to the nasal cartilage during the neonatal period can lead to a normalization of the nasal anatomy.<sup>42</sup> This study does not call into question NAM's efficacy; however, this efficacy is reliant on compliance with a strict follow-up schedule, which is not practical in all instances. Therefore, in this study, patients who had undergone NAM were excluded from the study population. This relieved parents from weekly visits for NAM adjustments and obviated the use of a bulky appliance.

Our hope was that intervening during the neonatal period when cartilage is most moldable would facilitate our repair and lead to long-lasting symmetry. Furthermore, by intervening early and releasing the well-described anomalous muscular attachments from the nasal ala, columella, and septum, we might theoretically arrest the progressive cleft lip and nasal deformity and in a sense attend to a less severe cleft than what we would have faced at 3–6 months. The growing field of fetoscopic-surgery has shown us that in many areas earlier intervention can lead to improvements in long-term outcomes.<sup>43–45</sup> Although fetal repair of the cleft lip and palate has not yet become a clinical reality, work by Longaker and Adzick<sup>46</sup> has demonstrated a marked improvement in surgical scars when repair is performed in-utero. It may be possible that similar benefits can be obtained during the privileged environment of the neonatal period (Fig. 11). Indeed, in our study, we were able to achieve a statistically significant correction of the cleft nasal deformity primarily through nasal molding alone. This obviates the need for placement of the typical nasal sutures



**Fig. 9.** Preoperative and 3-month postoperative photographs; repair performed at 4 weeks.

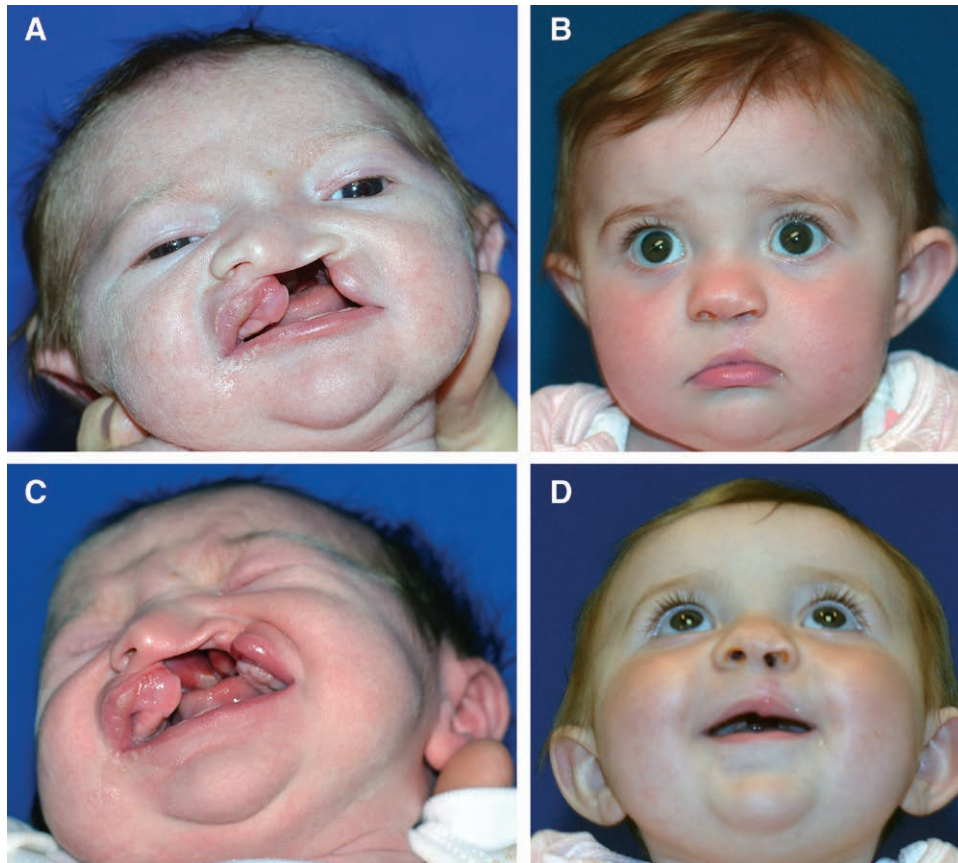(McComb sutures, interdomal sutures, elevating sutures, or quilting sutures) during primary cleft nasal repair.

Appropriate concerns have been raised about the safety of anesthesia during the neonatal period.<sup>47</sup> Chief among these are reports from the anesthesia literature, indicating possible return to fetal circulation and increased anesthetic risk.<sup>7,8</sup> However, advances in neonatal anesthesia may have mitigated many of these concerns. Indeed, a review of the anesthesia literature surrounding early cleft lip repair indicates complication rates similar to standard repair.<sup>7</sup> Similarly, in this series, we also did not note an increase in anesthetic or surgical complications as compared with rates historically seen at our institution. Though this still needs to be validated by a more rigorous case control format, it did substantiate continued progression of the study.

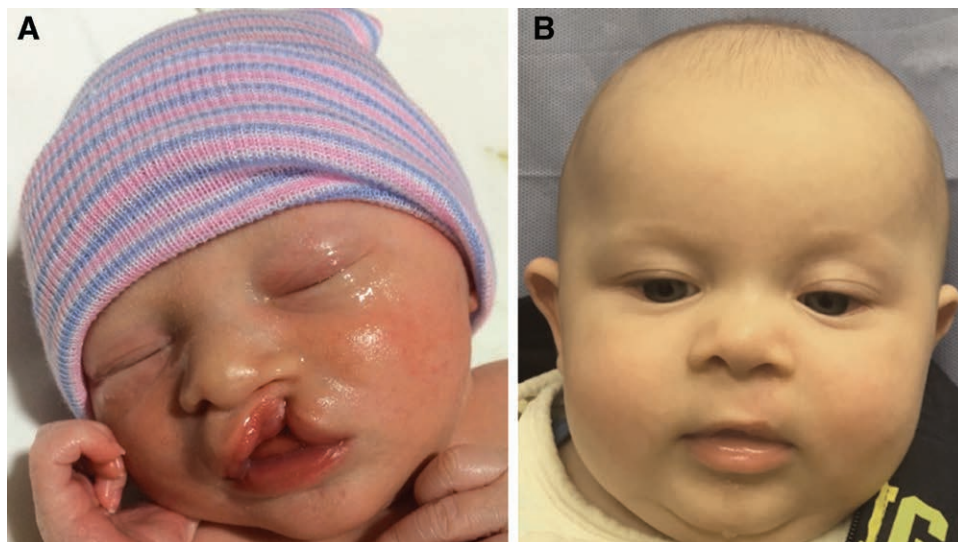Our anesthetic protocol considered the impact of anesthetic-induced cell apoptosis. The protocol included a short exposure to a volatile agent (70% nitrous oxide and

up to 3.5 MAC of sevoflurane) until an intravenous line was placed. After induction, the anesthetic was transitioned to total intravenous anesthesia with dexmedetomidine, remifentanyl, fentanyl, and rocuronium. Although very few patients required postoperative pain medication in the post anesthesia care unit (a benefit of opioid-sparing from dexmedetomidine), morphine sulfate was administered prn.

Study limitations include a small sample size, a single institution, and nonrandomization. Additionally, this study's broad applicability is limited by the fact that only 2 anesthesiologists participated in our study and adhered to the same anesthetic protocols. This protocol may not safely or effectively be performed at a facility without highly experienced pediatric anesthesiology colleagues along with the support of a modernized pediatric intensive care unit, should complications develop. We have also not yet shown this early repair protocol to be superior to the traditional 3–6-month-old child's repair through rigorous case control comparison. Other future opportunities for inves-



**Fig. 10.** Preoperative and 3-month postoperative photographs; repair performed at 4 weeks.



**Fig. 11.** Preoperative (A) and 3-month postoperative (B) photographs; repair performed at 2 weeks.

tigation include evaluation of long-term results, involving lip revision and secondary nasal surgery rates.

Our group submits this study as a prospective report, which challenges the status quo in consideration for alternative timing for the repair of the cleft lip and nasal deformity. Through this experience, we have developed

a protocol for safe and effective cleft lip and nasal repair. Family surveys postoperatively have unanimously been positive, with over 94% of families satisfied with their child's repair and no families who were dissatisfied. Furthermore, all families indicated that they would prefer earlier repair even if the results were only equivalent to traditional late

repair. Hypothetically, early repair allowed the families to move past the cleft deformity sooner and move toward a road of healing, feeding, and bonding.

## CONCLUSIONS

Although early cleft lip repair has been undertaken in the past, a protocol for safe and effective execution is lacking. Here, we present a large prospective study that utilizes a multidisciplinary approach to address many of the proposed barriers to early repair of the cleft lip. We also present evidence to suggest that early cleft lip repairs can be performed safely and is effective at improving postoperative nasal symmetry. Although longer term studies are still needed to compare results of this approach with the traditional approach, survey data suggest that parents would prefer earlier repair. In response to these results, we have updated our institutional paradigm to include cleft lip and nasal repair as early as 14 days of life. With increased experience, longer term data, and increased awareness of this option, we feel that our protocol for early cleft lip/nasal repair has the potential to be a paradigm shift in our treatment of the cleft lip/nasal deformity.

Jeff A. Hammoudeh, MD, DDS

Division of Plastic and Maxillofacial Surgery  
Children's Hospital of Los Angeles  
4650 West Sunset Boulevard  
Mailstop 96 Los Angeles, CA 90033  
E-mail: JHammoudeh@chla.usc.edu

## PATIENT CONSENT

Parents or guardians provided written consent for the use of the patients' image.

## REFERENCES

- Kobus K, Kobus-Zalesna K. Timing of cleft lip and palate repair. *Dev Period Med.* 2014;18:79–83.
- Chow I, Purnell CA, Hanwright PJ, et al. Evaluating the rule of 10s in cleft lip repair: do data support dogma? *Plast Reconstr Surg.* 2016;138:670–679.
- Greives MR, Camison L, Losee JE. Evidence-based medicine: unilateral cleft lip and nose repair. *Plast Reconstr Surg.* 2014;134:1372–1380.
- Wilhelmsen HR, Musgrave RH. Complications of cleft lip surgery. *Cleft Palate J.* 1966;3:223–231.
- Gillham JC, Anand S, Bullen PJ. Antenatal detection of cleft lip with or without cleft palate: incidence of associated chromosomal and structural anomalies. *Ultrasound Obstet Gynecol.* 2009;34:410–415.
- James JN, Schlieder DW. Prenatal counseling, ultrasound diagnosis, and the role of maternal-fetal medicine of the cleft lip and palate patient. *Oral Maxillofac Surg Clin North Am.* 2016;28:145–151.
- Galiniere P, Salazard B, Deberail A, et al. Neonatal repair of cleft lip: a decision-making protocol. *J Pediatr Surg.* 2008;43:662–667.
- Harris PA, Oliver NK, Slater P, et al. Safety of neonatal cleft lip repair. *J Plast Surg Hand Surg.* 2010;44:231–236.
- Nakajima T, Yoshimura Y. Early repair of unilateral cleft lip employing a small triangular flap method and primary nasal correction. *Br J Plast Surg.* 1993;46:616–618.
- Matsuo K, Hirose T. Nonsurgical correction of cleft lip nasal deformity in the early neonate. *Ann Acad Med Singapore.* 1988;17:358–365.
- McHeik JN, Sfalli P, Bondonny JM, et al. Early repair for infants with cleft lip and nose. *Int J Pediatr Otorhinolaryngol.* 2006;70:1785–1790.
- Erdmann MW, Waterhouse N. Neonatal cleft lip repair. *J R Soc Med.* 1992;85:108–109.
- Murray L, Hentges F, Hill J, et al.; Cleft Lip and Palate Study Team. The effect of cleft lip and palate, and the timing of lip repair on mother-infant interactions and infant development. *J Child Psychol Psychiatry.* 2008;49:115–123.
- Weatherley-White RC, Kuehn DP, Mirrett P, et al. Early repair and breast-feeding for infants with cleft lip. *Plast Reconstr Surg.* 1987;79:879–887.
- Petráčeková I, Zach J, Borský J, et al. Early and late operation of cleft lip and intelligence quotient and psychosocial development in 3-7 years. *Early Hum Dev.* 2015;91:149–152.
- McHeik JN, Levard G. Growth in infants in the first two years of life after neonatal repair for unilateral cleft lip and palate. *Int J Pediatr Otorhinolaryngol.* 2010;74:465–468.
- Boon L, Manicourt D, Marbaix E, et al. A comparative analysis of healing of surgical cleft lip corrected in utero and neonates. *Plast Reconstr Surg.* 1992;89:11–7; discussion 18.
- Matsuo K, Hirose T, Tomono T, et al. Nonsurgical correction of congenital auricular deformities in the early neonate: a preliminary report. *Plast Reconstr Surg.* 1984;73:38–51.
- Brown FE, Colen LB, Addante RR, et al. Correction of congenital auricular deformities by splinting in the neonatal period. *Pediatrics.* 1986;78:406–411.
- Tan S, Wright A, Hemphill A, et al. Correction of deformational auricular anomalies by moulding—results of a fast-track service. *N Z Med J.* 2003;116:U584.
- Kenny FM, Angsusingha K, Stinson D, et al. Unconjugated estrogens in the perinatal period. *Pediatr Res.* 1973;7:826–831.
- Hardingham TE, Muir H. The specific interaction of hyaluronic acid with cartilage proteoglycans. *Biochim Biophys Acta.* 1972;279:401–405.
- Hascall VC, Heinegård D. Aggregation of cartilage proteoglycans. II. Oligosaccharide competitors of the proteoglycan-hyaluronic acid interaction. *J Biol Chem.* 1974;249:4242–4249.
- Schiff M, Burn HF. The effect of intravenous estrogens on ground substance. *Arch Otolaryngol.* 1961;73:43–51.
- Uzuka M, Nakajima K, Ohta S, et al. The mechanism of estrogen-induced increase in hyaluronic acid biosynthesis, with special reference to estrogen receptor in the mouse skin. *Biochim Biophys Acta.* 1980;627:199–206.
- Madry H, Rey-Rico A, Venkatesan JK, et al. Transforming growth factor beta-releasing scaffolds for cartilage tissue engineering. *Tissue Eng Part B Rev.* 2014;20:106–125.
- Matsuo K, Hirose T, Otagiri T, et al. Repair of cleft lip with nonsurgical correction of nasal deformity in the early neonatal period. *Plast Reconstr Surg.* 1989;83:25–31.
- Bennun RD, Perandones C, Sepiarsky VA, et al. Nonsurgical correction of nasal deformity in unilateral complete cleft lip: a 6-year follow-up. *Plast Reconstr Surg.* 1999;104:616–630.
- Bell A, Lo TW, Brown D, et al. Three-dimensional assessment of facial appearance following surgical repair of unilateral cleft lip and palate. *Cleft Palate Craniofac J.* 2014;51:462–471.
- Desmedt DJ, Maal TJ, Kuijpers MA, et al. Nasolabial symmetry and esthetics in cleft lip and palate: analysis of 3D facial images. *Clin Oral Investig.* 2015;19:1833–1842.
- Hunt O, Burden D, Hepper P, et al. The psychosocial effects of cleft lip and palate: a systematic review. *Eur J Orthod.* 2005;27:274–285.
- Sinko K, Jagsch R, Precht V, et al. Evaluation of esthetic, functional, and quality-of-life outcome in adult cleft lip and palate patients. *Cleft Palate Craniofac J.* 2005;42:355–361.



33. Roosenboom J, Hellings PW, Picavet VA, et al. Secondary cleft rhinoplasty: impact on self-esteem and quality of life. *Plast Reconstr Surg*. 2014;134:1285–1292.
34. Hens G, Picavet VA, Poorten VV, et al. High patient satisfaction after secondary rhinoplasty in cleft lip patients. *Int Forum Allergy Rhinol*. 2011;1:167–172.
35. Gassling V, Koos B, Birkenfeld F, et al. Secondary cleft nose rhinoplasty: subjective and objective outcome evaluation. *J Craniomaxillofac Surg*. 2015;43:1855–1862.
36. Grayson BH, Santiago PE, Brecht LE, et al. Presurgical nasoalveolar molding in infants with cleft lip and palate. *Cleft Palate Craniofac J*. 1999;36:486–498.
37. Lee CT, Garfinkle JS, Warren SM, et al. Nasoalveolar molding improves appearance of children with bilateral cleft lip-cleft palate. *Plast Reconstr Surg*. 2008;122:1131–1137.
38. Monasterio L, Ford A, Gutiérrez C, et al. Comparative study of nasoalveolar molding methods: nasal elevator plus DynaCleft® versus NAM-Grayson in patients with complete unilateral cleft lip and palate. *Cleft Palate Craniofac J*. 2013;50:548–554.
39. Patel PA, Rubin MS, Clouston S, et al. Comparative study of early secondary nasal revisions and costs in patients with clefts treated with and without nasoalveolar molding. *J Craniofac Surg*. 2015;26:1229–1233.
40. Fisher DM. Unilateral cleft lip repair: an anatomical subunit approximation technique. *Plast Reconstr Surg*. 2005;116:61–71.
41. Patel KB, Mulliken JB. Correction of the vestibular web during primary repair of unilateral cleft lip. *Plast Reconstr Surg*. 2014;134:600e–607e.
42. Nazarian Mobin SS, Karatsonyi A, Vidar EN, et al. Is presurgical nasoalveolar molding therapy more effective in unilateral or bilateral cleft lip-cleft palate patients? *Plast Reconstr Surg*. 2011;127:1263–1269.
43. Adzick NS, Thom EA, Spong CY, et al.; MOMS Investigators. A randomized trial of prenatal versus postnatal repair of myelomeningocele. *N Engl J Med*. 2011;364:993–1004.
44. Estes JM, MacGillivray TE, Hedrick MH, et al. Fetoscopic surgery for the treatment of congenital anomalies. *J Pediatr Surg*. 1992;27:950–954.
45. Pedreira DAL, Albert Reece E, Chmait RH, et al. Fetoscopic repair of spina bifida—safer and better? *Ultrasound Obstet Gynecol*. 2016;48:141–147.
46. Longaker MT, Adzick NS. The biology of fetal wound healing: a review. *Plast Reconstr Surg*. 1991;87:788–798.
47. Wood FM. Hypoxia: another issue to consider when timing cleft repair. *Ann Plast Surg*. 1994;32:15–8; discussion 19.