



Case Report

Lithobezoar: A Case Report and Literature Review of an Infrequent Cause of Abdominal Pain

Murat Ferhat Ferhatoğlu

Department of General Surgery, Okan University Faculty of Medicine, Istanbul, Turkey

Abstract

A bezoar is the accumulation of indigestible substances in the gastrointestinal system. Presently described is the case of a 47-year-old male patient who was admitted to the clinic with nausea, vomiting, pain, and abdominal distension. He had a medical history of obsessive-compulsive disorder. He had begun eating soil in the previous 3 to 4 months. Gastroscopy revealed a large, solid, clay-like mass in the stomach. Surgery was successfully performed to remove the collected soil, but unfortunately, the patient died due to an acute myocardial infarction on the postoperative fourth day. Physicians should keep bezoars in mind in cases of unexplained abdominal symptoms, especially in females and patients with psychiatric disorders. Psychiatric disorders are often ignored by surgeons during examinations, which can lead to serious and life-threatening complications.

Keywords: Bezoar; eating disorder; earth-eating; obsessive-compulsive disorder; pica.

Please cite this article as "Ferhatoğlu MF. Lithobezoar: A Case Report and Literature Review of an Infrequent Cause of Abdominal Pain. Med Bull Sisli Etfal Hosp 2019;53(4):445-449".

A bezoar is defined as an indigestible conglomeration of foreign material located in the gastrointestinal system. It is an infrequent finding, with an incidence of less than 1% in the general population.^[1] They are usually located in the stomach, followed by the intestines as the second most frequent localization. Bezoars are classified in several subgroups according to the component material: phytobezoars, lactobezoars, lithobezoars, and pharmacobezoars. Abdominal pain is the most frequent symptom, and a bezoar may cause life-threatening complications, such as gastrointestinal obstruction or perforation. Small bezoars can be easily treated with endoscopic or pharmacological methods; however, large or complicated bezoars are usually treated with surgery.^[2] New technological tools, such as neodymium-doped yttrium aluminium garnet (Nd:YAG) lasers, offer promise for non-surgical treatment options for large be-

zoars.^[3] Presently described is the treatment and surgical approach used for a 47-year-old male patient with a large gastric bezoar related to the patient's psychiatric condition.

Case Report

A 47-year-old male patient was admitted to the clinic with nausea, vomiting, pain, and abdominal distention. He had a medical history of obsessive-compulsive disorder and had discontinued psychiatric treatment 6 months earlier. He had begun to eat soil in the 3 to 4 months prior to presentation. A large mass was palpated in the epigastric region of the abdomen. Blood test results were normal. Abdominal computed tomography (CT) imaging revealed a solid mass with air bubbles filling the stomach (Fig. 1). Gastroscopy was performed and a large, clay-like, solid mass was observed. Due to the size of the mass, a gastrotomy was per-

Address for correspondence: Murat Ferhat Ferhatoğlu, MD. Okan Üniversitesi Tıp Fakültesi, Genel Cerrahi Anabilim Dalı, İstanbul, Turkey

Phone: +90 555 321 47 93 **E-mail:** ferhatferhatoglu@gmail.com

Submitted Date: December 12, 2017 **Accepted Date:** March 19, 2018 **Available Online Date:** November 20, 2019

©Copyright 2019 by The Medical Bulletin of Sisli Etfal Hospital - Available online at www.sislietfaltip.org

OPEN ACCESS This is an open access article under the CC BY-NC license (<http://creativecommons.org/licenses/by-nc/4.0/>).



formed and 1800 g of soil was removed from the stomach (Fig. 2). The surgery was completed without complication. Unfortunately, however, the patient died due to an acute myocardial infarction on the postoperative fourth day.

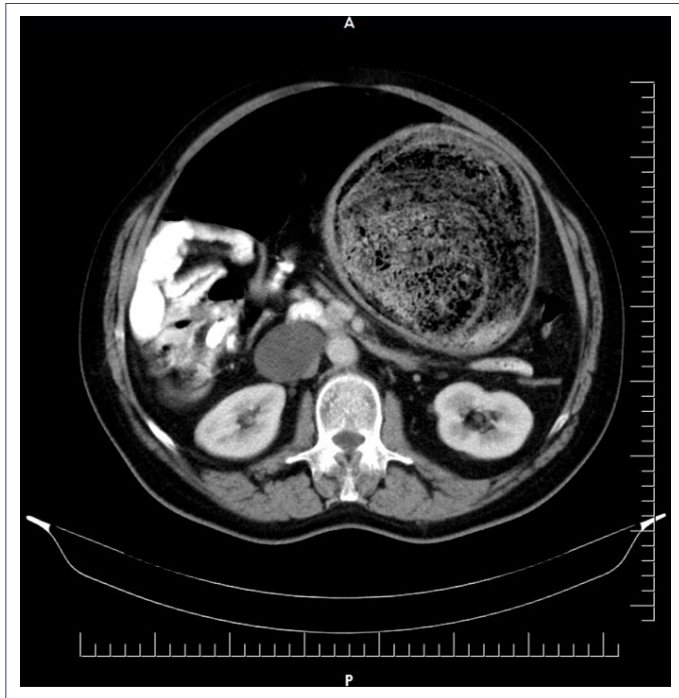


Figure 1. Abdominal computed tomography revealed a solid mass with air bubbles filling the stomach.

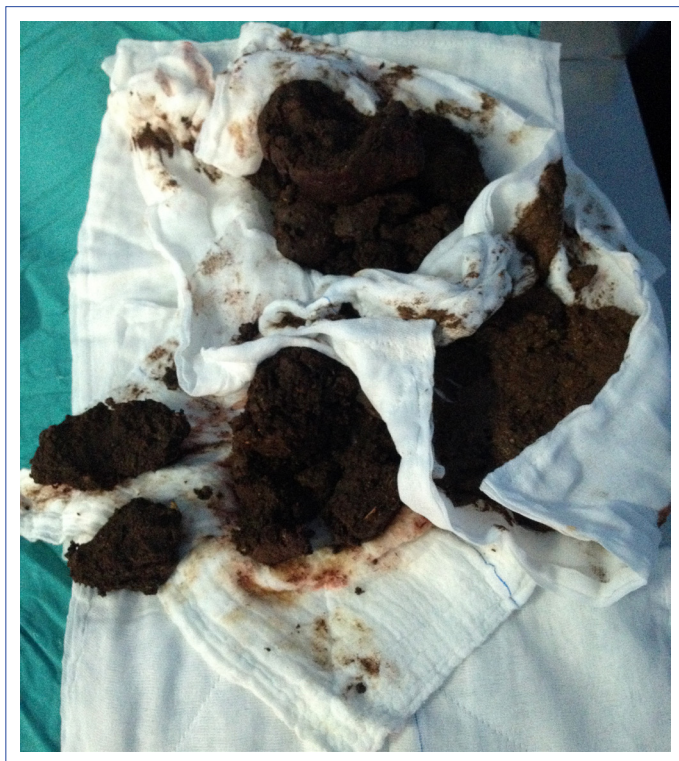


Figure 2. A large, clay-like mass of soil was removed from the stomach.

Discussion

A bezoar is the conglomeration of indigestible foreign material in the gastrointestinal tract. It is most often seen in female patients and patients with psychiatric and neurological disorders.^[2, 4] The reported incidence is between 0.0068% and 0.43%.^[1, 5, 6] Gastric bezoars are found in fewer than 0.5% of all upper gastrointestinal system endoscopies. A reported 0.4% to 4.8% of bezoar cases present with the symptoms of intestinal obstruction.^[7-11] The prevalence varies based on the geographic location and eating habits of ethnic groups. For example, persimmon bezoar (a kind of phytobezoar) cases are mostly reported from Turkey, Israel, Spain, and Japan.^[1, 12-16]

Four types of bezoars have been defined according to the contents: phytobezoar (indigestible plant material), trichobezoar (hair), lactobezoar (undigested milk in infants), and lithobezoar (soil and stone).^[2, 17] The phytobezoar is the most frequently seen type. Pumpkins, persimmons, grapes, and foods containing a large quantity of cellulose are the most common sources of phytobezoars.^[18-21] The trichobezoar is a hairball, mostly found in the stomach and nearly always diagnosed in young female patients with psychiatric disorders. Ingested hair accumulates between the gastric folds and forms a mass. In some cases, the bezoar may form in the stomach and reach small bowel. It has been described as "Rapunzel syndrome," and was first reported by Vaughan et al. in 1968.^[22, 23] Undigested milk and mucus in infants can form a lactobezoar.^[24] The pathogenesis is multifactorial and includes exogenous and endogenous factors. Synthetic milk products and medications inhibiting gastrointestinal motility are examples of possible exogenous factors, while premature birth, dehydration, and deficiency in gastrointestinal motility are examples of potential endogenous factors.^[25] Heinz-Ertan et al.^[26] reviewed 96 cases published in the literature between 1959 and 2012 and observed that most cases were described between 1975 and 1985. The reason for this frequency is unclear, but increased use of synthetic milk products during that time period may have been a factor. A lithobezoar is rare and most often seen in patients with iron deficiency anemia or the psychiatric disorder of geophagia, which is characterized by compulsive and persistent consumption of non-food substances, such as soil, stones, or ice. Our patient demonstrated symptoms of geophagia for 3 to 4 months prior to presentation.

Bezoar symptoms vary according to the size, location, and type of undigested foreign material, but may include nausea, vomiting, halitosis, weight loss, abdominal pain, abdominal distention, anemia, bloody stool, and upper gastrointestinal bleeding.^[17] Iwamura et al.^[25] reported that

abdominal pain was the most common symptom, followed by tarry or bloody stool. Five of 31 patients in that study were asymptomatic and the bezoar was discovered coincidentally. Our patient complained of nausea, vomiting, pain, and abdominal fullness. Rarely, symptoms of gastric ulceration, perforation, pancreatitis, and peritonitis may be seen due to chronic irritation of the gastric mucosa.^[27, 28] Lee et al.^[29] found that gastric ulceration was the most common complication of bezoars (41.2%).

A thorough clinical history is the main diagnostic tool. CT and endoscopy are confirmative diagnostic tests, and endoscopy may be the best choice for a minimally invasive treatment option for gastric bezoars.^[30] An endoscopic approach is insufficient for bezoars located in the small bowels, however, which require CT imaging for the diagnosis. CT also enables visualization of multiple small bowel bezoars, which is valuable in surgical patients.^[16]

Phytobezoars and lithobezoars are frequently found in the fundus part of the stomach as a single mass, but they may also occur as multiple masses. The most common location of trichobezoars is also the stomach, but they may reach to the small bowel. The color of a bezoar varies depending on the composition. A phytobezoar may be beige, yellow-green or black in color.^[31] Due to the content of mucus and milk, a lactobezoar is white.

There is no single, standard method for the removal of bezoars. Pharmacological, endoscopic, and surgical methods are primary treatment strategies.^[32] Small gastric bezoars may be conservatively treated with non-surgical methods. Acetylcysteine, cellulase, papain, and cola have been used, or mechanical, non-surgical methods, such as gastric lavage or endoscopic fragmentation with various devices, such as a polypectomy snare, biopsy forceps, alligator forceps, a basket, a lithotripter, argon plasma, and needle-knife or extracorporeal lithotripsy.^[30, 33] In a 2014 case report, Kurt et al.^[34] described a new snare device for bezoar fragmentation called a bezoaratom. A study from China incorporated a mini-explosive laser technique using an endoscope and found a cure rate of nearly 100% in 260 patients.^[35] Nd:YAG and holmium yttrium-aluminum-garnet (Ho:YAG) lasers have been reported in the treatment of large phytobezoars.^[3, 36] The most common treatment, however, is to use cola to dissolve a bezoar. The first case successfully treated with cola was reported in 2002 by Ladas et al.^[37] In a recent review of 24 publications including 46 patients, Ladas et al.^[18] reported that cola treatment had a success rate of 91.3%. It can be performed via gastric lavage, oral consumption of 3000 mL over a 12-hour period, or during endoscopy. The effect may be related to the low pH, high sodium bicarbonate

content, and CO₂ bubbles, which aid in dissolution.^[38] Cola has the advantage of being widely available, inexpensive, well-tolerated, and easy to administer.

Papain is an extract of the *Carica papaya* plant. It quickly hydrolyzes proteins and is used to tenderize meat. Successful treatment of bezoars with papain has been reported; however, physicians must be careful about adverse effects, such as gastric ulceration and esophageal perforation.^[39, 40]

Fruits are composed of large quantities of cellulose, and therefore, cellulase is widely used for chemical fragmentation of phytobezoars. The first successful treatment of a phytobezoar using cellulase was described in the 1970s.^[41, 42] Cellulase is not readily available by prescription in US pharmacies, but dietary supplements containing cellulase and other enzymes are accessible.^[43]

Cessation of oral nutrients combined with intravenous fluid administration and gastric lavage resolves 85% of gastric lactobezoars in infants.^[26] Reports in the literature have described the effective use of N-acetylcysteine in gastric lavage to treat a lactobezoar.^[44]

A combination of pharmacological and endoscopic treatment strategies is successful in more than 90% of cases.^[31] Trichobezoars are resistant to pharmacological therapies like papain, cellulase, or cola. Furthermore, endoscopic removal of a trichobezoar has only a 5% success rate due to the typically high density of the hairball.^[45] Most cases require a laparotomy or laparoscopic surgery.

Prokinetic drugs, such as metoclopramide, itopride, and mosapride improve gastric motility and may break down small bezoars soft enough to be fragmented by gastric peristalsis.^[31]

Surgical treatment is recommended if endoscopic and pharmacological strategies fail, the bezoar is very large, or complications such as perforation, penetration, or obstruction occur.^[18] Open or laparoscopic surgery under general anesthesia can be performed, according to the circumstances and the surgeon's experience. A gastrostomy procedure is generally applied for bezoars located in the stomach, while an enterotomy may be appropriate for bezoars located in the small bowel. Rarely, there may be bezoars located in both the stomach and the small bowel, which will necessitate both procedures. In this case, open surgical removal of the bezoar was selected rather than endoscopic fragmentation due to the large size and inadequate laparoscopic surgery experience with bezoars.

The recurrence rate of a bezoar may be as much as 13.5%.^[35] Prevention of recurrence is important; patients should minimize consumption of high-fiber foods and psychiatric disorders should be treated.

Conclusion

Physicians should keep bezoars in mind in cases of unexplained abdominal pain, halitosis, vomiting, and weight loss, especially in female patients or patients with psychiatric disorders. Bezoars can be life-threatening if complications occur, such as a perforation or obstruction. Patients with small gastric bezoars can usually be treated with non-surgical methods. The best known method is to use cola as a dissolver in the treatment of phytobezoars and lithobezoars. It is inexpensive, accessible, and well-tolerated. Cola can be used via oral intake, gastric lavage, or during endoscopy. Gastric lavage and bowel rest with intravenous fluid replacement can frequently be sufficient for lactobezoars in infants. Surgical treatment is recommended if endoscopic and pharmacological strategies fail, the bezoar is large in size or complications develop. Pharmacological treatment for trichobezoars is usually unsuccessful and this type of bezoar must generally be treated with surgery. New methods, such as Nd:YAG or Ho:YAG lasers, are promising treatment options for large bezoars, but more time and experience is needed to prove the reliability of these methods. Physicians must carefully observe the psychiatric condition of a patient. The discovery of a bezoar may be helpful in the identification of a psychiatric disorder. Failure to discern and treat a psychiatric condition may lead to failure of a surgical procedure or recurrence of the bezoar.

Disclosures

Informed Consent: Written informed consent was obtained from the patient for the publication of the case report and the accompanying images.

Peer-review: Externally peer-reviewed.

Conflict of Interest: None declared.

References

- Park SE, Ahn JY, Jung HY, Na S, Park SJ, Lim H, et al. Clinical outcomes associated with treatment modalities for gastrointestinal bezoars. *Gut Liver* 2014;8:400–7.
- Senol M, Ozdemir ZU, Sahiner IT, Ozdemir H. Intestinal Obstruction due to Colonic Lithobezoar: A Case Report and a Review of Literature. *Case Rep Pediatr* 2013;2013:854975.
- Grande G, Manno M, Zulli C, Barbera C, Mangiafico S, Alberghina N, et al. An alternative endoscopic treatment for massive gastric bezoars: Ho:YAG laser fragmentation. *Endoscopy*. 2016;48:E217.
- Goksugur SB, Karatas Z, Bekdas M, Dilek M. Dissolution of gastric bezoars using cola. *Turk J Gastroenterol* 2014;25:461.
- Mihai C, Mihai B, Drug V, Cijevschi Prelipcean C. Gastric bezoars-diagnostic and therapeutic challenges. *J Gastrointestin Liver Dis* 2013;22:111.
- Kadian RS, Rose JF, Mann NS. Gastric bezoars-spontaneous resolution. *Am J Gastroenterol* 1978;70:79–82.
- Yakan S, Sirinocak A, Telciler KE, Tekeli MT, Deneçli AG. A rare cause of acute abdomen: small bowel obstruction due to phytobezoar. *Ulus Trav Acil Cerrahi Derg* 2010;16:459–63.
- Ghosheh B, Salameh JR. Laparoscopic approach to acute small bowel obstruction: review of 1061 cases. *Surg Endosc* 2007;21:1945–9.
- de Toledo AP, Rodrigues FH, Rodrigues MR, Sato DT, Nonose R, Nascimento EF, et al. Diospyrobezoar as a cause of small bowel obstruction. *Case Rep Gastroenterol* 2012;6:596–603.
- Cifuentes Tebar J, Robles Campos R, Parrilla Paricio P, Lujan Mompéan JA, Escamilla C, Liron Ruiz R, et al. Gastric surgery and bezoars. *Dig Dis Sci* 1992;37:1694–6.
- Acar T, Tuncal S, Aydin R. An unusual cause of gastrointestinal obstruction: bezoar. *N Z Med J* 2003;116:422.
- Moffat JH, Fraser WP. Gastric Bezoar. *Can Med Assoc J* 1962;87:813–4.
- Gayà J, Barranco L, Llompарт A, Reyes J, Obrador A. Persimmon bezoars: a successful combined therapy. *Gastrointest Endosc* 2002;55:581–3.
- Moriel EZ, Ayalon A, Eid A, Rachmilewitz D, Krausz MM, Durst AL. An unusually high incidence of gastrointestinal obstruction by persimmon bezoars in Israeli patients after ulcer surgery. *Gastroenterology* 1983;84:752–5.
- Granot E, Fich A, Ayalon A, Manny J, Winograd I, Schwartz J, et al. An epidemic of persimmon bezoars in Israel. *Isr J Med Sci* 1984;20:167–9.
- Altintoprak F, Degirmenci B, Dikicier E, Cakmak G, Kivilcim T, Akbulut G, Dilek ON, Gunduz Y. CT findings of patients with small bowel obstruction due to bezoar: a descriptive study. *ScientificWorldJournal* 2013;2013:298392.
- Tan F, Mo H, He X, Pei H. An usual case of gastric outlet obstruction caused by multiple giant persimmon phytobezoars. *Gastroenterol Rep (Oxf)* 2016. pii: gow042.
- Ladas SD, Kamberoglou D, Karamanolis G, Vlachogiannakos J, Zouboulis-Vafiadis I. Systematic review: Coca-Cola can effectively dissolve gastric phytobezoars as a first-line treatment. *Aliment Pharmacol Ther* 2013;37:169–73.
- Holloway WD, Lee SP, Nicholson GI. The composition and dissolution of phytobezoars. *Arch Pathol Lab Med* 1980;104:159–61.
- Matsuo T, Ito S. The chemical structure of kaki-tannin from immature fruit of the persimmon. *Agric Biol Chem* 1978;126:421–4.
- Krausz MM, Moriel EZ, Ayalon A, Pode D, Durst AL. Surgical aspects of gastrointestinal persimmon phytobezoar treatment. *Am J Surg* 1986;152:526–30.
- Naik S, Gupta V, Naik S, Rangole A, Chaudhary AK, Jain P, et al. Rapunzel syndrome reviewed and redefined. *Dig Surg* 2007;24:157–61.
- Vaughan ED, Sawyers JL, Scott HW. The Rapunzel syndrome. An unusual complication of intestinal bezoar. *Surgery* 1968;63:339–43.
- Wolf RS, Bruce J. Gastrotomy for lactobezoar in a newborn infant. *J Pediatr* 1959;54:811–2.
- Iwamuro M, Okada H, Matsueda K, Inaba T, Kusumoto C, Imagawa

- A, et al. Review of the diagnosis and management of gastrointestinal bezoars. *World J Gastrointest Endosc* 2015;7:336–45.
26. Heinz-Erian P, Gassner I, Klein-Franke A, Jud V, Trawoeger R, Niederwanger C, Mueller T, Meister B, Scholl-Buergi S. Gastric lactobezoars - a rare disorder? *Orphanet J Rare Dis* 2012;7:3.
 27. Kwon Ann B. Is Abdominal Computed Tomography Helpful for the Management of an intestinal Obstruction Caused by a Bezoar. *J Korean Soc Coloproctol* 2012;28:69–70.
 28. Western C, Bokhari S, Gould S. Rapunzel syndrome: A case report and review. *J Gastrointest Surg* 2008;12:1612–4.
 29. Lee BJ, Park JJ, Chun HJ, Kim JH, Yeon JE, Jeon YT, et al. How good is cola for dissolution of gastric phytobezoars? *World J Gastroenterol* 2009;15:2265–9.
 30. Hung FC, Cho CY, Lo CC, Hwang JJ. Giant gastric phytobezoar successfully eradicated by oral intake plus endoscopic injection of Coca-Cola: a case report. *Intern Med Taiwan* 2009;20:162–6.
 31. Iwamuro M, Tanaka S, Shiode J, Imagawa A, Mizuno M, Fujiki S, et al. Clinical characteristics and treatment outcomes of nineteen Japanese patients with gastrointestinal bezoars. *Intern Med* 2014;53:1099–105.
 32. Misra SP, Dwivedi M, Misra V. Endoscopic management of a new entity-plastobezoar: a case report and review of literature. *World J Gastroenterol* 2006;12:6730–3.
 33. Lu L, Zhang XF. Gastric Outlet Obstruction—An Unexpected Complication during Coca-Cola Therapy for a Gastric Bezoar: A Case Report and Literature Review. *Intern Med* 2016;55:1085–9.
 34. Kurt M, Posul E, Yilmaz B, Korkmaz U. Endoscopic removal of gastric bezoars: an easy technique. *Gastrointest Endosc* 2014;5:895–6.
 35. Abbas TO. An Unusual Cause of Gastrointestinal Obstruction: Bezoar. *Oman Med J* 2016;26:127–8.
 36. Mao Y, Qiu H, Liu Q, Lu Z, Fan K, Huang Y, et al. Endoscopic lithotripsy for gastric bezoars by Nd:YAG laser-ignited mini-explosive technique. *Lasers Med Sci* 2014;29:1237–40.
 37. Ladas SD, Triantafyllou K, Tzathas C, Tassios P, Rokkas T, Raptis SA. Gastric phytobezoars may be treated by nasogastric Coca-Cola lavage. *Eur J Gastroenterol Hepatol* 2002;14:801–3.
 38. Hayashi K, Ohara H, Naitoh I, Okumura F, Andoh T, Itoh T, et al. Per-simmon bezoar successfully treated by oral intake of Coca-Cola: a case report. *Cases J* 2008;1:385.
 39. Dugan FA, Lilly JO, McCaffery TD. Dissolution of a phytobezoar with short-term medical management. *South Med J* 1972;65:313–6.
 40. Holsinger JW, Fuson RL, Sealy WC. Esophageal perforation following meat impaction and papain ingestion. *JAMA* 1968;204:734–5.
 41. Bruck HM. Letter: Gastric phytobezoar. *JAMA* 1975;231:26.
 42. Gold MH, Patteson TE 3rd, Green GI. Cellulase bezoar injection: a new endoscopic technique. *Gastrointest Endosc* 1976;22:200–2.
 43. Kramer SJ, Pochapin MB. Gastric phytobezoar dissolution with ingestion of diet coke and cellulase. *Gastroenterol Hepatol* 2012;8:770–2.
 44. Castro L, Berenguer A, Pilar C, Gonçalves R, Nunes JL. Recurrent gastric lactobezoar in an infant *Oxf Med Case Reports* 2014;2014:80–2.
 45. Frohna WJ. Metamucil bezoar: an unusual cause of small bowel obstruction. *Am J Emerg Med* 1992;10:393–5.