



Panoramic Radiograph and CBCT in Unilateral Mandibular Condylar Hyperplasia—A Case Report

A. Rizwana¹ N. Mohan¹ P. T. Ravi Kumar¹ R. Karthik¹ Sabitha Gokulraj¹

¹Department of Oral Medicine and Radiology, Vinayaka Mission Sankarachariyar Dental College, Vinayaka Mission Research Foundation -DU, Salem, Tamil Nadu, India

Address for correspondence A. Rizwana, MDS, Department of Oral Medicine and Radiology, Vinayaka Mission Sankarachariyar Dental College, Vinayaka Mission Research Foundation – DU, Salem – 636 308, Tamil Nadu, India (e-mail: rizoppa786@gmail.com).

Indian J Radiol Imaging 2021;31:1070–1074.

Abstract

Keywords

- ▶ cone-beam computed tomography
- ▶ facial asymmetry
- ▶ mandibular condyle
- ▶ panoramic radiography

Condylar hyperplasia (CH) of the mandible is a rare developmental disorder that results in enlargement of the condyle. It is predominant in females, mostly unilateral and self-limiting. This report presents a case of a 35-year-old female patient with unilateral condylar hyperplasia with an increase in vertical height of mandibular ramus of the affected side. After initial radiographic evaluation, the asymmetry index using a panoramic radiograph was determined and also analyzed using cone-beam computed tomography (CBCT). Condylar dimensions in all the planes were measured for both sides using CBCT. This case report emphasizes the importance of CBCT and its role in the diagnosis and assessment of mandibular condylar hyperplasia.

Introduction

Unilateral mandibular condylar hyperplasia is a rare developmental disorder. Mandibular condylar hyperplasia was first described in 1836 by Robert Adams.¹ The etiology and pathogenesis are poorly understood. It is self-limiting and tends to stabilize or stop with aging. It may progress slowly or rapidly, producing mandibular asymmetry, chin deviation, limited mouth opening, posterior open bite on the affected side, and cross-bite on the contralateral side.^{2,3} Since the growth vector of the mandible is the condyle, condylar hyperplasia is often accompanied by an increase in height of ramus or body or alveolar process of the affected side of the mandible. Imaging plays a vital role in accurate measurement of the condyle, thereby helping the treatment plan. This case report deals with the role of cone-beam computed tomography (CBCT), a recent imaging modality in diagnosis and treatment plan in a patient with condylar hyperplasia.

Case Report

A 35-year-old female patient reported to the department with the chief complaint of deviation of lower jaw toward the right side from the age of 15 years. She also noticed a swelling in her left preauricular region that was insidious in onset, small initially, and gradually attained the present size. No history of pain or clicking was found in that region. There was no history of trauma and a similar type of swelling in other parts of the body. The patient had difficulty in chewing initially; later she got adapted. The patient had a history of gastritis for 3 months and was under medication. Her dental history revealed uneventful extraction before 2 months. The patient was well oriented to time, place, and person. All her vitals were within the normal range.

On extraoral examination, facial asymmetry was noted. Chin has been deviated toward the right side. On mouth opening, facial midlines coincide and get deviated to the right side during closing of the mouth (▶ **Fig. 1**). Mouth opening

published online
January 10, 2022

DOI <https://doi.org/10.1055/s-0041-1741054>.
ISSN 0971-3026.

© 2022. Indian Radiological Association. All rights reserved.
This is an open access article published by Thieme under the terms of the Creative Commons Attribution-NonDerivative-NonCommercial-License, permitting copying and reproduction so long as the original work is given appropriate credit. Contents may not be used for commercial purposes, or adapted, remixed, transformed or built upon. (<https://creativecommons.org/licenses/by-nc-nd/4.0/>)
Thieme Medical and Scientific Publishers Pvt. Ltd., A-12, 2nd Floor, Sector 2, Noida-201301 UP, India

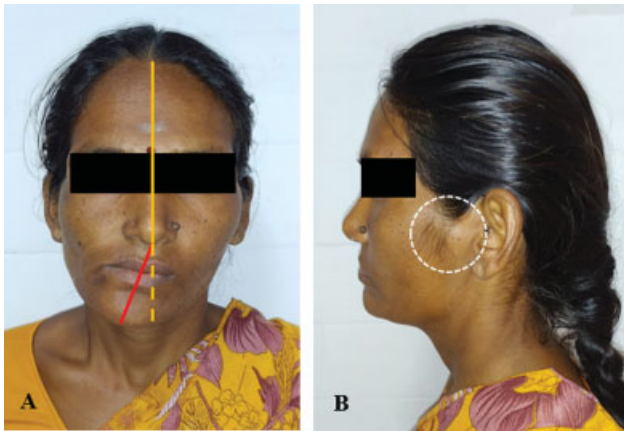

Fig. 1 (A) Deviation of mandible toward right side. (B) Swelling in the left preauricular region. Yellow line indicates midline and red line indicates the deviation of mandible towards right side.

was 35 mm. Lateral and protrusive movements were restricted. A single right submandibular lymph node measuring $\sim 1 \times 0.5$ cm was palpable, soft in consistency, tender, freely movable.

On temporomandibular joint (TMJ) examination, a well-defined solitary swelling measuring $\sim 1.5 \times 2$ cm was present in the left preauricular region, the skin over the swelling was stretched, and the color of the skin appears similar to adjacent skin. Secondary changes such as ulcer and sinus opening were not present. All inspectory findings regarding site, size, and shape were confirmed by palpation. The swelling was bony hard in consistency (prominent condyle) and nontender. No warmth felt. No clicking sound, crepitus heard. The swelling was found to move during mandibular movements. Muscles of mastication were nontender (**Fig. 1**).

On intraoral examination, dental midline did not coincide. Generalized gingival recession and attrition were present. Mesial tilting of 41, 42, 43 and distal tilting of 31, 32 were present. The posterior's mandibular teeth were lingually tilted (44, 45, 34, 37) (**Fig. 2**).

The provisional diagnosis was made as unilateral condylar hyperplasia of the mandible (left). The differential diagnosis was osteochondroma and osteoma.

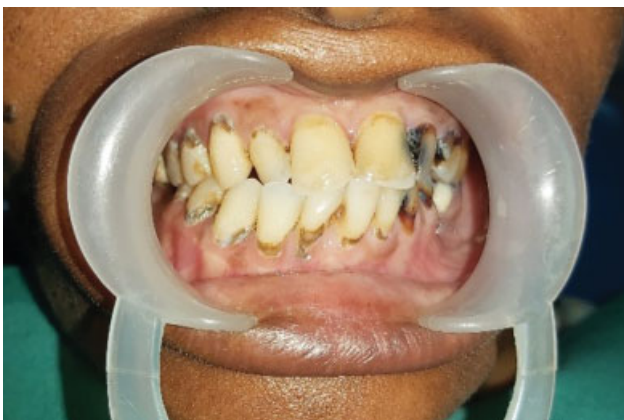

Fig. 2 Tilting of lower anteriors toward left side.

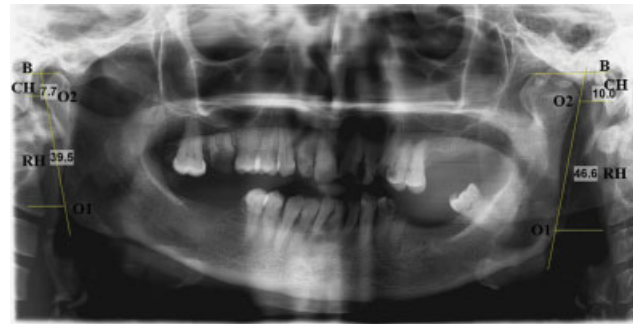

Fig. 3 (A) Vertical condylar asymmetry index described by Habets. (B) The highest point of the condyle; (O2) the most lateral point of the condyle; (O1) the most lateral points of the mandibular ramus; (RH) the mandibular ramus height and (CH) condylar height.

Panoramic tomography (PLANMECA Proline XC) revealed enlarged condyle on the left side with altered shape (**Fig. 3**). The cortical border was intact and the trabecular pattern was homogenous. An increase in height of the left-side ramus of the mandible was also noted. Mesial tilting of 41, 42, 43 and distal tilting of 31, 32 were present.

Asymmetry Index Calculation

In panoramic radiographs, 18 to 21% magnification in vertical height is seen according to Larheim and Svanaes (1986). In 1988, Habets et al proposed a Habets asymmetry index for determining the asymmetry using panoramic radiographs.⁴⁻⁶

Habets asymmetry index (AI) was calculated from the formula, $AI = [(R-L)/(R+L)] \times 100\%$.

A difference of $\sim 3\%$ is considered as asymmetrical. AI can be calculated for both condyle and ramus. In the present case, AI for condyle was 12.69% and for ramus was 8.42%, showing that condyle and ramus of both right and left side were asymmetric (**Fig. 3**).

In this case, unilateral enlargement of the condyle with the asymmetry of the mandible was clearly made out in posteroanterior view of skull and reverse Towne's projection (**Fig. 4**).

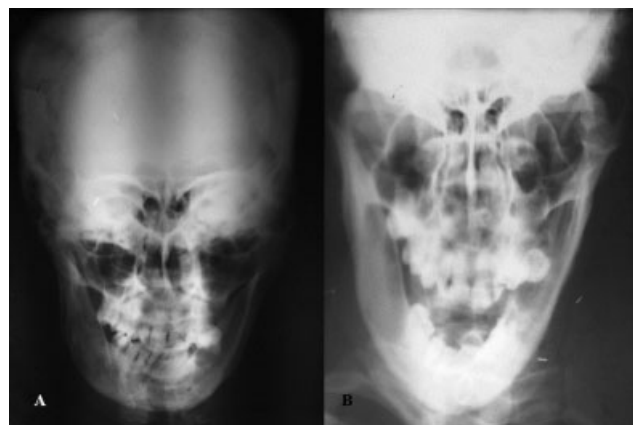


Fig. 4 (A) Posteroanterior view of skull shows deviation of mandible toward right side. (B) Reverse Towne's projection shows left condylar enlargement.

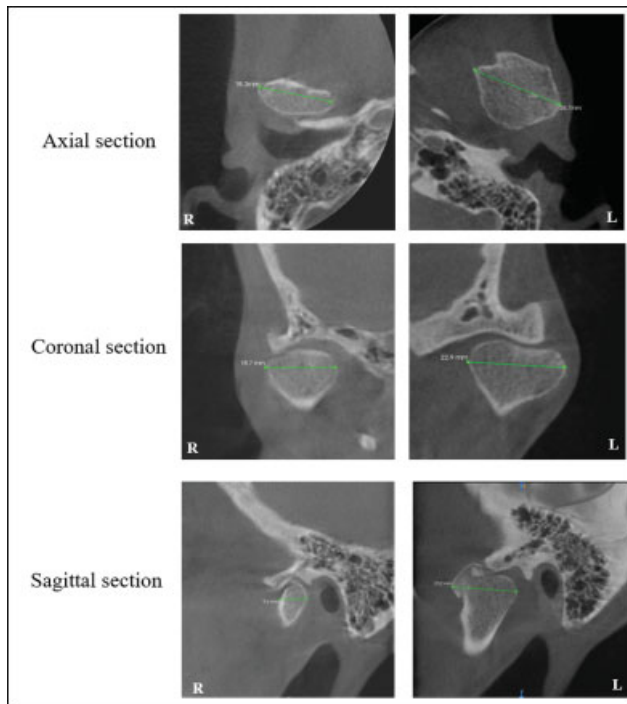


Fig. 5 Various section in cone-beam computed tomography showing comparison between both condyles with measurements.

CBCT of right and left TMJs was advised for more accurate measurements of the condylar dimensions.

After studying the various views, the left-side condyle and neck were found to be enlarged in all the three planes (→ **Figs. 5 and 6**). The shape of the condyle and the articular tubercle was altered. The shape of the left condyle resembles a heart

Table 1 Measurements of both condyle in all planes using CBCT

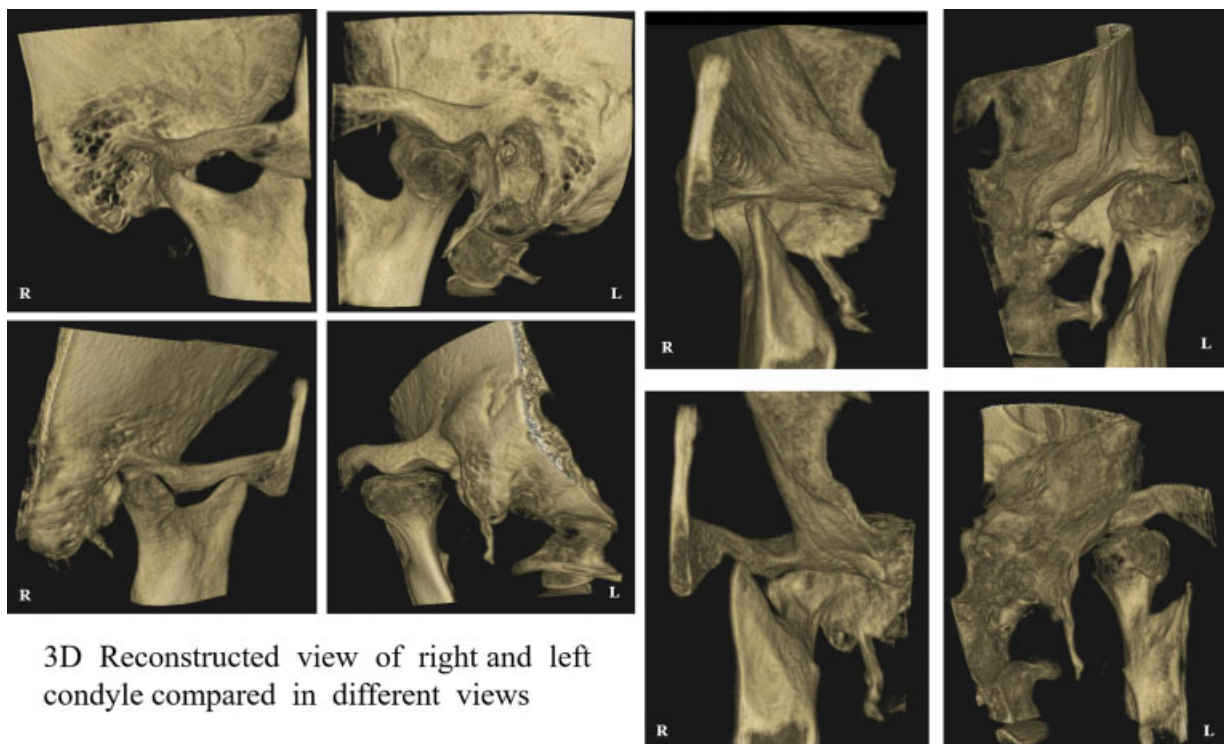
	Right condyle (mm)	Left condyle (mm)
Axial section (mediolateral dimension)	18.3	26.7
Coronal section (mediolateral dimension)	18.7	22.9
Sagittal section (anteroposterior dimension)	9.6	23.2

Abbreviation: CBCT, cone-beam computed tomography.

in the coronal section with a bony projection extending anteriorly that was seen in the sagittal section. The cortical border was intact. The trabecular pattern of the condyle was homogenous except for an area of radiopacity measuring 0.3 cm in diameter. The articular tubercle was flattened with an increased dimension anteroposterior dimension.

Measurements were made in all three planes using the software (Horos v3.3.6) (→ **Table 1**). The maximum difference in dimension was observed in the sagittal section that suggests that the condyle was more enlarged anteroposteriorly. The Hounsfield unit of both the condyles was indicated as calculated by the software (→ **Fig. 7**).

According to Obwegeser and Makek classification, the present case is type III condylar hyperplasia (chin deviation



3D Reconstructed view of right and left condyle compared in different views

Fig. 6 Three-dimensional reconstructed view of right and left condyle compared in different views.

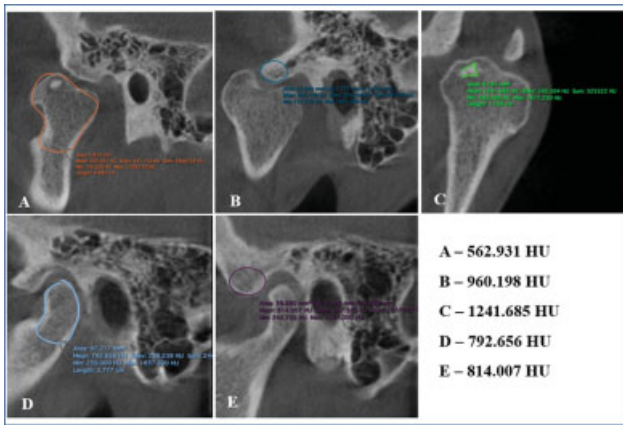


Fig. 7 Hounsfield units (HU) calculated using gray values. (A–C) Hounsfield unit values of affected left condyle. (D and E) Hounsfield unit values of unaffected right condyle.

toward the contralateral side with a sloping rima oris, midline shift, possible open bite and/or cross-bite) and according to Wolford classification, the present case is CH type I B (unilateral mandibular elongation chin deviation toward contralateral side, midline shift to contralateral side, lingual deviation of contralateral mandibular molars, possible posterior cross-bite, ipsilateral Class III occlusion).¹

Following the diagnosis, the surgical correction procedure was advised for the patient. However, the patient refused the treatment procedure.

Discussion

TMJ condylar hyperplasia is a reactive hyperplastic growth of the condyle, in which there are an impressive adaptive capacity and compensatory mechanisms of the human body. It is illustrated as a rare unilateral growth of the mandibular condyle, characterized by excessive bone growth resulting in facial asymmetry.^{1,7}

The condylar cartilage is a secondary cartilage that is highly responsible to mechanical stimuli and responds differently to various hormonal and chemical agents. Growth at the condyle is pressure adapted. The cap of the condyle undergoes endochondral ossification, whereas the rest of the condyle and the neck undergoes intramembranous ossification. The zone of growth in the condyle contains proliferative cells like skeletoblasts and prechondroblasts, that are exposed to the environment and are moldable to external stimuli. It has a multidirectional proliferative capacity.⁸

Condylar hyperplasia may be due to overactive cartilage or persistent cartilaginous rests, increasing the thickness of the entire cartilaginous and precartilaginous layers. Condylar hyperplasia is more common in the females before the age of 20 years. It is usually unilateral, self-limiting, and gets arrested with the termination of skeletal growth.

Facial asymmetry involving the TMJ can be TMJ pathology, unilateral condylar hyperplasia, unilateral mandibular condylar osteoma or osteoblastoma, and condylar resorption, among which unilateral condylar hyperplasia has the features of progressively worsening Class III occlusal rela-

tionship with a contralateral cross-bite, mandibular, and chin deviation to the opposite side. These characteristic features of condylar hyperplasia are seen in the present case.⁹

The most common benign tumor of condyle is osteochondroma followed by osteoma. In the present case, the patient was asymptomatic, whereas in the case of osteochondroma and osteoma, the patient may experience pain, clicking sound on the affected side, and is rarely asymptomatic.² Radiographic features of this case were a well-defined altered condyle, altered articular eminence, thickened condylar neck, and increased ramus height on the affected side. The cortical border was well defined and the trabecular pattern was homogenous except for a 0.3 cm area of radiopacity. In case of osteochondroma and osteoma, the condyle is irregular in shape and the trabecular pattern is heterogeneous. The articular eminence may be altered to compensate the altered condyle changes. The alteration in the condylar neck and ramus may be secondary to degenerative changes due to altered forces on the joint. Hence, the history of onset of the lesion (observed at her age of 15 years) and from the above features, it is an indication of developmental disorder of the mandibular condyle probably mandibular condylar hyperplasia. Since osteochondroma and osteoma are benign tumors, there will be no such secondary degenerative changes as noted in condylar hyperplasia.

A panoramic radiograph is generally a quick and convenient radiographic technique that is used for assessing mandibular lesions. It has a low radiation dose and covers broad coverage of facial bones and teeth.^{2,4} Since panoramic radiography involves distortion and elongation, CBCT was used to get more accurate measurements.

With CBCT, high-resolution images can be obtained with reduced radiation exposure to the patient when compared with multislice CT.¹⁰ It also can produce images resembling panoramic images with which the dentists are familiar (pseudopanoramic). Alveolar buccolingual cross-sectional images can also be produced by routine CBCT software that is also an advantage. Surface rendering can be done and the image analysis can also be done by the end-users. Carestream9300 S 3D extraoral imaging system (Carestream Health, Inc., Rochester, New York, United States) was used for obtaining CBCT images. Radiation exposure to the patient in CBCT was: 90 kVp, 5 mAs, and scan time 8.01s. Radiation exposure to the patient was 568 mGycm². Field of view for single TMJ was 180 × 180 × 180 μm.

Direct measurements of mandible were done in panoramic software (Romexis) and the asymmetry index was determined by Habets method. This method revealed both the condyle and ramus of the mandible of the present case were asymmetric. The altered articular tubercle and condylar neck were better appreciated on CBCT than a panoramic radiograph. In a panoramic radiograph, the shape of the condyle was noted to be enlarged, whereas in CBCT the sagittal section showed a bony projection extending anteriorly. Pinpoint radiopacity in the condylar trabecular pattern was appreciated only in CBCT, where a homogenous trabecular pattern was seen in a panoramic radiograph. In the

present case, bone density in Hounsfield units was also calculated for both the condyles using CBCT.

Obwegeser and Makek divided unilateral condylar hyperplasia into three types. Type I is hemimandibular elongation, type II is hemimandibular hyperplasia, and type III is a combination of type I and type II. The present case is type III condylar hyperplasia (chin deviation toward contralateral side with a sloping rima oris, midline shift, possible open bite and/or cross-bite). According to Wolford classification, unilateral condylar hyperplasia is divided into four types, among which type I and II have subtypes A and B. The present case is CH type IB (unilateral mandibular elongation chin deviation toward the contralateral side, midline shift to contralateral side, lingual deviation of contralateral mandibular molars, possible posterior cross-bite, ipsilateral Class III occlusion).¹

Nuclear imaging like bone scintigraphy, positron emission tomography, and single-photon emission computed tomography can be advised before surgery that helps to determine the growth phase of the condyle.^{11,12} This nuclear medicine examination uses technetium-99 along with methylene diphosphonate as phosphated radiotracer.¹³ The principle behind nuclear imaging is hydroxyapatite crystals and calcium from the bone tissue will be absorbed by the radioisotopes, so that the fixation intensity is proportional to the degree of osteoblast activity.

The primary treatment protocol for unilateral condylar hyperplasia is surgery followed by orthodontic teeth correction. The various surgical methods for unilateral condylar hyperplasia include unilateral sagittal split, bilateral sagittal split ramus osteotomies, unilateral or bilateral maxillary osteotomies with or without Le Fort I leveling osteotomy, and condylectomy. Surgical correction is indicated only after the completion of growth.^{1,14} Following surgery, joint functional exercises can be advised to recover mandible lateral and vertical movements and also to minimize the occurrence of intra-articular adhesions and capsular retractions. The various joint functional exercises include massage, masticatory, and cervical muscle relaxation, joint distraction, joint kinesiotherapy, joint mobilization exercises, mandibular mobilization exercises with hyperboloid and against resistance for muscular reinforcement.¹⁵ However, in the present case, the patient refused the treatment.

Conclusion

Condylar hyperplasia is a rare unilateral (rarely bilateral) growth of the mandibular condyle, characterized by excessive bone growth resulting in facial asymmetry. CBCT, an advanced imaging, can be used in diagnosis, assessment, and treatment planning of unilateral condylar hyperplasia of the mandible. The role of CBCT in the measurements for the

assessment of condylar hyperplasia and vertical height of ramus is emphasized.

Financial Support and Sponsorship
Nil.

Conflicts of Interest
There are no conflicts of interest.

References

- Almeida LE, Zacharias J, Pierce S. Condylar hyperplasia: an updated review of the literature. *Korean J Orthod* 2015;45(06): 333–340
- White and Pharoah. *Oral Radiology Principles and Interpretation*. First South Asian edition. India: Reed Elsevier India Private Limited; 2014
- Laskin DM, Greene CS, Hylander WL. *TMDs: An Evidence-Based Approach to Diagnosis and Treatment*. Hanover Park: Quintessence Publishing Co, Inc; 2006
- Bumann A, Lotzmann U, Mah J, et al. *TMJ (Temporomandibular Joint) Disorders and Orofacial Pain: The Role of Dentistry in a Multidisciplinary Diagnostic Approach*. 1. Aufl. Stuttgart: Thieme, Georg, Verlag; 2002 (Color Atlas of Dental Medicine)
- Sofyanti E, Boel T, Soegiharto B, Auerkari EI. TMD symptoms and vertical mandibular symmetry in young adult orthodontic patients in North Sumatra, Indonesia: a cross-sectional study. *F1000 Res* 2018;7:697
- Iturriaga V, Navarro P, Cantin M, Fuentes R. Prevalence of vertical condylar asymmetry of the temporomandibular joint in patients with signs and symptoms of temporomandibular disorders. *Int J Morphol* 2012;30:315–321
- Olate S, Netto HD, Rodriguez-Chessa J, Alister JP, de Albergaria-Barbosa J, de Moraes M. Mandible condylar hyperplasia: a review of diagnosis and treatment protocol. *Int J Clin Exp Med* 2013;6 (09):727–737
- Premkumar S. *Textbook of Craniofacial Growth*. 1 ed. New Delhi: Jaypee Brothers. Med Publ (Oulu) 2011;••:377
- Srivastava D, Singh H, Mishra S, Sharma P, Kapoor P, Chandra L. Facial asymmetry revisited: Part I- diagnosis and treatment planning. *J Oral Biol Craniofac Res* 2018;8(01):7–14
- Barghan S, Tetradis S, Mallya S. Application of cone beam computed tomography for assessment of the temporomandibular joints. *Aust Dent J* 2012;57(Suppl 1):109–118
- Appadurai R, Lingeshwar D, Shwetha V, Christina R. Bone scintigraphy as a diagnostic tool in condylar hyperplasia. *J Oral Maxillofac Radiol* 2017;5:84
- Yang Z, Reed T, Longino BH. Bone scintigraphy SPECT/CT evaluation of mandibular condylar hyperplasia. *J Nucl Med Technol* 2016;44(01):49–51
- Minte C, Sandoval P, Olate S. Condylar hyperplasia, diagnosis and clinical management. A clinical case report. *Rev Fac Odontol Univ Antioq* 2016;27:442–454
- Alyamani A, Abuzinada S. Management of patients with condylar hyperplasia: a diverse experience with 18 patients. *Ann Maxillofac Surg* 2012;2(01):17–23
- Pinto I, Fonseca J, Vinagre A, Angelo D, Sanz D, Grossmann E. Mandibular condylar hyperplasia: diagnosis and management. *Case Report Rev Dor* 2016;17:307–311