

Laparoscopic Ureteral Reimplant for Distal Ureteral Strictures

Kenneth Ogan, MD, John T. Abbott, MD, Chester Wilmot, MD, John G. Pattaras, MD

ABSTRACT

Background and Objectives: The incidence of ureteral injuries is on the rise. Endoscopic treatment of long distal ureteral strictures is associated with poor success rates, and open ureteral reimplantation is a potentially morbid surgical procedure. The objective of this study was to review our early results with laparoscopic ureteral reimplantation.

Methods: Between May 2004 and February 2007, 6 patients with ureteral strictures secondary to either gynecological surgery (4) or urolithiasis (2) presented for treatment. These patients failed traditional conservative treatment and underwent laparoscopic ureteral reimplantation.

Results: Five of the 6 cases were performed completely laparoscopically, while one patient had an elective open conversion to complete the vesicoureteral anastomosis. No major intraoperative or postoperative complications were encountered. The mean operating room time was 277 minutes (range, 180 to 360). The average hospital stay was 2.7 days (range, 2 to 5). All patients had a successful outcome defined as no evidence of radiographic obstruction and no clinical complaints of persistent renal colic. Mean follow-up was 13.2 months (range, 2 to 33).

Conclusion: Our early results demonstrate that laparoscopic ureteral reimplantation is an effective minimally invasive treatment option for distal ureteral strictures.

Key Words: Ureteral stricture, Ureteral reimplantation, Neocystostomy, Laparoscopy.

INTRODUCTION

The incidence of ureteral injuries has been on the rise. Regrettably, the majority of this increase can be attributed to the proliferation of ureteroscopic procedures and complex pelvic laparoscopy.^{1,2} Although some shorter ureteral strictures can be managed via an endoscopic approach, success rates suffer when longer strictures are treated. Thus, these strictures are traditionally managed with open laparotomy, which is usually associated with a significant hospital stay and convalescence. Several investigators have described laparoscopic ureteral reimplantation as a minimally invasive alternative to the open approach with comparable short-term success rates.

We describe our initial series of 6 patients who underwent laparoscopic ureteral reimplantation (LUR). This minimally invasive technique allows for treatment of long strictures of the distal ureter, without the need for complex reconstructive maneuvers.

METHODS

Between May 2004 and February 2007, 6 patients (5 females and 1 male) underwent LUR at Emory University Hospital (**Table 1**). Four of the patients had prior pelvic gynecological surgery, including laparoscopic-assisted vaginal hysterectomy,² total abdominal hysterectomy,¹ and laparoscopic treatment of endometriosis.¹ In the 3 patients who underwent hysterectomy, the ureteral injury (2 cut and 1 obstructed with a ligature) was unrecognized at the time of surgery and diagnosed in a delayed fashion. Retrograde ureteral stent placement was unsuccessful in all cases, and they were initially managed with percutaneous nephrostomy tube drainage until LUR. The patient with stage IV endometriosis was found to have hydronephrosis in the workup of infertility and did not require nephrostomy tube placement. The other 2 patients in our series had distal ureteral strictures secondary to impacted ureteral stones treated with multiple ureteroscopies and prolonged ureteral stenting. In all cases, stricture length and location were determined with appropriate antegrade and retrograde studies (**Figure 1**). In addition, functional studies were obtained if there was a question of decreased renal function.

Department of Urology, Emory University Medical School, Atlanta, Georgia, USA (all authors).

Address reprint requests to: Kenneth Ogan, MD, Department of Urology, Emory University Medical Center, 1365 Clifton Rd, Suite B, Atlanta, GA 30322, USA. Telephone: 404 778 3038, Fax: 404 778 4006, E-mail: kenneth.ogan@emoryhealthcare.org

© 2008 by JSLS, *Journal of the Society of Laparoendoscopic Surgeons*. Published by the Society of Laparoendoscopic Surgeons, Inc.

Table 1. Patient Results

Patient	Age	Sex	Etiology*	Ureteral Location	Procedure	EBL* (mL)	OR Time (min)	LOS* (day)	Complications	Success	F/U* (mo)
1	41	F	TAH	Right distal	LUR	150	360	5	Postoperative fevers	Yes	2
2	75	F	LAVH, prolapse repair	Right distal	LUR	200	272	2	None	Yes	7
3	65	F	Urolithiasis, ureteroscopy	Right distal	LUR	250	340	2	None	Yes	7
4	40	F	Endometriosis, laparoscopy	Left distal	LUR	50	224	2	None	Yes	12
5	35	F	LAVH	Right distal	LUR	200	180	3	Open conversion	Yes	18
6	79	M	Urolithiasis, ureteroscopy	Right distal	LUR (Psoas hitch)	50	283	2	None	Yes	34

*EBL = Estimated blood loss; OR = operating room; LOS = length of stay; F/U = follow up; LUR = laparoscopic ureteral reimplant; VH = vaginal hysterectomy; TAH = total abdominal hysterectomy; LAVH = laparoscopic assisted vaginal hysterectomy; F = female; M = male.

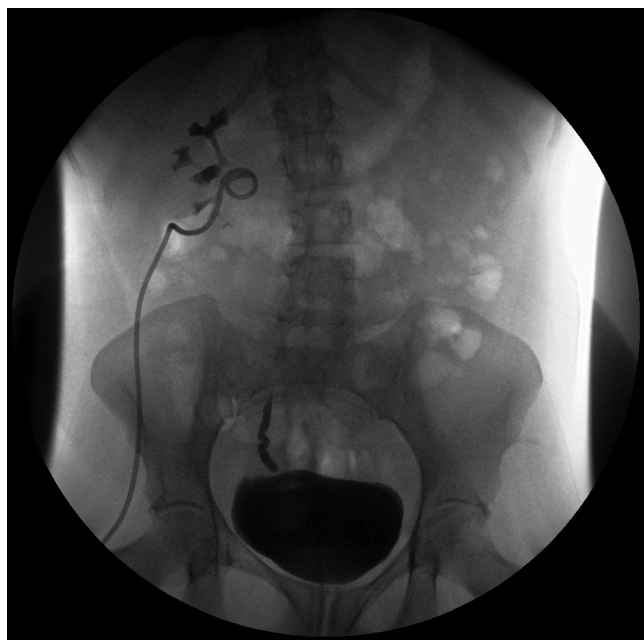


Figure 1. Preoperative right antegrade nephrostogram and simultaneous cystogram demonstrating distal ureteral stricture.

All procedures were performed transperitoneally in a similar fashion as previously described by Lima and associates.³ Following induction of anesthesia and the administration of intravenous prophylactic antibiotics, the patient is positioned in the modified lateral position. It is important that the genitalia are prepared into the operative field in case cystoscopy is required to aide in ureteral stent

placement. An infraumbilical incision is made, and the Veress needle is used to establish pneumoperitoneum. A 10-mm blunt tip optical trocar is then inserted under direct visualization through the umbilicus and used as the camera port. Subsequently, a second 12-mm trocar is placed two-thirds the distance between the umbilicus and anterior superior iliac spine. A 12-mm trocar is used to allow for easy passage of an SH-needle for intracorporeal suturing. Finally, a 5-mm trocar is placed midway between the umbilicus and pubic symphysis.

Once trocars are within the abdomen, the colon is mobilized medially along the line of Toldt. The ureter is identified cephalad to the bifurcation of the iliac vessels, away from the point of obstruction. Ureterolysis is then carried out in a caudal direction taking care not to devascularize the ureter. If the length of the stricture extends more proximally, the ureter can be mobilized cephalad to the lower pole of the kidney. Once the ureter becomes entrapped in scar tissue, the ureter is transected, taking care to excise any nonviable tissue. The healthy ureter is then sharply spatulated posteriorly.

The bladder is filled with 200 mL of normal saline, and the overlying peritoneum is divided between the obliterated umbilical ligaments. This allows entrance into the space of Retzius, and the bladder can then subsequently be further mobilized by dividing anterolateral attachments. When performing a bladder dome advancement technique, no further mobilization is typically necessary. When performing a psoas hitch for longer strictures, the contralateral

bladder pedicle may need to be divided before suturing the bladder to the ipsilateral psoas tendon. The ipsilateral anterior bladder wall is then opened transversely (2 cm to 3 cm) one-third the distance from the dome to the bladder neck. A temporary holding suture placed through the bladder caudal to the cystotomy can be brought through the anterior abdominal wall to make the subsequent anastomosis easier to perform. The middle portion of the posterior flap is then sewn to the apex of the spatulated ureter.³ Suturing the anastomosis is performed with a continuous 4-0 polyglactin suture with a double-armed, knotted suture as described for laparoscopic pyeloplasty by Eichel and associates.⁴ Once the posterior anastomosis is completed, a ureteral stent is passed proximally over a guidewire that is placed via the inferior trocar (**Figure 2**). When the wire cannot be directed into the proximal ureter secondary to a poor angle, it may be passed transurethrally with a flexible cystoscope or percutaneously through a large-bore angiocatheter. With the ureteral stent in place, the anterior anastomosis is completed, and the remaining bladder is closed in a longitudinal Heineke-Mikulicz fashion. For a psoas hitch procedure, interrupted polydioxanone sutures are used to approximate the bladder dome to the psoas tendon to allow a tension-free vesicoureteral anastomosis. Finally, the anastomosis is checked by instilling 300 mL of saline into the bladder, and any additional interrupted sutures are placed as necessary.

A Jackson Pratt drain is placed through the lateral 12-mm trocar site, placed on bulb suction, and removed on the second postoperative day as long as drain fluid analysis is not consistent with urine. The Foley catheter is removed 7

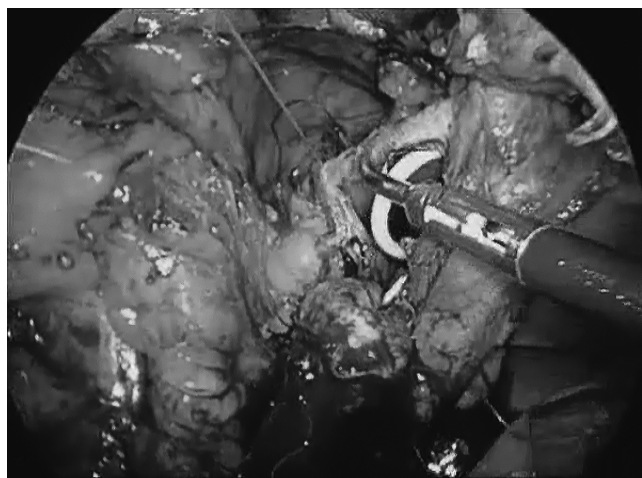


Figure 2. Laparoscopic view of partially completed vesicoureteral anastomosis with insertion of ureteral stent.

days to 10 days after cystography reveals no evidence of extravasation, and the ureteral stent is subsequently removed at 4 weeks to 6 weeks. Diuretic renal scintigraphy or cystography is performed at 3 months and further radiographic follow-up is done at 6 months and 1 year with repeat renal scintigraphy, sonography, or intravenous pyelography (**Figure 3**).

RESULTS

The mean age of the patients was 56 years (range, 35 to 79). Right ureteroneocystostomy was performed in 5 patients and on the left side in one. Procedures in all but one patient were performed completely laparoscopically. One patient had an elective open conversion to complete the ureteral anastomosis when the case was started emergently late in the day. No major intraoperative or postoperative complications occurred. The mean operating room time was 277 minutes (range, 180 to 360). The mean estimated blood loss was 150 mL (range, 50 to 250). The average hospital stay was 2.7 days (range, 2 to 5). Jackson Pratt drains were removed before discharge, and Foley

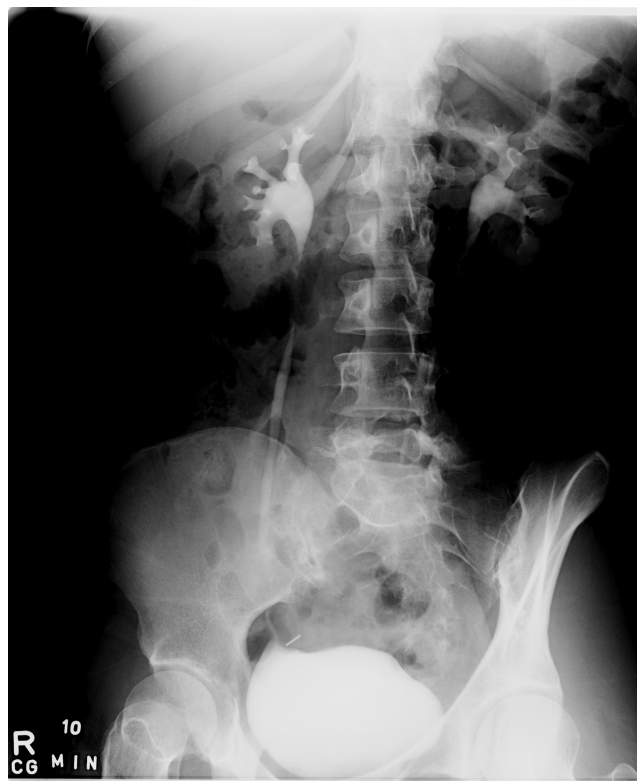

Figure 3. Postoperative intravenous pyelogram demonstrating no obstruction following right laparoscopic ureteral reimplant. [abs]

catheters were removed 7 days to 10 days postoperatively following a cystogram demonstrating no extravasation. Ureteral stents were removed in 4 weeks to 6 weeks with subsequent follow-up imaging as described above. All patients had a successful outcome defined as no evidence of obstruction on renal scintigraphy, refluxing cystography, or intravenous pyelography, and no clinical complaints of persistent renal colic. Postoperative follow-up was 13.2 months (range, 2 to 34).

DISCUSSION

The majority of ureteral injuries are iatrogenic. The 2 most common surgeries in which these injuries occur are pelvic laparoscopic procedures and ureteroscopy. In a literature review of laparoscopic ureteral injury in pelvic surgery by Ostrzenski and colleagues,² 70 reported instances of ureteral injury during laparoscopic surgery were identified among 2491 cases. The incidence of injury ranged from <1% to 2%. The most common procedure associated with ureteral injury was laparoscopic-assisted vaginal hysterectomy (LAVH). Ureteral repair was performed by laparotomy in the majority of cases, with only 11.4% of cases repaired laparoscopically. Since the majority of ureteral injuries are undetected intraoperatively, usually significant adverse sequelae are associated with delayed diagnosis and further treatments. As such, urinary tract injury during gynecological surgery commonly results in medicolegal action.⁵ Thus, it is especially advantageous if this complication can be managed in a minimally invasive manner to decrease further potential morbidity. Additionally, in a recent review, de la Rosette¹ and associates noted ureteral stricture to occur as a late complication of ureteroscopy in 0.5% to 2.5% of cases. However, as with our patients, it is not always known whether the cause of the stricture was the ureteroscopy or the inciting stone itself.

Laparoscopy has infiltrated almost every niche of urological surgery. Countless studies have demonstrated that laparoscopic techniques provide similar success rates with less morbidity, compared with their open counterparts. With the impressive long-term success rates seen with laparoscopic pyeloplasty,⁶ it seems reasonable to expect similar results with laparoscopic management of lower ureteral strictures. The first report of an intraoperative ureteral injury repaired laparoscopically was reported by Gomel and James in 1991.⁷ A transverse laceration on the anterior aspect of the ureter discovered during laparoscopic endometriosis ablation was successfully repaired laparoscopically with sutures and subsequent ureteral stenting. The first case of LUR was reported by Ehrlich and associates⁸ in children with vesicoureteral reflux, and Reddy and Evans⁹ reported the first case in an adult in 1994.

There has been a paucity of reports describing the short-term efficacy of LUR. **Table 2**^{10–13} lists the published series in which there are 3 or more patients. Similar to our study, the 2 series by Modi et al¹² and Nezhat et al¹³ involved patients who had either prior gynecological surgery or treatment of endometriosis. In the series by Modi and colleagues, patients presented with ureterovaginal fistula after a gynecologic procedure that included open abdominal hysterectomy,³ laparoscopic hysterectomy,¹ and vaginal hysterectomy.² In the series reported by Nezhat and associates, 6 patients presented with distal ureteral obstruction secondary to severe endometriosis. This highlights the potential for ureteral injury or obstruction in these at-risk patient populations. Of note, in both series all patients underwent ureteroneocystostomy in combination with psoas hitch. Conversely, 5 of 6 of our patients did not require a psoas hitch due to the utilization of a modified dome advancement technique as described

Table 2.
Series of Laparoscopic Ureteral Reimplantation in Adults

Author	Patients	Cause	Ureteral Reimplant*	LOS* (day)	Complications	Success	F/U* (mo)
Modi et al ¹²	6	Gynecological surgery	Psoas hitch	5.7 (5–6)	0	100%	8 (2–14)
Nezhat et al ¹³	6	Endometriosis	Psoas hitch	N/A	0	100%	33 (28–40)
Fugita et al ¹¹	3	Mixed	Boari flap	7.3 (3–13)	0	100%	11 (6–14)
Simmons et al ¹⁰	7	Iatrogenic, stones, other	LUR (4), Boari flap (3)	2.6 (2–3)	1 (Urinoma)	100%	23 (4–70)

* F/U = follow up; LOS = length of stay; LUR = laparoscopic ureteral reimplant; N/A = not available.

by Lima and associates.³ This technique allows for a tension-free anastomosis of the bladder to a ureter transected cephalad to the iliac vessels, usually without the need for a psoas hitch, transaction of the contralateral bladder pedicle, or complex laparoscopic suturing.

Finally, Simmons and colleagues¹⁰ recently compared their series of laparoscopic¹² and open³⁴ ureteroureterostomy, ureteroneocystostomy, and Boari flap procedures for benign stricture disease. As with our series, the 2 most common causes of stricture formation were iatrogenic (67%) secondary to prior rectal or gynecological procedures or impacted ureteral calculi (24%). The ureteral stricture cause, location, and length were equivalent between the open and laparoscopic groups. The authors reported no statistical difference in the success rates (100% versus 96%, $P=0.544$) and complication rates (8% versus 15%, $P=0.225$) between the laparoscopic and open groups, respectively. However, operative blood loss was greater and hospital stay was longer in the open group.

Contraindications for this procedure are the same as those for an open ureteroneocystostomy. Importantly, a widely patent tension-free anastomosis is critical to success. If the stricture is too long or located more proximally, then the bladder may need to be mobilized cephalad with either a psoas hitch or Boari flap. Although technically more complex, these procedures can also be performed laparoscopically.^{11,12} The obvious limitation of this study is its retrospective nature, small number of patients, and limited follow-up.

CONCLUSION

Distal ureteral injuries are on the rise secondary to complex pelvic laparoscopy and ureteroscopy. The short-term results of LUR are encouraging with excellent success rates and minimal morbidity. Longer follow-up will be necessary to ultimately determine whether LUR will be the approach of choice for distal ureteral strictures.

References:

1. de la Rosette JJ, Skrekas T, Segura JW. Handling and prevention of complications in stone basketing. *Eur Urol.* 2006;50(5):991–998; discussion 998–999.
2. Ostrzenski A, Radolinski B, Ostrzenska KM. A review of laparoscopic ureteral injury in pelvic surgery. *Obst Gynecological Surv.* 2003;58(12):794–799.

3. Lima GC, Rais-Bahrami S, Link RE, Kavoussi LR. Laparoscopic ureteral reimplantation: a simplified dome advancement technique. *Urology.* 2005;66(6):1307–1309.
4. Eichel L, Khonsari S, Lee DI, et al. One-knot pyeloplasty. *J Endourol.* 2004;18(3):201–204; discussion 204.
5. Brudenell M. Medico-legal aspects of ureteric damage during abdominal hysterectomy. *Br J Obstet Gynaecol.* 1996;103(12):1180–1183.
6. Inagaki T, Rha KH, Ong AM, Kavoussi LR, Jarrett TW. Laparoscopic pyeloplasty: current status. *BJU Int.* 2005;(95 suppl 2):102–105.
7. Gomel V, James C. Intraoperative management of ureteral injury during operative laparoscopy. *Fertil Steril.* 1991;55(2):416–419.
8. Ehrlich RM, Gershman A, Fuchs G. Laparoscopic vesicoureteroplasty in children: initial case reports. *Urology.* 1994;43(2):255–261.
9. Reddy PK, Evans RM. Laparoscopic ureteroneocystostomy. *J Urol.* 1994;152(6 pt 1):2057–2059.
10. Simmons MN, Gill IS, Fergany AF, Kaouk JH, Desai MM. Laparoscopic ureteral reconstruction for benign stricture disease. *Urology.* 2007;69(2):280–284.
11. Fugita OE, Dinlenc C, Kavoussi L. The laparoscopic Boari flap. *J Urol.* 2001;166(1):51–53.
12. Modi P, Goel R, Dodiya S. Laparoscopic ureteroneocystostomy for distal ureteral injuries. *Urology.* 2005;66(4):751–753.
13. Nezhat CH, Malik S, Nezhat F, Nezhat C. Laparoscopic ureteroneocystostomy and vesicopsoas hitch for infiltrative endometriosis. *JLS.* 2004;8(1):3–7.