

Cement embolism into the venous system after pedicle screw fixation: case report, literature review, and prevention tips

Ghassan Kerry, Claus Ruedinger, Hans-Herbert Steiner

Department of Neurosurgery, Klinikum Nuernberg, Germany

Abstract

The strength of pedicle screws attachment to the vertebrae is an important factor affecting their motion resistance and long term performance. Low bone quality, *e.g.* in osteopenic patients, keeps the screw bone interface at risk for subsidence and dislocation. In such cases, bone cement could be used to augment pedicle screw fixation. But its use is not free of risk. Therefore, clinicians, especially spine surgeons, radiologists, and internists should become increasingly aware of cement migration and embolism as possible complications. Here, we present an instructive case of cement embolism into the venous system after augmented screw fixation with fortunately asymptomatic clinical course. In addition we discuss pathophysiology and prevention methods as well as therapeutic management of this potentially life-threatening complication in a comprehensive review of the literature. However, only a few case reports of cement embolism into the venous system were published after augmented screw fixation.

Introduction

It is a well-documented fact that the bone mineral density (BMD) has a very important impact on the stability of pedicle screws.^{1,3} Although the pedicles provide a stable screw fixation in vertebral bone, dislocation of pedicle screws remains a significant clinical problem for patients with low bone quality, which number is increasing due to growing elderly population. Subsequently, more age related bone diseases such as instability in cases of vertebral fractures due to osteoporosis or tumors will increase the frequency of pedicle screw instrumentation procedures.

In healthy vertebral bone, bicortical pedicle screws could acquire higher fixation strength than the unicortical.⁴ Additionally, the screw diameter and length also have been proposed to increase the stability.^{5,6} Nevertheless, cement augmented pedicle screw fixation is

often mandatory in cases of osteoporosis bone aiming for achieving the most possible spinal stability. One of the complications of this procedure is the perivertebral cement leak, which has frequently been described. In addition, there is also a potential risk of cement migration into the venous system, which has been rarely documented.

Case Report

An 87-year-old man diagnosed with spondylolisthesis due to a non-traumatic osteoporotic compression fracture of the 3rd lumbar vertebra was admitted to our hospital with severe low back pain associated with load-dependent bilateral buttock pain radiating also bilaterally into the L4 dermatome. Because of the advanced age of the patient, a conservative treatment including physiotherapy and mobilization with a stabilizing orthosis accompanied by oral analgesia was firstly conducted.

Due to progression of pain and vertebral slipping after 6 consecutive months of conservative therapy, a minimal invasive dorsal instrumentation under general anesthesia was ultimately performed.

We chose a percutaneous dorsal approach with 4 stab incisions to insert the pedicle screws and both rods. Admittedly, the BMD was preoperatively not measured. Intraoperatively, a very low bone quality was noted so that pedicle screw augmentation with polymethylmethacrylate (PMMA) cement was conducted to increase the implants stability. Two cc of PMMA per pedicle were injected into the distal tip of the preformed screw hole and along its entire length at the level of the 2nd lumbar vertebral body (VB) under lateral and intermittent anteroposterior fluoroscopy control. Then, 6.5-mm-diameter and 50-mm-long pedicle screws were inserted.

Three cc of PMMA per pedicle were injected into the 4th lumbar VB in the same previous manner. Afterwards, 7.5-mm-diameter and 50-mm-long pedicle screws were inserted. The intraoperative simultaneous fluoroscopy showed no cement extravasations at any time of the procedure. Finally, 90-mm-long rod was inserted to the left side and 80-mm-long rod to the right side; both were then tightened with 2 locking nuts each.

After this procedure, clinical improvements in the form of alleviation of pain and rapid postoperative mobilization were achieved. A routine high resolution computed tomographic scan revealed postoperatively presence of cement in a left laterovertebral lumbar vein extending into the inferior vena cava. A small asymptomatic vascular epidural leak was also observed (Figures 1 and 2). The origin of the leak arose at the level of the augmentation in

Correspondence: Ghassan Kerry, Department of Neurosurgery, Klinikum Nuernberg, Bresslauer Strasse 201, D-90471 Nuremberg, Germany.
T.: +49.911.398.2318 - Fax: +49.911.398.2981.
E-mail: ghassan.kerry@klinikum-nuernberg.de

Key words: pedicle screw augmentation, osteoporosis, cement embolism, polymethylmethacrylate, spinal fracture.

Contributions: the authors contributed equally.

Conflict of interests: the authors declare no potential conflict of interests.

Received for publication: 3 June 2013.
Accepted for publication: 17 June 2013.

This work is licensed under a Creative Commons Attribution NonCommercial 3.0 License (CC BY-NC 3.0).

©Copyright G. Kerry et al., 2013
Licensee PAGEPress, Italy
Orthopedic Reviews 2013; 5:e24
doi:10.4081/or.2013.e24

the 4th lumbar VB.

The patient denied any chest pain or dyspnea and he was not in respiratory distress with respiratory rate of 20/min. Findings of the postoperative cardiopulmonary examinations as well as chest radiograph were age-appropriate within normal ranges.

As thrombosis prophylaxis, the patient received subcutaneously a weight-based low molecular weight heparin and 100 mg/d acetylsalicylic acid orally. No cardiac or respiratory dysfunctions were noticed over the entire treatment period and the patient was discharged 2 weeks postinterventional. Clinically, the patient showed an uncomplicated 1-year follow-up.

Discussion

The cement embolism is a major hazard of augmented pedicle screws. To date, only a few cases of cement migration into the venous system have been reported after augmented pedicle screw fixation (Supplementary Table 1). Nevertheless, it remains unclear whether this complication is rare or rather under-diagnosed. In a study performed by Barragàn-Campos *et al.*,⁷ merely cement leakage into the inferior vena cava showed a statistically significant association with pulmonary cement embolism.

The risk of cement embolism after augmented screw fixation depends on the intraosseous vascular anatomy of the vertebrae on the one hand and technical aspects on the other.

Anatomically, the basivertebral veins lie in the interiors of the vertebral bodies as venous channels communicating anteriorly through small openings on the front and sides of the vertebral bodies with the anterior external vertebral plexuses and converging towards the posterior surfaces into the horizontal branches of the anterior internal vertebral plexuses. The intervertebral veins in the lumbar region open externally into the lumbar veins conveying blood from the internal and external vertebral plexuses.⁸ In our case, we suspect the basivertebral vein as cement embolus access point. A remarkable enlargement of those veins occurs at an advanced age,⁸ which could largely promote cement embolism. The role of vertebrography in minimizing the risk of cement embolism by preventing cement placement within the basivertebral veins is controversial. As for us, we share the notion of the authors, who don't see the vertebrography as a safety feature,⁹ not only because of the different chemical and physical properties of contrast media (CM) in comparison with bone cement, which allow the CM to migrate easily through the venous plexus, but also due to the persistence of intravertebral opacifications which could interfere with cement injection.

Furthermore, cement migration into the intervertebral veins could lead to spinal canal and foraminal narrowing and subsequently to postinterventional radicular compression symptoms. In such cases, a surgical removal of the intraspinal and intraforaminal cement may be necessary. In addition, polymerization-generated heat and ischemia could cause radicular irritation and radiculopathy which cannot be treated surgically.⁷

The technical aspects can be divided in 2 subgroups. The first subgroup is the viscosity of bone cement; the second is the pressure occurring during inserting the bone cement. Those two subgroups have a crucial aspect during the procedure, thus cement embolism is highest possible when it is injected in a low viscous state with high pressure. On the one hand, a cavity should be prolonged to reduce the pressure whilst inserting the cement. On the other hand, the acrylic cement should be injected in a stage of advanced polymerization after being mixed to the consistency of paste.

A meticulous monitoring of the cement flow with a good quality biplane fluoroscopy is essential during injection. If a minimal cement leakage into the perivertebral veins or behind the line of the posterior wall is detected, the procedure should be immediately stopped. Despite good quality lateral fluoroscopy, a laterovertbral cement leakage could be overlapped owing to the intravertebral cement. Therefore, a good quality biplane fluoroscopy or intermittent anteroposterior fluoroscopy could overcome this problem.¹⁰ Nevertheless, the venous cement migration in our case could

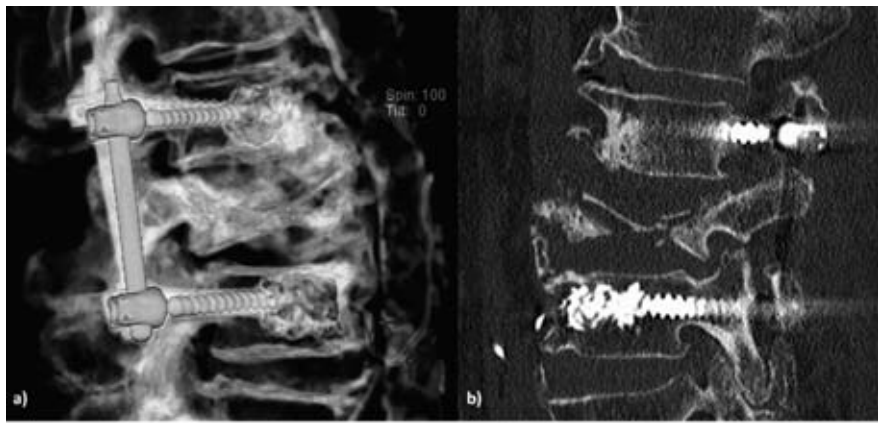


Figure 1. 3D reconstruction (a) and sagittal computed tomography scan (b) showing bone cement migration (arrows) in the perivertebral lumbar vein extending into the inferior vena cava at the level of the 4th VB

not be intraoperatively recognized by using a lateral and intermittent anteroposterior fluoroscopy; most probably due to a low-quality radiograph with a limited viewing angle which made the real-time leakage detection impossible. The quality difference between intraoperatively and postoperatively radiography is mirrored in Figure 3.

Subsuming, the cement migration into the inferior vena cava may have been caused during our procedure by insufficient polymerization of the PMMA at the time of the intraosseous injection in addition to high injection pressure combined with increased cement volume in comparison to the augmentation at the level of the 2nd lumbar VB.

In general, the BMD has a linear relationship with the pullout strength. Moreover, the cement augmentation improves the strength of the screw-bone interface and increases the pullout resistance in osteoporotic vertebrae as well as in revision cases.¹¹ Commonly, PMMA cement is used as an augmentation material. It is non biological, and more stable than calcium phosphate cement (CPC), and cheaper. In a study on human cadaveric vertebrae, Moore DC et al. reported that CPC provides an alternative to PMMA with the advantage of being replaced during bone remodeling. Nevertheless, the pullout strength was increased in average up to 147% with PMMA augmentation and 102% with CPC.¹²

The bone cement can be inserted into the vertebra before inserting the screw, or after that via perforated screws and it can be injected either to the distal tip of the screw hole or along its entire length. Especially in revision cases, the authors of recent publications suggest that the cement injection along the entire screw length produce higher pullout strength than the injection only at the distal tip of the screw.^{13,14} However, the cement injection along the pedicle length is indicated only for intact pedicles, because of possible cement leak

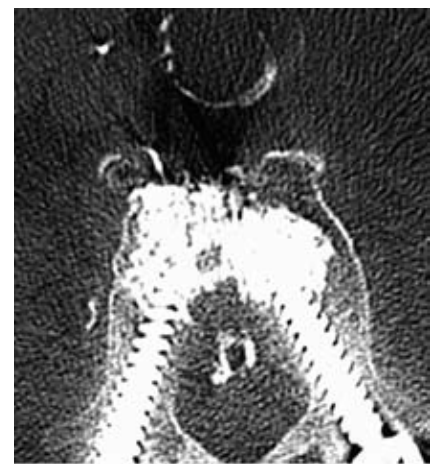

Figure 2. Axial computed tomography scan with bone settings at the level of the cement migration (L4) after pedicle screw augmentation showing bone cement in left laterovertbral lumbar veins, and inferior vena cava, as well as intraspinal (arrows).

through broken pedicles. Furthermore, it is essential to be aware of the position of the most proximal perforation in relation to the insertion depth while inserting the cement via perforated screws, otherwise epidural leakage can occur. The pedicle screws designed with distal perforation could reduce the epidural cement leakage but there biomechanical qualities have not received adequate testing as of yet.¹⁴

Well knowing that the bicortical screws could improve the stability,¹³ the perforation of the anterior vertebral cortex while using bone cement should be avoided to prevent perivertebral cement leakages. A screw implantation depth of more than 50% into the vertebral body should be aimed as well as an optimal ratio between screw width and pedicle width.¹⁵ It is still controversial, whether the convergence of

pedicle screws is biomechanically better than the straight insertion. Barber *et al.* suggest that the angular insertion of pedicle screws by 30° in the coronal plane increases the pullout strength by 28.6%.¹⁶ Nevertheless, the non-convergence method was shown to be more stable in terms of longitudinal linkage.¹⁷ However, clinical analyses of long-term follow-up and further biomechanical studies are needed.

In a three-year follow-up of 37 patients, Moon *et al.* did not report any cement embolism after PMMA augmented screw fixation but extravasations into the ventral aspect of the vertebral body were observed in 5.4% of the cases.¹⁸ However, the low amount of injected cement in Moon *et al.*'s study (1.7-2.0 cc/pedicle) is worthy of particular mention. In comparison, Frankel *et al.* injected PMMA in a range between 2.0-5.0 cc per pedicle and reported on asymptomatic cement extravasations occurred in nine of 23 patients (39%) and one asymptomatic PMMA pulmonary embolus (4%).¹⁹ Fransen *et al.* reported on no cement extravasation in a paper including 3 patients with an injected PMMA amount of 1.5 cc per pedicle in each case.²⁰ Moreover, it is not yet clear if a high-amount of injected PMMA subsequently leads to more implants stability. In this field, a cadaveric study of Frankel *et al.* did not show any significant disparity in the pullout strength of both, small-amount group and high-amount group of injected PMMA.²¹ Nevertheless, a general recommendation for the amount of the injected PMMA into the VB can not be provided due to the anatomical varieties and the small number of adequate studies. Furthermore, Frankel *et al.*'s study showed no significant correlation between volume of used bone cement and cement leakage.¹⁹ However, Ruy *et al.* reported on minimizing the migration of PMMA by the use of smaller volumes of bone cement and slow injection time under low pressure.²²

Moreover, fat embolism was reported after cement augmented pedicle screw fixation and should be considered as a possible complication of the augmented instrumentation of osteoporotic spine, even if its occurrence seems to be rarely in comparison with other complications like cement leaks or screw loosening.²³

In clinical practice, cases of chest pain or dyspnea are initially presented to an internist for primary diagnosis and treatment. If the patient's past medical history is revealing cement augmented screw fixation, especially internists and radiologists should be aware of a possible delayed cement embolism. In cases of pulmonary cement embolism, the patients may remain asymptomatic or may initially claim chest pain, dizziness, sweating, and/or dyspnea. These symptoms can immediately follow the venous cement migration or long time after that; in some reported cases even after hospital discharge.⁹ In such symptomatic

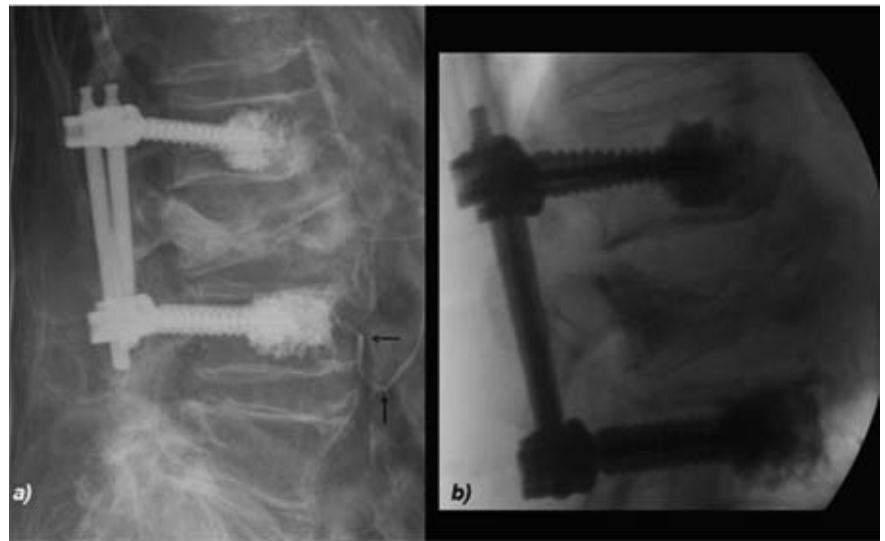


Figure 3. Bone cement migration (arrows) is seen at the postoperatively radiograph (a) but not at the intraoperatively one (b). Note the quality difference between both radiographs.

cases, a chest radiograph should be immediately performed. As an effect of the high density of bone cement compared with lung parenchyma, normal x-ray of the thorax could show cement emboli very well especially in comparison with preoperative chest images. Radiographically, the appearance of tubular or high-density opacities in chest radiographs following the spreading of pulmonary arteries is reconcilable to pulmonary cement embolism.²⁴

The treatment of venous cement embolism depends mainly on the clinical symptoms; therefore, no general treatment recommendation could be found in the literature. Choe *et al.* suggested only clinical follow-up in asymptomatic cases without anticoagulants and reported that the patients remained asymptomatic during long-term follow-up.²⁴ Some authors suggested anticoagulation therapy in symptomatic cases with initial heparinization and a following 6-month coumarin therapy; surgical intervention to remove cement embolus was also reported in symptomatic cases.^{25,26} Furthermore, Tozzi *et al.* reported on thrombi covering most of the acrylic surface of the embolus.²⁶

In our case, we performed prophylactically an initial weight-based anticoagulation therapy with heparin and a long-term antiplatelet therapy with low dose acetylsalicylic acid. Our aim was to prohibit a possible thrombus formation on the embolic cement material in the full knowledge that it is not yet verified whether the venous cement leak has an effect on blood clotting or not.

Conclusions

This paper illustrates an asymptomatic bone cement migration into the inferior vena cava as a complication of augmented screw fixation. However, whether the stiffness or the chemical properties of the cement, or both, may lead to secondary lesions is unknown. Misinterpretation of patient's pain accounts for delay in diagnosis. Therefore, in cases of chest pain after such surgical intervention a chest radiograph should be taken immediately and the possible reconcilability of characteristic radiographic findings with cement pulmonary embolism should be recognized.

Due to the relatively minor number of reported cases and the wide range of possible complication, the ideal treatment of cement embolism is not entirely clear and varies from clinical follow-up, to treatment with anticoagulants, or even surgical embolectomy. Our experience through this case and the observations of others suggest that in cases of cement embolism into the venous system an anticoagulation therapy has no negative effects on the clinical course if the contraindications are respected. Moreover, it appears to be positively effective on the prevention of pulmonary embolism. However, additional studies are needed before recommending any therapeutic approach of this potentially life-threatening complication. Nevertheless, the decision not to start an anticoagulation therapy in asymptomatic cases cannot be interpreted as a lack of treatment as long as no data support the for-

mation of thrombi on the cement. In conclusion, both, creating a void within the vertebral body and cements injection in suitable consistency under low pressure reduce the risk of cement embolism after augmented screw fixation. Furthermore, an early postoperative CT is recommended not only to check the proper implants position but also to detect possible cement migration, which leads to appropriate processing before clinical deterioration.

References

- Halvorson TL, Kelley LA, Thomas KA, *et al.*. Effects of bone mineral density on pedicle screw fixation. *Spine* 1994;19:2415-20.
- Wittenberg RH, Shea M, Swartz DE, *et al.* Importance of bone mineral density in instrumented spine fusions. *Spine* 1991;16:647-52.
- Yamagata M, Kitahara H, Minami S, *et al.* Mechanical stability of the pedicle screw fixation systems for the lumbar spine. *Spine* 1992;7:S51-4.
- Weinstein JN, Rydevic BL, Rauschnig W. Anatomic and technical considerations of pedicle screw fixation. *Clin Orthop Relat Res* 1992;284:34-6.
- Polly DW, Orchowski JR, Ellenbogen RG. Revision pedicle screws: bigger, longer shims - what is best? *Spine* 1998;12:1374-5.
- Zindrick MR, Wiltse LL, Widell EH, *et al.* A biomechanical study of intrapeduncular screw fixation in the lumbosacral spine. *Clin Orthop Relat Res* 1986;:99-112.
- Barragán-Campos HM, Vallée JN, Lo D, *et al.* Percutaneous vertebroplasty for spinal metastases: complications. *Radiology* 2006;238:354-62.
- Gray H. *Anatomy of the Human Body*. Philadelphia: Lea & Febiger; 1918. pp 668-669.
- Bernhard J, Heini PF, Villiger PM. Asymptomatic diffuse pulmonary embolism caused by acrylic cement: an unusual complication of percutaneous vertebroplasty. *Ann Rheum Dis* 2003;62:85-6.
- Jensen ME, Avery JE, Mathis JM, *et al.* Percutaneous polymethylmethacrylate vertebroplasty in the treatment of osteoporotic vertebral body compression fractures: technical aspects. *AJNR Am J Neuroradiol* 1997;18:1897-1904.
- Cho W, Cho SK, Wu C. The biomechanics of pedicle screw-based instrumentation. *J Bone Joint Surg Br* 2010;92:1061-5.
- Moore DC, Maitra RS, Farjo LA, *et al.* Restoration of pedicle screw fixation with an in situ setting calcium phosphate cement. *Spine* 1997;22:1696-705.
- Renner SM, Lim TH, Kim WJ, *et al.* Augmentation of pedicle screw fixation strength using an injectable calcium phosphate cement as a function of injection timing and method. *Spine* 2004;29:E212-6.
- Chen LH, Tai CL, Lee DM, *et al.* Pullout strength of pedicle screws with cement augmentation in severe osteoporosis: a comparative study between cannulated screws with cement injection and solid screws with cement pre-filling. *BMC Musculoskelet Disord* 2011;12:33.
- Becker S, Chavanne A, Spitaler R, *et al.* Assessment of different screw augmentation techniques and screw designs in osteoporotic spines. *Eur Spine J* 2008; 17:1462-9.
- Barber JW, Boden SD, Ganey T, Hutton WC. Biomechanical study of lumbar pedicle screws: does convergence affect axial pull-out strength? *J Spinal Disord* 1998;11:215-20.
- Sterba W, Kim DG, Fyhrie DP, *et al.* Biomechanical analysis of differing pedicle screw insertion angles. *Clin Biomech* 2007;22:385-91.
- Moon BJ, Cho BY, Choi EY, Zhang HY. Polymethylmethacrylate-augmented screw fixation for stabilization of the osteoporotic spine: a three-year follow-up of 37 patients. *J Korean Neurosurg Soc* 2009; 46:305-11.
- Frankel BM, Jones T, Wang C. Segmental polymethylmethacrylate-augmented pedicle screw fixation in patients with bone softening caused by osteoporosis and metastatic tumor involvement: a clinical evaluation. *Neurosurgery* 2007;61:531-7.
- Fransen P. Increasing pedicle screw anchoring in the osteoporotic spine by cement injection through the implant. Technical note and report of three cases. *J Neurosurg Spine* 2007;7:366-9.
- Frankel BM, D'Agostino S, Wang C. A biomechanical cadaveric analysis of polymethylmethacrylate-augmented pedicle screw fixation. *J Neurosurg Spine* 2007;7: 47-53.
- Ryu KS, Park CK, Kim MC, Kang JK. Dose-dependent epidural leakage of polymethylmethacrylate after percutaneous vertebroplasty in patients with osteoporotic vertebral compression fractures. *J Neurosurg* 2002;96:56-61.
- Temple JD, Ludwig SC, Ross WK, *et al.* Catastrophic fat embolism following augmentation of pedicle screws with bone cement: a case report. *J Bone Joint Surg Am* 2002;84:639-42.
- Choe DH, Marom EM, Ahrar K, *et al.* pulmonary embolism of polymethyl methacrylate during percutaneous vertebroplasty and kyphoplasty. *AJR* 2004;183:1097-102.
- Rasch A, Sindermann J, Scheld HH, Hoffmeier A. Pulmonary palacos embolism: a case report. *Thorac Cardiovasc Surg* 2010;58:437-9.
- Tozzi P, Abdelmoumene Y, Corno AF, *et al.* Management of pulmonary embolism during acrylic vertebroplasty. *Ann Thorac Surg* 2002;74:1706-8.