

Case Report

Successful Treatment of Advanced Primary Cutaneous Peripheral T-Cell Lymphoma with Oral Bexarotene Monotherapy

Yota Sato Taku Fujimura Yumi Kambayashi Akira Hashimoto
Setsuya Aiba

Department of Dermatology, Tohoku University Graduate School of Medicine,
Sendai, Japan

Keywords

Primary cutaneous peripheral T-cell lymphoma not otherwise specified · Cutaneous T-cell lymphomas · Treatment · Bexarotene monotherapy

Abstract

Bexarotene is a third-generation retinoid X receptor-selective retinoid that is widely used for the early treatment of advanced-stage cutaneous T-cell lymphomas. In this report, we describe a case of successful treatment of advanced primary cutaneous peripheral T-cell lymphoma not otherwise specified (PTCL-NOS) with oral bexarotene monotherapy. After the administration of oral bexarotene at a dose of 300 mg/m²/day, all skin lesions and lymph nodes regressed, and complete remission was achieved for 1 year. Our case suggested that bexarotene monotherapy could be one of the possible therapies for the treatment of primary cutaneous PTCL-NOS.

© 2018 The Author(s)
Published by S. Karger AG, Basel

Introduction

Bexarotene is widely used for the treatment of early- to advanced-stage cutaneous T-cell lymphomas (CTCL), especially in European countries [1–3]. In addition, bexarotene is not

only administered for the treatment of mycosis fungoides (MF) and Sézary syndrome (SS), but is also useful for other subpopulations of CTCL, including lymphomatoid papulosis, primary cutaneous anaplastic large-cell lymphoma and peripheral T-cell lymphomas not otherwise specified (PTCL-NOS) [4–6]. These reports suggested the diverse anti-tumor effects of bexarotene for CTCL. In this report, we describe a case of successfully controlled advanced primary cutaneous PTCL-NOS by oral bexarotene monotherapy.

Case Report

A 67-year-old Japanese woman visited our outpatient clinic with ulcerated, infiltrated erythema and subcutaneous nodules on the left lower leg. She had been treated for CTCL with interferon for 8 years. On her initial visit, physical examination revealed prominent, infiltrated erythema on the bilateral lower legs (Fig. 1a). In addition, PET-CT scan revealed increased levels of standard uptake at the right axillary, left subclavicular, left internal deep cervical, and right inguinal lymph nodes (Fig. 1b). A biopsy specimen from the left lower leg revealed atypical lymphoid cells densely infiltrated from the upper dermis to the subcutaneous tissue without epidermotropism (Fig. 1c, d). Immunohistochemical staining revealed that these atypical lymphocytes, which were distributed throughout the dermis, were positive for CD3, CD4, CD5, and CD45, and negative for CD7, CD8, CD30, CD56, and EBER. Assessment of T-cell receptor gene rearrangement by Southern blot analysis confirmed the monoclonality of the T-cell receptor β -chain. In addition, the biopsy specimen from lymph nodes revealed infiltration of the same phenotypes of atypical lymphocytes with abnormal lymph node structure. From the above findings, we diagnosed this patient as having primary cutaneous PTCL-NOS (T3bN3M0 stage IIIB). We administered oral bexarotene 300 mg/m²/day and the infiltrated erythemas gradually regressed. Six months after the administration of bexarotene, all infiltrated erythemas had disappeared together with the pigmentation and scarring (Fig. 1e). Moreover, follow-up PET-CT scan revealed normal levels of standard uptake at all lymph nodes (Fig. 1f). One year after the remission of the infiltrated erythema and lymph node swelling, PTCL-NOS was still under remission.

Discussion

Numerous treatments have been used for advanced CTCL and the treatments also differ according to the country. Quaglino et al. [1] reported a large multicenter retrospective analysis of global patterns of care for advanced MF and SS, suggesting that the heterogeneity in treatment was not related to disease survival except for chemotherapy as a first treatment. Among them, bexarotene is administered as an early treatment for MF and SS in both the USA and other countries, though interferon is administered as a first-line treatment for MF and SS in non-US countries [1]. This global study suggested the potency of bexarotene for the treatment of advanced CTCL.

Bexarotene is a third-generation retinoid X receptor-selective retinoid and the mechanisms of its anti-tumor effects are diverse [7]. Bexarotene induces the normalization of keratinocyte differentiation [8] as well as dose-dependent apoptosis of CTCL cells by reducing serum IL-4 [9]. In addition, bexarotene reduces the expression of CCR4 and E-selectin, leading to suppressed migration of CTCL cells in the lesional skin [10]. These reports supported clinical benefits of bexarotene for the treatment of CTCL. Indeed, a clinical trial for the

treatment of advanced CTCL with bexarotene has been reported [2, 3, 11], suggesting that bexarotene is effective for both early and advanced CTCL. Focusing on advanced CTCL, Duvic et al. [2] reported that 55% (21 of 38) of advanced CTCL patients (stage IIB–IVB) responded to bexarotene monotherapy with 13% (5 of 38) attaining complete response by the conventional dose of 300 mg/m²/day. Moreover, the rate of relapse after response was 36% and the projected median duration of the response was 299 days, suggesting difficulties in maintaining a complete response with bexarotene monotherapy in advanced CTCL patients.

In this report, we describe a case of successful long-term control of advanced primary cutaneous PTCL-NOS with oral bexarotene monotherapy. Indeed, after the administration of oral bexarotene at the conventional dose, all skin lesions and lymph nodes regressed achieving complete remission for 1 year. Our case suggested that bexarotene monotherapy could be one of the possible therapies for the treatment of primary cutaneous PTCL-NOS. Since this report presents only a single case, further cases may provide more fundamental insights into the efficacy of bexarotene on primary cutaneous PTCL-NOS.

Statement of Ethics

The patient gave written informed consent.

Disclosure Statement

The authors have no conflicts of interest to declare.

References

- 1 Quaglino P, Maule M, Prince HM, Porcu P, Horwitz S, Duvic M et al. Global patterns of care in advanced stage mycosis fungoides/Sezary syndrome: a multicenter retrospective follow-up study from the Cutaneous Lymphoma International Consortium. *Ann Oncol*. 2017 Oct;28(10):2517–25.
- 2 Duvic M, Hymes K, Heald P, Breneman D, Martin AG, Myskowski P et al; Bexarotene Worldwide Study Group. Bexarotene is effective and safe for treatment of refractory advanced-stage cutaneous T-cell lymphoma: multinational phase II-III trial results. *J Clin Oncol*. 2001 May;19(9):2456–71.
- 3 Duvic M, Martin AG, Kim Y, Olsen E, Wood GS, Crowley CA et al; Worldwide Bexarotene Study Group. Phase 2 and 3 clinical trial of oral bexarotene (Targretin capsules) for the treatment of refractory or persistent early-stage cutaneous T-cell lymphoma. *Arch Dermatol*. 2001 May;137(5):581–93.
- 4 Tanita K, Fujimura T, Sato Y, Hidaka T, Furudate S, Kambayashi Y et al. Successful Treatment of Primary Cutaneous Peripheral T-Cell Lymphoma Presenting Acquired Ichthyosis with Oral Bexarotene Monotherapy. *Case Rep Oncol*. 2017 Apr;10(1):328–32.
- 5 Fujimura T, Furudate S, Tanita K, Sato Y, Kambayashi Y, Hidaka T et al. Successful control of phototherapy-resistant lymphomatoid papulosis with oral bexarotene. *J Dermatol*. 2018 Feb;45(2):e37–8.
- 6 Oliveira A, Fernandes I, Alves R, Lima M, Selores M. Primary cutaneous CD30 positive anaplastic large cell lymphoma: report of a case treated with bexarotene. *Leuk Res*. 2011 Nov;35(11):e190–2.
- 7 Panchal MR, Scarisbrick JJ. The utility of bexarotene in mycosis fungoides and Sézary syndrome. *Oncotargets Ther*. 2015 Feb;8:367–73.
- 8 Smit JV, de Jong EM, van Hooijdonk CA, Otero ME, Boezeman JB, van de Kerkhof PC. Systemic treatment of psoriatic patients with bexarotene decreases epidermal proliferation and parameters for inflammation, and improves differentiation in lesional skin. *J Am Acad Dermatol*. 2004 Aug;51(2):257–64.
- 9 Budgin JB, Richardson SK, Newton SB, Wysocka M, Zaki MH, Benoit B et al. Biological effects of bexarotene in cutaneous T-cell lymphoma. *Arch Dermatol*. 2005 Mar;141(3):315–21.
- 10 Richardson SK, Newton SB, Bach TL, Budgin JB, Benoit BM, Lin JH et al. Bexarotene blunts malignant T-cell chemotaxis in Sezary syndrome: reduction of chemokine receptor 4-positive lymphocytes and decreased chemotaxis to thymus and activation-regulated chemokine. *Am J Hematol*. 2007 Sep;82(9):792–7.

- 11 Hamada T, Sugaya M, Tokura Y, Ohtsuka M, Tsuboi R, Nagatani T et al. Phase I/II study of the oral retinoid X receptor agonist bexarotene in Japanese patients with cutaneous T-cell lymphomas. *J Dermatol.* 2017 Feb;44(2):135–42.

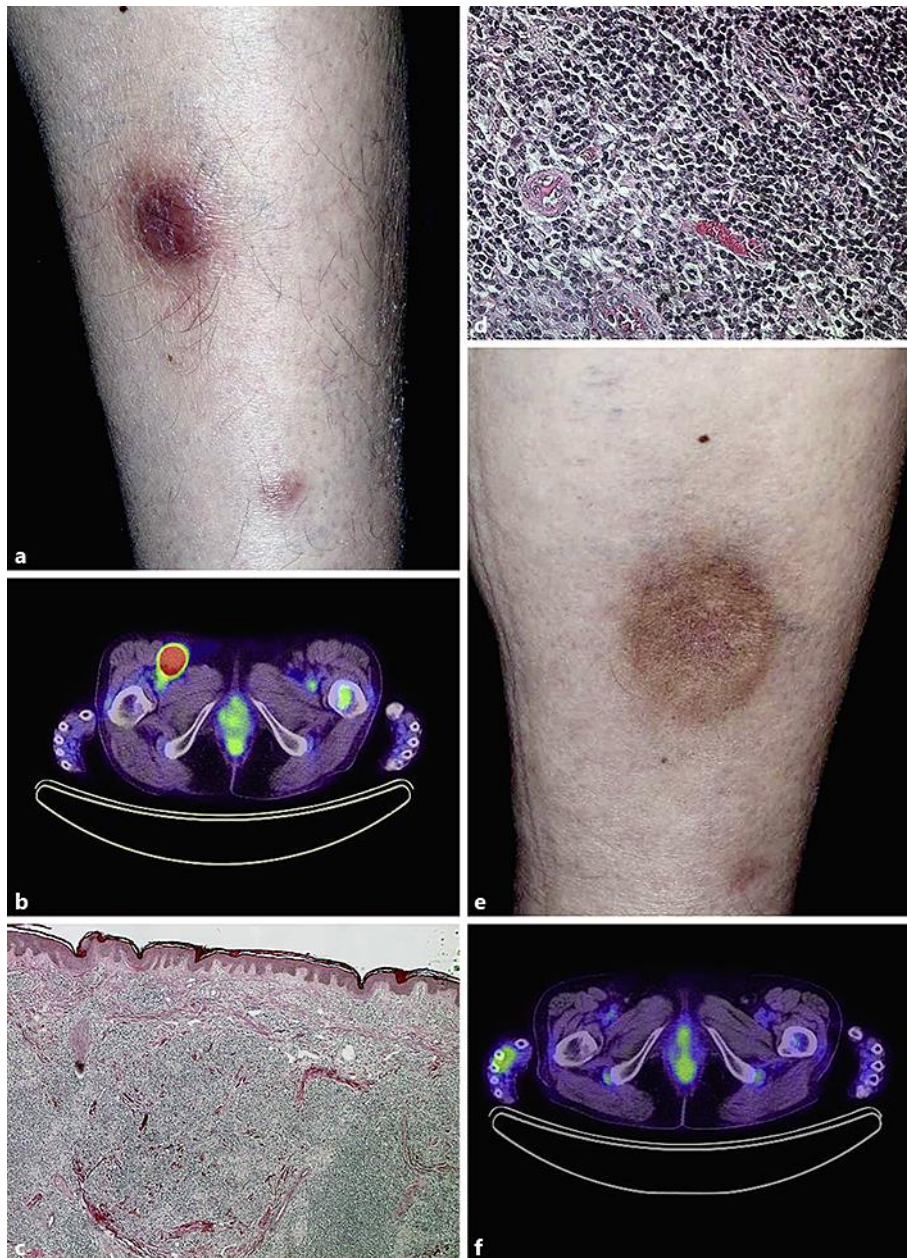


Fig. 1. Prominent, infiltrated erythema on the left lower leg (a). Increased levels of standard uptake at the right inguinal lymph nodes (b). Atypical lymphoid cells densely infiltrated from the upper dermis to the subcutaneous tissue without epidermotropism (H&E staining; original magnification $\times 50$ [c], $\times 400$ [d]). Six months after the administration of bexarotene, the infiltrated erythema on the left lower leg had regressed (e) and the levels of standard uptake at right inguinal lymph nodes were normal (f).